

PDF hosted at the Radboud Repository of the Radboud University Nijmegen

The following full text is a publisher's version.

For additional information about this publication click this link.

<http://hdl.handle.net/2066/81858>

Please be advised that this information was generated on 2020-10-28 and may be subject to change.

CLINICAL INVESTIGATION

Lymphoma

PROGRESSIVE MUSCLE ATROPHY AND WEAKNESS AFTER TREATMENT BY
MANTLE FIELD RADIOTHERAPY IN HODGKIN LYMPHOMA SURVIVORS

ELENA M. VAN LEEUWEN-SEGARCEANU, M.D.,* LUCILLE D. A. DORRESTEIJN, M.D., PH.D.,[†]
SIGRID PILLEN, M.D., PH.D.,[‡] DOUWE H. BIESMA, M.D., PH.D.,[§] OSCAR J. M. VOGELS, M.D., PH.D.,[¶]
AND NENS VAN ALFEN, M.D., PH.D.[‡]

Departments of *Internal Medicine and [¶]Neurology and Clinical Neurophysiology, St. Antonius Hospital, Nieuwegein; [†]Department of Neurology, Medisch Spectrum Twente, Enschede; [‡]Department of Neurology and Clinical Neurophysiology, Donders Center for Neuroscience, Radboud University Nijmegen Medical Center, Nijmegen; and [§]Department of Internal Medicine, University Medical Center Utrecht, The Netherlands

Purpose: To describe the damage to the muscles and propose a pathophysiologic mechanism for muscle atrophy and weakness after mantle field radiotherapy in Hodgkin lymphoma (HL) survivors.

Methods and Materials: We examined 12 patients treated by mantle field radiotherapy between 1969 and 1998. Besides evaluation of their symptoms, the following tests were performed: dynamometry; ultrasound of the sternocleidomastoid, biceps, and antebrachial flexor muscles; and needle electromyography of the neck, deltoid, and ultrasonographically affected arm muscles.

Results: Ten patients (83%) experienced neck complaints, mostly pain and muscle weakness. On clinical examination, neck flexors were more often affected than neck extensors. On ultrasound, the sternocleidomastoid was severely atrophic in 8 patients, but abnormal echo intensity was seen in only 3 patients. Electromyography of the neck muscles showed mostly myogenic changes, whereas the deltoid, biceps, and antebrachial flexor muscles seemed to have mostly neurogenic damage.

Conclusions: Many patients previously treated by mantle field radiotherapy develop severe atrophy and weakness of the neck muscles. Neck muscles within the radiation field show mostly myogenic damage, and muscles outside the mantle field show mostly neurogenic damage. The discrepancy between echo intensity and atrophy suggests that muscle damage is most likely caused by an extrinsic factor such as progressive microvascular fibrosis. This is also presumed to cause damage to nerves within the radiated field, resulting in neurogenic damage of the deltoid and arm muscles. © 2012 Elsevier Inc.

Hodgkin lymphoma, Dropped head syndrome, Mantle field radiotherapy, Muscle damage, Muscle ultrasound.

INTRODUCTION

The survival of Hodgkin lymphoma (HL) patients has improved significantly during the past decades, with 70–97% of the present cases being cured (1–3). With longer follow-up, it has become apparent that survivors of HL carry risks for treatment-related side effects that may not manifest until many years later (4, 5). In patients previously treated by radiotherapy (RT), cardiovascular complications and secondary malignant tumors have the greatest impact on the patients' survival and have been extensively investigated (6–9).

Less frequently reported late effects are atrophy and weakness of the muscles within the radiation fields (10–14). A considerable number of HL survivors report pain, stiffness, or weakness of the muscles; in two reports, 25% and 50%

of patients treated by mantle field RT experience these problems after a mean of 10 and 19 years of follow-up (15, 16). Although the mantle field technique has been replaced in recent years by less extensive radiation fields, many patients are still alive who have been treated by this method. As an estimate, 573 HL survivors were treated by RT including the mantle field in a large trial from 1993 to 1999 in eight European countries (3). The 10-year overall survival was 92% and 84% for patients with favorable and unfavorable features, respectively (3), leaving about 500 patients still alive who were treated during this period with mantle field RT. Furthermore, in a recent cohort study performed in four centers in The Netherlands, 1,415 HL survivors were identified who were treated by mantle field RT between 1965 and 1995 (7).

Reprint requests to: Elena M. van Leeuwen-Segarceanu, M.D., Department of Internal Medicine, St. Antonius Hospital, Koekoekslaan 1, 3435 CM Nieuwegein, The Netherlands. Tel: (+31) 88-3203000; Fax: (+31) 30-6056357; E-mail: e.segarceanu@antoniusziekenhuis.nl

Conflict of interest: none.
Received July 26, 2010, and in revised form Nov 1, 2010.
Accepted for publication Nov 2, 2010.

Muscular symptoms of the neck and shoulder areas have a long-onset latency (12, 13). Inasmuch as weakness may be progressive, clinicians dealing with HL survivors will be confronted with these symptoms and should have knowledge about the treatment and prognosis of these late effects. The aim of this study was to gain more insight into the pathophysiology and the clinical picture of muscle atrophy in HL survivors treated by the mantle field technique. Furthermore, we give suggestions for the management of these late effects.

METHODS AND MATERIALS

Patients

Between November 2007 and August 2008, 81 HL survivors were enrolled in a study to evaluate the late sequelae of treatment. Ethical approval was given by the Institutional Review Board of the St. Antonius hospital, Nieuwegein. All HL survivors registered at our institution who were free of disease and had been followed up for more than 2 years from the diagnosis of HL were invited to participate ($n = 113$). Nineteen HL survivors were deceased; 7 HL survivors did not attend their regular checkups and could not be traced. Another 6 HL survivors declined participation because of old age ($n = 3$), long traveling distance ($n = 1$), or no specific reason ($n = 2$).

Part of this study included neurologic examination including determination of muscle strength. Twenty patients had been irradiated by mantle field RT (Table 1). They were all considered candidates for the current study. Three patients were not invited to participate because of recently diagnosed metastatic malignancy ($n = 2$) or end-stage heart failure ($n = 1$). Five of the remaining 17 patients refused participation because of long traveling distance ($n = 3$), advanced age ($n = 1$), and absence of neck symptoms ($n = 1$). Twelve patients (8 women and 4 men) gave informed consent (Fig. 1). The baseline characteristics did not differ from those of the HL survivors treated by mantle field RT who were not included.

Treatment characteristics

In all patients the total RT dose to the mantle field was 40 Gy in 20 fractions of 2 Gy, given in anterior-posterior and posterior-anterior fields on alternate days. Over the years the RT techniques

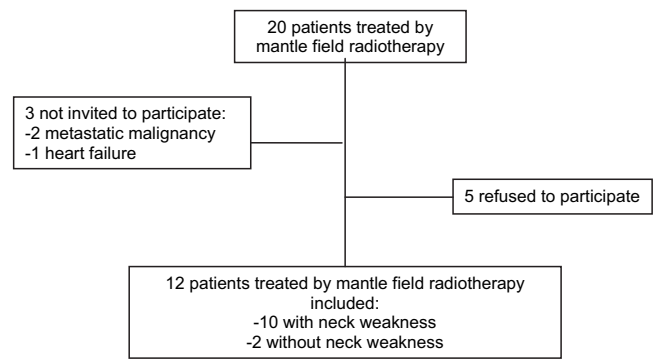


Fig. 1. Selection of study population.

have changed. Until 1976, a cobalt-60 unit was used, and after that a 6 to 10-MV linear accelerator was used. Three patients were also treated with chemotherapy.

Clinical examination

All patients were examined according to a standardized protocol. A detailed history was taken about previous neurologic symptoms or operations before treatment for HL. Patients were asked to fill in a customized questionnaire including all neurologic symptoms and functional impairments we had encountered in the whole group. Furthermore, two standardized questionnaires were distributed: the Neck Disability Index to enquire about neck symptoms (17) and the Checklist Individual Strength-20 (CIS-20) to examine fatigue (18).

A detailed clinical examination was performed by a senior staff neurologist (O.J.M.V.). Strength of the neck flexor muscles was assessed with the patient in supine position, and the neck extensors with the patient in a prone position. Both were graded according to the Medical Research Council (MRC) scale (19).

Muscle strength was also measured with a hand-held dynamometer (Citec dynamometer CT 3001, C.I.T. Technics, Groningen, The Netherlands) in five different muscle groups (neck flexors, neck extensors, shoulder abductors, elbow flexors, and grip strength). Maximum muscle strength was tested using the break method, in which the examiner gradually overcomes the muscle strength of the patient and stops at the moment the extremity gives way (20). Grip

Table 1. Baseline characteristics of the total cohort of 81 Hodgkin lymphoma survivors

Characteristic	Treatment		
	Mantle field RT ($n = 20$)	RT on the neck only ($n = 19$)	No RT on the neck ($n = 42$)
Sex, male	10	10	28
Age (y) \pm SD	53 \pm 10	40 \pm 11	49 \pm 13
RT dose (Gy) \pm SD	40 \pm 1*	36 \pm 4 [†]	–
Follow-up since diagnosis (y) \pm SD	23 \pm 8	9 \pm 5	11 \pm 7
Patients with neck muscle weakness, total	17 (83%)	4 (21%)	4 (10%)
Patients with neck muscle weakness according to follow-up (y) since RT			
<10	–	0/13	
10–19	6/8	4/6	
20–29	7/8	–	
>30	4/4	–	

Abbreviations: RT = radiotherapy; SD = standard deviation.

* Dose to the mantle.

[†] Dose to the neck.

strength was measured using the make method, requiring the patient to exert maximal pressure on the dynamometer. In each patient every muscle group was measured three times and the average score was calculated. Results under the 5th percentile of the normal population (adjusted for sex) were considered abnormal (21).

Ancillary investigations

Quantitative muscle ultrasound. Muscle ultrasound examinations were performed on the sternocleidomastoid, the biceps, and the antibrachial flexor muscles using a standard technique and normal values as described previously (22, 23). A broadband linear 5- to 17-MHz transducer (Philips IU22, The Netherlands) was used. All system-setting parameters were kept constant throughout the study (gain 70 dB, compression 55, no adjustments in time gain compensation or focus). For echo intensities, three consecutive measurements were taken of every muscle under study, and the results were averaged. The mean muscle echo intensity was calculated from a region of interest comprising as much muscle tissue as possible without the surrounding fascia, using a histogram-based grey-scale analysis with 256 grey levels (23). Muscle thickness was measured with electronic calipers. Increased echo intensity is indicative of an intrinsic muscle disease (24).

To compare individual patients and muscles in this study, echo intensity and muscle thickness were transformed into Z scores. The Z score reflects the number of standard deviations a measure deviates from normal, given a certain age and sex. Abnormal echo intensity for individual muscles was defined as a Z score of more than 2. For muscle atrophy, the same cutoff value was used (Z score below -2).

Nerve conduction studies and needle electromyography. Electrophysiologic examination was performed using standard techniques with a Medelec Synergy electromyography (EMG) system (Viasys, Oxford Medical Instruments, Surrey, UK). Both nerve conduction studies and needle EMG were performed according to standardized clinical protocols for the detection of polyneuropathy and myopathy. Findings were compared to normal values from our cen-

ter's database. Nerve conduction studies included sensory nerve action potential (SNAP) amplitude and nerve conduction velocity of both median nerves to the third digit and both superficial radial nerves. Needle EMG of the splenius capitis, sternocleidomastoid, and deltoid muscles was performed bilaterally in all patients. Additional needle EMG was performed of the biceps and antibrachial flexor muscles if they showed abnormal echo intensity on ultrasound.

Statistical analysis

Statistical analysis was performed using SPSS version 15.0 (SPSS Inc., Chicago, IL). One-sample *t*-tests were conducted for comparison between the echo intensity or muscle thickness Z scores and 0 (the standardized value for certain age and sex).

RESULTS

HL survivors

Baseline characteristics of the HL survivors ($n = 81$) are presented in Table 1. Neck muscle weakness revealed by clinical examination had a prevalence of 31%, being highest in the subgroup of patients treated by mantle field RT: 85%. This high percentage was not found in patients treated by RT to the neck only (25%). These patients were treated more recently and with lower-dose RT, reflecting a change in the treatment approach during more recent years. The percentage of patients with neck weakness increased from 0% (0/13) in patients irradiated less than 10 years ago to 71% (10/14), 88% (7/8), and 100% (4/4) in patients irradiated between 10 and 20 years ago, 20 and 30 years ago, and more than 30 years ago, respectively.

Mantle field subgroup

Demographic data of the subgroup of 12 mantle field patients are presented in Table 2. Nine patients had other

Table 2. Demographic characteristics of 12 Hodgkin lymphoma survivors treated by mantle field radiotherapy

Patient	Age (y)	Sex	Treatment year	Chemotherapy	Comorbidity	MRC grade neck flexors
1	62	M	1973	No	Aortic valve stenosis, RT induced osteoporosis, cervical spine arthrodesis	4
2	58	M	1982	No	Aortic valve stenosis, myocardial infarction	3-
3	47	F	1983	Yes 3 × MOPP	Lung fibrosis, thyroid dysfunction	3-
4	60	M	1981	No	Atherosclerosis carotid artery, CAD, thyroid dysfunction, osteoporosis, esophageal stricture	2
5	58	F	1985	Yes 3 × MOPP	Breast cancer, thyroid dysfunction, persistent tachycardia	2
6	62	F	1993	No	-	3+
7	52	M	1969	No	CAD, constrictive pericarditis, thyroid cancer, lung fibrosis	3+
8	47	F	1978	No	Breast cancer, thyroid dysfunction, constrictive pericarditis, aortic valve replacement	3+
9	34	F	1997	No	Lung fibrosis, thyroid dysfunction	3+
10	50	F	1987	No	Breast cancer, CAD, thyroid dysfunction	4-
11	55	M	1991	Yes 8 × MOPP/ ABV	-	5
12	48	M	1985	No	-	5

Abbreviations: RT = radiotherapy; MRC = Medical Research Council scale; MOPP = mechlorethamine, vincristine, prednisone, procarbazine; CAD = coronary artery disease; ABV = doxorubicin, bleomycin, vinblastin.

comorbidities within the radiation field, including three women with breast cancer treated by mastectomy.

Neck symptoms were present in 10 patients. (Table 3). They reported pain and fatigue in the neck muscles which already started a few years after RT. Neck symptoms were constantly present in 2 patients and were triggered by activities during which the head had to be held in the same position for more than 30 minutes in 8 patients. The patients experienced more frequent headaches than before receiving RT; they also experienced pain and weakness in the shoulders and arms. Because of these symptoms, patients were particularly disabled in the following activities: walking for more than 30 minutes, swimming, lifting the head while in a supine position, driving a car, working on the computer, reading, and lifting heavy bags. Ten patients were using pain medication for neck pain on a regular basis, or had repeat-

edly consulted a physiotherapist with satisfactory but only temporary relief.

On the CIS-20 scale, 10 patients had mean scores exceeding 35 points, meeting the criterion for chronic fatigue. On the Neck Disability Index, the mean and median scores of the total group were 14 and 17 (range, 0–25) (Table 3).

Clinical examination

The 10 patients with neck symptoms were found to have neck flexor weakness on clinical examination. This was graded 2–4+ on the MRC scale. Neck extension was less often impaired in 6 of the 12 patients. In 2 patients a dropped head syndrome was observed, signifying a Grade <3 paresis on the MRC scale (*i.e.*, a disability of the neck extensors to overcome gravity in prone position). On muscle dynamometry, muscle weakness in one or more of the investigated muscles was found in all but 4 patients (Table 3).

Muscle ultrasound

Muscle ultrasound showed atrophy of the sternocleidomastoid muscles in all but 1 patient. The mean Z score of this muscle was -2.27 , significantly lower than in the normal population ($p < 0.01$). In contrast with the decrease in muscle volume, the echo intensity was rarely above 2 standard deviations in the sternocleidomastoid muscles. Abnormal findings on ultrasound were rare in the muscles outside the radiation field (Table 3).

Nerve conduction studies

Nerve conduction studies showed abnormalities in 6 patients, of whom only 1 had been treated by chemotherapy (Patient 11). One patient had low SNAP amplitudes and borderline low conduction velocities of all investigated nerves. Another patient had borderline low amplitude SNAP of the superficial radial nerves on both sides and borderline low nerve conduction velocities of both median nerves. Three patients had low SNAP amplitudes of the superficial radial nerves; in 1 patient this was present unilaterally. Finally, 1 patient had isolated low nerve conduction velocity of the right median nerve at the wrist segment, compatible with a (subclinical) carpal tunnel syndrome unrelated to the RT.

Needle EMG

Needle EMG showed abnormal findings in the majority of the neck and deltoid muscles. Abnormalities were less prevalent in the biceps and antibrachial flexor muscles (Table 3).

Myogenic changes (small amplitude, short-duration motor unit action potentials) were most prevalent in the cervical muscles, occurring in 11 patients (Fig. 2). Only 1 patient showed light neuropathic changes (large amplitude, long-duration motor unit action potentials) in the neck muscles. The deltoid muscles showed mostly neuropathic abnormalities in 6 patients, whereas myogenic changes and mixed changes were present in 3 patients and 1 patient, respectively. The biceps and antibrachial flexor muscles showed neuropathic damage in all patients investigated except for 1 patient. No spontaneous activity pointing to denervation

Table 3. Results in 12 Hodgkin lymphoma survivors treated by mantle field radiotherapy

Investigation	Abnormal findings (n)
Questionnaire about neck symptoms:	
Neck pain	9 (75%)
Tired feeling in the neck muscles	7 (58%)
Hanging neck	7 (58%)
Thinner neck	9 (75%)
Neck Disability Index	9 (75%)
Severely disabled (score 25–34)	1 (8%)
Moderately disabled (score 15–24)	5 (42%)
Mildly disabled (score 5–14)	3 (25%)
CIS-20	10 (83%)
Clinical examination (MRC scale)	
Neck flexors	10 (83%)
Neck extensors	6 (50%)
Dynamometry	
Neck flexors	8 (67%)
Neck extensors	4 (33%)
Shoulder abductor	8 (67%)
Elbow flexors	5 (42%)
Antebrachial flexors	2 (17%)
Echo intensity	
Sternocleidomastoid muscles	3 (25%)
Biceps muscles	3 (25%)
Antebrachial flexor muscles	3 (25%)
Diameter	
Sternocleidomastoid muscles	8 (67%)
Biceps muscles	1 (8%)
Antebrachial flexor muscles	0
Needle EMG	
Sternocleidomastoid muscles	12 (100%)
Splenius capitis muscles	12 (100%)
Deltoid muscles	10 (83%)
Biceps muscles	2 (17%)
Antebrachial flexors	5 (42%)
Nerve conduction studies	
SNAP amplitude median nerves	1 (8%)
SNAP amplitude radial nerves	5 (42%)
Conduction velocity median nerves	2 (25%)
Conduction velocity radial nerves	1 (8%)

Abbreviations: CIS-20 = Checklist Individual Strength-20; MRC = Medical Research Council scale; EMG = electromyography; SNAP = sensory nerve action potential.

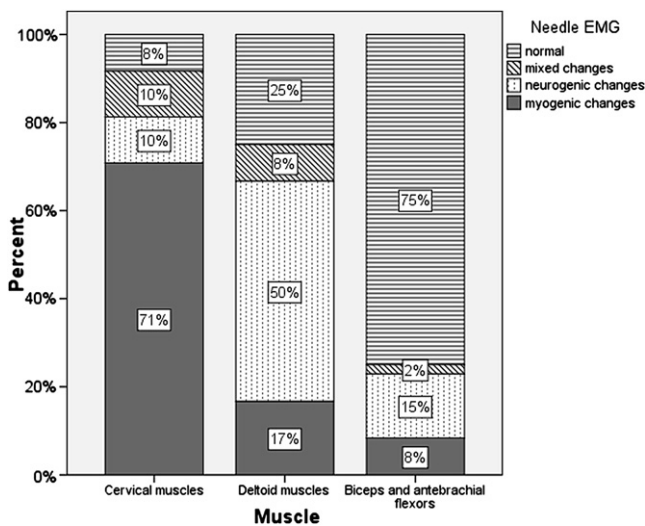


Fig. 2. Results of needle electromyography (EMG).

or myositis was found in any of the patients, but 2 patients showed myokymia, 1 in the right deltoid and the other in the right sternocleidomastoid muscle.

DISCUSSION

Clinical findings

Neck muscle weakness is a very frequent late complication in HL survivors treated with mantle field RT, occurring in 85% of the patients in our cohort. Patients with impaired neck muscle strength have a large scale of symptoms, which negatively influence their daily activities and result in increased fatigue scored on the CIS-20 scale. Mantle field RT survivors with preserved neck muscle strength do not experience such severe symptoms.

All patients diagnosed with cervical muscle weakness were radiated more than 10 years ago, and most patients (11/12) had an onset latency of more than 15 years. These findings are in line with previous reports describing symptomatic neck muscle weakness mostly occurring more than 10 years after RT (13). The progressive character of the muscle damage is shown by the fact that no patients irradiated less than 10 years ago had weakness, compared to diminished strength in all survivors treated more than 30 years ago. Longer follow-up of patients treated by more recent radiation techniques and lower dose will show whether these patients will also develop cervical muscle weakness.

Few reports on HL survivors with impaired neck muscle strength describe patients with neck extensor weakness, presenting with a dropped head syndrome (13, 25). Clinically, we found predominantly neck flexor weakness. When we examined the neck flexors and extensors by needle EMG, all patients showed an equal amount of abnormalities in both muscle groups, suggesting that both the anterior and the posterior neck compartments are equally affected by RT.

To our knowledge, our study is the first to perform systematic testing of all neck muscles in an unselected group of patients who have received mantle field treatment. Typically,

patients do not consult their physicians because of neck flexor weakness because this manifests in impairment of lifting the head from the pillow or maintaining head position when swimming on the back, and these are not very debilitating symptoms, in contrast to the dropped head syndrome that occurs when severe damage to the neck extensors develops (26).

Two mantle-field irradiated HL survivors did not show neck muscle weakness at all. After receiving RT, they had both engaged in sport activities in which the neck muscles are trained (rowing and water polo). Possibly, muscle strength training may have prevented neck muscle weakness. Interestingly, they showed no late sequelae in other structures, either (cardiac valves, carotid wall, thyroid gland). Apparently, some patients are less vulnerable to radiation-induced damage in these tissues, possibly because of genetic differences in radiosensitivity (27).

Pathophysiology

There is no consensus about the cause of the muscle atrophy in the few studies performed so far. Several theories have been proposed based on a small number of cases (10, 11, 13, 28, 29). Some findings have been consistent with primary damage to the neurons, others showed primary damage to the muscles or to extrinsic factors like the vasculature or the connective tissue respectively.

In our study the sternocleidomastoid muscle was severely atrophic in 67% of patients, and the group as a whole had a significant lower diameter (and thus volume) of this muscle in comparison to the general population. The discrepancy between this severe atrophy and the mostly normal echo intensity suggests that muscle damage is most likely caused by an extrinsic factor (*e.g.*, progressive microvascular fibrosis). This was hypothesized earlier by Fajardo *et al.*, who showed that capillaries are susceptible to radiation damage (30).

Needle EMG of the neck muscles in the radiation field showed mostly myogenic changes, with small motor units consistent with the amount of atrophy found. This pattern has also been found by others (10, 11, 13), but our study includes the largest number of patients and shows a consistent pattern of myogenic changes in 71% of the muscles entirely situated within the radiation field. Twenty percent of the neck muscles showed neuropathic or mixed changes, which can presumably also be explained by vascular injury triggering nerve damage.

The deltoid muscles, which are partially in the radiation field, and the muscles entirely outside the radiation field seemed to have mostly neuropathic damage on needle EMG, suggesting primary affection of the nerve roots and brachial plexus, which are situated in the radiation field for a long distance. The axillary nerves that innervate the deltoid muscles are especially prone to injury because they have a smaller diameter and are situated in the axilla, which receives a substantial amount of the radiation (31). Only 1 of the 3 patients who were treated by chemotherapy showed neuropathic changes, so this did not substantially contribute to this finding. The myogenic changes in the deltoid muscles

could have been directly caused by radiation to these muscles, inasmuch as there is some dispersion of radiation, as shown in dosimetry studies (31).

We did not perform muscle biopsy in these patients to confirm our hypothesis. However, a myogenic origin of damage in irradiated muscles was shown in four previous reports analyzing muscle biopsy specimens (10–12). One case report describing the trapezius muscle in a 42-year-old HL survivor previously treated by mantle field RT was suggestive of nemaline myopathy (12). This disorder, characterized by muscle atrophy and intracytoplasmic rod formation in the myofibers, has been observed in a variety of settings (*e.g.*, polymyositis, spinal progressive muscle atrophy, acute alcoholic myopathy) when the congenital and familial types, which are most frequent, are discounted. However, it is also a known phenomenon in muscle aging (32), possibly suggesting that RT induces accelerated muscle aging. This disorder was, however, not described in other HL survivors with muscle weakness. Two other studies performing muscle biopsies in irradiated patients are suggestive of muscular damage (10, 11). Unfortunately, biopsy specimens were taken from the deltoid muscle, which is not completely within the radiation field (11). Furthermore, Aggarwal *et al.* conclude, after extensive investigations including muscle biopsies, that the cause of the muscle atrophy is myogenic, but their report was presented only as an abstract and did not state from which muscles the biopsy specimens were taken (10). Another case study describes

a muscle biopsy from a deltoid muscle in a patient who had been treated by whole-body RT, a highly uncommon treatment modality for HL. The muscle biopsy revealed chronic neurogenic reinnervation (13).

Clinical implications

Until now, therapy has been focused on supportive care measurements like soft neck collars or surgery (posterior spinal arthrodesis) in more severe cases (26). Based on our hypothesis that primary vascular injuries may cause myogenic damage in the muscles in the radiation field, we recommend training of the affected muscles. It is hoped that this may promote increased vascularization of the muscles by the formation of collateral vessels, which can contribute to maintaining muscle strength and integrity. Our theory is supported by the fact that the 2 patients who received mantle field irradiation but did not experience neck weakness performed sports during which the neck muscles are intensively trained. Moreover, patients visiting a physiotherapist on a regular basis report beneficial results from performing regular training exercises.

Currently, we refer our patients with neck weakness to an academic rehabilitation center where they can undergo a suitable muscle strength training program aiming at reduction of neck symptoms and gain of muscle strength. Further studies are needed in which HL survivors who received mantle field irradiation are randomized between training on a regular basis vs. no training.

REFERENCES

- Klimm B, Eich HT, Haverkamp H, *et al.* Poorer outcome of elderly patients treated with extended-field radiotherapy compared with involved-field radiotherapy after chemotherapy for Hodgkin's lymphoma: An analysis from the German Hodgkin Study Group. *Ann Oncol* 2007;18:357–363.
- Aleman BM, Raemaekers JM, Tomisic R, *et al.* Involved-field radiotherapy for patients in partial remission after chemotherapy for advanced Hodgkin's lymphoma. *Int J Radiat Oncol Biol Phys* 2007;67:19–30.
- Ferne C, Eghbali H, Meerwaldt JH, *et al.* Chemotherapy plus involved-field radiation in early-stage Hodgkin's disease. *N Engl J Med* 2007;357:1916–1927.
- Hull MC, Morris CG, Pepine CJ, *et al.* Valvular dysfunction and carotid, subclavian, and coronary artery disease in survivors of Hodgkin lymphoma treated with radiation therapy. *JAMA* 2003;290:2831–2837.
- Aleman BM, van den Belt-Dusebout AW, Klokman WJ, *et al.* Long-term cause-specific mortality of patients treated for Hodgkin's disease. *J Clin Oncol* 2003;21:3431–3439.
- Aleman BM, van den Belt-Dusebout AW, De Bruin ML, *et al.* Late cardiotoxicity after treatment for Hodgkin lymphoma. *Blood* 2007;109:1878–1886.
- De Bruin ML, Dorresteijn LD, van't Veer MB, *et al.* Increased risk of stroke and transient ischemic attack in 5-year survivors of Hodgkin lymphoma. *J Natl Cancer Inst* 2009;101:928–937.
- Hodgson DC, Gilbert ES, Dores GM, *et al.* Long-term solid cancer risk among 5-year survivors of Hodgkin's lymphoma. *J Clin Oncol* 2007;25:1489–1497.
- Hancock SL, Hoppe RT. Long-term complications of treatment and causes of mortality after Hodgkin's disease. *Semin Radiat Oncol* 1996;6:225–242.
- Aggarwal S, Amato A. Radiation induced myopathy following mantle field radiation for Hodgkin's disease: A report of 4 cases. *Neurology* 2007;68(Suppl 1). P05.107 (Abstract).
- Furby A, Behin A, Lefaucheur JP, *et al.* Late-onset cervicoscapular muscle atrophy and weakness after radiotherapy for Hodgkin disease: A case series. *J Neurol Neurosurg Psychiatry* 2010;81:101–104.
- Portlock CS, Boland P, Hays AP, *et al.* Nemaline myopathy: A possible late complication of Hodgkin's disease therapy. *Hum Pathol* 2003;34:816–818.
- Rowin J, Cheng G, Lewis SL, *et al.* Late appearance of dropped head syndrome after radiotherapy for Hodgkin's disease. *Muscle Nerve* 2006;34:666–669.
- Stone HB, Coleman CN, Anscher MS, *et al.* Effects of radiation on normal tissue: consequences and mechanisms. *Lancet Oncol* 2003;4:529–536.
- Fossa SD, Holte H, Holmen MM, *et al.* [Long-term effects after mantle field radiotherapy for Hodgkin's lymphoma]. *Tidsskr Nor Laegeforen* 2005;125:41–44.
- Johansson AS, Erlanson M, Lenner P, *et al.* [Late side-effects are common after treatment of Hodgkin's disease: Muscular atrophy following radiotherapy is a neglected risk]. *Lakartidningen* 1998;95:44–47.
- Vernon H, Mior S. The Neck Disability Index: A study of reliability and validity. *J Manipulative Physiol Ther* 1991;14:409–415.
- Vercoulen JHMM, Alberts M, Bleijenberg G. [De checklist individual strength]. *Gedrachtstherapie* 1999;32:131–136.
- Medical Research Council. Aids to examination of the peripheral nervous system. Memorandum no. 45. London: Her Majesty's Stationery Office; 1976.

20. van der Ploeg RJ, Oosterhuis HJ, Reuvekamp J. Measuring muscle strength. *J Neurol* 1984;231:200–203.
21. van der Ploeg RJ, Fidler V, Oosterhuis HJ. Hand-held myometry: Reference values. *J Neurol Neurosurg Psychiatry* 1991;54:244–247.
22. Pillen S, van Dijk JP, Weijers G, *et al*. Quantitative gray-scale analysis in skeletal muscle ultrasound: A comparison study of two ultrasound devices. *Muscle Nerve* 2009;39:781–786.
23. Arts IM, Pillen S, Schelhaas HJ, *et al*. Normal values for quantitative muscle ultrasonography in adults. *Muscle Nerve* 2010;41:32–41.
24. Pillen S, Arts IM, Zwarts MJ. Muscle ultrasound in neuromuscular disorders. *Muscle Nerve* 2008;37:679–693.
25. Bhatia S, Miller R, Lachance D. Neck extensor muscle weakness (dropped head syndrome) following radiotherapy. *Radiol Oncol* 2006;40:29–33.
26. Gerling MC, Bohlman HH. Dropped head deformity due to cervical myopathy: Surgical treatment outcomes and complications spanning twenty years. *Spine* 2008;33:E739–E745.
27. Stone HB, McBride WH, Coleman CN. Modifying normal tissue damage postirradiation: Report of a workshop sponsored by the Radiation Research Program, National Cancer Institute, Bethesda, Maryland, September 6–8, 2000. *Radiat Res* 2002;157:204–223.
28. McFarlane VJ, Clein GP, Cole J, *et al*. Cervical neuropathy following mantle radiotherapy. *Clin Oncol (R Coll Radiol)* 2002;14:468–471.
29. Gillette EL, Mahler PA, Powers BE, *et al*. Late radiation injury to muscle and peripheral nerves. *Int J Radiat Oncol Biol Phys* 1995;31:1309–1318.
30. Fajardo LF, Berthrong M. Vascular lesions following radiation. *Pathol Annu* 1988;23(Pt 1):297–330.
31. Amies C, Rose A, Metcalfe P, *et al*. Multicentre dosimetry study of mantle treatment in Australia and New Zealand. *Radiother Oncol* 1996;40:171–180.
32. Tomonaga M. Histochemical and ultrastructural changes in senile human skeletal muscle. *J Am Geriatr Soc* 1977;25:125–131.