

## PDF hosted at the Radboud Repository of the Radboud University Nijmegen

The following full text is a publisher's version.

For additional information about this publication click this link.

<http://hdl.handle.net/2066/81650>

Please be advised that this information was generated on 2021-01-17 and may be subject to change.

## EDITORIALS



## Routine Angioplasty after Fibrinolysis — How Early Should “Early” Be?

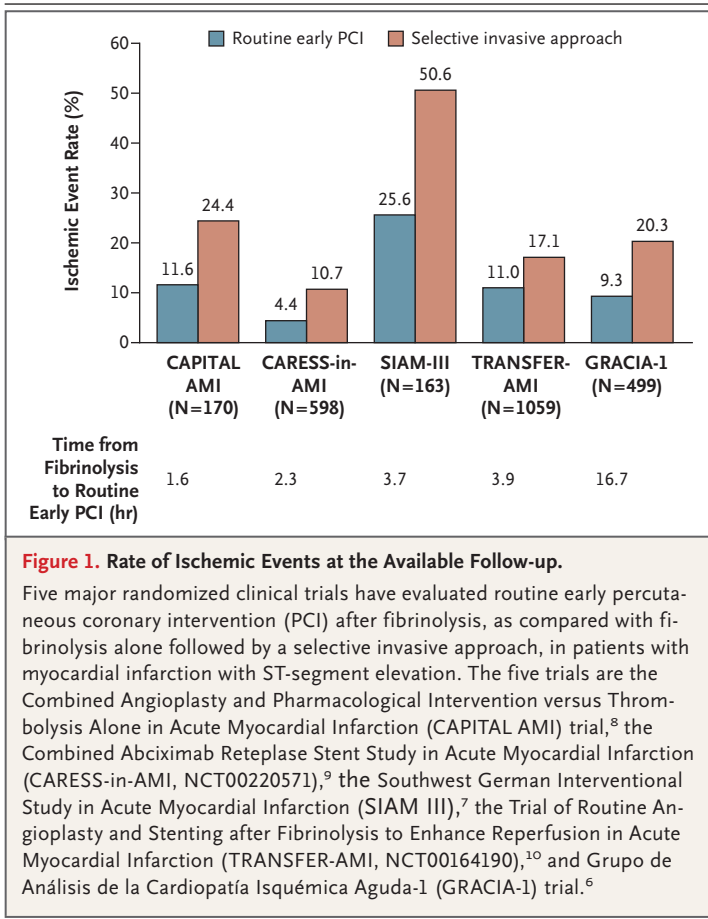
Freek W.A. Verheugt, M.D.

Reperfusion therapy has represented a great leap forward in the management of myocardial infarction with ST-segment elevation. Its goal is early and complete recanalization of the infarct-related artery to salvage myocardium and improve both early and late clinical outcomes. Complete reperfusion can be achieved with either fibrinolysis or primary percutaneous coronary intervention (PCI), but with primary PCI the success rate is higher than 90%, whereas current fibrinolytic therapy leads to full reperfusion in only 50 to 55% of recipients. Primary PCI, therefore, looks like the most appropriate reperfusion tool, but there are substantial logistic restrictions associated with it. The door-to-balloon time with primary PCI is typically longer than the time within which in-hospital fibrinolytic therapy can be initiated, and primary PCI requires a network of dedicated ambulances and emergency departments to shorten the door-to-balloon time as much as possible.<sup>1,2</sup> Primary PCI is an especially attractive strategy in the United States, where nearly 80% of the adult population lives within 1 hour's drive of a PCI center.<sup>3</sup>

Investigators have tried to combine the best of both therapies by performing PCI immediately after fibrinolysis. The concept of fibrinolysis followed immediately by PCI (termed facilitated PCI) seems attractive: early reperfusion with the use of a widely available strategy to salvage as much myocardium as possible, followed by PCI to ensure both reperfusion in the case of fibrinolytic failure and prevention of recurrent thrombosis that may result in reocclusion and reinfarction. Studies of PCI performed immediately after fibrinolysis were initiated in the late 1980s, but a meta-analysis in 2005 showed that this approach was not usually beneficial,<sup>4</sup> probably in part be-

cause of the use of outdated fibrinolytic and antiplatelet regimens and PCI equipment in those studies but also because of the increased risk of bleeding. The latter concern, especially, made many interventional cardiologists reluctant to intervene after fibrinolysis, although the results of a trial of rescue PCI after failed fibrinolysis suggest that this procedure is effective and relatively safe.<sup>5</sup> Since the major problem with the combination of fibrinolytic therapy with immediate PCI is thought to be the short interval between fibrinolysis and PCI, some later studies have investigated the outcome when a longer interval is used. Besides reducing the risk of bleeding, this approach enables the transfer of patients from centers that do not have the capability of performing PCI (where initial fibrinolysis is performed) to a PCI center. These studies showed that the approach was successful; however, the sample sizes in the studies were relatively small.<sup>6-9</sup>

In this issue of the *Journal*, Cantor et al. report the results of the Trial of Routine Angioplasty and Stenting after Fibrinolysis to Enhance Reperfusion in Acute Myocardial Infarction (TRANSFER-AMI; ClinicalTrials.gov number, NCT00164190), a large study on this topic.<sup>10</sup> More than 1000 Canadian patients with myocardial infarction with ST-segment elevation who were treated with fibrinolysis were randomly assigned to interhospital transfer for intended routine early PCI (within 6 hours after fibrinolysis) or an ischemia-guided strategy, in which patients were transferred for angiography only in the case of failed fibrinolysis or of recurrent ischemia. As in the four smaller trials, the rate of recurrent ischemia was significantly reduced with early routine PCI as compared with a selective invasive approach. Given the sample size and the study design, and with little evidence to



suggest a risk associated with the transfer itself, the trial can be considered definitive, in that it confirms earlier randomized studies with a similar relative risk reduction. Current guidelines for the management of myocardial infarction with ST-segment elevation in Europe and the United States have adopted this strategy with a moderate<sup>11</sup> to high<sup>12</sup> level of evidence, to which TRANSFER-AMI substantially contributes.

The interval from fibrinolysis to PCI and the rate of ischemic events in the five available studies are shown in Figure 1. The time to PCI was well within 24 hours after fibrinolysis in each study, and there was no difference among the trials in efficacy relative to the time to PCI. The intervals ranged from 2 to 17 hours. The former interval should be considered to be the lowest acceptable one, since PCI immediately after fibrinolysis has proved to be ineffective.<sup>4</sup> On the other hand, an interval of 17 hours seemed to be as good as PCI at 2 hours. Waiting longer than 24 hours can be disadvantageous given the increas-

ing risk of reocclusion of the infarct-related artery.<sup>13</sup> Performing PCI 72 hours or more after the event will probably offer no protection against reinfarction. In the large Occluded Artery Trial (OAT, NCT00004562),<sup>14</sup> in which patients were randomly assigned to undergo PCI of an occluded infarct-related artery or not to undergo PCI, late opening (72 hours after infarction or longer) showed no benefit with respect to reinfarction or death. It should be noted that only a quarter of the patients in the OAT were given fibrinolytic therapy for their index infarction. Thus, it seems that the optimal window for early PCI after fibrinolysis is somewhere between 2 and 24 hours. This observation was recently confirmed in a large French registry study of reperfusion therapy for myocardial infarction with ST-segment elevation.<sup>15</sup>

Fibrinolysis is still by far the most frequently performed reperfusion strategy for myocardial infarction with ST-segment elevation worldwide. Should all patients who have received fibrinolytic therapy be transferred for early PCI? Given the mechanism of early reocclusion and reinfarction and the consistent benefit observed in the randomized trials of an early invasive approach, the answer should be yes. Transfer must not be on an emergency basis, except in the case of patients in whom fibrinolysis has failed, and can probably wait until the day after fibrinolytic therapy is given. Such a strategy improves the results of fibrinolysis while at the same time allowing a transition of care that causes less stress both to the patient and to ambulance crews.

Timely primary PCI remains the optimal therapy for myocardial infarction with ST-segment elevation; however, owing to the logistic and temporal restraints of primary PCI, fibrinolysis is still the only possible initial reperfusion strategy in large parts of the world, including large parts of the Western world. Fibrinolysis, however, should be followed by an early invasive approach; in this setting, PCI has a central role.

Dr. Verheugt reports receiving consulting fees from Bayer, Lilly/Daiichi Sankyo, Boehringer Ingelheim, and Bristol-Myers Squibb/Pfizer and speaking fees from AstraZeneca, Boehringer Ingelheim, and Sanofi-Aventis. No other potential conflict of interest relevant to this article was reported.

From the Department of Cardiology, Onze Lieve Vrouwe Gasthuis, Amsterdam.

1. Kalla K, Christ G, Karnik R, et al. Implementation of guidelines improves standard of care: the Viennese registry on reperfusion strategies in ST-elevation myocardial infarction (Vienna STEMI Registry). *Circulation* 2006;113:2398-405.

2. Ting HH, Rihal CS, Gersh BJ, et al. Regional systems of care to optimize timeliness of reperfusion therapy for ST-elevation myocardial infarction: the Mayo Clinic STEMI Protocol. *Circulation* 2007;116:729-36.
3. Nallamothu BK, Bates ER, Wang Y, Bradley EH, Krumholz HM. Driving times and distances to hospitals with percutaneous coronary intervention in the United States: implications for pre-hospital triage of patients with ST-elevation myocardial infarction. *Circulation* 2006;113:1189-95.
4. Keeley EC, Boura JA, Grines CL. Comparison of primary and facilitated percutaneous coronary interventions for ST-elevation myocardial infarction: quantitative review of randomised trials. *Lancet* 2006;367:579-88. [Erratum, *Lancet* 2006;367:1656.]
5. Gershlick AH, Stephens-Lloyd A, Hughes S, et al. Rescue angioplasty after failed thrombolytic therapy for acute myocardial infarction. *N Engl J Med* 2005;353:2758-68.
6. Fernandez-Avilés F, Alonso JJ, Castro-Beiras A, et al. Routine invasive strategy within 24 hours of thrombolysis versus an ischaemia-guided conservative approach for acute myocardial infarction with ST-segment elevation (GRACIA-1): a randomized controlled trial. *Lancet* 2004;364:1045-53.
7. Scheller B, Hennen B, Hammer B, et al. Beneficial effects of immediate stenting after thrombolysis in acute myocardial infarction. *J Am Coll Cardiol* 2003;42:634-41.
8. Le May MR, Wells GA, Labinaz M, et al. Combined Angioplasty and Pharmacological Intervention Versus Thrombolysis Alone in Acute Myocardial Infarction (CAPITAL AMI study). *J Am Coll Cardiol* 2005;46:417-24.
9. Di Mario C, Dudek D, Piscione F, et al. Immediate angioplasty versus standard therapy with rescue angioplasty after thrombolysis in the Combined Abciximab REtEplase Stent Study in Acute Myocardial Infarction (CARESS-in-AMI): an open, prospective, randomised, multicentre trial. *Lancet* 2008;371:559-68.
10. Cantor WJ, Fitchett D, Borgundvaag B, et al. Routine early angioplasty after fibrinolysis for acute myocardial infarction. *N Engl J Med* 2009;360:2705-18.
11. Antman EM, Hand M, Armstrong PW, et al. 2007 Focused update of the ACC/AHA 2004 guidelines for the management of patients with ST-elevation myocardial infarction: a report of the American College of Cardiology/American Heart Association Task Force on Practice Guidelines: developed in collaboration with the Canadian Cardiovascular Society endorsed by the American Academy of Family Physicians: 2007 Writing Group to Review New Evidence and Update the ACC/AHA 2004 Guidelines for the Management of Patients with ST-Elevation Myocardial Infarction, writing on behalf of the 2004 Writing Committee. *Circulation* 2008;117:296-329. [Erratum, *Circulation* 2008;117(6):e162.]
12. Van de Werf F, Bax J, Betriu A, et al. Management of acute myocardial infarction in patients presenting with ST-segment elevation: the Task Force on the Management of ST-Segment Elevation Acute Myocardial Infarction of the European Society of Cardiology. *Eur Heart J* 2008;29:2909-45.
13. Verheugt FWA, Meijer A, Lagrand WK, Van Eenige MJ. Reocclusion: the flip side of coronary thrombolysis. *J Am Coll Cardiol* 1996;27:766-73.
14. Hochman JS, Lamas GA, Buller CE, et al. Coronary intervention for persistent occlusion after myocardial infarction. *N Engl J Med* 2006;355:2395-407.
15. Danchin N, Coste P, Ferrières J, et al. Comparison of thrombolysis followed by broad use of percutaneous coronary intervention with primary percutaneous coronary intervention for ST-segment-elevation acute myocardial infarction: data from the French Registry on acute ST-elevation myocardial infarction (FAST-MI). *Circulation* 2008;118:268-76.

Copyright © 2009 Massachusetts Medical Society.

## Cancer Genomes on a Shoestring Budget

Jay Shendure, M.D., Ph.D., and Colin J. Stewart, M.B., Ch.B.

In a remarkably short time, the use of massively parallel technologies has greatly reduced the cost of DNA sequencing.<sup>1</sup> Already, these technologies have permitted the whole-genome sequencing of several persons<sup>2-4</sup> and one tumor<sup>5</sup> for a small fraction of the cost of the sequencing of the first human genome. However, the cost of whole-genome sequencing is still many tens of thousands of dollars — too expensive for routine application to even modest numbers of samples in either a research or a clinical setting.

In this issue of the *Journal*, Shah et al.<sup>6</sup> describe the identification of a likely “driver” mutation of the *FOXL2* gene in adult-type granulosa-cell tumors (GCTs), relatively uncommon neoplasms that account for 3 to 5% of all ovarian cancers.<sup>7</sup> The discovery was made by sequencing the transcriptome of tumor specimens, rather than by sequencing genomic DNA (gDNA). The transcriptome is defined as the full set of messenger RNA (mRNA) present in a population of cells. The usu-

al goal of characterizing a transcriptome is to quantify the relative abundance with which individual genes are expressed in a given tissue (e.g., with microarrays). In contrast, the objective of this study was to mine transcribed sequences to indirectly identify nonsynonymous mutations in the tumor genome — that is, those altering protein-coding sequences.

To put this in context, more than 98% of the human genome comprises sequences with regulatory or unknown function, interspersed with nearly 200,000 exons that collectively encode mRNA (the “exome” contributing 1 to 2% of the genome in aggregate); mRNA, in turn, encodes proteins. The vast majority of somatic mutations that have been identified to date and that clearly drive the development of cancer in humans are either large-scale structural changes (e.g., rearrangements and copy-number changes) or small mutations that alter protein-coding sequences. Whole-genome sequencing of a tumor (and