

## PDF hosted at the Radboud Repository of the Radboud University Nijmegen

The following full text is a publisher's version.

For additional information about this publication click this link.

<http://hdl.handle.net/2066/57281>

Please be advised that this information was generated on 2021-03-01 and may be subject to change.

## Medical Mystery — The Answer

**TO THE EDITOR:** The medical mystery in the July 1 issue<sup>1</sup> involved 50-year-old identical twins (Fig. 1A). The patient is the twin on the left side of the photograph. He has acromegaly caused by a growth hormone–hypersecreting pituitary macroadenoma. He presented with visual-field impairment, and magnetic resonance imaging showed a pituitary macroadenoma with extrasellar extension (Fig. 1B shows a coronal section, and Fig. 1C a sagittal section). A few months earlier, obstructive sleep apnea had been diagnosed. The history also included headache, enlargement of the feet, increased sweating, and joint stiffness. The patient’s serum insulin-like growth factor level was elevated, at 56.5 nmol per liter (mean for age, 17.0 nmol per liter), and an oral glucose-tolerance test showed a failure to suppress growth hormone (5 mU per liter; normal value, <2 mU per liter).

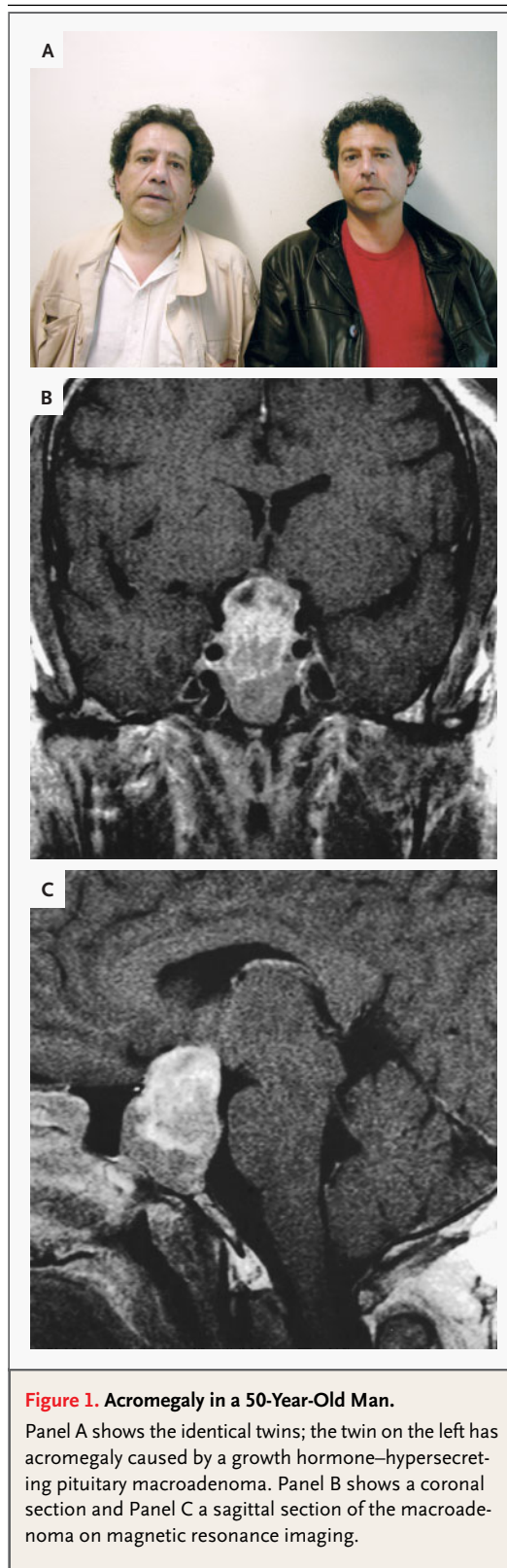
The patient’s coarse facial features were evident in comparison with the facial features of his identical twin. The acral enlargement (nose and lips) and enlargement of the facial soft tissue (skin folds and infraorbital puffiness) are striking. Few patients with acromegaly seek care owing to the very slow progression. The patient underwent transsphenoidal surgery, with visual-field improvement. Complete relief from symptoms was not attained, and treatment with a somatostatin analogue was started, which reduced the patient’s headache, fatigue, and sweating.

Willy-Anne Nieuwlaat, M.D.  
Gerlach Pieters, M.D., Ph.D.

University Medical Center Sint Radboud  
6500 HB Nijmegen, the Netherlands

1. Nieuwlaat W-A, Pieters G. A medical mystery — which twin is the patient? *N Engl J Med* 2004;351:68.

*Editor’s note:* We received 2655 responses to this medical mystery: 57 percent from physicians in practice, 19 percent from physicians in training, 12 percent from medical students, and 12 percent from other readers. Responses were received from 86 countries. Sixty-four percent of respondents correctly diagnosed acromegaly in the twin in the white shirt; 23 percent suggested other endocrinopathies such as hypothyroidism, Hashimoto’s thyroiditis, and Cushing’s syndrome. Other, less common diagnoses included Paget’s disease, the superior vena cava syndrome, lung cancer, chronic obstructive



pulmonary disease, chronic renal failure, nephrosis, amyloidosis, Dilantin (phenytoin) toxicity, leprosy, scleroderma, myotonic dystrophy, Parkinson's

disease, and hemochromatosis. Two percent of respondents suggested that the twin in the red shirt had Bell's palsy — he did not.

## A Girl with a Birth Weight of 280 g, Now 14 Years Old

**TO THE EDITOR:** One of us and several colleagues previously reported in the *Journal* the survival, at 18 months of age, of a girl with extreme symmetrical intrauterine growth restriction; she had a birth weight of 280 g and a length of 25 cm at a gestational age of 26 weeks and 6 days.<sup>1</sup> To our knowledge, her birth weight remains the lowest in the world literature. We now report her growth and development at 14 years of age, as she enters high school (Fig. 1).

At two years of age, our patient had a Mental Development Index score of 86 (normal range, 84 to 116) on the Bayley Scales of Infant Development and was walking independently. Toilet training took place at three years of age. At five years of age, her visual acuity was 20/200 (in the right eye) and 20/100 (in the left) and was corrected with eyeglasses. Her only hospitalization was at four years of age, for pneumonia. She continues to have reactive airway disease. She started kindergarten at six years of age. A workup for failure to thrive and short stature at three and nine years of age, respectively, revealed no abnormalities. Menarche occurred at 13 years of age. She attends a regular school and has a cumulative grade-point average of 3.70 (of a possible 4.00) for the previous eight years. Since her birth, she has gained an average of 1.8 kg in weight and 9.7 cm in height annually. The 50th percentile for weight and height for girls at the age of 14 years are 50 kg and 163 cm, respectively. Despite her present weight of 25.4 kg and height of 136.5 cm, no psychosocial maladaptations have been reported. The results of her high-school entrance examinations were in the 83rd percentile nationally.

Neonatal survival improves dramatically from 5 percent at a gestational age of 23 weeks to 90 percent at a gestational age of 27 weeks. Despite the routine use of antenatal and postnatal corticosteroids, surfactants, and aggressive ventilation, prospective studies have demonstrated that newborns delivered before 24 weeks of gestation have been completed are less likely to survive and to survive without deficits than are those delivered after a longer gestation. Girls generally have a better prognosis than boys.<sup>2</sup> The normal cognitive develop-

ment of our patient is more remarkable than her survival. A significant number of newborns with an extremely low birth weight (<1000 g) and intrauterine growth restriction who have been followed to school age have suboptimal neurodevelopmental outcomes and cognitive function.<sup>3,4</sup> Fifty-two newborns with a birth weight of less than 400 g have been described in the literature. Their average gestational age was 25 weeks and 6 days, and 83 percent were girls. All had symmetrical intrauterine growth restriction.<sup>5</sup> These extremely low-birth-



**Figure 1.** The Patient at 14 Years of Age.