

## PDF hosted at the Radboud Repository of the Radboud University Nijmegen

The following full text is a publisher's version.

For additional information about this publication click this link.

<http://hdl.handle.net/2066/52742>

Please be advised that this information was generated on 2020-10-29 and may be subject to change.

# The trochlea is medialized by total knee arthroplasty

## An intraoperative assessment in 61 patients

Huib J Meijerink<sup>1</sup>, Marco Barink<sup>1</sup>, Corné J M van Loon<sup>2</sup>, Paul J A Schwering<sup>3</sup>,  
Roland D Donk<sup>3</sup>, Nico Verdonschot<sup>1</sup> and Maarten C de Waal Malefijt<sup>1</sup>

Departments of Orthopaedics, <sup>1</sup>Radboud University Nijmegen Medical Centre, Nijmegen, <sup>2</sup>Rijnstate Hospital, Arnhem, <sup>3</sup>Canisius-Wilhelmina Hospital, Nijmegen, the Netherlands.

Correspondence MdWM: M.deWaalMalefijt@orthop.umcn.nl

Submitted 06-04-21. Accepted 06-09-05

**Background** A medialization of the femoral component in a total knee arthroplasty (TKA) causes abnormal patellar tracking, which could result in patellar instability, pain, wear, and failure. Previous reports defined medialization in relation to the neutral position of the femoral component, but omitted to compare it to the anatomical position of the trochlea. We assessed intraoperatively whether there is a systematic error of the position of the prosthetic groove relative to the anatomical trochlea.

**Material and methods** A special instrument was developed to measure consecutively the mediolateral position of the anatomical trochlea and the mediolateral position of the prosthetic groove. 3 experienced knee surgeons determined the mediolateral error of the prosthetic groove in primary TKAs in 61 patients.

**Results** There was a significant medial error of the prosthetic groove relative to the preoperative position of the trochlea, with a mean medial error of 2.5 mm (SD 3.3)

**Interpretation** Our findings indicate that the trochlea is medialized by TKA. Because a conscious medialization of the femoral component in a TKA produces abnormal patellar tracking patterns, further investigations will be needed to analyze the clinical consequences of this medialization of the trochlea.

(Boyd et al. 1993, Healy et al. 1995, Harwin 1998), and is an important reason for revision surgery. Most patellofemoral complications are associated with abnormal patellar tracking (Harwin 1998). Thus, patella tracking is an important issue in TKA, which is, among other parameters, influenced by the mediolateral and rotational position of the femoral component. Several studies have shown that small modifications in alignment of the femoral component cause significant changes in patella tracking (Grace and Rand 1988, Rhoads et al. 1990, Anouchi et al. 1993, Miller et al. 2001).

In a recent cadaver experiment involving TKAs without resurfacing of the patella, we observed that the patella in a TKA is displaced to the medial side in a flexed knee, when compared to the preoperative position (Barink et al. 2006). A medialization of the patella results in a higher Q-angle, as the direction of the patella tendon differs more from the vector of the Quadriceps. Because the loads are maximal in a flexed knee (Petersilge et al. 1994), one could expect an increase in compressive and shear forces on the patellar joint (Low et al. 2000). Armstrong et al. (2003) described that the position of the patella changes with any malposition of the femoral component, which could result in patellar instability, pain, wear, and failure. Furthermore, Rhoads et al. (1990, 1993) concluded that medial femoral displacement produces abnormal patellar tracking patterns with higher stresses on the patella. Although these authors also described problems with medialization of the femoral com-

After implantation of a total knee arthroplasty (TKA), patellofemoral complaints is one of the complications with the highest incidence (1–24%)

ponent and the patella, they defined medialization in relation to the standard or neutral position of the femoral component of a TKA, but omitted to compare it to the preoperative, anatomical position of the trochlea.

We therefore assessed whether there is a systematic error of the position of the prosthetic groove relative to the anatomical trochlea. We designed a prospective study with the participation of three surgeons, and analyzed intraoperatively the mediolateral placement of the trochlea of a TKA.

### Material and methods

We developed a special instrument to measure intraoperatively the mediolateral position of the trochlea (Figure 1). After preparing the knee for a primary TKA, just before any bone resection took place, this instrument was placed on the distal femur. 3 hollow cylinders with a diameter of 2.7 mm were positioned in the epicondyles as reference points and the 3 fixing pins of the instrument were slid into those cylinders. Perpendicular to the mediolateral scale was a sliding part of the instrument with a plastic disc as probe. This probe simulated the articular surface of the patella, and had 2 different diameters (33 and 55 mm) to choose the best fitting in the trochlea. Our measurements were performed at the most distal point of the trochlea, because this was a recognizable and reproducible point. When the disc was resting in this most distal point of the trochlea, the preoperative, anatomical mediolateral position of the trochlea was determined. After preparing the distal femur and placing the trial component of a TKA, the 3 pins of the instrument were slid into the 3 hollow cylinders in the epicondyles again and the mediolateral position of the most distal point of the prosthetic groove was determined. The difference between both positions was defined as the mediolateral error of the prosthetic groove relative to the anatomical position of the trochlea, with positive values for medial displacements and negative values for lateral displacements. The most distal point of the trochlea lies approximately at the axis of the femur. Thus, the amount of rotation of the femoral component does not influence the mediolateral position of this point of the trochlea. All measurements were per-




Figure 1. Instrument installed on a sawbone of a distal femur to measure the mediolateral position of the most distal point of the notch. A: hollow cylinder in the epicondyle; B: fixing pin of the instrument; C: probe resting in the most distal point of the notch; D: mediolateral scale.

formed by the surgeons and were rounded to whole millimeters. The inter- and intraobserver variability of our measuring instrument was tested by 5 observers with 5 measurements each, and the standard deviations were 0.7 mm and 0.4 mm, respectively.

3 surgeons measured the mediolateral error of the prosthetic groove in a primary TKA in 61 patients. All patients were operated for symptomatic osteoarthritis or rheumatoid arthritis. There were no exclusion criteria. All surgeons were experienced knee surgeons with more than 4 years of experience with the implant. None of the patellae were resurfaced. Surgeon A routinely placed an LCS rotating platform prosthesis (DePuy, Warsaw, IN) and determined the mediolateral error in 21 patients. Surgeons B and C placed a PFC prosthesis (DePuy, Warsaw, IN) and both measured the mediolateral error in 20 patients each. All three surgeons used their own criteria for the mediolateral positioning of the femoral component; surgeons A and B both strived for optimal coverage of both condyles, and surgeon C preferred a flush position of the femoral component relative to the lateral epicondyle. The LCS prosthesis, as used by surgeon A, has a resection guide that is placed on the distal femur after the distal resection is performed. The position of this resection guide is fixed, and after the other resections are made the trial component has exactly the same mediolateral position. Thus, the mediolateral position of the femoral component of the LCS prosthesis (surgeon A) has been based

The mediolateral error of the prosthetic groove relative to the preoperative position of the trochlea. The mean, range, standard deviation (SD), 95% confidence interval (CI) and the significance of the error of each group are shown

Group	Mean (mm)	Range (mm)	SD (mm)	95% CI (mm)	P-value
All patients	2.5	-4 to 9	3.3	1.7–3.3	< 0.001
Surgeon A	1.5	-3 to 7	2.5	0.3–2.6	0.01
Surgeon B	4.4	0 to 9	2.7	3.1–5.6	< 0.001
Surgeon C	1.7	-4 to 8	3.7	-0.1–3.5	0.06
LCS Prosthesis (surgeon A)	1.5	-3 to 7	2.5	0.3–2.6	0.01
PFC Prosthesis (surgeons B + C)	3.0	-4 to 9	3.5	1.9–4.1	< 0.001

on the distal resection plane. In contrast to the LCS system, with the system of the PFC prosthesis, the trial component can be moved more medially or laterally after all resections are performed. Thus, surgeons B and C could overview the whole distal femur, including the anterior and posterior part, during the positioning of the femoral component.

In addition to the question of whether there is a systematic error of the position of the prosthetic groove relative to the anatomical trochlea, we compared the mediolateral positioning of the trochlea of 2 different prosthetic designs and 3 different surgeons, each with their own criteria for mediolateral positioning of the femoral component. Moreover, we analyzed the influence of difference in size of the prosthesis on mediolateral positioning of the prosthetic groove.

### Statistics

Statistical analysis to assess whether there was a systematic error in the position of the prosthetic groove relative to the anatomical trochlea was performed with the one-sample t-test for all patients together, and for each surgeon and prosthetic design separately. For the assessment of the difference in mediolateral error between the 3 surgeons, we used one-way ANOVA with Bonferroni correction for pairwise testing. For the difference in mediolateral error between the 2 prosthetic designs, a t-test for 2 independent samples was used. The influence of prosthetic size on the mediolateral error was analyzed with linear regression. P-values less than 0.05 were defined as being statistically significant.

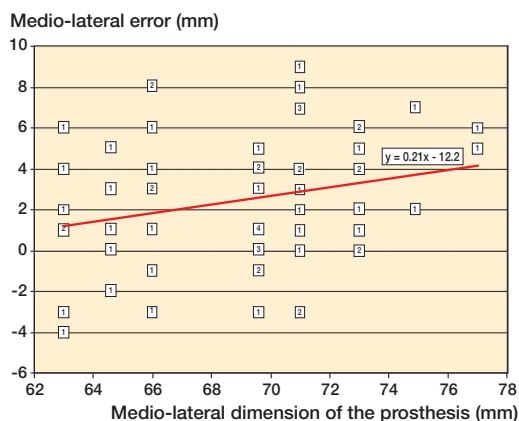


Figure 2. The mediolateral error of the prosthetic groove as a function of the mediolateral dimension of the prosthesis. The numbers in the squares represent the number of measurements at that position.

### Results

There was a medial error ( $p < 0.001$ ) of the prosthetic groove relative to the preoperative position of the trochlea in all 61 patients together, with a mean medial error of 2.5 mm (SD 3.3, 95% CI: 1.7–3.3 mm) (Table). Surgeon B placed the prosthetic groove significantly more medially than surgeon A ( $p = 0.01$ ) and surgeon C ( $p = 0.02$ ). The difference in mediolateral error between the 2 prosthetic designs was not significant ( $p = 0.08$ ). The correlation between size of the femoral component and mediolateral error was not significant ( $R = 0.24$ ,  $p = 0.06$ ) (Figure 2).

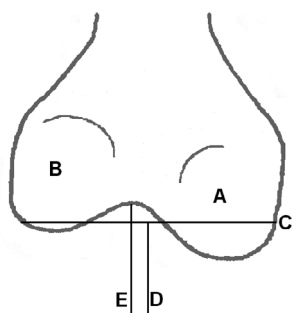


Figure 3. Schematic illustration of the asymmetric distal femoral resection, with a medial displacement of the middle of the distal resection, relative to the anatomical position of the trochlea. A: medial condyle; B: lateral condyle; C: distal resection; D: middle of the distal resection; E: anatomical position of the trochlea.

## Discussion

Our findings indicate that there is a systematic medial error in the position of the prosthetic groove. This is in agreement with our cadaver experiment involving TKAs without resurfacing of the patella, where we observed that the patella in a TKA was displaced to the medial side in a flexed knee, as compared to the preoperative position (Barink et al. 2006). A plausible cause for this medial error might be the difference in distal position of the femoral condyles. Morphological studies of the distal femur have shown that in most femurs the medial condyle is positioned more distally (Yoshioka et al. 1987, Nuño and Ahmed 2003). This means that the resection area of the medial condyle is greater than that of the lateral condyle, when the resection is performed in a plane perpendicular to the mechanical axis of the leg. Thus, when a femoral component is placed exactly in the middle of the distal resection, the middle of the prosthesis will be shifted to the wider resection area of the medial condyle and will therefore cause a medial displacement of the trochlea (Figure 3). Moreover, Eckhoff et al. (1996 a, b) showed that the sulcus of the trochlea is lateral to the mid-plane between the condyles. This could be another aspect of the asymmetrical distal resection area to explain a medial error of the trochlea in TKA in the case of femoral components with equal widths of the medial and lateral condyles. It therefore seems more appropriate to develop femoral components with a wider medial condyle than the lateral condyle, to achieve an anatomical position

of the prosthetic groove and good coverage of both condyles as well. To our knowledge, there is only one prosthetic design with a wider medial condyle on the market (3DKnee, Encore Medical, Austin, TX).

In addition, we had expected a greater medial error with greater sizes of the femoral components, because greater sizes should give more discrepancy in the widths of the condylar resection area. Moreover, Eckhoff et al. (1996b) speculated that the sulcus of the anatomical distal femur is more lateral in a wider femur. We found a tendency ( $p = 0.06$ ) for a larger size of femoral prosthesis to have a greater medial error.

Another remarkable result was that surgeon B placed the prosthetic groove significantly more medial than surgeons A and C. Although surgeon A used another prosthetic design than surgeons B and C, we did not find any significant difference in mediolateral error between these prosthetic designs. This indicates that surgical judgement may govern mediolateral positioning, rather than the prosthetic system. Surgeon C preferred a flush position of the femoral component relative to the lateral epicondyle, and was consequently less influenced by the asymmetrical distal resection area of the condyles. Surgeon C was the only surgeon for whom the medial error was not significant. Surgeons A and B both strived for optimal coverage of both condyles. Surgeon A had to base the positioning of the femoral component only on the distal resection plane, with the resection guide placed on the distal femur. After all bone resections were performed, surgeon B could view the whole distal femur during the mediolateral positioning. The exact anatomy seems less obvious after all bone resections, and it appears that with a complete overview of the whole distal femur, surgeon B was more affected by the asymmetrical distal resection area, which causes a shift of the prosthetic groove to the wider medial condyle.

One important issue is the clinical consequence of a displacement of the prosthetic groove in the medial direction. Rhoads et al. (1990, 1993) concluded that medial femoral displacement produces abnormal patellar tracking patterns with higher stresses on the patella. Armstrong et al. (2003) described that the position of the patella changes with any malposition of the femoral component. In

this study, we determined the mediolateral position of the most distal point of the trochlea, which is assumed to prescribe the position of the patella in flexion of the knee joint. Although we had already observed in a cadaver experiment (involving TKAs without resurfacing of the patella) that the patella in a TKA is displaced to the medial side in a flexed knee (Barink et al. 2006), we did not analyze the position of the patella in the current study. Furthermore, when there is resurfacing of the patella, a conscious medialization of the patellar component could compensate for a medially displaced prosthetic groove, and medialization of the patellar component has been suggested as a means of improving patellar tracking (Brick and Scott 1988, Yoshii et al. 1992). Although some good initial results of patellar component medialization in TKA have been described (Hofmann et al. 1997, Lewonowski et al. 1997), it seems better to strive for an anatomical positioning of the TKA than to compensate for a medial error of the femoral component by placing a medially displaced patella prosthesis. The conclusion of our study is that the trochlea is medialized by TKA. Because a conscious medialization of the femoral component in a TKA produces abnormal patellar tracking patterns—which could result in patellar instability, pain, wear, and failure—further investigations will be needed to analyze the clinical consequences of this medialization of the trochlea.

#### Contributions of authors

HJM: designed the study, analyzed the data and wrote and revised the manuscript. CJL: designed the study, performed measurements and reviewed the manuscript. PJS and RDD: performed measurements. NV and MWM: designed the study and reviewed the manuscript.

No competing interests declared.

- Anouchi Y S, Whiteside L A, Kaiser A D, Milliano M T. The effects of axial rotational alignment of the femoral component on knee stability and patellar tracking in total knee arthroplasty demonstrated on autopsy specimens. *Clin Orthop* 1993; (287): 170-7.
- Armstrong A D, Brien H J, Dunning C E, King G J, Johnson J A, Chess D G. Patellar position after total knee arthroplasty: influence of femoral component malposition. *J Arthroplasty* 2003; 18 (4): 458-65.

- Barink M, Meijerink H J, van Kampen A, Verdonchot N, de Waal Malefijt M C. Asymmetrical total knee arthroplasty does not improve patella tracking. A study without patella resurfacing. Accepted for publication in *Knee Surg Sports Traumatol Arthrosc*.
- Boyd A D Jr, Ewald F C, Thomas W H, Poss R, Sledge C B. Long-term complications after total knee arthroplasty with or without resurfacing of the patella. *J Bone Joint Surg (Am)* 1993; 75 (5): 674-81.
- Brick G W, Scott R D. The patellofemoral component of a total knee arthroplasty. *Clin Orthop* 1988; (231): 163-78.
- Eckhoff D G, Burke B J, Dwyer T F, Pring M E, Spitzer V M, VanGerwen D P. Sulcus morphology of the distal femur. *Clin Orthop* 1996a; (331): 23-8.
- Eckhoff D G, Montgomery W K, Stamm E R, Kilcoyne R F. Location of the femoral sulcus in the osteoarthritic knee. *J Arthroplasty* 1996b; 11 (2): 163-5.
- Grace J N, Rand J A. Patellar instability after total knee arthroplasty. *Clin Orthop* 1988; (237): 184-9.
- Harwin S F. Patellofemoral complications in symmetrical total knee arthroplasty. *J Arthroplasty* 1998; 13 (7): 753-62.
- Healy W L, Wasilewski S A, Takei R, Oberlander M. Patellofemoral complications following total knee arthroplasty. Correlation with implant design and patient risk factors. *J Arthroplasty* 1995; 10 (2): 197-201.
- Hofmann A A, Tkach T K, Evanich C J, Camargo M P, Zhang Y. Patellar component medialization in total knee arthroplasty. *J Arthroplasty* 1997; 12 (2): 155-60.
- Lewonowski K, Dorr L D, McPherson E J, Huber G, Wan Z. Medialization of the patella in total knee arthroplasty. *J Arthroplasty* 1997; 12 (2): 161-7.
- Low F H, Khoo L P, Chua C K, Lo N N. Determination of the major dimension of femoral implants using morphometrical data and principal component analysis. *Proc Inst Mech Eng (H)* 2000; 214 (3): 301-9.
- Miller M C, Zhang A X, Petrella A J, Berger R A, Rubash H E. The effect of component placement on knee kinetics after arthroplasty with an unconstrained prosthesis. *J Orthop Res* 2001; 19 (4): 614-20.
- Nuño N, Ahmed A M. Three-dimensional morphometry of the femoral condyles. *Clin Biomech* 2003; 18 (10): 924-32.
- Petersilge W J, Oishi C S, Kaufman K R, Irby S E, Colwell C W Jr. The effect of trochlear design on patellofemoral shear and compressive forces in total knee arthroplasty. *Clin Orthop* 1994; (309): 124-30.
- Rhoads D D, Noble P C, Reuben J D, Mahoney O M, Tullos H S. The effect of femoral component position on patellar tracking after total knee arthroplasty. *Clin Orthop* 1990; (260): 43-51.
- Rhoads D D, Noble P C, Reuben J D, Tullos H S. The effect of femoral component position on the kinematics of total knee arthroplasty. *Clin Orthop* 1993; (286): 122-9.
- Yoshii I, Whiteside L A, Anouchi Y S. The effect of patellar button placement and femoral component design on patellar tracking in total knee arthroplasty. *Clin Orthop* 1992; (275): 211-9.
- Yoshioka Y, Siu D, Cooke T D. The anatomy and functional axes of the femur. *J Bone Joint Surg (Am)* 1987; 69 (6): 873-80.