

## PDF hosted at the Radboud Repository of the Radboud University Nijmegen

The following full text is a publisher's version.

For additional information about this publication click this link.

<http://hdl.handle.net/2066/52340>

Please be advised that this information was generated on 2021-04-10 and may be subject to change.

## Description of the attachment geometry of the anteromedial and posterolateral bundles of the ACL from arthroscopic perspective for anatomical tunnel placement

Joan W. H. Luites · Ate B. Wymenga ·  
Leendert Blankevoort · Jan G. M. Kooloos

Received: 28 September 2006 / Accepted: 14 August 2007 / Published online: 27 September 2007  
© Springer-Verlag 2007

**Abstract** The anterior cruciate ligament (ACL) consists of an anteromedial bundle (AMB) and a posterolateral bundle (PLB). A reconstruction restoring the functional two-bundled nature should be able to approximate normal ACL function better than the most commonly used single-bundle reconstructions. Accurate tunnel positioning is important, but difficult. The purpose of this study was to provide a geometric description of the centre of the attachments relative to arthroscopically visible landmarks. The AMB and PLB attachment sites in 35 dissected cadaver knees were measured with a 3D system, as were anatomical landmarks of femur and tibia. At the femur, the mean ACL centre is positioned  $7.9 \pm 1.4$  mm (mean  $\pm$  1 SD) shallow, along the notch roof, from the most lateral over-the-top position at the posterior edge of the intercondylar notch and from that point  $4.0 \pm 1.3$  mm from the notch roof, low on the surface of the lateral condyle wall.

The mean AMB centre is at  $7.2 \pm 1.8$  and  $1.4 \pm 1.7$  mm, and the mean PLB centre at  $8.8 \pm 1.6$  and  $6.7 \pm 2.0$  mm. At the tibia, the mean ACL centre is positioned  $5.1 \pm 1.7$  mm lateral of the medial tibial spine and from that point  $9.8 \pm 2.1$  mm anterior. The mean AMB centre is at  $3.0 \pm 1.6$  and  $9.4 \pm 2.2$  mm, and the mean PLB centre at  $7.2 \pm 1.8$  and  $10.1 \pm 2.1$  mm. The ACL attachment geometry is well defined relative to arthroscopically visible landmarks with respect to the AMB and PLB. With simple guidelines for the surgeon, the attachments centres can be found during arthroscopic single-bundle or double-bundle reconstructions.

**Keywords** Anterior cruciate ligament · Anteromedial bundle · Posterolateral bundle · Anatomic ACL reconstruction · Double-bundle ACL reconstruction · Arthroscopic view · Tunnel placement · ACL anatomy

J. W. H. Luites (✉)

Research, Development & Education,  
OrthoResearch Unit, Sint Maartenskliniek,  
P.O.Box 9011, 6500 GM Nijmegen, The Netherlands  
e-mail: j.luites@maartenskliniek.nl

A. B. Wymenga

Department of Orthopaedics,  
Knee Reconstruction Unit, Sint Maartenskliniek,  
P.O.Box 9011, 6500 GM Nijmegen, The Netherlands

L. Blankevoort

Department of Orthopaedic Surgery,  
Orthotrauma Research Centre Amsterdam,  
Academic Medical Centre, University of Amsterdam,  
P.O.Box 22660, 1100 DD Amsterdam, The Netherlands

J. G. M. Kooloos

Department of Anatomy, Radboud University,  
P.O.Box 9101, 6500 HB Nijmegen, The Netherlands

### Introduction

The anterior cruciate ligament (ACL) consists of two functional bundles [2, 4, 16]. The anteromedial bundle (AMB) originates anteroproximal in the intercondylar notch, close to the over-the-top position at the posterior edge of the notch, from the deep high part of the femoral attachment area and inserts anteromedial on the anterior intercondylar area of the tibia. The posterolateral bundle (PLB) originates more posteriorly and distally in the notch, from the shallow low part of the femoral attachment area and inserts posterolateral on the anterior intercondylar area of the tibia. The ACL reconstruction aims at restoring normal knee function. Most ACL replacements are performed with the isometric single-bundle technique.

Isometric positioning of a single-bundle graft results in replacement of the AMB only. Although tensioned over the complete range of motion, the fibres are mostly tight in flexion. The AMB is the major constraint for anterior tibial displacement of the flexed knee [30], but cannot restore normal knee laxity and kinematics near extension [4, 28, 41]. In an effort to improve knee mechanics, double-bundle anatomic ACL reconstructions are now developed with reconstruction of both AMB and PLB [9, 10, 13, 19, 28, 35, 40, 46, 49, 50, 52, 53]. As presented in previous studies, a reconstructed PLB is able to restore stability in knee angles where an isometrically placed graft fails [28, 41, 50]. Additional restraint against anterior displacement in 15° of flexion [48] as well as prevention of the pivot shift is demonstrated [28, 50]. Therefore, a reconstruction with two bundles should be able to approximate normal ACL function over the complete range of motion [39, 41, 51].

Tunnel positioning is an important factor for clinical success of ACL reconstructions. Incorrect tibial [23] and femoral [29, 55] tunnel placements result in abnormal knee mechanics. Anatomical placement restores normal knee function better than isometric placement [36, 55]. However, accurate tunnel placement seems difficult. Misplacement between 25 and 65% of the tibial and femoral tunnels is reported [8, 27, 47]. Double-bundle ACL reconstructions require an anatomical placement of the bone tunnels. It is difficult to identify the ACL remnants in chronic ACL-injured knees. Therefore, detailed information about the approximate native position is essential to determine proper anatomic tunnel placement for the two bundles during arthroscopy [17]. The anatomical position has been the subject of many studies [3, 5, 12, 14–16, 20, 26, 33, 34, 37, 38, 44]. Only a few recent studies have described the anatomic positions of the AM and PL bundles [11, 32, 45, 52]. Due to the two-dimensional and limited view on the arthroscopic monitor, the landmarks and descriptions used in the above-mentioned studies seem not sufficient for correct positioning of the two separate bundles in all planes during arthroscopic surgery.

This study is aimed at acquiring quantitative geometric data of the ACL attachments on tibia and femur, such that these data can be used in an arthroscopically guided procedure for reconstruction of the ACL. We hypothesized that reliable guidelines to find the centres of the AMB, PLB and ACL relative to arthroscopically visible landmarks can be established. For the purpose of an anatomically accurate reconstruction of the ACL, the variations should be equal to or less than reported in other studies. As regard to the dimensions of drilled tunnel holes, normally 10 up to 12 mm, 95% (mean  $\pm$  2SD) of the attachment centres should be within this range. Therefore the a priori set assumption is that the maximally acceptable SD is 2.5 up to 3 mm.

## Methods

### Dissection

Thirty-five intact human cadaveric knee joints of elderly donors preserved in formalin, without signs of gross bony deformity, previous fracture or degenerative disease and with intact knee ligaments were dissected. Because of local post-dissection handling procedures, no exact data on gender and age of the donors were available, but they were older than 60 years. The muscles and anterior capsule were removed. The ligaments were left intact in order to preserve controlled motion of the knee. The femur was fixated in a clamp, the tibia was moved, resulting in flexion and extension of the knee joint. During this repeated passive movement, the two functional components of the ACL were identified, based on a visually detectable difference in their tensioning patterns as described by Girgis et al. [16]. In 90° of flexion, an anterior load was manually applied. This caused tension in the fibres of the medial tibial attachment site, the AMB. The fibres of the PLB remained slack. This procedure enabled a separation of the two bundles at the tibial attachment from ventral. The femur was turned in the clamp to enable a posterior approach and the posterior cruciate ligament (PCL) was removed. In this position the initial division of the ACL at the tibial attachment was visible and used to extend the division towards the femoral origin. The tibia was moved towards extension. The PLB-fibres, inserting at the lateral femoral ACL attachment site, tightened, enabling to complete the separation as far as the femoral attachment. The outline contours of both AMB and PLB attachment areas were marked, with a waterproof felt pen.

### Anatomical position

To quantify the position of the centres of the attachment sites relative to arthroscopically visible landmarks, three-dimensional (3D) measurements were made with a 3Space Fastrak electromagnetic tracking system (Polhemus Navigation Sciences, Colchester, VT, USA). The *x*, *y* and *z* co-ordinates of each measured point were recorded with an accuracy of 0.35 mm [42]. On the femur and tibia, the attachment sites of the AMB, PLB and the entire ACL were digitized by means of a collection of points placed at equal distances on the marked outlines. The 3D position of the centres of the ACL, AMB and PLB attachments were calculated by the geometric mean of all points on the outlines. The 3D distances between the centres of the two bundles were calculated. On both femur and tibia, an arthroscopically visible landmark was digitized that served as the origin of a local coordinate system. The absolute

two-dimensional (2D) positions of the centres relative to these landmarks were calculated. The position in the third dimension was determined by the surface geometry of the femoral condyle and the intercondylar tibial area, respectively.

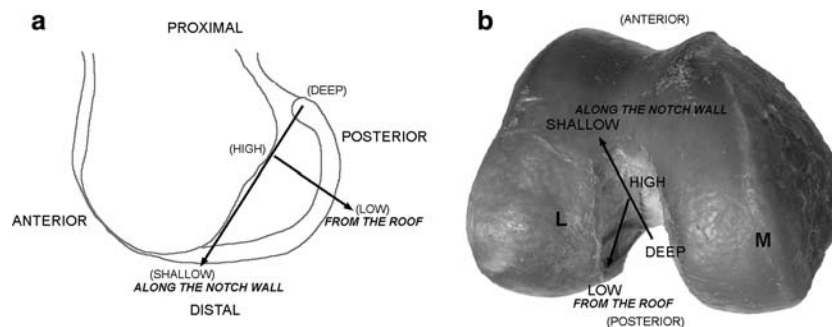
Absolute positions can depend on different knee sizes and the dimensions of the femoral notch and the intercondylar tibial area. To correct for this, the relative centre positions were also calculated. Additional reference points near the attachment area on femur and tibia were digitized. Between these points two reference lines were defined to create a 2D coordinate system. The distances defined the dimensions of the femoral notch and intercondylar tibial area. Absolute centre positions were transformed in positions relative to the reference lines (%) within femur and tibia. To detect whether the absolute position of the attachment centres was actually influenced by knee size, statistical analyses were performed. The relation between absolute position and knee size can be demonstrated with a correlation coefficient. The Pearson's correlations between the distances of the absolute positions and the length of the reference lines, representing knee size, were calculated. Correlations with a Pearson's correlation coefficient  $r > 0.6$  and a significance level  $P < 0.05$ , for a 95% alpha level were considered relevant and confirmed the relation between knee size and absolute centre position.

## Femur

In the anatomical nomenclature the femoral ACL attachment uses anterior/posterior and proximal/distal positions, relative to the extended knee [17] (Fig. 1a). Since this study aimed at describing the positions of the AMB and PLB of the femoral attachment from an arthroscopic perspective, the arthroscopic nomenclature was used as

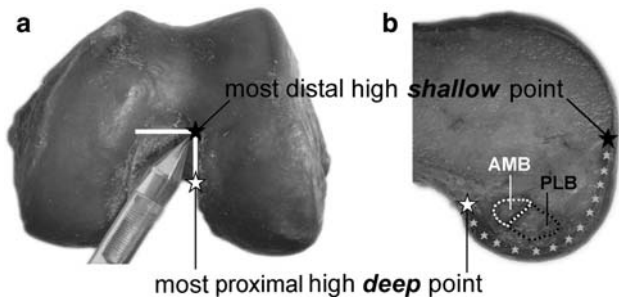
recommended by the ‘‘ESSKA Scientific Workshops’’ in 1998 [4]. The definitions, shallow/deep and high/low, refer to the position along the wall and from the roof of the intercondylar notch in a 90° flexed knee (Fig. 1b).

The digitized points on the femur are represented in Fig. 2. The main femoral landmark was derived from the over-the-top position, located at the posterior edge of the intercondylar notch. The most proximal high deep point (D) on the lateral condyle was found at the 10.30 o'clock position in the arc of the femoral notch, in a right knee (at 1.30 in a left knee) [17] (Fig. 2). The circumferences of the ACL attachments were digitized, as was the additional reference point, the most distal high shallow point (S). This point is positioned on the distal cartilage edge of the lateral condyle in the anterior notch outlet (Fig. 2a). The femoral coordinate system was defined with two reference lines (Fig. 3). The first-defined femoral reference line (from D to S) divided the notch roof from the notch wall and defined the length of the lateral notch depth (ND). The lowest, dorsal point (L) on the posterior joint cartilage edge was found using a line parallel to the line DS. The second reference line (from L to H) was defined from point L perpendicular to crossing point H, high in the notch at the line DS. It indicated the magnitude of the notch height (NH). After creating this coordinate system, the calculated attachment centres (C) of the ACL, AMB and PLB were projected on the line DS at point P. The absolute centre position (mm) was composed of the distance between the main femoral landmark, the high deep point D and the point P and the distance between the point P and the centre C. The relative (%) position was calculated by dividing the distance DP by DS (notch depth) and distance CP by LH (notch height). Finally the individual results were displayed in a diagram to define the distribution of the centres relative to the means and the advised tunnel position.

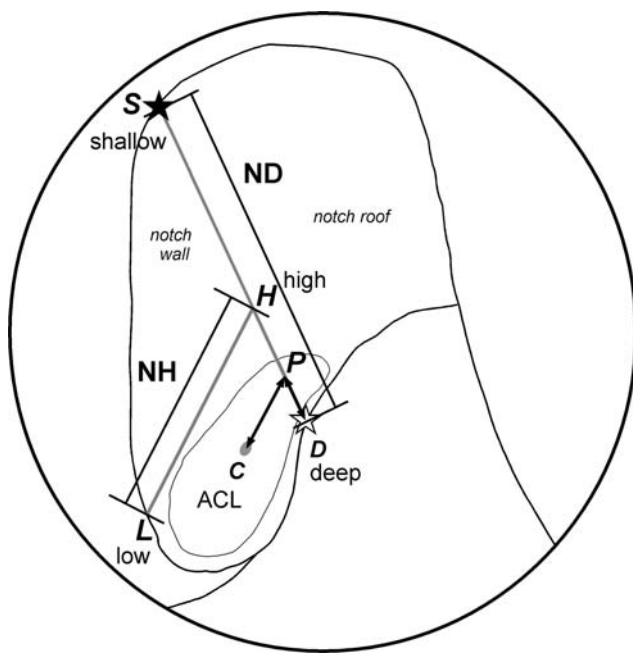


**Fig. 1** The orientation in the femoral notch, used in this study, is based on the recommendations of the ESSKA 1998 [4]. The notch depth (ND) is directed from *shallow* to *deep* in anatomic distal–proximal direction. The notch height (NH) is directed from *low* to

*high* in anatomic dorsal–ventral direction. The notch wall is located at the medial side of the lateral condyle. The notch roof is the connection between the two condyles



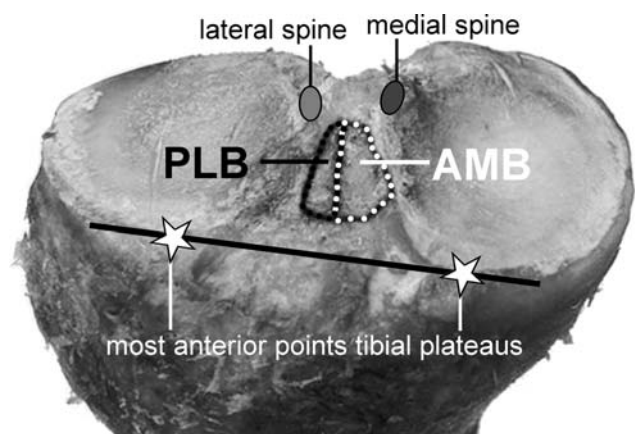
**Fig. 2** **a** Distal view at a left femur. The high shallow and high deep points of the cartilage border were determined by placing the stylus at the point of an imaginary *rectangular corner*, indicating the separation between wall and roof, this corresponds with the 1.30 o'clock position in a left knee (10.30 o'clock in a right knee). **b** View at the medial side of a left lateral femoral condyle. The points that were digitized: AMB (*white rounds*) and PLB (*black rounds*) attachments; the cartilage border (*grey asterisks*), with the most distal, high shallow point (*black asterisk*) and most proximal, high deep point (*white asterisk*) indicating the separation between the notch wall on the lateral condyle and the notch roof



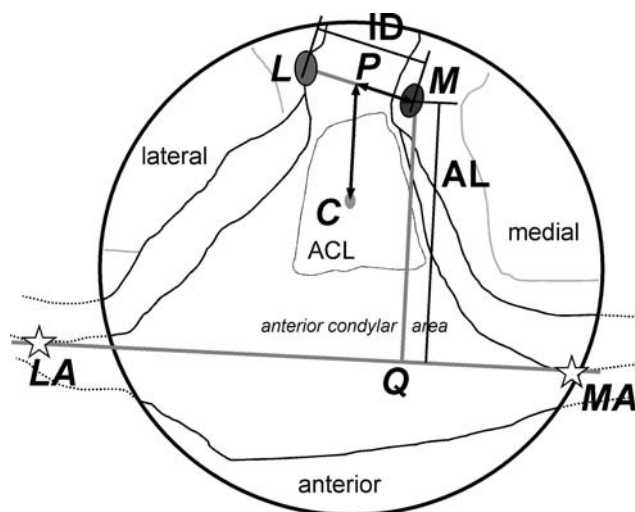
**Fig. 3** A schematic arthroscopic femoral view through the antero-medial portal. The femoral coordinate system is indicated. The *first reference line*, from the high deep point (D) to the high shallow point (S) on the cartilage edge separated the notch wall on the lateral condyle from the notch roof and defined the notch depth (ND). The *second reference line*, a perpendicular line, from the lowest point on the posterior cartilage edge (L) to the crossing point on the line DS (H) and defined the notch height (NH). The calculated attachment centre of the ACL (C) was projected on line DS (P). The absolute distances DP and CP were calculated, as were the distances relative to the reference lines (DP/DS and CP/LH). This was also done for the AMB and PLB, for the sake of clearness, only the *centre* of the entire ACL is depicted

Tibia

The digitized points on the tibia are represented in Fig. 4. The medial tibial spine (M) was determined as the main tibial landmark. The circumferences of the ACL attachments were digitized, as were the additional reference points. Those were, besides the lateral tibial spine (L), the most anterior points on the margin of the articular surfaces of the medial tibial condyle (MA) and lateral tibial condyle (LA). The tibial coordinate system was defined as follows (Fig. 5). The first tibial reference line (from M to L) was defined between the medial and the lateral tibial spine representing the interspinal distance (ID). A line connecting the anterior points MA and LA indicated the anterior margin of the articular surface of the medial and lateral condyles of the tibia. The second reference line (from M to Q) connected the medial spine (M) perpendicular with the anterior margin at crossing point Q. The length of the second reference line represents the length of the anterior intercondylar area (AL). After creating this coordinate system, the calculated attachment centres of the ACL, AMB and PLB were projected on the line ML at point P. The absolute centre position (mm) was composed of the distance between the major tibial landmark, the medial tibial spine M and the point P, and the distance between the point P and the centre C. The relative position (%) was calculated by dividing the distance MP by ML (interspinal distance) and distance CP by MQ (anterior length). Finally the individual results were displayed in a diagram to define the distribution of the centres relative to the means and the advised tunnel position.



**Fig. 4** Proximal view at the articular surfaces of the tibial condyles and the anterior intercondylar area. The points that were digitized: AMB (*white rounds*) and PLB (*black rounds*) attachments; the lateral tibial spine (*light grey oval*) and medial tibial spine (*dark grey oval*) and the most anterior points on the margin of the articular surface of the medial and lateral tibial condyles (*white asterisks*)



**Fig. 5** A schematic arthroscopic tibial view. The tibial coordinate system is indicated. The *first reference line*, from the medial spine (M) to the lateral spine (L), defined the interspinal distance (ID). The *second reference line*, from the medial spine (M) perpendicular to the crossing point (Q) at the anterior line between the most anterior points on the margin of the articular surface of the medial and lateral tibial condyles defined the anterior intercondylar length (AL). The calculated attachment centre (C) was projected on line ML (P). The absolute distances MP and CP were calculated, as were the distances relative to the reference lines (MP/ML and CP/MQ). This was also done for the AMB and PLB, for the sake of clearness, only the *centre* of the entire ACL is depicted

## Surface

To determine the surface dimensions of the bony attachment areas, a line was fitted through the digitized points on the outlines of both the AMB and PLB attachments on femur and on the tibia. The enclosed surface of all areas was calculated (in  $\text{mm}^2$ ), with the aid of a Delaunay triangulation based on the Qhull algorithm as provided by Matlab<sup>®</sup> (version 7 The MathWorks, Inc, more details provided on <http://www.mathworks.com>). The surface of the entire ACL attachment was calculated as the sum of AMB and PLB. Also the percentage of AMB and PLB surfaces was calculated relative to the ACL attachment surface. Statistical analyses to detect differences in size of the attachment surfaces were performed. Femoral AMB and femoral PLB, tibial AMB and tibial PLB and finally femoral ACL and tibial ACL were compared. A 2-tailed Student's *t* test for paired data was used. Statistical significance was defined as  $P < 0.05$ , for a 95% alpha level.

## Results

### Femur

The oval-shaped attachment of the anterior cruciate ligament was situated on the medial surface of the lateral

femoral condyle. It was positioned deep in the notch, covering most of the proximal half of the wall. The fibres of the deep low border attached to the edge of the joint cartilage, following the contour of this edge posteriorly on the condyle. In only 4 of the 35 specimens, the attachment site was completely limited to the medial wall of the lateral condyle and had no footprint in the notch roof. In 31 femurs, a small part of the deep high AMB attachment extended into the intercondylar notch roof.

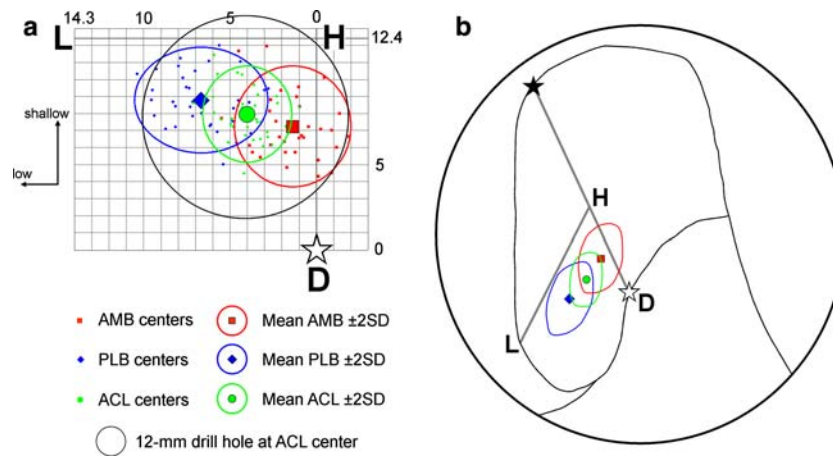
The notch depth ( $DS = 31.8 \pm 2.6$  mm) was the largest distance of the femoral dimensions. On average it was  $2\frac{1}{4}$  times the length of the notch height ( $LH = 14.3 \pm 1.5$  mm). In shallow–deep direction measured along the notch, relative to the notch depth, the centres of the two bundles were more close to each other, than in high–low direction measured from the roof, relative to the notch height. The mean position of all AMB centres along the roofline of the notch was 7.2 mm shallow from the high deep corner at  $\frac{1}{4}$  of the ND-line (Table 1; Fig. 6). In 9 of the 35 femurs the centre of the AMB was not situated on the condyle wall, but above the transition line on the notch roof. Therefore, the average centre was high in the notch at  $\frac{1}{10}$  of the NH-line, 1.4 mm from the roof. The centre of the PLB was positioned slightly more shallow at less than 2 mm from the AMB (Table 1; Fig. 6). However, it was situated clearly lower, about 5 mm, on the femoral condyle wall, approximately halfway the notch height. The centre position of the entire ACL was in the middle between the AMB and the PLB at  $\frac{1}{4}$  of both reference lines. Approximately 96% of the mean centres were inside a 12 mm drill hole, if positioned at the mean centre of the ACL attachment. The Pearson's correlation coefficients between the absolute positions and the reference lines were smaller than 0.3 and not significant ( $P > 0.05$ ).

The mean centres of the AMB and PLB were situated  $6.2 \pm 1.2$  mm from each other. The AMB attachment area, 45% of the total ACL, was significantly ( $P = 0.005$ ) smaller than the PLB attachment area (Table 2).

**Table 1** The positions of the ligament centres in the femoral notch

	Absolute distances (mm) mean (SD)		Relative distances (%) mean (SD)	
	DP	CP	DP/DS	CP/LH
AMB	7.2 (1.8)	1.4 (1.7)	23 (6)	10 (12)
PLB	8.8 (1.6)	6.7 (2.0)	28 (6)	47 (13)
ACL	7.9 (1.4)	4.0 (1.3)	25 (5)	28 (9)

*DP* The absolute distance from the high deep point D until point P, the projection of the mean ligament centre at the DS-line, in the notch depth direction; *CP* the absolute distance from the mean ligament centre until point P at the LH-line, in notch height direction; *DP/DS* The relative position of the centre to the notch depth; *CP/LH* The relative position of the centre to the notch height



**Fig. 6** **a** A two-dimensional graph of the medial side of a right lateral femoral condyle with the individual centres, and the mean centres with the 95% Confidence Interval of the AMB (red squares), PLB (blue diamonds) and ACL (green dots). The position of a 12 mm drill

hole at the ACL centre is also displayed. **b** A schematic arthroscopic view through the anteromedial portal with the mean centres and the 95% Confidence Interval areas of the AMB (red square with line), PLB (blue diamond with line) and ACL (green dot with line)

**Tibia**

The tibial attachment area of the ACL was situated between the medial and lateral tibial condyle covering the medial part of the anterior intercondylar area. It was stretched out from the region between the tibial spines to anterior with various extensions, more or less shaped as a footprint. The fibres of the AMB inserted medially along the cartilage edge of the articular surface of the medial tibial condyle. The PLB covered the lateral side of the attachment area and was bounded by the attachment of the anterior horn of the lateral meniscus.

The interspinal distance (ML = 12.9 ± 1.6 mm) between the medial and the lateral spine was on the average half times the length of the anterior intercondylar area (MQ = 24.8 ± 2.7 mm). The average centre of the AMB was situated closest to the medial spine, lateral at ¼ of the ID. The PLB was 4 mm more lateral, approximately half-way between the medial and lateral spine (Table 3; Fig. 7). The ACL was in between at 2/5 of the ID. In anterior direction the AMB, ACL and PLB were close to each other, just over 1/3 of the anterior length. Approximately 94% of the mean centres were inside a 10 mm drill hole, if positioned at the mean centre of the ACL attachment (Table 3; Fig. 7). The Pearson’s correlations coefficients between the absolute positions and the interspinal distance (reference line ML) were smaller than 0.3 and not significant (P > 0.05). The Pearson’s correlations coefficients between the absolute positions and the anterior length (reference line MQ) were significant (P < 0.05), however smaller than 0.6.

The mean centres of the AMB and PLB were situated 4.5 ± 0.1 mm from each other. The tibial AMB attachment area of 59% was significantly larger than the PLB

attachment area (P < 0.001). The tibial attachment area of the ACL and of the AMB was significantly larger than on the femur (P < 0.001) (Table 2).

**Discussion**

Incorrect tunnel placement, tibial [22, 25] as well as femoral [43], is seen as one of the most important causes of clinical failure in single-bundle ACL reconstructions [1]. In double-bundle ACL reconstruction, exact anatomic tunnel placement seems to be even more essential. Two bundles must be accurately placed relative to the surrounding structures and relative to each other. Although exact tunnel positioning is important, it seems difficult, even for experienced surgeons [8, 27, 47]. A clear description of the anatomic centres with guidelines to determine the correct tunnel position during arthroscopic procedures can improve the accuracy.

The femoral positions of the two distinct bundles found in this study, the AMB deep high and the PLB shallow low in the notch, are broadly in line with literature [11, 20, 32, 45, 52]. Compared to others, the landmarks that are used in the present study are more easy to locate during

**Table 2** The surface dimensions of the ACL and the two bundles at femur and tibia

	Absolute surface area (mm) mean (SD)			Relative surface to total ACL (%) mean (SD)	
	ACL	AMB	PLB	AMB	PLB
Femur	184 (52)	81 (27)	103 (39)	45 (11)	55 (11)
Tibia	229 (53)	136 (37)	93 (33)	59 (9)	41 (9)

**Table 3** The positions of the ligament centres at the anterior intercondylar tibial area

	Absolute distances (mm)		Relative distances (%)	
	mean (SD)		mean (SD)	
	MP	CP	MP/ML	CP/MQ
AMB	3.0 (1.6)	9.4 (2.2)	23 (12)	37 (9)
PLB	7.2 (1.8)	10.1 (2.1)	55 (13)	38 (9)
ACL	5.1 (1.7)	9.8 (2.1)	39 (12)	38 (8)

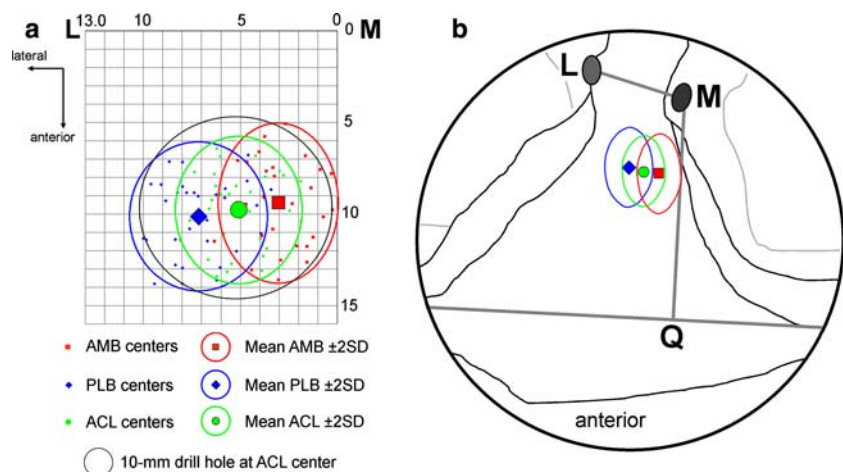
*MP* The absolute distance from the medial spine (M) until the point P, the projection of the mean ligament centre at the line ML in lateral direction; *CP* the absolute distance from the mean ligament centre until point P on the line ML, in anterior direction; *MP/ML* The relative position of the centre to the interspinal distance; *CP/MQ* The relative position of the centre to the anterior length

arthroscopy. Harner et al. [20] quantified the cross-sectional shape and area of the femoral and tibial attachments of both components in 10 knees without describing the positions relative to landmarks. Yasuda et al. [52] limit their study to the femoral attachment, using five specimens. They describe the centre of the PLB 5 to 8 mm anterior to the edge of the joint cartilage, on the vertical line through the contact point between the femoral condyle and the tibial plateau in a 90° flexed knee. Because this point depends on the position of the knee, it can be difficult to locate accurately during an arthroscopic procedure. Colombet et al. [11] examined seven specimens, collecting especially data of the attachment dimensions. The femoral results presented by the studies of Mochizuki et al. [32] and Takahashi et al. [45] are more suitable for practical use during arthroscopy; however, no exactly defined landmarks were used. The tibial results of Takahashi et al. [45] cannot easily be transferred to the arthroscopic situation. Finally, above-mentioned studies did not present the centres of the ACL attachment.

Tunnel positioning in the femoral notch is often determined by the ‘clock’ method [13, 18, 35, 36, 52, 54]. However, this only determines the high–low position from the roof, in the transversal plane along the arc of the femoral notch [17, 54]. The accuracy in the sagittal plane, deep–shallow along the roof of the notch, seems to affect the functional outcome more [17, 21, 29, 55, 56]. This position is often determined with a femoral guide placed behind the posterior edge of the intercondylar notch, at the over-the-top position, not to be confused with the Resident’s ridge [24]. This seems sufficiently accurate for determining the AMB centre, when a guide with a 7 mm offset is placed in the 10.30 or 1.30 o’clock position. The 7 mm offset of the guide places the tunnel in the sagittal plane close to the AMB centre position, found in this study, i.e. 7.2 mm shallow along the roof. Although we did not translate the measured distance in a clock position, the 10.30 clock position seems close to the measured position in the transversal plane, 1.4 mm low from the roof on the condyle wall. This corresponds with the results of Mochizuki et al. [32] and Yasuda et al. [52]. However, the clock method is sensitive to subjective interpretation of positioning the face of the clock [7]. It is not sufficient to find the correct position for the PLB, especially in the sagittal plane. Therefore Colombet et al. [11] defined an extra guideline to position the PLB tunnel: 8 mm lower and ‘shallower’ relative to the AMB centre, found with the clock method. The present study is more precise: 1.3 mm more shallow along the notch and 5.3 mm lower from the roof on the condyle wall, relative to the above-described position of the AMB centre. These positions can best be approached through an anteromedial arthroscopic portal [6].

Various methods can be used to determine the correct drill hole position at the tibia. Some authors prefer placement of the tibial tunnel based on avoiding graft impingement against the roof of the femoral notch with

**Fig. 7** **a** A two-dimensional graph of a right anterior intercondylar tibial area with the individual centres, and the mean centres with the 95% Confidence Interval of the AMB (red squares), PLB (blue diamonds) and ACL (green dots). The position of a 10 mm drill hole at the ACL centre is also displayed. **b** A schematic arthroscopic view with the mean centres and the 95% Confidence Interval areas of the AMB (red square with line), PLB (blue diamond with line) and ACL (green dot with line)





knee extension [22, 34, 44]. Others prefer guides that use the posterior cruciate ligament (PCL) attachment as reference point [31]. Based on these methods, positioning in anteroposterior direction, the sagittal plane, is defined. However, placement of the tunnel in mediolateral direction, the transversal plane, which is also important [26], is not determined. Some studies describe the mediolateral position, relative to the width of the tibial plateau [23, 45]. However, this guideline cannot be used during an arthroscopic procedure. The results of this study can be used for arthroscopic positioning in both directions.

The division of the AMB and PLB on the tibia in anteroposterior direction is similar to Harner et al. [20], resulting in a medial AMB and lateral PLB. This deviates only marginally from other definitions, where the division is in an anteromedial and a posterolateral part [3, 16, 38]. The position of the centres in anteroposterior direction correspond with the results of Takahashi et al. [45], who used similar reference points to define the anterior margin of the articular surface of the tibial condyles. The centres of the two bundles were more close to each other on the tibia, than on the femur.

The size of the femoral ACL attachment  $184 \pm 52 \text{ mm}^2$  was similar to the result of Odensten and Gillquist ( $200 \text{ mm}^2$ ) [38]. Other studies found smaller attachment areas,  $132 \text{ mm}^2$  [45] and  $113 \text{ mm}^2$  [20]. This difference may be caused by a different measuring method, using the largest projection in a 2D image plane. Our study measured the actual three-dimensional attachment area. The partition of the femoral attachment area was nearly equal with 45%, 55%, respectively, for the AMB and PLB. This was comparable to Harner et al. [20] (AMB = 52%, PLB = 48%) and Takahashi et al. [45] (AMB = 50%, PLB = 50%). The average tibial attachment area found in this study was larger than the femoral attachment. This is in line with the results of Girgis et al. [16] and Fuss et al. [15]. On the other hand, Takahashi et al. [45] found that the femoral attachment was larger than the tibial attachment ( $132$  vs  $119 \text{ mm}^2$ ). Harner et al. [20] and Odensten and Gillquist [38] found similar sizes for the tibial and femoral attachment areas. In our study the AMB occupied 59% of the tibial attachment, nearly similar to the 57% of Takahashi et al. [45], slightly more than the 52% Harner et al. [20] found.

There was a large variation in knee sizes and dimensions of the reference lines. However, we did not find a correlation between the absolute distance of the attachment centres and the size of the reference lines, i.e. knee size. The absolute positions of the attachment centres were more or less similar for large and small knees. Therefore both absolute as well as relative data can be used as guidelines to find the anatomical positions. At the arthroscopic view, the absolute positions are more useful than the relative positions.

As regards to the dimensions of drilled tunnel holes (10–12 mm), the standard deviations of the attachment centres within 3 mm are acceptable. The femoral positions had less variations than the tibial positions. The positions for the entire ACL attachment had less variations than the attachment positions for the separate bundles. The results of this study seem to produce accurate guidelines to find the anatomic tunnel position during arthroscopic reconstruction. However, some limitations must be mentioned. The subdivision of the ACL in AMB and PLB is not based on anatomically distinct fibre bundles surrounded with fibrous issue [5, 15, 33, 38]. Fibres of both bundles are twisted around each other [33]. Division of the ACL in separate bundles is not easy [3]. Therefore utmost care was taken to divide the two functional bundles according to a previously described method [11, 20]. The method, based on observed tension variation during passive flexion–extension movement was reported to be consistent [32]. This is expressed in the standard deviations (SD) of the mean attachment centres. The variation of the population is expressed by the SD of the ACL centre. The SD of the mean PLB and mean AMB centres show this variation combined with the division error. For the tibia the SDs of the PLB and AMB attachment centres are equal to that of the ACL. For the femur the SDs of the two bundle centres are slightly larger. However, these results do not point to large errors in the identification of the two bundles. The variations of attachment centre positions are actually rather small and similar to other studies [11, 45].

The age of the cadaveric knee specimens was more than 60 years. However, only knees without severe arthritic signs were evaluated. It seems likely that the data can be transferred to the, mostly younger, population receiving an ACL reconstruction [3, 11, 34, 44]. Perfusion fixation preserves the outer contours of shapes i.e. ligament bundles, so neither the identification nor the measurements of the various bundles can be assumed to have been hampered by the fixation.

## Conclusions

This study was performed because no earlier study described the ACL, AMB and PLB attachment centres relative to arthroscopically visible landmarks. This resulted in quantitative data of the positions of the attachment centres of the ACL and its two bundles, relative to bony landmarks on femur and tibia, visible through an arthroscope. Using these results, the surgeon will be able to determine the anatomical position of the ACL and the two functional bundles during arthroscopy without additional images or fluoroscopic support. The results can be applied for anatomic single-bundle or anatomic double-bundle techniques.

**Acknowledgments** The authors would like to thank Willem van de Wijdeven, Huub Peeters and Bart Nienhuis for their contributions to this work. This study was funded by grant 99-W14 from the AO Research Fund, Association for Osteosynthesis Foundation, Switzerland.

## References

- Aglietti P, Buzzi R, Giron F, Simeone AJ, Zaccherotti G (1997) Arthroscopic-assisted anterior cruciate ligament reconstruction with the central third patellar tendon. A 5–8-year follow-up. *Knee Surg Sports Traumatol Arthrosc* 5(3):138–144
- Amis AA, Beynonn B, Blankevoort L, Chambat P, Christel P, Durselen L, Friederich N, Grood E, Hertel P, Jakob R (1994) Proceedings of the ESSKA Scientific Workshop on Reconstruction of the Anterior and Posterior Cruciate Ligaments. *Knee Surg Sports Traumatol Arthrosc* 2(3):124–132
- Amis AA, Dawkins GP (1991) Functional anatomy of the anterior cruciate ligament. Fibre bundle actions related to ligament replacements and injuries. *J Bone Joint Surg Br* 73(2):260–267
- Amis AA, Jakob RP (1998) Anterior cruciate ligament graft positioning, tensioning and twisting. *Knee Surg Sports Traumatol Arthrosc* 6(Suppl 1):S2–S12
- Arnoczky SP (1983) Anatomy of the anterior cruciate ligament. *Clin Orthop* 172:19–25
- Arnold MP, Kooloos J, Van Kampen (2001) Single-incision technique misses the anatomical femoral anterior cruciate ligament insertion: a cadaver study. *Knee Surg Sports Traumatol Arthrosc* 9(4):194–199
- Arnold MP, Verdonschot N, Van Kampen (2005) ACL graft can replicate the normal ligament's tension curve. *Knee Surg Sports Traumatol Arthrosc* 13(8):625–631
- Behrend H, Stutz G, Kessler MA, Rukavina A, Giesinger K, Kuster MS (2006) Tunnel placement in anterior cruciate ligament (ACL) reconstruction: quality control in a teaching hospital. *Knee Surg Sports Traumatol Arthrosc* 14(11):1159–1165
- Bellier G, Christel P, Colombet P, Djian P, Franceschi JP, Sbihi A (2004) Double-stranded hamstring graft for anterior cruciate ligament reconstruction. *Arthroscopy* 20(8):890–894
- Buonocristiani AM, Tjoumakaris FP, Starman JS, Ferretti M, Fu FH (2006) Anatomic double-bundle anterior cruciate ligament reconstruction. *Arthroscopy* 22(9):1000–1006
- Colombet P, Robinson J, Christel P, Franceschi JP, Djian P, Bellier G, Sbihi A (2006) Morphology of anterior cruciate ligament attachments for anatomic reconstruction: a cadaveric dissection and radiographic study. *Arthroscopy* 22(9):984–992
- Dodds JA, Arnoczky SP (1994) Anatomy of the anterior cruciate ligament: a blueprint for repair and reconstruction. *Arthroscopy* 10(2):132–139
- Franceschi JP, Sbihi A, Champsaur P (2002) [Arthroscopic reconstruction of the anterior cruciate ligament using double anteromedial and posterolateral bundles]. *Rev Chir Orthop Reparatrice Appar Mot* 88(7):691–697
- Fu FH, Harner CD, Johnson DL, Miller MD, Woo SL (1994) Biomechanics of knee ligaments: basic concepts and clinical application. *Instr Course Lect* 43:137–148
- Fuss FK (1989) Anatomy of the cruciate ligaments and their function in extension and flexion of the human knee joint. *Am J Anat* 184(2):165–176
- Girgis FG, Marshall JL, Monajem A (1975) The cruciate ligaments of the knee joint. Anatomical, functional and experimental analysis. *Clin Orthop* 106:216–231
- Giron F, Cuomo P, Aglietti P, Bull AM, Amis AA (2006) Femoral attachment of the anterior cruciate ligament. *Knee Surg Sports Traumatol Arthrosc* 14(3):250–256
- Hamada M, Shino K, Horibe S, Mitsuoka T, Miyama T, Shiozaki Y, Mae T (2001) Single- versus bi-socket anterior cruciate ligament reconstruction using autogenous multiple-stranded hamstring tendons with endoButton femoral fixation: a prospective study. *Arthroscopy* 17(8):801–807
- Hara K, Kubo T, Suginosita T, Shimizu C, Hirasawa Y (2000) Reconstruction of the anterior cruciate ligament using a double bundle. *Arthroscopy* 16(8):860–864
- Harner CD, Baek GH, Vogrin TM, Carlin GJ, Kashiwaguchi S, Woo SL (1999) Quantitative analysis of human cruciate ligament insertions. *Arthroscopy* 15(7):741–749
- Hefzy MS, Grood ES, Noyes FR (1989) Factors affecting the region of most isometric femoral attachments. Part II The anterior cruciate ligament. *Am J Sports Med* 17(2):208–216
- Howell SM, Clark JA (1992) Tibial tunnel placement in anterior cruciate ligament reconstructions and graft impingement. *Clin Orthop* 283:187–195
- Howell SM, Wallace MP, Hull ML, Deutsch ML (1999) Evaluation of the single-incision arthroscopic technique for anterior cruciate ligament replacement. A study of tibial tunnel placement, intraoperative graft tension, and stability. *Am J Sports Med* 27(3):284–293
- Hutchinson MR, Ash SA (2003) Resident's ridge: assessing the cortical thickness of the lateral wall and roof of the intercondylar notch. *Arthroscopy* 19(9):931–935
- Ikeda H, Muneta T, Niga S, Hoshino A, Asahina S, Yamamoto H (1999) The long-term effects of tibial drill hole position on the outcome of anterior cruciate ligament reconstruction. *Arthroscopy* 15(3):287–291
- Jackson DW, Gasser SI (1994) Tibial tunnel placement in ACL reconstruction. *Arthroscopy* 10(2):124–131
- Kohn D, Busche T, Carls J (1998) Drill hole position in endoscopic anterior cruciate ligament reconstruction. Results of an advanced arthroscopy course. *Knee Surg Sports Traumatol Arthrosc* 6(Suppl 1):S13–S15
- Loh JC, Fukuda Y, Tsuda E, Steadman RJ, Fu FH, Woo SL (2003) Knee stability and graft function following anterior cruciate ligament reconstruction: comparison between 11 o'clock and 10 o'clock femoral tunnel placement. *Arthroscopy* 19(3):297–304
- Markolf KL, Hame S, Hunter DM, Oakes DA, Zoric B, Gause P, Finerman GA (2002) Effects of femoral tunnel placement on knee laxity and forces in an anterior cruciate ligament graft. *J Orthop Res* 20(5):1016–1024
- Marshall JL, Wang JB, Furman W, Girgis FG, Warren R (1975) The anterior drawer sign: what is it? *J Sports Med* 3(4):152–158
- McGuire DA, Hendricks SD, Sanders HM (1997) The relationship between anterior cruciate ligament reconstruction tibial tunnel location and the anterior aspect of the posterior cruciate ligament insertion. *Arthroscopy* 13(4):465–473
- Mochizuki T, Muneta T, Nagase T, Shirasawa S, Akita KI, Sekiya I (2006) Cadaveric knee observation study for describing anatomic femoral tunnel placement for two-bundle anterior cruciate ligament reconstruction. *Arthroscopy* 22(4):356–361
- Mommersteeg TJ, Kooloos JG, Blankevoort L, Kauer JM, Huiskes R, Roeling FQ (1995) The fibre bundle anatomy of human cruciate ligaments. *J Anat* 187(Pt 2):461–471
- Morgan CD, Kalman VR, Grawl DM (1995) Definitive landmarks for reproducible tibial tunnel placement in anterior cruciate ligament reconstruction. *Arthroscopy* 11(3):275–288
- Muneta T, Sekiya I, Yagishita K, Ogiuchi T, Yamamoto H, Shinomiya K (1999) Two-bundle reconstruction of the anterior cruciate ligament using semitendinosus tendon with endobuttons: operative technique and preliminary results. *Arthroscopy* 15(6):618–624

36. Musahl V, Plakseychuk A, VanScyoc A, Sasaki T, Debski RE, McMahon PJ, Fu FH (2005) Varying femoral tunnels between the anatomical footprint and isometric positions: effect on kinematics of the anterior cruciate ligament-reconstructed knee. *Am J Sports Med* 33(5):712–718
37. Norwood LA, Cross MJ (1979) Anterior cruciate ligament: functional anatomy of its bundles in rotatory instabilities. *Am J Sports Med* 7(1):23–26
38. Odensten M, Gillquist J (1985) Functional anatomy of the anterior cruciate ligament and a rationale for reconstruction. *J Bone Joint Surg Am* 67(2):257–262
39. Papachristou G, Tilentzoglou A, Efsthopoulos N, Khaldi L (1998) Reconstruction of anterior cruciate ligament using the doubled tendon graft technique: an experimental study in rabbits. *Knee Surg Sports Traumatol Arthrosc* 6(4):246–252
40. Pederzini L, Adriani E, Botticella C, Tosi M (2000) Technical note: double tibial tunnel using quadriceps tendon in anterior cruciate ligament reconstruction. *Arthroscopy* 16(5):E9
41. Radford WJ, Amis AA (1990) Biomechanics of a double prosthetic ligament in the anterior cruciate deficient knee. *J Bone Joint Surg Br* 72(6):1038–1043
42. Sidles JA, Larson RV, Garbini JL, Downey DJ, Matsen FA III (1988) Ligament length relationships in the moving knee. *J Orthop Res* 6(4):593–610
43. Sommer C, Friederich NF, Muller W (2000) Improperly placed anterior cruciate ligament grafts: correlation between radiological parameters and clinical results. *Knee Surg Sports Traumatol Arthrosc* 8(4):207–213
44. Staubli HU, Rauschnig W (1994) Tibial attachment area of the anterior cruciate ligament in the extended knee position. Anatomy and cryosections in vitro complemented by magnetic resonance arthrography in vivo. *Knee Surg Sports Traumatol Arthrosc* 2(3):138–146
45. Takahashi M, Doi M, Abe M, Suzuki D, Nagano A (2006) Anatomical study of the femoral and tibial insertions of the anteromedial and posterolateral bundles of human anterior cruciate ligament. *Am J Sports Med* 34(5):787–792
46. Takeuchi R, Saito T, Mituhashi S, Suzuki E, Yamada I, Koshino T (2002) Double-bundle anatomic anterior cruciate ligament reconstruction using bone-hamstring-bone composite graft. *Arthroscopy* 18(5):550–555
47. Topliss C, Webb J (2001) An audit of tunnel position in anterior cruciate ligament reconstruction. *Knee* 8(1):59–63
48. Torg JS, Conrad W, Kalen V (1976) Clinical diagnosis of anterior cruciate ligament instability in the athlete. *Am J Sports Med* 4(2):84–93
49. Yagi M, Kuroda R, Nagamune K, Yoshiya S, Kurosaka M (2007) Double-bundle ACL reconstruction can improve rotational stability. *Clin Orthop Relat Res* 454:100–107
50. Yagi M, Wong EK, Kanamori A, Debski RE, Fu FH, Woo SL (2002) Biomechanical analysis of an anatomic anterior cruciate ligament reconstruction. *Am J Sports Med* 30(5):660–666
51. Yamamoto Y, Hsu WH, Woo SL, Van Scyoc AH, Takakura Y, Debski RE (2004) Knee stability and graft function after anterior cruciate ligament reconstruction: a comparison of a lateral and an anatomical femoral tunnel placement. *Am J Sports Med* 32(8):1825–1832
52. Yasuda K, Kondo E, Ichiyama H, Kitamura N, Tanabe Y, Tohyama H, Minami A (2004) Anatomic reconstruction of the anteromedial and posterolateral bundles of the anterior cruciate ligament using hamstring tendon grafts. *Arthroscopy* 20(10):1015–1025
53. Yasuda K, Kondo E, Ichiyama H, Tanabe Y, Tohyama H (2006) Clinical evaluation of anatomic double-bundle anterior cruciate ligament reconstruction procedure using hamstring tendon grafts: comparisons among 3 different procedures. *Arthroscopy* 22(3):240–251
54. Zantop T, Petersen W, Sekiya JK, Musahl V, Fu FH (2006) Anterior cruciate ligament anatomy and function relating to anatomical reconstruction. *Knee Surg Sports Traumatol Arthrosc* 14(10):982–992
55. Zavras TD, Race A, Amis AA (2005) The effect of femoral attachment location on anterior cruciate ligament reconstruction: graft tension patterns and restoration of normal anterior–posterior laxity patterns. *Knee Surg Sports Traumatol Arthrosc* 13(2):92–100
56. Zavras TD, Race A, Bull AM, Amis AA (2001) A comparative study of ‘isometric’ points for anterior cruciate ligament graft attachment. *Knee Surg Sports Traumatol Arthrosc* 9(1):28–33