

PDF hosted at the Radboud Repository of the Radboud University Nijmegen

The following full text is a publisher's version.

For additional information about this publication click this link.

<http://hdl.handle.net/2066/23217>

Please be advised that this information was generated on 2020-09-28 and may be subject to change.

2,8-DIHYDROXYADENINE STONE FORMATION IN A RENAL TRANSPLANT RECIPIENT DUE TO ADENINE PHOSPHORIBOSYLTRANSFERASE DEFICIENCY

DIRK J. DE JONG, KAREL J. M. ASSMANN, RONNEY A. DE ABREU, LEO A. H. MONNENS, FRANS J. H. M. VAN LIEBERGEN, HENRI B. P. M. DIJKMAN AND FRANS T. M. HUYSMANS

From the Department of Internal Medicine, Bosch Medicentrum, s'-Hertogenbosch and Departments of Pathology, Pediatrics and Nephrology, University Hospital Nijmegen, Nijmegen, The Netherlands

KEY WORDS: kidney, urinary calculi, kidney transplantation, adenine phosphoribosyltransferase

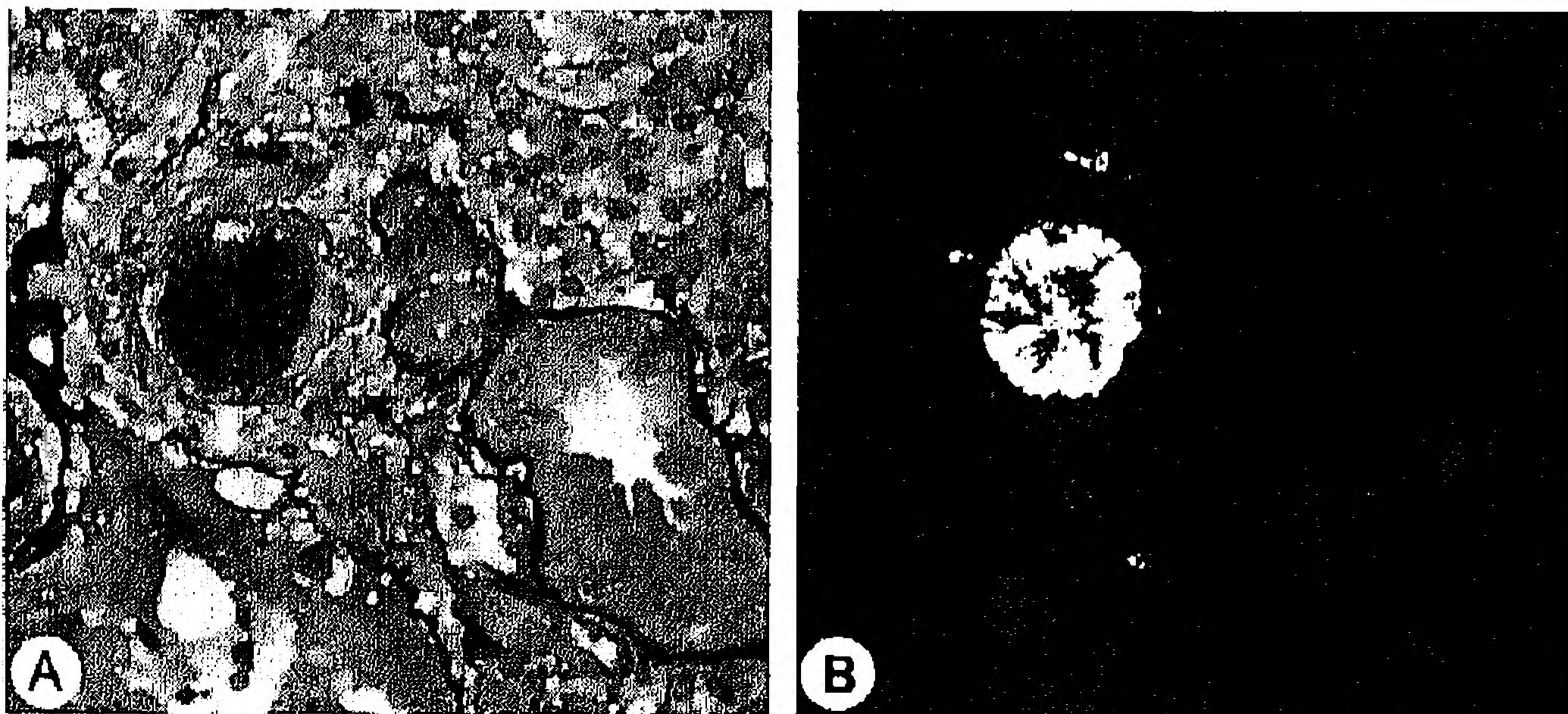
2,8-Dihydroxyadenine urolithiasis is a rare but probably under diagnosed disorder^{1,2} that may ultimately lead to chronic renal failure caused by recurrent stone formation.³⁻⁸ In this hereditary condition stones form due to a homozygote adenine phosphoribosyltransferase deficiency that makes conversion of adenine to adenine monophosphate impossible. Instead of adenine monophosphate, insoluble 8-hydroxyadenine and 2,8-dihydroxyadenine are formed. Inhibition of xanthine oxidase activity with allopurinol prevents the conversion of adenine to 8-hydroxyadenine and 2,8-dihydroxyadenine, effectively inhibiting 2,8-dihydroxyadenine crystal and stone formation.^{1,3,5,6} We report on a renal transplant recipient with a history of urolithiasis and 2,8-dihydroxyadenine crystal formation in the renal graft.

CASE REPORT

A 56-year-old man on peritoneal dialysis had a history of recurrent radiolucent and radiopaque urolithiasis of supposed uric acid composition, necessitating 9 surgical interventions between the ages of 16 and 41 years. At the end of this period endogenous creatinine clearance was 84 ml. per minute. Subsequently during 15 years of treatment with allopurinol only 1 renal stone developed but renal function gradually decreased, probably because of frequently recurring pyelonephritis.

Renal transplantation was performed and allopurinol was discontinued. Biopsy of the renal graft was obtained on day 10 postoperatively because of oliguria. Little sign of rejection or cyclosporine nephrotoxicity was noted but there were many round yellow-brownish crystals of various sizes in the tubular lumina, epithelial cells and interstitium, where they were sometimes surrounded by macrophages and an occasional giant cell (part A of figure). Under polarized light the crystals appeared to be birefringent and composed of radially arranged fine needles (part B of figure). This material was also observed in urinary sediment. Serum level and urinary excretion of uric acid were normal. After conversion of cyclo-

Accepted for publication April 12, 1996.



Biopsy of renal transplant. A, crystalline material in interstitium and tubuli. B, same area under polarized light. Methenamine silver stain, reduced from $\times 420$.

sporine to azathioprine maximal endogenous creatinine clearance was only 32 ml. per minute.

Biopsies on days 27 and 51 showed acute interstitial rejection with tubulointerstitial damage in addition to crystals. Despite antirejection treatments hemodialysis had to be started on day 80. The graft was removed 6 months later with signs of chronic vascular rejection and diffuse deposition of crystals. Biopsy of the contralateral kidney of the donor obtained because of insufficient renal transplant function showed signs of cyclosporine nephrotoxicity and mild vascular rejection but no crystals.

2,8-Dihydroxyadenine urolithiasis was suspected on crystal morphology and confirmed by detection of 2,8-dihydroxyadenine on high performance liquid chromatography in urine and serum, and on crystal analysis by x-ray diffraction microanalysis. Mean adenine phosphoribosyltransferase activity in lymphocytes plus or minus standard deviation was 0.7 ± 0.6 nmol./ 10^6 cells per hour (normal 13.6 ± 0.9) in our patient, in the normal range in his brother, and intermediate in his 2 sisters and 2 children (11.9 ± 0.9 and 4.7 to 5.8 nmol./ 10^6 cells per hour, respectively). 2,8-Dihydroxyadenine was not measurable in urine samples from these relatives. The data support the hereditary homozygous character of 2,8-dihydroxyadenine urolithiasis due to adenine phosphoribosyltransferase deficiency.¹

DISCUSSION

Our patient had a long history of urolithiasis. After renal transplantation 2,8-dihydroxyadenine crystals in the renal graft led to considerable destruction of the graft, although a role for other factors, such as rejection, cannot be excluded. Only a few other cases with 2,8-dihydroxyadenine crystal formation in a renal graft have been reported.^{1,5,9} In general, 2,8-dihydroxyadenine urolithiasis is a rare but under diagnosed disorder.¹ Due to chemical similarity 2,8-dihydroxyadenine can easily be mistaken for uric acid.¹ Therefore, in our patient stone formation was probably initially due to 2,8-dihydroxyadeninuria, resulting in renal failure. Also, the prevention of new stone formation after the start of allopurinol therapy supports 2,8-dihydroxyadenine stone formation from the outset.

CONCLUSIONS

Since new stone formation can be prevented with allopurinol,^{1,5} early diagnosis of 2,8-dihydroxyadenine urolithiasis is warranted and it can be suggested by the aspect of the crystals in urine. The diagnosis can be made by analysis of crystal or stone composition, and confirmed by measurement of 2,8-dihydroxyadenine levels in urine and serum, and adenine phosphoribosyltransferase activity in lymphocytes. The risk in family members can be assessed by measuring adenine phosphoribosyltransferase activity in the lymphocytes.

REFERENCES

1. Simmonds, H. A., Sahota, A. S. and van Acker, K. J.: Adenine phosphoribosyltransferase deficiency and 2,8-dihydroxyadenine lithiasis. In: *The Metabolic Basis of Inherited Disease*, 6th ed. Edited by C. R. Scriver, A. L. Beaudet, W. S. Sly and D. Valle. New York: McGraw-Hill, chapt. 39, pp. 1029-1044, 1989.
2. Johnson, L. A., Gordon, R. B. and Emmerson, B. T.: Adenine phosphoribosyltransferase: a simple spectrophotometric assay and the incidence of mutation in the normal population. *Biochem. Genet.*, **15**: 265, 1977.
3. Greenwood, M. C., Dillon, M. J., Simmonds, H. A., Barratt, T. M., Pincott, J. R. and Metreweli, C.: Renal failure due to 2,8-dihydroxyadenine urolithiasis. *Eur. J. Ped.*, **138**: 346, 1982.
4. Schabel, F., Doppler, W., Hirsch-Kauffmann, M., Glatzl, J., Schweiger, M., Berger, H. and Heinz-Erian, P.: Hereditary deficiency of adenine phosphoribosyl transferase. *Paed. Paedol.*, **15**: 233, 1980.
5. Glicklich, D., Gruber, H. E., Matas, A. J., Tellis, V. A., Karwa, G., Finley, K., Salem, C., Soberman, R. and Seegmiller, J. E.: 2,8-Dihydroxyadenine urolithiasis: report of a case first diagnosed after renal transplant. *Quart. J. Med.*, **69**: 785, 1988.
6. Van Acker, K. J., Simmonds, H. A., Potter, C. and Cameron, J. S.: Complete deficiency of adenine phosphoribosyltransferase. Report of a family. *New Engl. J. Med.*, **297**: 127, 1977.
7. Usenius, J.-P., Ruopuro, M.-L. and Usenius, R.: Adenine phosphoribosyltransferase deficiency: 2,8-dihydroxyadenine urolithiasis in a 48-year-old woman. *Brit. J. Urol.*, **62**: 521, 1988.
8. Chevet, D., Le Pogamp, P., Gie, S., Gary, J., Daudon, M. and Hamet, M.: 2,8-Dihydroxyadenine urolithiasis in an adult. Complete adenine phosphoribosyl transferase deficiency. Family study. *Kidney Int.*, **26**: 226, 1984.
9. Gagné, E. R., Deland, E., Daudon, M., Noël, L. H. and Nawar, T.: Chronic renal failure secondary to 2,8-dihydroxyadenine deposition: the first report of recurrence in a kidney transplant. *Amer. J. Kidney Dis.*, **24**: 104, 1994.