

PDF hosted at the Radboud Repository of the Radboud University Nijmegen

The following full text is a publisher's version.

For additional information about this publication click this link.

<https://hdl.handle.net/2066/226267>

Please be advised that this information was generated on 2021-04-11 and may be subject to change.

BRAIN COMMUNICATIONS

Ophthalmological findings in facioscapulohumeral dystrophy

Rianne J. M. Goselink,¹ Vivian Schreur,² Caroline R. van Kernebeek,¹ George W. Padberg,¹ Silvère M. van der Maarel,³ Baziel G. M. van Engelen,¹ Corrie E. Erasmus¹ and Thomas Theelen²

Ophthalmological abnormalities in facioscapulohumeral dystrophy may lead to treatable vision loss, facilitate diagnostics, could help unravelling the pathophysiology and serve as biomarkers. In this study, we provide a detailed description of the ophthalmological findings in a well-defined cohort of patients with facioscapulohumeral dystrophy using state of the art retina imaging techniques. Thirty-three genetically confirmed patients (aged 7–80 years) and 24 unrelated healthy controls (aged 6–68 years) underwent clinical ophthalmological examination, fundus photography, optical coherence tomography/angiography, genotyping and neurological examination. All patients had normal corrected visual acuity and normal intraocular pressure. In 27 of the 33 patients, weakness of the orbicularis oculi was observed. Central retinal pathology, only seen in patients and not in healthy controls, included twisting (tortuosity) of the retinal arteries in 25 of the 33 patients and retinal pigment epithelium defects in 4 of the 33 patients. Asymmetrical foveal hypoplasia was present in three patients, and exudative abnormalities were observed in one patient. There was a correlation between the severity of retinal tortuosity and the D4Z4 repeat array size ($R^2 = 0.44$, $P < 0.005$). Follow-up examination in a subgroup of six patients did not show any changes after 2 years. To conclude, retinal abnormalities were frequent but almost always subclinical in patients with facioscapulohumeral dystrophy and consisted primarily of arterial tortuosity and foveal abnormalities. Retinal tortuosity was seen in the retinal arterioles and correlated with the D4Z4 repeat array size, thereby providing clinical evidence for an underlying genetic linkage between the retina and facioscapulohumeral dystrophy.

1 Department of Neurology, Donders Centre for Neuroscience, Radboud University Medical Centre, Nijmegen 6500 HB, The Netherlands

2 Department of Ophthalmology, Radboud University Medical Centre, Nijmegen 6500 HB, The Netherlands

3 Department of Human Genetics, Leiden University Medical Centre, 2333 ZC Leiden, The Netherlands

Correspondence to:

Rianne J. M. Goselink, MD

Department of Neurology (943)

Donders Centre for Neuroscience

Radboud University Medical Centre

P.O. Box 9101, Nijmegen 6500 HB, The Netherlands

E-mail: rianne.goselink@radboudumc.nl

Keywords: neuromuscular diseases; muscular dystrophy; facioscapulohumeral; retinal telangiectasis

Abbreviations: DCP = deep capillary plexus; FSHD = facioscapulohumeral dystrophy; OCT = optical coherence tomography; OCT = optical coherence tomography angiography; SCP = superficial capillary plexus; TI = tortuosity index

Received July 03, 2019. Revised August 28, 2019. Accepted September 16, 2019. Advance Access publication October 11, 2019

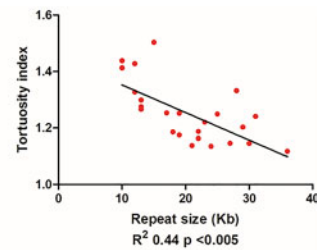
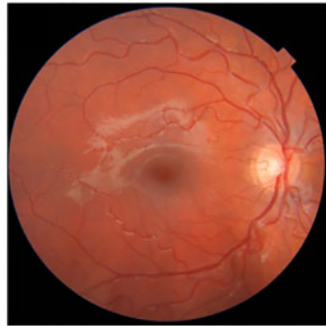© The Author(s) (2019). Published by Oxford University Press on behalf of the Guarantors of Brain.

This is an Open Access article distributed under the terms of the Creative Commons Attribution Non-Commercial License (<http://creativecommons.org/licenses/by-nc/4.0/>), which permits non-commercial re-use, distribution, and reproduction in any medium, provided the original work is properly cited. For commercial re-use, please contact journals.permissions@oup.com

Graphical Abstract

Ophthalmologic findings in Facioscapulohumeral dystrophy

Retinal abnormalities such as arterial tortuosity were frequent (27/33 patients) and mostly subclinical.



The severity of retinal tortuosity was correlated with the genetic defect. This provides clinical evidence for an underlying genetic linkage between the retina and FSHD.

Introduction

Facioscapulohumeral dystrophy (FSHD) is one of the most frequent muscular dystrophies and is hallmarked by progressive and irreversible muscle weakness (Mul *et al.*, 2016). However, systemic complications, such as vision loss, hearing loss, intellectual disability and epilepsy, may occur as well (Trevisan *et al.*, 2008; Chen *et al.*, 2013; Dorobek *et al.*, 2015; Nikolic *et al.*, 2016). Ophthalmological features have received little attention in FSHD because the original description in 1987 (Fitzsimons *et al.*, 1987), which is remarkably given that retinal abnormalities in FSHD may: (i) lead to treatable vision loss; (ii) facilitate diagnosing FSHD in patients with and without a muscular phenotype (Bass *et al.*, 2011; Vance *et al.*, 2011; Sgobbi de Souza *et al.*, 2016); (iii) help to unravel the pathophysiology of FSHD and (iv) serve as a biomarker (Longmuir *et al.*, 2010).

Signature ophthalmological pathology in FSHD consists of capillary abnormalities in the retinal periphery, which may lead to Coats-like syndrome (Fitzsimons *et al.*, 1987; Ganesh *et al.*, 2012; Statland *et al.*, 2013). The term Coats-like syndrome is derived from Coats' disease, a non-hereditary retinal condition, which usually occurs unilaterally in young males. Coats-like syndrome and Coats' disease are assumed to have an identical underlying mechanism of abnormal retinal vessel architecture, leading to exudations, retinal detachment and secondary glaucoma (Fitzsimons *et al.*, 1987; Shields *et al.*, 2001; Shields and Shields, 2002; Ramasubramanian and Shields, 2012; Matos *et al.*, 2017). Coats-like syndrome may cause severe visual impairment up to blindness in FSHD if not treated timely (Matos *et al.*, 2017). Current guidelines advise

referral to ophthalmological specialists for patients with FSHD with visual complaints or with a severe pathogenic variant (Tawil *et al.*, 2015). However, data on the frequency and techniques for accurate ophthalmological monitoring in FSHD are lacking (Tawil *et al.*, 2015).

There is an important knowledge gap in retinal vasculopathy in FSHD, both in terms of patient management, i.e. diagnostics, counselling and therapeutic management, and in terms of research, such as molecular mechanisms (Fitzsimons, 2011) and biomarker potential of retinal changes (Longmuir *et al.*, 2010). Novel, non-invasive and high-resolution imaging techniques such as optical coherence tomography (OCT) and OCT angiography (OCTA) provide a detailed imaging of retinal structure and vessel perfusion in three dimensions and may provide complementary information on retinal pathology in FSHD. We applied these techniques to study the prevalence, appearance and natural history of retinal abnormalities in patients with genetically confirmed FSHD compared with a healthy control group.

Materials and methods

Participants

Participants were recruited from the patient database of the national FSHD referral centre (Radboud University Medical Centre, Nijmegen, The Netherlands). Patients clinically affected by FSHD with a genetically proven diagnosis were eligible for inclusion. Patients participated in an observational cohort study on multiple aspects of FSHD, which included ophthalmological examination.

An age-matched healthy control group was selected from the OCTA database of the Radboud University Medical Centre, Nijmegen and was analysed retrospectively. This study has been approved by the Medical Review Ethics Committee region Arnhem-Nijmegen (NL53213.091.15). Written informed consent was obtained from participants and also from parents/legal guardians if participants were under 18 years.

Clinical assessment

Patients underwent a complete ophthalmological examination including best corrected visual acuity, refraction measurement, intraocular pressure measurement, slit lamp examination and funduscopy by an experienced ophthalmologist. In addition, the muscle phenotype was assessed in patients with FSHD by manual muscle force testing (Vanhoutte *et al.*, 2012) and graded by the FSHD clinical score (Lamperti *et al.*, 2010) and the age-adjusted clinical severity scale (Ricci *et al.*, 1999; van Overveld *et al.*, 2005). A 2-year clinical and ophthalmological follow-up was executed in all patients under the age of 19 years as part of a larger natural history study.

Image acquisition and processing

Both the 45° colour fundus photographs of the posterior pole and the swept source OCT/A images were obtained by a combined fundus camera and OCTA device (DRI Triton™ OCT, Topcon Corporation, Tokyo, Japan).

Colour fundus photographs were qualitatively assessed by two independent graders (R.J.M.G. and V.S.), scoring vessel tortuosity, microaneurysms, vascular density and the presence of other vascular abnormalities. Vessel tortuosity describes an abnormal trajectory of the vessel with increased twists and turns. For the vessel tortuosity, a three-point grading scale (no–mild–severe tortuosity) was used. The graders were blinded for the patient/control characteristics. Discrepancies between graders were solved by open adjudication. For quantitative analysis, we used the Fiji software (version 1.51, freely available at <https://imagej.nih.gov/ij/download.html>; Schindelin *et al.*, 2012). We manually selected the four largest arteries in the funduscopy for arterial tortuosity index (TI) calculation by dividing the sum of actual branch lengths with the sum of straight lengths between branches (Lee *et al.*, 2017).

Fovea-centred 3 × 3 mm OCTA images were obtained and standardized following the previously described protocol (Schreur *et al.*, 2019). Qualitative assessment of the OCT B-scans (graders V.S. and T.T.) and OCTA scans (V.S. and R.J.M.G.) included structural abnormalities such as vascular tortuosity, microaneurysms, capillary non-perfusion, foveal avascular zone abnormalities and vascular density. Quantitative analysis of OCTA included vessel density and vessel tortuosity measurements. Vessel density was measured as an area percentage on both the complete 3 × 3 mm images and superior,

nasal, inferior and temporal circular quadrants separately (Fig. 1). The vessel tortuosity was assessed by quantification of the TI on the complete skeletonized images (Lee *et al.*, 2017) and calculated the arterial TI dividing the sum of actual branch lengths with the sum of straight lengths between branches (Lee *et al.*, 2017).

Statistical analysis

For comparison of the TI between patients and controls, the non-paired *t*-test was performed, and for the 2-year follow-up analysis, the paired *t*-test was performed. To assess the correlation between qualitative scoring and quantitative scoring of the tortuosity severity and between the tortuosity and the genetic defect and disease severity, linear regressions were used. Statistical analysis was performed using GraphPad Prism (version 5.00 for Windows, GraphPad Software, San Diego, CA, USA; www.graphpad.com).

Data availability

The data from this study cannot be made publicly available, as no patient approval has been obtained for sharing coded data. Output of statistical analyses will be made available upon reasonable request.

Results

Demographics

A total of 60 eyes of 33 patients were examined in this study. Twenty patients were female (57%), and the mean (SD; range) age was 35 years (21.0; 7–80). All patients were clinically affected with a mean (SD; range) muscle weakness of 7.8 points (5.2; 1–15) on the 15-point FSHD clinical score. Thirty-one patients had FSHD type 1 with a mean (SD; range) number of D4Z4 repeat units of 4.3 (1.9; 2–8), the other two patients had FSHD type 2 with an SMCHD1 pathogenic variant. The healthy control cohort consisted of 26 eyes of 24 participants (53% female). The mean (SD; range), age was 46 years (25; 11–67, paired *t*-test, *P* = 0.08). All but one patient with FSHD had a normal best corrected visual acuity and a normal intraocular pressure (Table 1). Twenty-seven patients had problems closing their eyes completely due to weakness of the orbicularis oculi; forced closure of the eyes was possible in 16 of these patients, whereas 11 patients kept an incomplete eyelid closure (lagophthalmus). Eight patients used eye drops (artificial tears) to treat dry eyes, and five patients had topical antibiotic treatment for eye infections in their medical history.

Colour fundus photographs

Qualitative assessment showed an increased tortuosity in retinal arteries in 25 of the 33 (76%) patients with

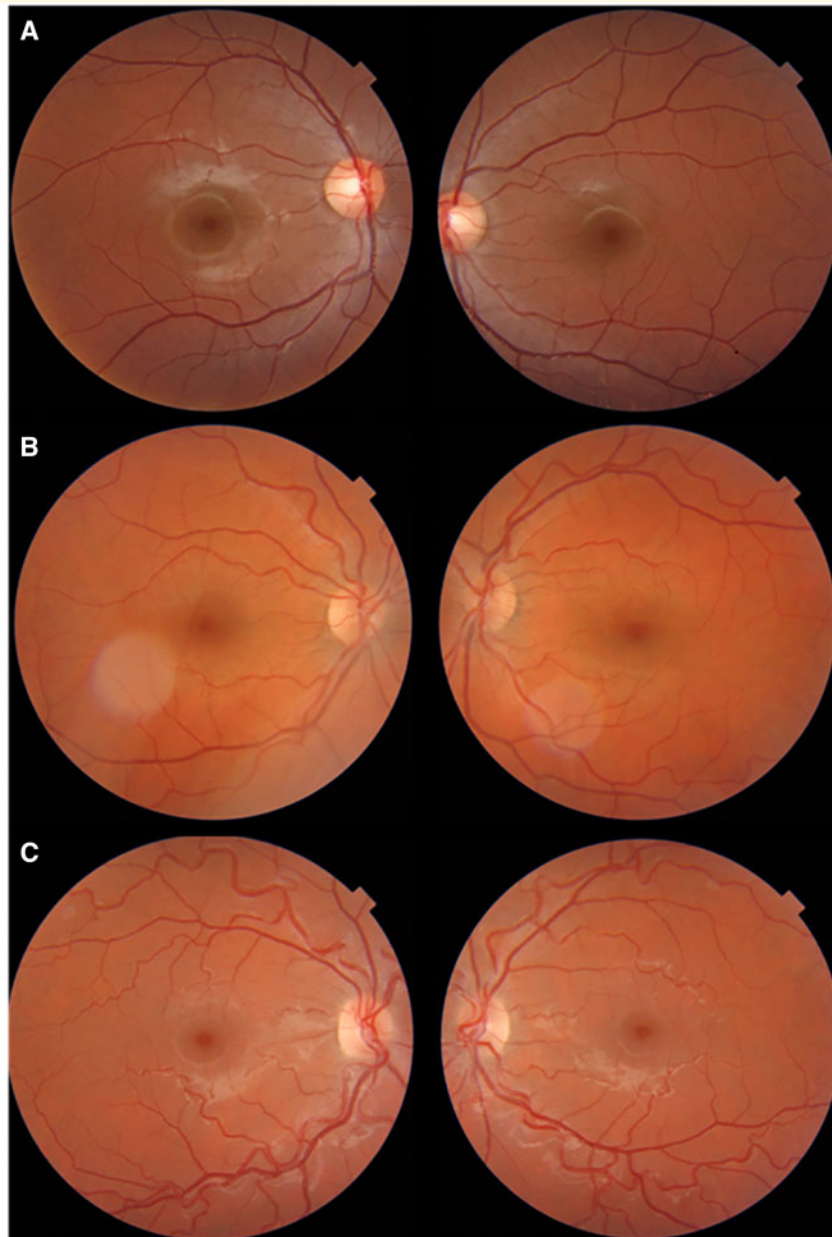


Figure 1 Tortuosity of the retinal arteries. Sample patients with (A) absent, (B) mild and (C) severe tortuosity of the retinal arteries.

Table 1 Demographics

	Patients with FSHD (33 participants, 60 eyes)	Healthy controls (26 participants, 28 eyes)
Female (%)	57	53
Age (years), mean (SD; range)	35 (21; 7–80)	46 (25; 11–67)
FSHD clinical score (0–15), mean (SD; range)	7.8 (5.2; 1–15)	NA
Visual acuity OD/OS	1/1	1/1
Number of D4Z4 units (FSHD1 only), mean (SD; range)	4.23 (1.93; 2–8)	NA

NA = not applicable; OD = oculus dexter, right eye; OS = oculus sinister, left eye.

FSHD (41 of the 60 eyes, 11 eyes with severe and 30 eyes with mild tortuosity, Fig. 1). Tortuous retinal arteries were not seen in any of the controls, and there was no tortuosity of the venous structures in patients or controls. Qualitative scoring of the fundus photographs revealed one retinal venous occlusion in one eye of one patient and no other abnormalities such as microaneurysms or an abnormal vascular density.

Quantitative assessment also showed that the arterial TI was higher in the patient group than in the control group (1.13 versus 1.25, $P < 0.0001$, Fig. 2). The qualitative scoring correlated with the quantitative scoring ($R^2 = 0.55$, $P < 0.0001$).

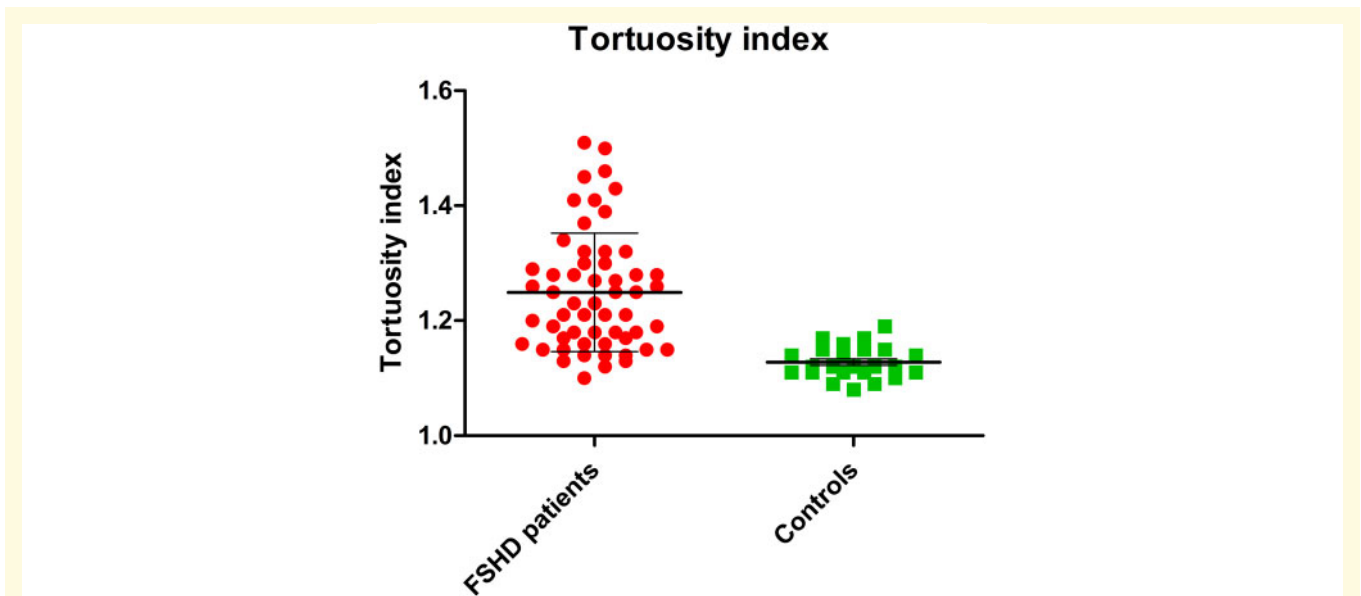


Figure 2 Tortuosity index compared with controls. Tortuosity index of patients versus controls showing an increased arterial tortuosity in patients with FSHD.

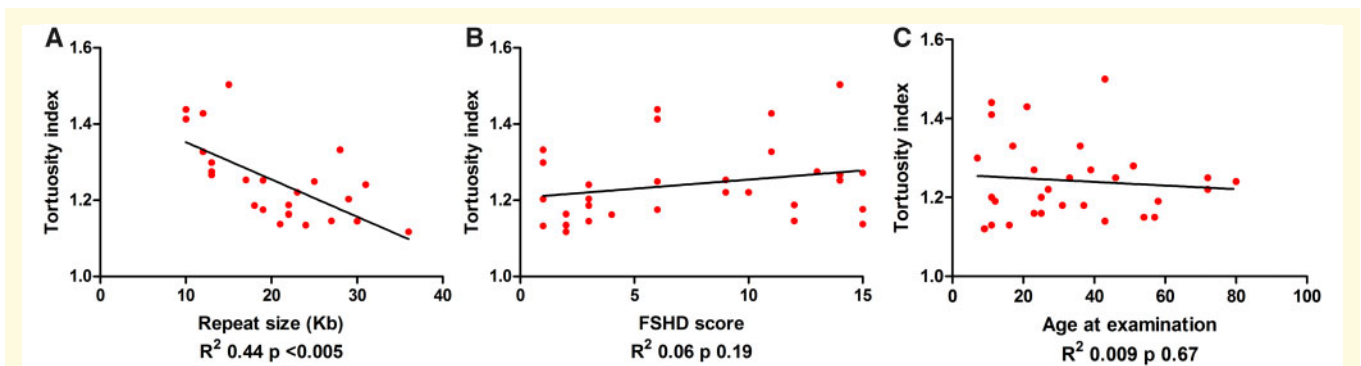


Figure 3 Tortuosity correlates with genetic severity. Regression analysis of tortuosity and (A) genetic severity as measured by the repeat size, (B) disease severity as measured by the FSHD clinical score and (C) age at examination.

We found a negative correlation between the severity of retinal tortuosity and the residual D4Z4 repeat array size ($R^2 = 0.44$, $P < 0.005$, Fig. 3), i.e. patients with the shortest D4Z4 repeat array lengths (2–3U) had severest tortuosity. We did not detect a correlation between the severity of retinal tortuosity and the severity of muscle weakness (FSHD clinical score, $R^2 = 0.06$, $P = 0.19$, Fig. 3) or a correlation between retinal tortuosity and patient's age. Severe retinal tortuosity was seen in young age (youngest patient was 8 years), and normal retinal vasculature was seen more frequently in adults. The regression analysis of these sub-studies is depicted graphically in Fig. 3.

Optical coherence tomography

We found abnormalities in 7 of the 33 patients with FSHD; focal retinal pigment epithelium defects were

seen in five eyes of the four patients, asymmetrical foveal hypoplasia was observed in six eyes of the three patients and intraretinal fluid accumulation with associated intraretinal hyperreflective dots was observed in both eyes of one patient (Fig. 4). In this patient, retinal changes were located in the outer nuclear layer on the temporal inferior side of the fovea, without showing any abnormalities on colour fundus photography. None of the patients experienced visual deterioration, and therefore, treatment was not indicated. All seven patients with posterior pole retinal abnormalities on OCT were severely affected patients with severe retinal tortuosity, an early onset (before the age of 5 years), a mean FSHD clinical score of 12.9 (range 11–15) and a mean number of 3.4 D4Z4 repeat array units (range 3–7 and compared with a mean of 4.2 repeat array units in the complete group). Two of these patients were under the age of 12 years.

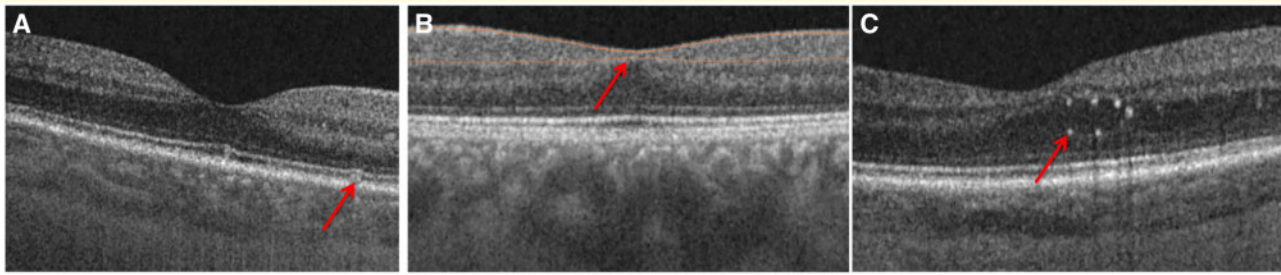


Figure 4 Retinal abnormalities on OCT scans. Types of retinal abnormalities detected on OCT scans of patients with FSHD. **(A)** Focal retinal pigment epithelium defect (44-year-old male; arrow), **(B)** foveal hypoplasia (17-year-old female) and **(C)** exudative abnormalities (72-year-old female, arrow).

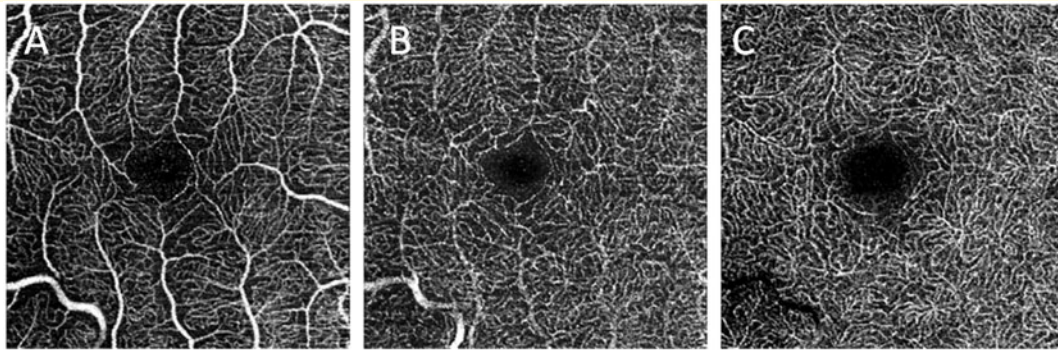


Figure 5 Retinal abnormalities on OCTA scans. Sample OCTA images of a patient with FSHD: **(A)** inner vessel layer; **(B)** intermediate vessel layer; and **(C)** outer vessel layer. Note the tortuosity of the largest retinal vessels in the inner layer.

Optical coherence tomography angiography

In 26 eyes of the 28 healthy controls and 62 eyes of the 33 patients with FSHD, OCTA was performed. In 11 eyes (seven patients and four controls), image quality was insufficient for analysis, mostly due to the inability of the very young patients for stable fixation during the examination. Mild vascular tortuosity of the largest vessels was seen in the superficial capillary plexus of six eyes of the patients with FSHD (Fig. 5). Six eyes of three patients showed foveal hypoplasia on structural OCT, with an exceptionally small foveal avascular zone on OCTA in all three vascular plexuses. One of those patients showed capillary non-perfusion.

Quantitative analysis of the vessel density of the superficial capillary plexus, the intermediate capillary plexus and the deep capillary plexus, did not show significant differences compared with healthy controls (Fig. 6), independent of whether the macular area was analysed as a whole or quadrant wise. Also, vessel tortuosity did not differ compared with healthy controls (Fig. 6).

Follow-up assessment

Six patients (aged 6–18 years) had ophthalmological follow-up examination after a 2-year interval. Qualitative

examination of the fundus photographs, OCT/A images did not show any changes over 2 years (Fig. 7). Quantitative analysis of the arterial tortuosity did not show a significant difference in TI (TI 1.37 at baseline and 1.34 at follow-up; mean of differences 0.03, $P = 0.10$).

Discussion

In this study, we refined the ophthalmological phenotype of FSHD types 1 and 2 by applying modern ophthalmological imaging methods. Our main findings were as follows: (i) posterior pole retinal abnormalities were frequent but almost always subclinical in patients with FSHD; (ii) foveal abnormalities were present in 7 of the 33 patients; (iii) retinal tortuosity is restricted to the retinal arterioles and inversely correlated with residual D4Z4 repeat array size and (iv) retinal abnormalities appeared stable over a 2-year period.

The prevalence of retinal abnormalities in our study was high and in concordance with historical prevalence estimations (49–75%; Fitzsimons *et al.*, 1987; Padberg *et al.*, 1995). None of the retinal changes in our current study caused patient complaints or vision loss. Retinal arteriole tortuosity was seen in the majority of fundus

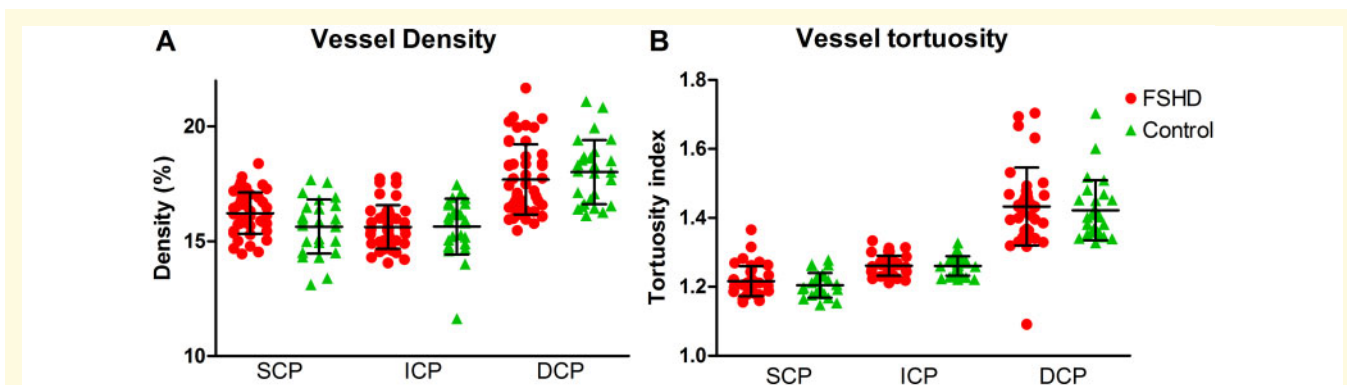


Figure 6 Macular vessel density and tortuosity compared to controls. Comparison of the macular vessel density (**A**) and vessel tortuosity (**B**) between patients with FSHD and healthy controls. None of the layers showed a significantly different density or tortuosity (unpaired *t*-tests: 1.21 versus 1.20, $P = 0.25$, for inner vessel layer; 1.26 versus 1.26, $P = 0.87$, for intermediate vessel layer; 1.43 versus 1.42, $P = 0.68$, for outer vessel layer). The variation of vessel tortuosity was broader in patients with FSHD in the DCP layer. DCP = deep capillary plexus; SCP = superficial capillary plexus.

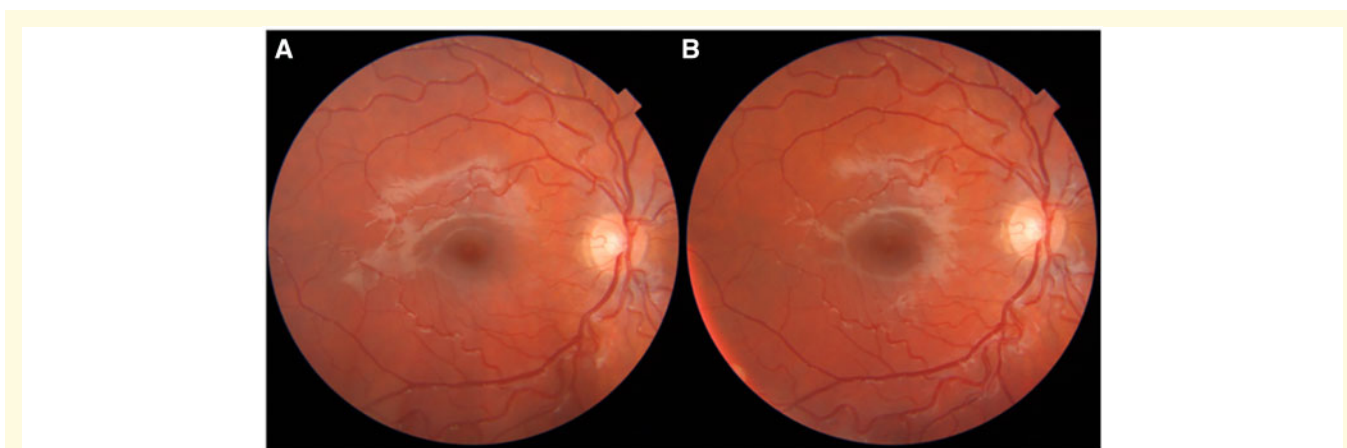


Figure 7 Follow-up of arterial tortuosity. A male patient at **A** baseline (age 11 years) and **B** after 2-year follow-up (age 13 years). Arterial tortuosity is seen, which is unchanged after the follow-up period.

photographs, and foveal abnormalities such as retinal pigment epithelium alterations, foveal hypoplasia and exudative abnormalities were seen with OCT in a minority of patients. Thus, the new imaging modalities provided a more detailed insight in the structural and functional retina alterations and refined the ophthalmological phenotype of FSHD.

With OCTA, we observed tortuosity only in the large arterioles of the retinal posterior pole, whereas the venous and capillary vascular structures remained unchanged. This is in contrast with other diseases causing tortuosity such as genuine Coats' disease or diabetic retinopathy, which primarily affects the capillary system (Lee *et al.*, 2017). In contrast to retinal arterioles, the capillaries do not contain smooth muscle in the vessel wall. It is possible, therefore, that the tortuosity in FSHD may be related to a defect of the muscular vessel wall, consistent with the earlier observation of transcriptional

deregulation of genes expressed in endothelial or smooth muscle cells (Osborne *et al.*, 2007).

In our study, we found a correlation between the severity of tortuosity and the residual D4Z4 repeat array size. This finding might well provide clinical evidence for the suspected genetic linkage between the retina and FSHD (Osborne *et al.*, 2007). In FSHD, epigenetic dysregulation of D4Z4 leads to disease pathology and various FSHD-related pathways, such as the Wnt-Norrin-PAX6 (Fitzsimons, 2011; Block *et al.*, 2013; Gan *et al.*, 2014) and PGC1 α /ERR α (Banerji *et al.*, 2018), are linked with (retinal) vascular functions (Osborne *et al.*, 2007; Wuebbles *et al.*, 2009; Fitzsimons, 2011). We further hypothesize involvement of the CXCR4-SDF1 axis (Geng *et al.*, 2012; Dmitriev *et al.*, 2013), which has a role in endothelial tip cell morphology and vascular branching (Strasser *et al.*, 2010). The CXCR4-SDF1 axis is controlled by DUX4, which is located in the D4Z4 repeat

array and becomes epigenetically dysregulated in FSHD (Lemmers *et al.*, 2010), and defective CXCR4 signalling might result in retinal tortuosity. Further evidence for the developmental origin of retinal tortuosity in FSHD is that severe tortuosity is seen at an early age and the association with the D4Z4 repeat array size, which has recently been shown for facial weakness as well (Mul *et al.*, 2018).

It is of interest that retinal vascular developmental disorders have been shown to hinder the normal maturation of the fovea centralis of the retina (Springer and Hendrickson, 2004, 2005; Provis and Hendrickson, 2008), leading to foveal hypoplasia. If no foveal avascular zone is observed, foveal function and, thus, visual acuity may be reduced (Pakzad-Vaezi *et al.*, 2017). However, in our patients, foveal hypoplasia was associated with an foveal avascular zone, albeit reduced, which may prevent foveal dysfunction (Pakzad-Vaezi *et al.*, 2017). According to our study results, foveal hypoplasia with preserved visual function may thus be a ocular property of FSHD in patients with abnormalities of large retinal vessels. Intraretinal fluid may also be a consequence of abnormal retinal vessel formation in FSHD.

Non-invasive retinal imaging is emerging as biomarker strategy in neurodegenerative diseases. In Alzheimer's disease, a decreased vessel density is observed, and in multiple sclerosis, a decreased retinal blood flow is seen (Wang *et al.*, 2018). In FSHD, we did not observe changes in retinal tortuosity over time or a correlation with the severity of muscle weakness in asymptomatic patients. Therefore, our findings provide no further support for retinal tortuosity as a general biomarker for progression in FSHD, which is in contrast to the earlier work (Longmuir *et al.*, 2010). By contrast, symptomatic patients with Coats-like syndrome or posterior pole abnormalities may progress over time.

A limitation of this study is the absence of detailed images of the retinal periphery and fluorescence angiography. Therefore, the presence of these abnormalities cannot be excluded as they are most frequently located in the retinal periphery in FSHD (Fitzsimons *et al.*, 1987). It is important to mention that, in our cohort, we neither found symptomatic patients nor observed advanced stages of retinal disease such as microaneurysms, oedema and exudates in the central part of the retina.

Providing adequate clinical management of retinal complications in FSHD is challenging. Which subgroup of patients requiring monitoring and which techniques are optimal for monitoring are unclear. On the one hand, Coats-like syndrome tends to affect patients with FSHD with the shortest D4Z4 repeat array size (Statland *et al.*, 2013); on the other hand, patients with FSHD with longer repeat lengths can certainly present with vision loss even before muscular symptoms (Vance *et al.*, 2011; Sgobbi de Souza *et al.*, 2016). Severe retinal tortuosity was seen from an early age, and screening should be commenced preferably soon after diagnosis, with

continued yearly screening only if indicated. Today, no predictive factors for the development of Coats-like syndrome in FSHD are known. We, therefore, would recommend future studies to focus on the natural history of retinal abnormalities with longitudinal ultrawidefield OCTA imaging, to investigate the retinal periphery and to improve the detection of patients at risk of vision loss.

Funding

This study was financially supported by research grants from the charitable foundation Prinses Beatrix Spierfonds and Spieren voor Spieren, W.OR14.22.

Competing interests

R.J.M.G., V.S., C.R.V.K. and T.T. report no disclosures relevant to the article. S.M.v.d.M. is a consultant for Fulcrum Therapeutics and receives grants from the NIH National Institute of Neurologic Disorders and Stroke (P01NS069539), the NIH National Institute of Arthritis and Musculoskeletal and Skin Diseases (R01AR066248), the Prinses Beatrix Spierfonds, the FSH Society, Stichting Spieren voor Spieren and Friends of FSH Research. G.W.P. is a consultant for Atyr-Pharma and Facio Therapies. C.E.E. receives grants from Prinses Beatrix Spierfonds. B.G.M.v.E. receives grants from Prinses Beatrix Spierfonds, Association Francaise contre les Myopathies, Stichting Spieren voor Spieren, FSHD Stichting and NWO Dutch Organization for scientific research.

References

- Banerji CRS, Panamarova M, Pruller J, Figeac N, Hebaishi H, Fidanis E, et al. Dynamic transcriptomic analysis reveals suppression of PGC1alpha/ERRalpha drives perturbed myogenesis in facioscapulohumeral muscular dystrophy. *Hum Mol Genet* 2018; 28: 1244–59.
- Bass SJ, Sherman J, Giovinazzo V. Bilateral Coats' response in a female patient leads to diagnosis of facioscapulohumeral muscular dystrophy. *Optometry* 2011; 82: 72–6.
- Block GJ, Narayanan D, Amell AM, Petek LM, Davidson KC, Bird TD, et al. Wnt/beta-catenin signaling suppresses DUX4 expression and prevents apoptosis of FSHD muscle cells. *Hum Mol Genet* 2013; 22: 4661–72.
- Chen TH, Lai YH, Lee PL, Hsu JH, Goto K, Hayashi YK, et al. Infantile facioscapulohumeral muscular dystrophy revisited: expansion of clinical phenotypes in patients with a very short EcoRI fragment. *Neuromuscul Disord* 2013; 23: 298–05.
- Dmitriev P, Stankevicius L, Anseau E, Petrov A, Barat A, Dessen P, et al. Defective regulation of miRNAs target genes in myoblasts from facioscapulohumeral dystrophy patients. *J Biol Chem* 2013; 288: 34989–5002.
- Dorobek M, van der Maarel SM, Lemmers R, Ryniewicz B, Kabzinska D, Frants RR, et al. Early-onset facioscapulohumeral muscular dystrophy type 1 with some atypical features. *J Child Neurol* 2015; 30: 580–7.

- Fitzsimons RB. Retinal vascular disease and the pathogenesis of facioscapulohumeral muscular dystrophy. A signalling message from Wnt? *Neuromuscul Disord* 2011; 21: 263–71.
- Fitzsimons RB, Gurwin EB, Bird AC. Retinal vascular abnormalities in facioscapulohumeral muscular dystrophy. A general association with genetic and therapeutic implications. *Brain* 1987; 110: 631–48.
- Gan Q, Lee A, Suzuki R, Yamagami T, Stokes A, Nguyen BC, et al. Pax6 mediates ss-catenin signaling for self-renewal and neurogenesis by neocortical radial glial stem cells. *Stem Cells* 2014; 32: 45–58.
- Ganesh A, Kaliki S, Shields CL. Coats-like retinopathy in an infant with preclinical facioscapulohumeral dystrophy. *J AAPOS* 2012; 16: 204–6.
- Geng LN, Yao Z, Snider L, Fong AP, Cech JN, Young JM, et al. DUX4 activates germline genes, retroelements, and immune mediators: implications for facioscapulohumeral dystrophy. *Dev Cell* 2012; 22: 38–51.
- Lamperti C, Fabbri G, Vercelli L, D'Amico R, Frusciante R, Bonifazi E, et al. A standardized clinical evaluation of patients affected by facioscapulohumeral muscular dystrophy: the FSHD clinical score. *Muscle Nerve* 2010; 42: 213–7.
- Lee H, Lee M, Chung H, Kim HC. Quantification of retinal vessel tortuosity in diabetic retinopathy using optical coherence tomography angiography. *Retina* 2017; 38: 976–85.
- Lemmers RJ, van der Vliet PJ, Klooster R, Sacconi S, Camano P, Dauwerse JG, et al. A unifying genetic model for facioscapulohumeral muscular dystrophy. *Science* 2010; 329: 1650–3.
- Longmuir SQ, Mathews KD, Longmuir RA, Joshi V, Olson RJ, Abramoff MD. Retinal arterial but not venous tortuosity correlates with facioscapulohumeral muscular dystrophy severity. *J AAPOS* 2010; 14: 240–3.
- Matos R, Beato J, Silva M, Silva S, Brandão E, Falcão-Reis F, et al. Combined treatment with intravitreal bevacizumab and laser photocoagulation for exudative maculopathy in facioscapulohumeral muscular dystrophy. *Ophthalmic Genet* 2017; 38: 490–3.
- Mul K, Lassche S, Voermans NC, Padberg GW, Horlings CG, van Engelen BG. What's in a name? The clinical features of facioscapulohumeral muscular dystrophy. *Pract Neurol* 2016; 16: 201.
- Mul K, Voermans NC, Lemmers R, Jonker MA, van der Vliet PJ, Padberg GW, et al. Phenotype-genotype relations in facioscapulohumeral muscular dystrophy type 1. *Clin Genet* 2018; 94: 521–7.
- Nikolic A, Ricci G, Sera F, Bucci E, Govi M, Mele F, et al. Clinical expression of facioscapulohumeral muscular dystrophy in carriers of 1-3 D4Z4 reduced alleles: experience of the FSHD Italian National Registry. *BMJ Open* 2016; 6: e007798.
- Osborne RJ, Welle S, Venance SL, Thornton CA, Tawil R. Expression profile of FSHD supports a link between retinal vasculopathy and muscular dystrophy. *Neurology* 2007; 68: 569–77.
- Padberg GW, Brouwer OF, de Keizer RJ, Dijkman G, Wijmenga C, Grote JJ, et al. On the significance of retinal vascular disease and hearing loss in facioscapulohumeral muscular dystrophy. *Muscle Nerve Suppl* 1995; S73–80.
- Pakzad-Vaezi K, Keane PA, Cardoso JN, Egan C, Tufail A. Optical coherence tomography angiography of foveal hypoplasia. *Br J Ophthalmol* 2017; 101: 985–8.
- Provis JM, Hendrickson AE. The foveal avascular region of developing human retina. *Arch Ophthalmol* 2008; 126: 507–11.
- Ramasubramanian A, Shields CL. Bevacizumab for Coats' disease with exudative retinal detachment and risk of vitreoretinal traction. *Br J Ophthalmol* 2012; 96: 356–9.
- Ricci E, Galluzzi G, Deidda G, Caccuri S, Colantoni L, Merico B, et al. Progress in the molecular diagnosis of facioscapulohumeral muscular dystrophy and correlation between the number of KpnI repeats at the 4q35 locus and clinical phenotype. *Ann Neurol* 1999; 45: 751–7.
- Schindelin J, Arganda-Carreras I, Frise E, Kaynig V, Longair M, Pietzsch T, et al. Fiji: an open-source platform for biological-image analysis. *Nat Methods* 2012; 9: 676–82.
- Schreur V, Domanian A, Liefers B, Venhuizen FG, Klevering BJ, Hoyng CB, et al. Morphological and topographical appearance of microaneurysms on optical coherence tomography angiography. *Br J Ophthalmol* 2019; 103: 630–5.
- Sgobbi de Souza PV, Vieira de Rezende Pinto WB, de Rezende Batistella GN, Dias RB, Bulle Oliveira AS. Teaching NeuroImages: Coats disease revealing facioscapulohumeral muscular dystrophy. *Neurology* 2016; 87: e39.
- Shields JA, Shields CL. Review: Coats disease: the 2001 LuEsther T. Mertz lecture. *Retina* 2002; 22: 80–91.
- Shields JA, Shields CL, Honavar SG, Demirci H, Cater J. Classification and management of Coats disease: the 2000 Proctor Lecture. *Am J Ophthalmol* 2001; 131: 572–83.
- Springer AD, Hendrickson AE. Development of the primate area of high acuity. 2. Quantitative morphological changes associated with retinal and pars plana growth. *Vis Neurosci* 2004; 21: 775–90.
- Springer AD, Hendrickson AE. Development of the primate area of high acuity, 3: temporal relationships between pit formation, retinal elongation and cone packing. *Vis Neurosci* 2005; 22: 171–85.
- Statland JM, Sacconi S, Farmakidis C, Donlin-Smith CM, Chung M, Tawil R. Coats syndrome in facioscapulohumeral dystrophy type 1: frequency and D4Z4 contraction size. *Neurology* 2013; 80: 1247–50.
- Strasser GA, Kaminker JS, Tessier-Lavigne M. Microarray analysis of retinal endothelial tip cells identifies CXCR4 as a mediator of tip cell morphology and branching. *Blood* 2010; 115: 5102–10.
- Tawil R, Kissel JT, Heatwole C, Pandya S, Gronseth G, Benatar M. Evidence-based guideline summary: evaluation, diagnosis, and management of facioscapulohumeral muscular dystrophy: Report of the Guideline Development, Dissemination, and Implementation Subcommittee of the American Academy of Neurology and the Practice Issues Review Panel of the American Association of Neuromuscular & Electrodiagnostic Medicine. *Neurology* 2015; 85: 357–64.
- Trevisan CP, Pastorello E, Tomelleri G, Vercelli L, Bruno C, Scapolan S, et al. Facioscapulohumeral muscular dystrophy: hearing loss and other atypical features of patients with large 4q35 deletions. *Eur J Neurol* 2008; 15: 1353–8.
- van Overveld PG, Enthoven L, Ricci E, Rossi M, Felicetti L, Jeanpierre M, et al. Variable hypomethylation of D4Z4 in facioscapulohumeral muscular dystrophy. *Ann Neurol* 2005; 58: 569–76.
- Vance SK, Wald KJ, Sherman J, Freund KB. Subclinical facioscapulohumeral muscular dystrophy masquerading as bilateral Coats disease in a woman. *Arch Ophthalmol* 2011; 129: 805–9.
- Vanhoutte EK, Faber CG, van Nes SI, Jacobs BC, van Doorn PA, van Koningsveld R, et al. Modifying the Medical Research Council grading system through Rasch analyses. *Brain* 2012; 135: 1639–49.
- Wang L, Murphy O, Caldito NG, Calabresi PA, Saidha S. Emerging applications of optical coherence tomography angiography (OCTA) in neurological research. *Eye Vis (Lond)* 2018; 5: 11.
- Wuebbles RD, Hanel ML, Jones PL. FSHD region gene 1 (FRG1) is crucial for angiogenesis linking FRG1 to facioscapulohumeral muscular dystrophy-associated vasculopathy. *Dis Model Mech* 2009; 2: 267–74.