

## PDF hosted at the Radboud Repository of the Radboud University Nijmegen

The following full text is a publisher's version.

For additional information about this publication click this link.

<http://hdl.handle.net/2066/21446>

Please be advised that this information was generated on 2020-10-29 and may be subject to change.

# Urokinase Therapy in Neonates with Catheter Related Central Venous Thrombosis

M. L. G. Wever, K. D. Liem, W. B. Geven, R. B. Tanke

From the Department of Pediatrics, University Hospital Nijmegen, The Netherlands

## Summary

The results of fibrinolytic therapy with urokinase were evaluated in 26 neonates with catheter related central venous thrombosis. Complete thrombolysis could be achieved in 13 patients (50%), partial thrombolysis in 3 patients (12%). No effect was seen in 10 patients (38%). Therapy success was influenced by age, size and location of the thrombus. Coincidence of infection occurred in 16 patients (62%). Mild hemorrhagic complications were seen in 2 patients (8%), no other significant side effects were observed. Nine patients with residual thrombosis were treated with oral anticoagulants following urokinase resulting in resolution of the thrombus in 6 patients within 3 months (67%). The incidence of asymptomatic recurrent thrombosis was high (28%). Urokinase might be an effective and safe treatment for central venous thrombosis in neonates. Prophylactic antibiotic therapy during the infusion of urokinase and long-term treatment with oral anticoagulants after thrombolysis are advisable. Early detection of thrombosis might enhance the success rate of fibrinolytic therapy. Therefore, we strongly recommend routine echocardiographic screening of central venous catheters.

## Introduction

The use of central venous catheters to optimize nutrition and monitoring of low birthweight and critically ill newborns has become common practice in neonatal intensive care units. However, these catheters are not without potential hazards. Sepsis and thrombosis are known major complications (1-4). Central venous thrombosis can be associated with significant morbidity and mortality. Early detection and treatment is crucial.

There is no consensus in the literature about the treatment of choice for neonates with central venous thrombosis. Immediate removal of the catheter, once the diagnosis of central venous thrombosis is made, has been recommended (5). However, the risk for pulmonary embolization due to mobilization of the thrombus is imaginable. Surgical thrombectomy is technically difficult and poses a considerable life threatening risk to the severely ill infant (6-8). Heparin is a prophylactic drug and could be used in patients with mild thrombosis to prevent further thrombus extension. Nevertheless, one should not rely exclusively on the endogenous fibrinolytic capacity of the neonate, but should attempt to lyse a major central venous thrombus with thrombolytic agents (9).

In the past decade thrombolytic drugs have gained widespread recognition in the treatment of myocardial infarction, pulmonary embolism, deep venous and arterial thrombosis (10, 11). Although used extensively in the adult, there is sparse information on their effectiveness in the newborn (6). There have been no large case-series or controlled trials of infants treated with fibrinolytic agents for catheter related thrombosis. Eight case reports describe the use of urokinase in neonates, using different dosages and therapy durations (12-19). These initial successful reports regarding thrombolytic therapy in neonates encouraged us to apply this therapy to our patients. In this report, we present our experience of 26 infants treated with urokinase infusion for catheter related central venous thrombosis.

## Patients and Methods

Between October 1988 and September 1992, at our neonatal intensive care unit, central venous catheters were inserted in 434 infants. All patients with central venous catheters were traced by analysis of our computerized registration. The catheters used were either polyvinylchloride umbilical catheters (Sherwood®, Argyle), hydrophilic polyurethane catheters (Hydrocath® or Umbilicath®, Viggo) or silastic catheters (Broviac®, Bard). Venous access was achieved by means of umbilical vein catheterization in 216 patients (50%). In the remaining 218 infants (50%) catheters were placed either by means of percutaneous insertion via peripheral veins (basilic vein, greater saphenous vein, cephalic vein) or via the subclavian vein using the Seldinger method on the ward (20), or through cutdown of the jugular vein in the operating room. Right atrial position of the catheter tip was confirmed by chest X-ray. Heparin was infused at a continuous rate of 2 U/h through the catheters. A continuous minimum flow of 2 ml/h of dextrose solution was maintained through the catheters at all times. The central venous catheters were not used for infusion of packed red blood cells nor to obtain blood samples, except blood cultures in case of clinical suspicion of sepsis. Sepsis was suspected if two or more of the following clinical signs were present: leucopenia  $<5.0 \times 10^9/l$ , C-reactive protein  $>20$  mg/l, deterioration of respiratory and/or circulatory functions, temperature instability. Infection was defined as a positive blood culture drawn through the central venous catheter and/or a positive culture of the tip of the catheter after removal. Sepsis was defined as positive cultures with clinical signs of sepsis.

Since September 1989 echo Doppler cardiography has been performed as routine screening in all patients with central venous catheters before removal of the catheter or sooner in case of symptoms of thrombosis. Before this data echo Doppler cardiography was only performed on indication. A thrombus was defined as an echodense structure larger than 2 mm in the heart or in the great vessels. Special attention was paid to the superior and inferior vena cava, the hepatic vein and to malposition of the catheter in the left atrium. Length and diameter of the thrombus were measured in mm, thrombus mass was calculated in  $mm^3$  ( $\pi r^2 l$ , whereas  $r$  = radius and  $l$  = length of the thrombus). Echo Doppler cardiography led to the diagnosis in 23 patients (Fig. 1). Some peripheral veins (subclavian vein, hepatic vein) are easier visualized by catheter phlebography, which was used in 3 patients to confirm the diagnosis.

Correspondence to: Dr. M. L. G. Wever, Department of Pediatrics, University Hospital Nijmegen, P. O. Box 9101, N-6500 HB Nijmegen, The Netherlands - FAX Number: +31 80 61 64 28

All 26 patients (14 girls and 12 boys) with catheter related central venous thrombosis were treated with urokinase. The records, echo Doppler cardiography reports and laboratory values of these patients were reviewed. None of the patients had a platelet count below  $50 \times 10^9/l$  or a history of intracranial hemorrhage (21).

Immediately after establishing the diagnosis, blood samples were taken for determination of thrombin time, fibrinogen and plasminogen as a baseline before urokinase infusion. In an attempt to reach an effective local thrombolysis the catheter was left in place and used for urokinase administration. Urokinase was given as a bolus of 4400 IU per kilogram of body weight over 10 minutes, followed by a continuous initial infusion of 4400 IU per kilogram per hour (6, 10). No other antithrombotic agents were used concurrent with urokinase. The prophylactic infusion of heparin 2 U/h was interrupted during urokinase therapy. After urokinase administration, thrombin time and fibrinogen were measured at intervals of 4 h during the first 12 h and thereafter once every 12 h if necessary. In order to achieve a safe fibrinolytic state the urokinase infusion rate was adjusted until the thrombin time was prolonged to 2–3 times normal control values (50–75 s) (10). Whenever the fibrinogen level dropped below 1000 mg/l (6), fresh frozen plasma was administered in a dose of 10 ml per kilogram of body weight while thrombolytic therapy was continued. Careful clinical observation, monitoring of vital parameters and cerebral ultrasound were performed to detect hemorrhage. If any signs of bleeding occurred urokinase was stopped instantly. After three days of treatment echocardiographic assessment was repeated to evaluate therapy success. If necessary, remaining thrombus mass was calculated. A complete resolution of the thrombus was considered successful thrombolysis. In cases of partial thrombus reduction therapy was continued for another 2 to 3 days. If the clot resolved completely or if the clot still persisted despite extended therapy the urokinase infusion was terminated and the catheter was removed. After removal the tip of the catheter was cut off in a sterile manner and cultured.

Immediately following urokinase therapy oral anticoagulants were started in patients with residual thrombosis, in order to prevent thrombus extension and possibly enhance further resolution of the thrombus. In patients without residual thrombosis oral anticoagulants were only prescribed if the thrombus had been echographically adherent to the atrium or vessel wall, in which case there is an increased risk of damage to the endothelium and subsequent recurrent thrombosis. Fenprocoumon was used in the period 1988–1990, in a dose of 200–300  $\mu\text{g}/\text{kg}$ . Since 1991, we used warfarin in an initial dose of 200 to 400  $\mu\text{g}/\text{kg}$ , followed the next day by a maintenance dose of 50–200  $\mu\text{g}/\text{kg}$  once a day. The dose was adjusted until thrombotest values were reached between 2.5–3.3 INR. Treatment with oral anticoagulants was supported by low dose urokinase (100–400 U/kg per hour) to ensure vessel patency until adequate thrombotest values were reached. Duration of treatment with oral anticoagulants was 3 months, after which period follow-up echo Doppler cardiography was performed.

For all data, means and standard deviations were calculated. Statistical analysis was performed where necessary using the Chi-square test, Wilcoxon test or Student-t-test. Results were considered to be significant when  $p < 0.05$ .

## Results

Characteristics of 26 neonates with central venous thrombosis are presented in Table 1. The remaining 408 patients without central venous thrombosis had a mean birth weight of  $1988 \pm 1041$  grams and a mean gestational age of  $33.5 \pm 5.0$  weeks. Both birth weight and gestational age were significantly higher in the group with thrombosis ( $p < 0.05$  and  $p < 0.02$ ).

Among the 26 patients with catheter related central venous thrombosis prematurity ( $n = 8$ ) and birth asphyxia ( $n = 7$ ) were the main reasons for admission to our department. Less frequent diagnoses were congenital diaphragmatic hernia ( $n = 3$ ), meconium aspiration syndrome ( $n = 2$ ), sepsis ( $n = 2$ ), gastro-intestinal surgery ( $n = 2$ ), pneumothorax ( $n = 1$ ) and chylothorax ( $n = 1$ ). All patients were critically ill on admission, 24 required artificial ventilation. All patients received total

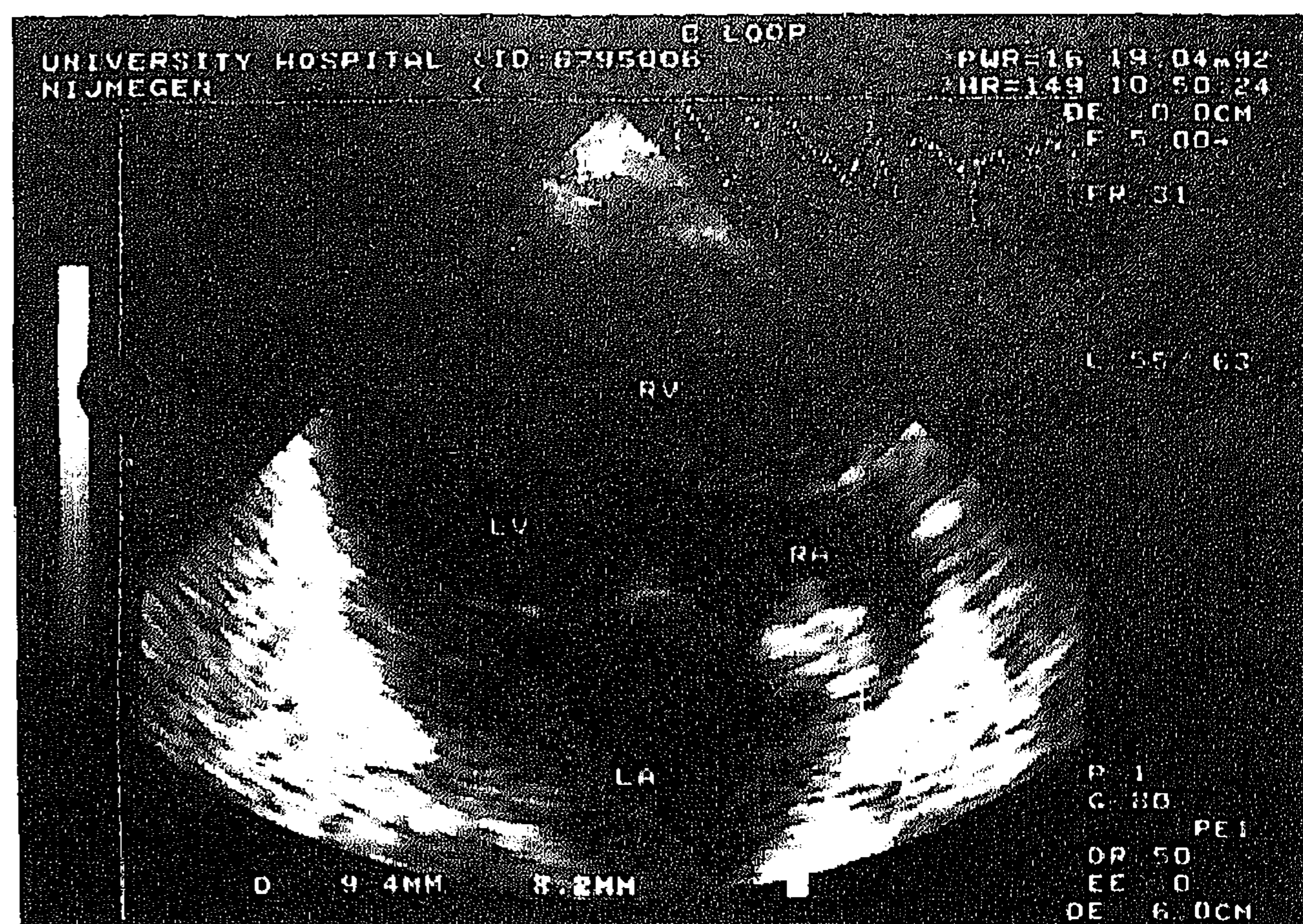


Fig. 1 Two-dimensional echocardiogram showing a large thrombotic mass in the right atrium (RA). LA: left atrium, RV: right ventricle, LV: left ventricle

parenteral nutrition and multiple medications through their central venous catheters. The osmolarity of the infused solutions ranged from 285 to 750 mOsm/l.

Half of the central venous catheters were inserted within the first two days of life. Umbilical vein catheterization was performed in 14 patients. The percutaneous method via peripheral veins was applied in 4 patients. In 5 patients venous access was achieved by means of percutaneous catheterization of the subclavian vein and in 3 patients by means of cutdown of the jugular vein. Catheters used were polyvinylchloride umbilical catheters 5 French ( $n = 5$ ), hydrophilic polyurethane umbilical catheters 5 French ( $n = 7$ ), single lumen hydrophilic percutaneous catheters 22 or 20 Gauge ( $n = 7$ ), double lumen hydrophilic polyurethane percutaneous catheters 18 Gauge ( $n = 3$ ), and silastic catheters 4.2 French ( $n = 3$ ). In one patient the type of the catheter was unknown.

At the time of diagnosis 15 patients (58%) had clinical symptoms suspicious for central venous thrombosis, particularly sepsis ( $n = 14$ ), sometimes in combination with superior or inferior vena cava syndrome ( $n = 8$ ) and/or chylothorax ( $n = 1$ ). The remaining 11 patients (42%) had no clinical symptoms of thrombosis at the time of diagnosis, except signs of catheter malfunction such as partial or complete occlusion ( $n = 2$ ).

Table 1 Patient characteristics ( $n = 26$ )

	Mean	SD	Range
<b>General</b>			
Gestational age (weeks)	36.1	4.8	26.9–42.0
Birthweight (grams)	2603	1350	495–4580
Apgar score 5'	6.8	2.4	3.0–10.0
<b>Thrombus</b>			
Age at diagnosis (days)	19	15	5–56
Indwelling time catheter (days)	13	9	4–50
Thrombus mass ( $\text{mm}^3$ )	263	352	4–1649
<b>Coagulation studies</b>			
Thrombin time (s)	38	6	28–54
Fibrinogen (ml/l)	3470	1248	1410–5789
Plasminogen (%)	66	15	44–91
<b>Urokinase</b>			
Max. maintenance ( $\text{U}/\text{kg} \times \text{h}$ )	14345	9105	4400–35700
Therapy duration (h)	92	51	21–262

Fig. 2A

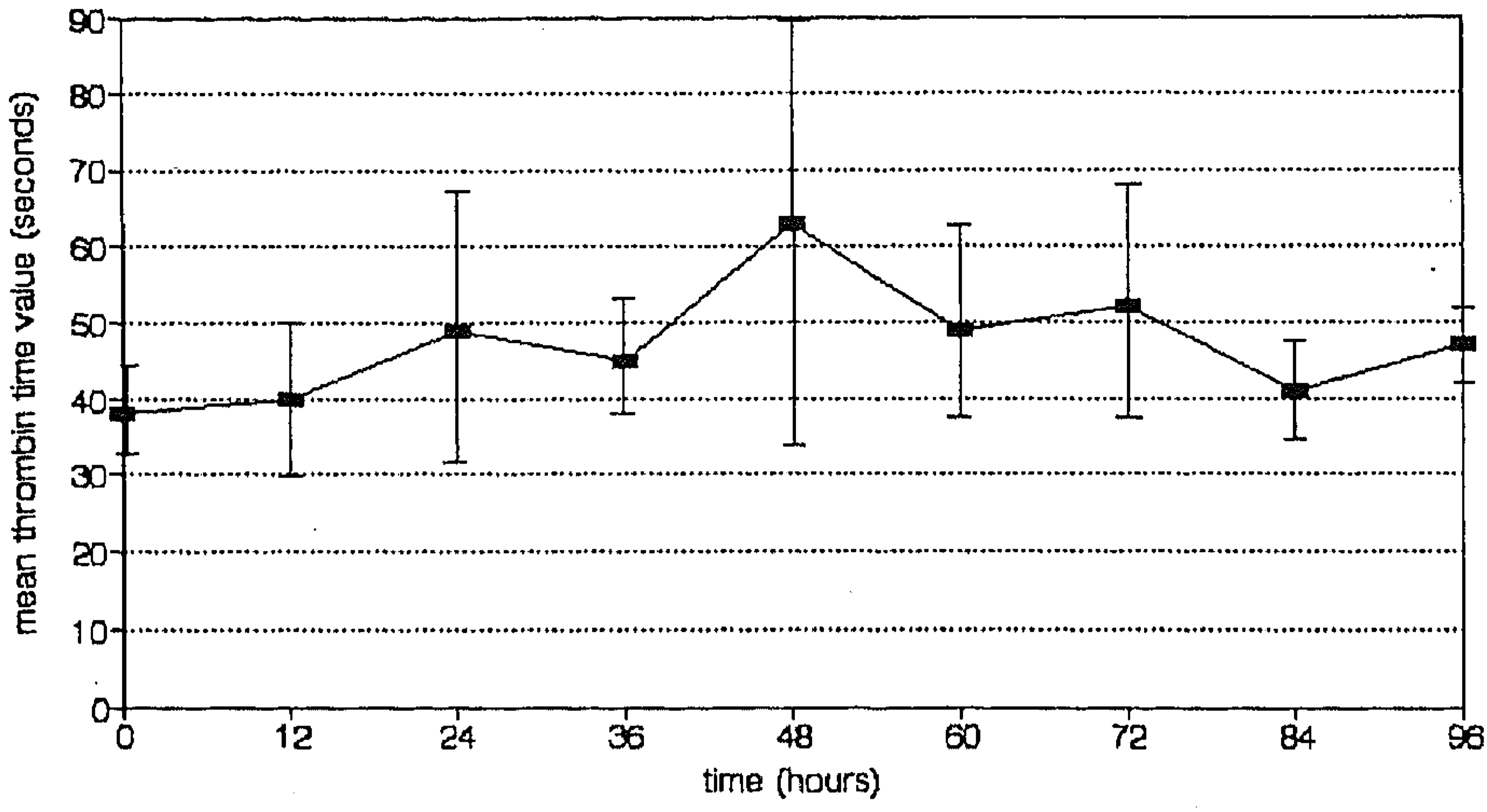


Fig. 2B

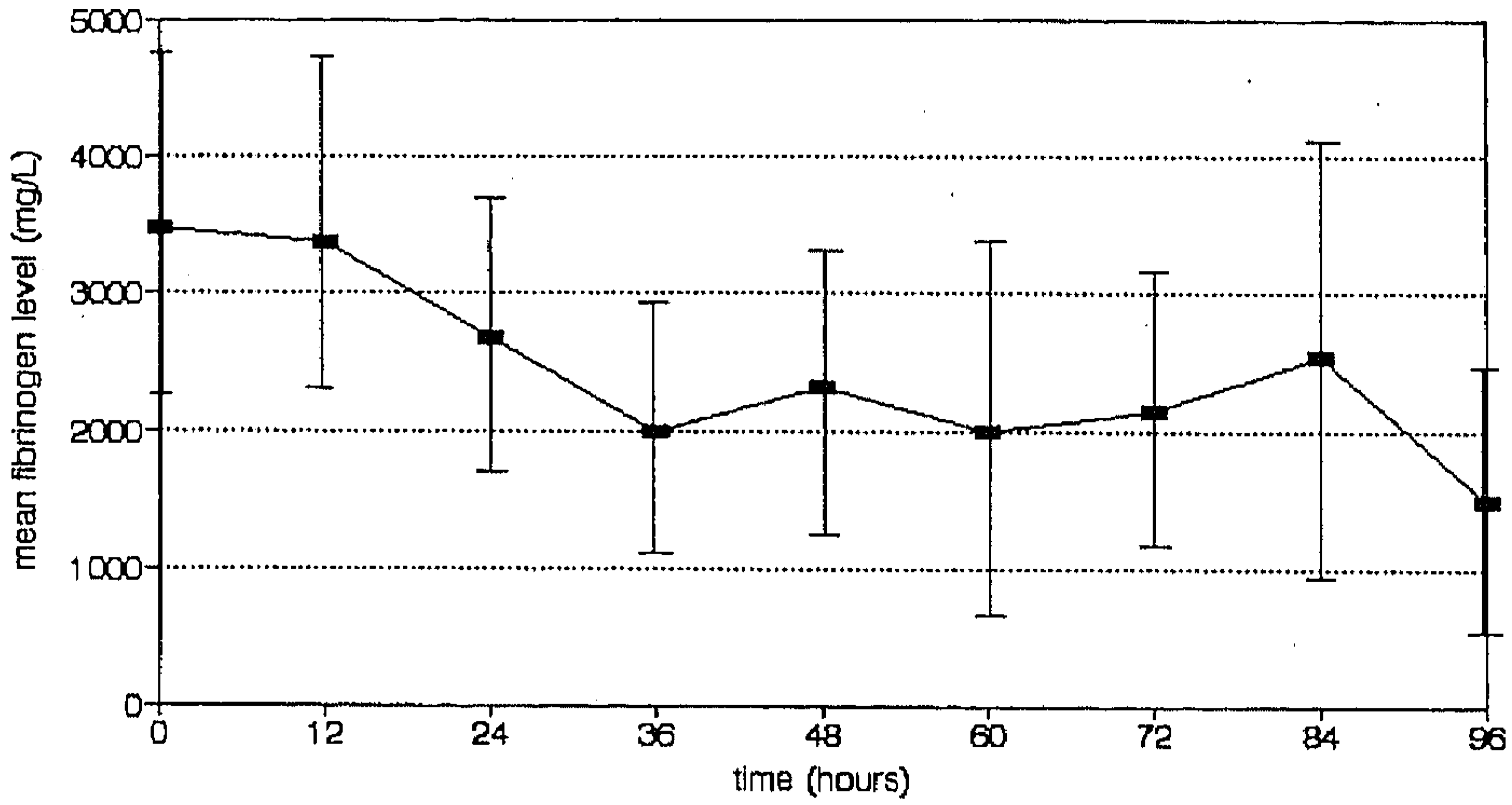


Fig. 2C

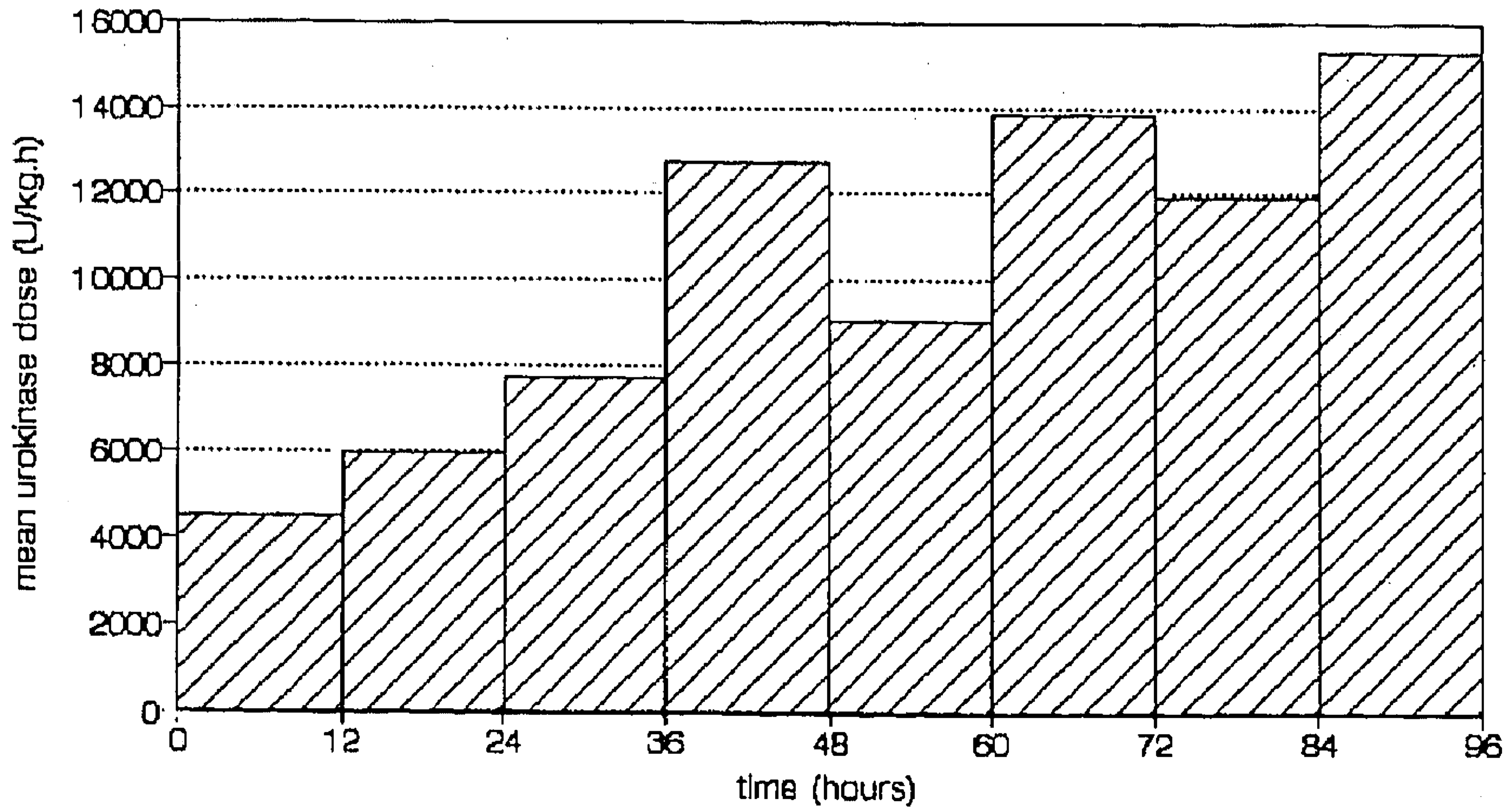


Fig. 2 Mean thrombin time values and mean fibrinogen levels with standard deviations during urokinase therapy

Positive blood or catheter tip cultures were found in 16 patients (62%). Eleven of these patients also had clinical signs of sepsis. The infections were predominantly caused by *Staphylococcus epidermidis* (n = 9). Other cultured micro-organisms included: *Staphylococcus aureus* (n = 2); *Escherichia coli* (n = 2); *Enterobacter cloacae* (n = 2); *Klebsiella oxytoca* (n = 1). The occurrence of infection seemed to be influenced by the indwelling time of the catheter: a mean indwelling time of 15 days in patients with infection, and a mean indwelling time of 10 days in patients without infection. The difference was not statistically significant.

In 10 patients the thrombus was located in the right atrium (38%). Other locations included: superior vena cava (n = 5); inferior vena cava (n = 2); left atrium (n = 3); hepatic vein (n = 4); subclavian vein (n = 2). Thrombosis in the left atrium could be explained by malposition of the central venous catheter with crossing of the foramen ovale. Mean thrombus size at the time of diagnosis was 263 mm<sup>3</sup>.

Coagulation studies before therapy and average urokinase dosage are listed in Table 1. Average thrombin time and fibrinogen course during urokinase therapy are mapped out in Fig. 2. In 19 patients a thrombin time  $\geq 50$  s was achieved. In 9 patients fibrinogen dropped below 1000 mg/l and fresh frozen plasma was administered during urokinase infusion. Neither the maximum thrombin time nor the administration of fresh frozen plasma correlated with therapy success.

Complete thrombolysis was achieved in 13 patients (50%). In these patients there was no residual thrombus detectable by echo Doppler cardiography after urokinase therapy, indicating a thrombus mass reduction of 100%. Partial thrombolysis could be achieved in 3 patients (12%). These patients presented a reduction in thrombus mass of 64%, 61% and 20% respectively. Of the remaining 10 patients (38%) the thrombus did not change or became even larger despite urokinase therapy. Hence, therapy failure was observed in a total of 13 patients (50%). In one patient an extremely large thrombus extended through the foramen ovale into the left atrium, necessitating surgical thrombectomy to prevent cerebral thromboembolic complications. Several factors influencing therapy success of urokinase are presented in Table 2.

Mild hemorrhagic complications were noted in 2 patients. In these cases therapy was stopped because of persistent oozing from previous heel puncture sites and a dropping hemoglobin level. Both patients had a fibrinogen level below 1000 mg/l before the onset of hemorrhagic complications. The remaining 7 patients with fibrinogen levels below 1000 mg/l (lowest value 215 mg/l) did not have any signs of bleeding. Cerebral hemorrhage or focal ischemic cerebral damage due to embolic complications were excluded in our patients by means of ultrasound examination.

Of 12 patients with residual thrombosis 9 received additional treatment with oral anticoagulants (Fig. 3). In six of these patients the treated residual clots resolved within 3 months. Two patients with residual thrombosis died of severe bronchopulmonary dysplasia and sepsis before oral medication was tolerated, and in one patient a contraindication for oral anticoagulants was present. Of 14 patients without residual thrombosis after urokinase therapy or thrombectomy 7 received oral anticoagulants. At follow-up ultrasound asymptomatic recurrent thromboses were noted in 4 of 14 successfully treated patients, 3 despite additional oral anticoagulants.

## Discussion

Central venous thrombosis has been reported to occur in 2–10% of neonates with central venous catheters (3, 4, 13, 22). An increased incidence of thrombosis (up to 25%) with the use of larger catheters,

Table 2 Factors influencing therapy success of urokinase

	Patients	Success	(%)
Indwelling time catheter			
<14 days	19	11	(58%)
$\geq 14$ days	7	2	(29%)
Thrombus size			
<100 mm <sup>3</sup>	7	5	(71%)
$\geq 100$ mm <sup>3</sup>	14	5	(36%)
Thrombus localization			
central	20	12	(60%)
peripheral	6	1	(17%)
Blood culture			
negative	10	7	(70%)
positive	16	6	(38%)
Perinatal asphyxia			
Apgar 5' >7	11	7	(64%)
Apgar 5' <7	15	4	(27%)

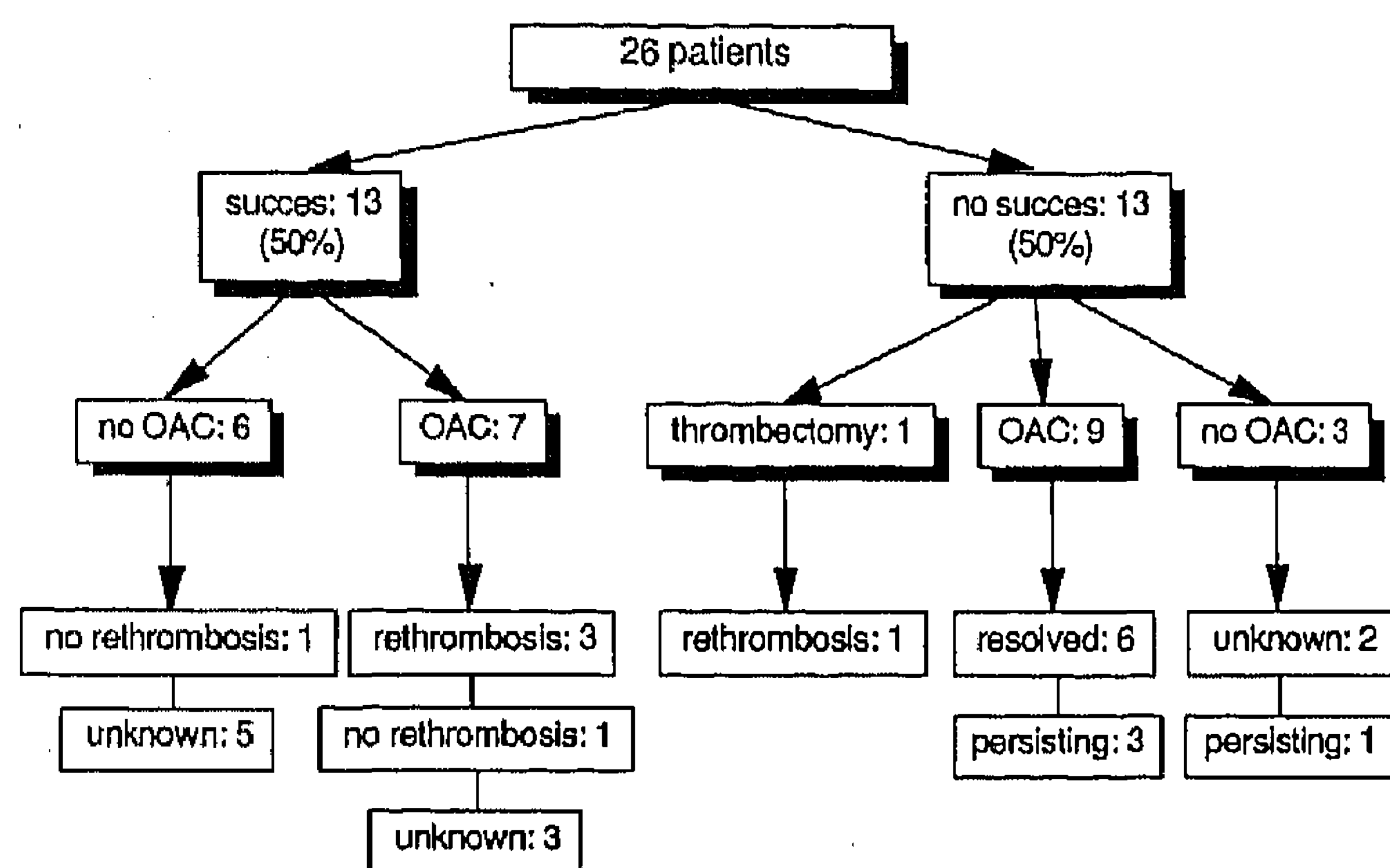


Fig. 3 Overview of outcome and after treatment of 26 patients treated with urokinase for central venous thrombosis. OAC: oral anticoagulants

especially silastic catheters has been reported by several authors (2, 16, 23). The incidence of central venous thrombosis in our department was 6%. Due to the lack of routine screening of central venous catheters during the first year of our study period, and the fact that catheter phlebography was not performed systematically in our patients an underestimation of the incidence of thrombosis may be possible.

Thrombosis on the tip of a central venous catheter can cause obstruction and catheter malfunction and subsequent stasis of blood and solutions (13). Superimposed infection with bacteria or fungi easily occurs and can lead to life-threatening illness (22, 24). Right atrial thrombi may obstruct venous return which can lead to superior or inferior vena cava syndrome, hydrocephalus, or chylothorax (22, 25, 26). When the thrombus extends through the tricuspid valve into the right ventricle tricuspid insufficiency may incite cardiac failure (12, 27). If clot disruption occurs, irreversible vascular obstructive disease may result from multiple small micro-emboli in the pulmonary vasculature. Cardiac arrest and death due to major pulmonary embolism have been reported (16, 22, 27). Cerebral emboli are also possible in cases of left atrial thrombi (27). We noted several of these complications in our patients, particularly infection and vena cava syndrome. Nevertheless, as much as 35% of our patients remained asymptomatic.

Prevention of these harmful complications by early detection of thrombosis is essential. Echo Doppler cardiography or catheter phle-

bography are most frequently applied for this purpose. Echo Doppler cardiography allows visualization and accurate localization and measurement of a thrombus in the heart or great vessels. Modern ultrasound technology makes it possible to distinguish distances of less than 1 mm (28). However, in neonates the diagnostic efficacy of echocardiography for the detection of venous thrombosis has not been adequately assessed (29). Also, echo Doppler cardiography can not provide sufficient assessment to thrombosis in peripheral veins. Therefore, studies comparing echo Doppler cardiography and catheter phlebography in neonates are urgently needed. The importance of routine screening for thrombosis has been emphasized in the literature. It has been recommended that the initial investigation should be obtained no sooner than 3 weeks after catheter insertion (3). Nevertheless, in our study 19 (73%) thrombi were detected at a catheter indwelling time of less than 14 days, indicating that the initial screen should be obtained before the second week.

In our opinion, of the conventional thrombolytic agents urokinase is the drug of choice in the neonatal period because of its single-step plasminogen activation, a more predictable dose-response relationship than other agents and its nonantigenicity in humans (6, 10). Streptokinase should not be used in the newborn because of risk of bleeding complications during prolonged use. Urokinase has a more selective action on fibrin, and is therefore less dangerous. Recently developed thrombolytic agents such as recombinant single-chain urokinase plasminogen activator (r scu-PA) and recombinant tissue-type plasminogen activator (rt-PA) could also be applied in the newborn, however experience with these agents in neonates is limited (29–31). Moreover, a recent multicenter trial in adults has reported a higher incidence of cerebral haemorrhage with the use of rt-PA (32).

In studies performed on adults the incidence of reperfusion of coronary arteries has been 60–70%, regardless of the agent used (29, 30). In adults with catheter related central venous thrombosis, treatment with urokinase resulted in complete thrombolysis in 36 of 38 patients (95%) (33). In the literature, 8 case reports describe the use of urokinase in newborns, resulting in thrombolysis in 26 of 29 infants (90%) (12–19). In contrast, we could only achieve complete thrombolysis in 50% of our patients, in spite of high dosages of urokinase. It seems likely that in neonates the results of thrombolytic therapy are less favourable than in adults. Factors such as reduced levels of plasminogen, and higher levels of inhibitors of plasminogen activation have been thought to contribute to a decreased fibrinolytic activity in the newborn and an impaired response to fibrinolytic therapy in newborns compared to adults (34–36). Investigators have suggested that the newborn may need up to 11 times the usual dosage of urokinase compared to adults (9). A recent in vitro study showed an evident resistance of newborn fibrin clots to all thrombolytic agents due to low levels of plasminogen. The degree of fibrinolysis could be increased to adult values by increasing plasminogen concentrations (35). These findings may explain the relative insensitivity to even high dosages of thrombolytic agents in newborn, which is also illustrated by the minimal alterations in thrombin time and fibrinogen level during urokinase therapy (Fig. 2). It is possible that increasing the concentration of plasminogen will enhance the clinical response to thrombolytic therapy in newborns. However, in our patients the administration of fresh frozen plasma did not enhance the success rate of urokinase therapy.

Other factors that are less favourable for successful thrombolytic therapy are peripheral location of the thrombus, large thrombus size, thrombus age more than 7 days and low plasminogen concentration (10). We noted that a lower incidence of successful thrombolysis in our patients may have been related to some of these factors (Table 2), but

significant differences can not be proved. Rather large differences are required to obtain statistical significance. Nevertheless, these results could provide some guidelines for future investigations in neonates. Perinatal asphyxia and sepsis are thought to be risk factors for the development of thrombosis, possibly related to some degree of disseminated intravascular coagulation and hypoxic damage to vessel endothelium (6, 37, 38). We noted a high incidence of infection in our patients (62%). Therefore, we recommend prescribing antibiotics in neonates with thrombosis in an attempt to treat coexistent or prevent superimposed infection and possibly therapy failure. Because of the predominance of gram-positive strains (69%) small-spectrum antibiotics may be applied, unless blood cultures prove otherwise. Broad-spectrum antibiotics should only be given if necessary, because of the risk of multiresistant strains.

A significantly higher birth weight and gestational age were found in neonates with catheter related central venous thrombosis when compared to neonates without thrombosis in the presence of a central venous catheter. These findings suggest that neonates with a higher birthweight and gestational age are at risk for developing catheter related central venous thrombosis. A relatively large proportion of neonates with a higher weight probably has perinatal asphyxia or sepsis, which may contribute to the development of thrombosis. Another possibility is that small thrombi may be overlooked in low birth weight neonates because of the difficulty of performing echo Doppler cardiography, which therefore becomes less reliable in these infants.

Hemorrhagic complications during thrombolytic therapy occur in about 5% of adult patients (29, 30). In neonates, hemorrhagic and embolic complications are especially feared. In case reports using urokinase for central venous thrombosis in neonates pulmonary embolism has been reported in 2 of 29 neonates (7%) (14, 16). Cerebral hemorrhage has been reported once in a patient with arterial thrombosis (39). We noted only mild peripheral hemorrhagic complications in 2 patients (8%).

In adults, approximately 10 to 20 percent of reperfused arteries develop recurrent thrombosis despite additional anticoagulant therapy (29, 30). In the neonatal case-reports reviewed by these authors recurrent thrombosis occurred in 6 of 29 patients (21%) (12–19). In our study 4 patients developed recurrent thrombosis (28%), three despite anticoagulant therapy. Of 9 residual thrombi after urokinase therapy 6 (67%) resolved following additional anticoagulant therapy for 3 months. It is not clear whether these thrombi would have resolved spontaneously without anticoagulant therapy. Patients with and without residual thrombosis after urokinase therapy may benefit from additional treatment with oral anticoagulants. The appropriate duration and dose of oral anticoagulants needs further investigation.

Prevention of catheter related central venous thrombosis is an important, yet unresolved, issue. A continuous infusion of low dose heparin has been shown to prolong catheter patency (40), but a significant reduction in catheter related central venous thrombosis has not been confirmed (8, 41). Despite heparin prophylaxis in all patients with central venous catheters we reported a rather high incidence of thrombosis (6%). Hydrophilic polyurethane catheters seem to have the least thrombogenic properties (42). However, prolonged use of hydrophilic polyurethane catheters did not lead to a significant reduction in the incidence of thrombi when compared to prolonged use of polyvinyl chloride catheters (43). It is possible that the abnormal coagulation and fibrinolytic system in the newborn and conditions such as sepsis and asphyxia are of greater importance in the etiology of catheter related thrombosis. Apart from limited use of central venous catheters, especially in asphyxiated and septic newborns, early detection and

appropriate treatment of catheter related central venous thrombosis remain of crucial importance.

#### Acknowledgements

The authors wish to thank R. van Megen and N. Jacobs for their technical assistance, G. Born MSc for his statistical assistance, L. S. Sanchez MD for her linguistic support and Prof. L. A. H. Monnens MD PhD for his critical review of the script.

#### References

1. Ryan JA, Abel RM, Abbott WM, Hopkins CC, Chesney TM, Colley R, Phillips K, Fischer JE. Catheter complications in total parenteral nutrition. *N Engl J Med* 1974; 290: 757-61.
2. Grisoni ER, Mehta SK, Connors AF. Thrombosis and infection complicating central venous catheterization in neonates. *J Pediatr Surg* 1986; 21: 772-6.
3. Mactier H, Alroomi LG, Young DG, Raine PAM. Central venous catheterisation in very low birthweight infants. *Arch Dis Child* 1986; 61: 449-53.
4. Marsh D, Wilkerson SA, Cook LN, Pietsch JB. Right atrial thrombus formation screening using two-dimensional echocardiograms in neonates with central venous catheters. *Pediatrics* 1988; 81: 284-6.
5. Mendoza GJB, Soto A, Brown EG, Dolgin SE, Steinfeld L, Sweet AY. Intracardiac thrombi complicating central total parenteral nutrition: Resolution without surgery or thrombolysis. *J Pediatr* 1986; 108: 610-3.
6. Corrigan JJ. Neonatal thrombosis and the thrombolytic system: pathophysiology and therapy. *Am J Pediatr Hematol Oncol* 1988; 10: 83-91.
7. O'Neill JA, Neblett WW, Born ML. Management of major thromboembolic complications of umbilical artery catheters. *J Pediatr Surg* 1981; 16: 972-8.
8. Schmidt B, Andrew M. Neonatal thrombosis: a critical appraisal of the available evidence on prevention, diagnosis, and treatment. In: Perinatal Thrombosis and Hemostasis. Suzuki S, Hathaway WE, Bonnar J, Sutor AH, eds. Springer-Verlag, Tokyo 1991; pp 137-44.
9. Corrigan JJ, Sleeth JJ, Jeter M, Lox CD. Newborn's fibrinolytic mechanism: components and plasmin generation. *Am J Hematol* 1989; 32: 273-8.
10. Bell WR, Meek AG. Guidelines for the use of thrombolytic agents. *N Engl J Med* 1979; 301: 1266-70.
11. The Urokinase Pulmonary Embolism Trial: A National Cooperative Study. American Heart Association Monograph, No. 39. *Circulation* 1973; 47 (Suppl 2): 7-23.
12. Delaplane D, Scott JP, Riggs TW, Silverman BL, Hunt CE. Urokinase therapy for a catheter-related right atrial thrombus. *J Pediatr* 1982; 100: 149-52.
13. Curnow A, Idowu J, Behrens E, Toomey F, Georgeson K. Urokinase therapy for silastic catheter-induced intravascular thrombi in infants and children. *Arch Surg* 1985; 120: 1237-40.
14. Zureikat GY, Martin GR, Silverman NH, Newth CJL. Urokinase therapy for a catheter-related right atrial thrombus and pulmonary embolism in a 2-month-old infant. *Pediatr Pulmonol* 1986; 2: 303-6.
15. Pongiglione G, Marasini M, Ribaldone D, Silvestri G, Tuo P, Garello-Cantoni L. Right atrial thrombosis in two premature infants: successful treatment with urokinase and heparin. *Eur Heart J* 1986; 7: 1086-9.
16. Sadiq HF, Devaskar S, Keenan WJ, Weber TR. Broviac catheterization in low birth weight infants: incidence and treatment of associated complications. *Crit Care Med* 1987; 15: 47-50.
17. Wilson CM, Merritt RJ, Thomas DW. Successful treatment of superior cava syndrome with urokinase in an infant. *J Parenter Enteral Nutr* 1988; 12: 81-3.
18. Griffin MP, Casta A. Successful urokinase therapy for superior vena cava syndrome in a premature infant. *Am J Dis Child* 1988; 142: 1267-8.
19. Caglar MK, Tolboom J. Successful treatment of superior vena cava syndrome with urokinase in an infant with a central venous catheter. *Helv Paediat Acta* 1988; 43: 483-6.
20. Valk WJC, Liem KD, Geven WB. The Seldinger technique as an alternative approach for the percutaneous insertion of a hydrophilic poly-urethane central venous catheter in the newborn. *JPEN* 1995 (accepted).
21. Schmidt B, Andrew M. Report of scientific and standardization subcommittee on neonatal hemostasis: diagnosis and treatment of neonatal thrombosis. *Thromb Haemost* 1992; 67 (3): 381-2.
22. Mollitt DL, Golladay ES. Complications of TPN catheter induced vena caval thrombosis in children less than one year of age. *J Pediatr Surg* 1983; 18: 462-6.
23. Gauderer MW, Stellato TA. Subclavian Broviac in children - technical considerations in 146 consecutive placements. *J Pediatr Surg* 1985; 20: 402-5.
24. Haddad W, Idowu J, Georgeson K, Bailey L, Doroshov R, Pickham N. Septic atrial thrombosis: a potentially lethal complication of Broviac catheters in infants. *Am J Dis Child* 1986; 140: 778-81.
25. Haar RL, Miller CA. Hydrocephalus resulting from superior vena caval thrombosis in an infant. *J Neurosurg* 1975; 42: 596-601.
26. Kramer SS, Taylor GA, Garfinkel DJ, Simmons MA. Lethal chylothoraces due to superior vena caval thrombosis in infants. *Am J Radiology* 1981; 137: 559-63.
27. Mahoney L, Snider AR, Silverman NH. Echocardiographic diagnosis of intracardiac thrombi complicating total parenteral nutrition. *J Pediatr* 1981; 98: 469-71.
28. Goldberg SJ, Allen HD, Sahn DJ. Pediatric and adolescent echocardiography; a handbook. Year Book Medical Publishers, Chicago 1975; pp 3-11.
29. Marder VJ, Sherry S. Thrombolytic therapy: current status. *N Engl J Med* 1988; 318: 1512-20 (part one).
30. Marder VJ, Sherry S. Thrombolytic therapy: current status. *N Engl J Med* 1988; 318: 1585-95 (part two).
31. Anderson BJ, Keeley SR, Johnson ND. Caval thrombolysis in neonates using low doses of recombinant human tissue-type plasminogen activator. *Anaesth Intensive Care* 1991; 19: 22-7.
32. ISIS-3. A randomised comparison of streptokinase vs tissue plasminogen activator vs anistreplase and of aspirin plus heparin vs aspirin alone among 41299 cases of suspected acute myocardial infarction. *Lancet* 1992; 339: 753-70.
33. Seigel EL, Jew AC, Delcore R, Iliopoulos JI, Thomas JH. Thrombolytic therapy for catheter-related thrombosis. *Am J Surg* 1993; 166: 716-8.
34. Ekelund H, Hedner U, Nilsson IM. Fibrinolysis in newborns. *Acta Paediatr Scand* 1970; 59: 33-43.
35. Andrew M, Brooker L, Leaker M, Paes B, Weitz J. Fibrin clot lysis by thrombolytic agents is impaired in newborns due to a low plasminogen concentration. *Thromb Haemost* 1992; 68: 325-30.
36. Edelberg JM, Enghild JJ, Pizzo SV, Gonzalez-Gronow M. Neonatal plasminogen displays altered cell surface binding and activation kinetics. *J Clin Invest* 1990; 86: 107-12.
37. Schmidt B, Zipursky A. Thrombotic disease in newborn infants. *Clin perinatal* 1984; 11: 461-88.
38. Vailas GN, Brouillette RT, Scott JP, Shkolnik A, Conway J, Wiringa K. Neonatal aortic thrombosis: recent experience. *J Pediatr* 1986; 109: 101-8.
39. Strife JL, Ball WS, Towbin R, Keller MS, Dillon T. Arterial occlusions in neonates: use of fibrinolytic therapy. *Radiology* 1988; 166: 395-400.
40. Rajani K, Goetzman BW, Wennberg RP, Turner E, Abildgaard C. Effect of heparinization in fluids infused through an umbilical artery catheter on catheter patency and frequency of complications. *Pediatrics* 1979; 63: 552-6.
41. Schmidt B. Neonatal thrombotic disease: prevention, diagnosis and treatment. *J Pediatr* 1988; 113: 407-10.
42. Borow M, Crowley JG. Evaluation of central venous catheter thrombogenicity. *Acta Anaesthesiol Scand* 1985; Suppl 81: 59-64.
43. Jackson JC, Truog WE, Watchko JF, Mack LA, Cyr DR, van Belle G. Efficacy of thromboresistant umbilical artery catheters in reducing aortic thrombosis and related complications. *J Pediatr* 1987; 110: 102-5.

Received March 15, 1994 Accepted after resubmission October 18, 1994