

PDF hosted at the Radboud Repository of the Radboud University Nijmegen

The following full text is a publisher's version.

For additional information about this publication click this link.

<http://hdl.handle.net/2066/154451>

Please be advised that this information was generated on 2019-11-20 and may be subject to change.



White matter integrity in small vessel disease is related to cognition



Anil M. Tuladhar^{a,b,1}, Anouk G.W. van Norden^{c,1}, Karlijn F. de Laat^d, Marcel P. Zwiers^b,
Ewoud J. van Dijk^a, David G. Norris^{b,e,f}, Frank-Erik de Leeuw^{a,g,*}

^aDonders Institute for Brain, Cognition and Behaviour, Centre for Neuroscience, Department of Neurology, Radboudumc, PO Box 9101, Nijmegen 6500 HB, The Netherlands

^bDonders Institute for Brain, Cognition and Behaviour, Centre for Cognitive Neuroimaging, Radboud University Nijmegen, PO Box 9101, Nijmegen 6500 HB, The Netherlands

^cDepartment of Neurology, Amphia Ziekenhuis, Breda, The Netherlands

^dDepartment of Neurology, HagaZiekenhuis, Den Haag, The Netherlands

^eErwin L. Hahn Institute for Magnetic Resonance Imaging, University of Duisburg-Essen, Essen, Germany

^fMIRA Institute for Biomedical Technology and Technical Medicine, University of Twente, Enschede, The Netherlands

^gDonders Institute for Brain, Cognition and Behaviour, Centre for Neuroscience, Department of Psychiatry, Radboud University Nijmegen Medical Centre, PO Box 9101, Nijmegen 6500 HB, The Netherlands

ARTICLE INFO

Article history:

Received 11 January 2015

Received in revised form 6 February 2015

Accepted 10 February 2015

Available online 17 February 2015

Keywords:

Cerebral small vessel disease

Cognition

Tract-based spatial statistics

White matter integrity

ABSTRACT

Cerebral small vessel disease, including white matter hyperintensities (WMH) and lacunes of presumed vascular origin, is common in elderly people and is related to cognitive impairment and dementia. One possible mechanism could be the disruption of white matter tracts (both within WMH and normal-appearing white matter) that connect distributed brain regions involved in cognitive functions. Here, we investigated the relation between microstructural integrity of the white matter and cognitive functions in patients with small vessel disease. The Radboud University Nijmegen Diffusion tensor and Magnetic resonance Cohort study is a prospective cohort study among 444 independently living, non-demented elderly with cerebral small vessel disease, aged between 5500 and 85 years. All subjects underwent magnetic resonance imaging and diffusion tensor imaging scanning and an extensive neuropsychological assessment. We showed that loss of microstructural integrity of the white matter at specific locations was related to specific cognitive disturbances, which was mainly located in the normal-appearing white matter ($p < 0.05$, FWE-corrected for multiple comparisons). The microstructural integrity in the genu and splenium showed the highest significant relation with global cognitive function and executive functions, in the cingulum bundle with verbal memory performance. Associations between diffusion tensor imaging parameters and most cognitive domains remained present after adjustment for WMH and lacunes. In conclusion, cognitive disturbances in subjects with cerebral small vessel disease are related to microstructural integrity of multiple white matter fibers (within WMH and normal-appearing white matter) connecting different cortical and subcortical regions.

© 2015 The Authors. Published by Elsevier Inc. This is an open access article under the CC BY-NC-ND license (<http://creativecommons.org/licenses/by-nc-nd/4.0/>).

1. Introduction

Cerebral small vessel disease (SVD) manifests on conventional MR images (i.e. T1 and Fluid Attenuated Inversion Recovery (FLAIR)) as white matter hyperintensities (WMH) and lacunes of presumed vascular origin (Wardlaw et al., 2013). These SVD markers are commonly observed in the elderly population. SVD is related to cognitive impairment and may, in some, ultimately lead to dementia (de Groot et al., 2000; Vermeer et al., 2003). This is supposedly due to the disruption of important white matter (WM) tracts. Despite the high prevalence of SVD (de Leeuw et al., 2001; Vernooij et al., 2007), relatively few develop evident cognitive decline or dementia (Vermeer et al., 2003). Other factors,

apart from WMH and lacunes, presumably play a role in the transition from relative intact cognitive performance to severe cognitive decline in these few individuals. One of these factors could be the (loss of) microstructural integrity of the largest part of the WM; the on FLAIR imaging normal-appearing white matter (NAWM) surrounding the SVD. Pathological studies have demonstrated loss of microstructural integrity in the NAWM (Grafton et al., 1991) that cannot be visualized with conventional imaging, but can be investigated with diffusion tensor imaging (DTI).

DTI provides information on the microstructural integrity of the WM. DTI measures the local water diffusion profiles by: fractional anisotropy (FA), which represents a normalized ratio of diffusion directionality; mean diffusivity (MD), which reflects the overall magnitude of water diffusion; axial diffusivity (AD), which reflects the diffusivity parallel to the WM tracts and radial diffusivity (RD), which is the diffusivity perpendicular to these tracts (Pierpaoli et al., 1996). Loss of

* Corresponding author. Tel.: +31 243613396; fax: +31 243541122.

E-mail address: FrankErik.deLeeuw@radboudumc.nl (F.-E. de Leeuw).

¹ Authors contributed equally to this work.

microstructural integrity is typically reflected by a reduction in FA and/or an increase in MD (Sen and Bassar, 2005); the latter can result from different combinations of changes in AD and RD. Few studies in patients with cerebral SVD demonstrated a relation between higher MD and lower FA and loss of cognitive function (Della Nave et al., 2007; Nitkunan et al., 2008; O'Sullivan et al., 2001b; O'Sullivan et al., 2004; Xu et al., 2010). These studies had, however, small sample sizes and were not able to properly adjust for possible confounders. One large population-based cohort study demonstrated relation between microstructural integrity of both WMH and NAWM and cognitive function. However, the regional differences of microstructural integrity were not taken into account (Vernooij et al., 2009).

We hypothesized that cognitive performance in subjects with SVD would not only be related to loss of WM microstructural integrity within the WMH, but also to specific areas within the NAWM. We conducted DTI using tract-based spatial statistics (TBSS) analyses to investigate the location of microstructural WM loss related to cognitive disturbances. Also, additional adjustments for the WMH and lacunes were made to examine whether the associations in the WM were primarily explained by the typical manifestations of SVD on conventional MRI.

2. Methods and materials

2.1. Study population

The Radboud University Nijmegen Diffusion tensor and Magnetic resonance imaging Cohort (RUN DMC) study prospectively investigates the risk factors and clinical consequences of brain changes among 503 non-demented elderly with cerebral SVD. The selection procedure of the participants and study protocol were described previously in detail (van Norden et al., 2011). In short, on the basis of established research criteria SVD was defined as the presence of lacunes and/or WMH on neuroimaging (Erkinjuntti, 2002). Symptoms of SVD include acute symptoms, such as TIAs or lacunar syndromes, or subacute manifestations, such as cognitive and motor (gait) disturbances and/or depressive symptoms (Roman et al., 2002). Inclusion criteria were: (a) age between 50 and 85 years; and (b) cerebral SVD on neuroimaging. The main exclusion criteria were dementia (American Psychiatric Association, 2000), (psychiatric) disease interfering with cognitive testing or follow-up, WMH or SVD mimics and MRI contraindications or known claustrophobia. Consecutive patients referred to the Department of Neurology between October 2002 and November 2006 were selected for participation. Participants were selected for participation in the study by a three-step approach. After reviewing the medical history, 1004 individuals were invited by letter. Of those 1004, 727 were eligible after contact by telephone and 525 agreed to participate. In 22 individuals exclusion criteria were found during their visit to our research center, yielding a response of 71.3% (503/705). For the present study, 59 subjects were additionally excluded because of territorial infarcts ($n = 55$) and inadequate quality of the MRI image ($n = 4$), resulting in a final population of 444 participants. All participants signed an informed consent form. The Medical Review Ethics Committee region Arnhem-Nijmegen approved the study.

2.2. Measurement of cognitive function

Cognitive function was assessed by a standardized neuropsychological test battery and has been described in detail elsewhere (van Norden et al., 2011). Performance across tests was made comparable by transforming raw test results in z-scores. We calculated compound scores for seven cognitive domains. Global cognitive function was evaluated by the Mini Mental State Examination (MMSE) and the cognitive index. The cognitive index is a compound score that was calculated as the mean of the z-scores of the 1-letter subtask of the Paper-Pencil Memory Scanning Task, the mean of the reading subtask of the Stroop

test, the mean of the Symbol-Digit Substitution Task and the mean of the added score on the three learning trials of the Rey Auditory Verbal Learning Test and the delayed recall of this last test (Vermeer et al., 2003). Verbal memory is a compound score of the mean of two z-scores from the Rey Auditory Verbal Learning Test; one for the added scores of the three learning trials of this test, and one for the delayed recall of this test. Visuospatial memory is a compound score of the mean of the z-scores of the immediate recall trial and the delayed recall trial of the Rey's Complex Figure Test. Psychomotor speed was calculated as the mean of the z-scores of the 1-letter subtask of the Paper-Pencil Memory Scanning Task, the reading subtask of the Stroop test and the Symbol-Digit Substitution Task. Fluency was calculated from the mean of the z-scores of both verbal fluency tasks. Concept shifting was calculated as the z-score of the third subtask of the Stroop. Attention is a compound score of the z-score of the total time of the Verbal Series Attention Test (de Groot et al., 2000).

2.3. Magnetic resonance imaging scanning protocol

MRI scans of all participants were acquired on a single 1.5-T MRI. The protocol included, among other sequences, the following whole brain scans: 3D T1 magnetization-prepared rapid gradient echo (MPRAGE) sequence (TR/TE/TI 2250/3.68/850 ms; flip angle 15°; voxel size $1.0 \times 1.0 \times 1.0$ mm), a fluid-attenuated inversion recovery (FLAIR) sequence (TR/TE/TI 9000/84/2200 ms; voxel size $1.0 \times 1.2 \times 5.0$ mm, interslice gap 1 mm) and DTI sequences (TR/TE 10,100/93 ms; voxel size $2.5 \times 2.5 \times 2.5$ mm; 4 unweighted scans, 30 diffusion weighted scans with b-value 900 s/mm^2).

2.4. Conventional magnetic resonance imaging analysis

WMH were manually segmented on FLAIR images and the number of lacunes was rated according to a standardized protocol (van Norden et al., 2011). In addition, the visual Fazekas scale was used on the FLAIR images to rate the severity of changes in the white matter (Fazekas et al., 1987). All imaging analyses were performed by two trained raters blinded to clinical information. In a random sample of 10%, interrater variability for total WMH volume yielded an intra-class correlation coefficient of 0.99. The probability map of the white matter hyperintensities were created using a method previously described by de Laat and colleagues (de Laat et al., 2011). In short, we registered the WMH maps to the T1 images using the transformation matrix from the registration parameters of skull-stripped FLAIR images to the T1-images that were obtained using Functional MRI of the Brain linear image registration tool (<http://www.fmrib.ox.ac.uk/fsl/fnirt>). Next, we normalized the WMH maps non-linearly to the group-specific template using the transformation parameters of T1 images to the group-specific template obtained from Functional MRI of the Brain non-linear registration tool (<http://www.fmrib.ox.ac.uk/fsl/flirt>). Finally, we averaged the normalized WMH maps to create a probability map of the WMH of the study population (Fig. 1).

We computed gray (GM) and WM tissue and cerebrospinal fluid (CSF) probability maps using SPM 5 unified segmentation routines on the T1 MPRAGE images (Ashburner and Friston, 2005). Total GM, WM and CSF volumes were calculated by summing all voxel volumes that had a $p > 0.5$ for belonging to that tissue class. Total brain volume (TBV) was taken as the sum of total GM and WM. Intracranial volume (ICV) was a summation of all tissue classes. To normalize for head size, TBV was expressed as percentage of total ICV.

2.5. DTI analysis

Tract-based spatial statistics (TBSS) is a relatively new method that mitigates the limitations of VBM analysis (Smith et al., 2006). This analysis is restricted to those WM voxels that constitute the skeleton (core) of the brain's connective architecture. This skeleton can be matched

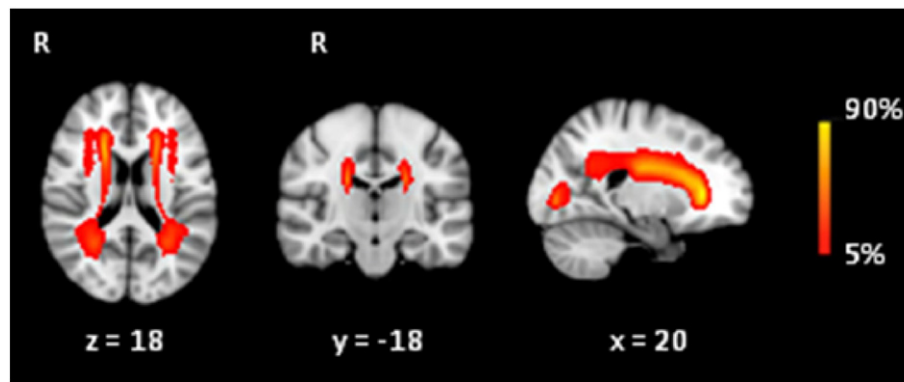


Fig. 1. The probability distribution of the white matter hyperintensities (in red), color-coded in percent (color-bar), thresholded from 5% to 90%. These images are projected onto spatially normalized (Montreal Neurological Institute stereotactic space). R = right.

more accurately (compared to whole-brain normalization) across subjects, enabling robust voxel-wise analysis of the microstructural WM integrity across subjects.

Diffusion data were first preprocessed to detect and correct head and cardiac motion artifacts, using an in-house developed iteratively re-weighted-least-squares algorithm named 'PATCH' (Zwiers, 2010). FA, MD, AD and RD images were then calculated using DTIFit within the Functional MRI of the Brain diffusion toolbox, which were fed into the TBSS pipeline (Smith et al., 2006). The thinning procedure was conducted on the mean FA image to create a common skeleton, which represents the core-structure of the WM tract. This skeleton was thresholded at the FA-value 0.3 to include the major WM tracts and to account for the inter-subject variability. All normalized FA data were then projected onto this skeleton. These skeleton projection factors were then applied to the MD, AD and RD images. These data were then fed into the voxel-wise cross-subject statistics. In addition, we obtained FA, MD, AD and RD for three parts of the corpus callosum by performing region-of-interest analyses. The corpus callosum provides interhemispheric connections between cortical and subcortical regions and might play an important role in cognitive function (Bloom and Hynd, 2005). We created masks for genu, body and splenium of the corpus callosum by applying the WM atlas (Johns Hopkins University WM labels, provided by Functional MRI of the Brain Software Library (FSL)) on the mean FA skeleton. The masks were visually inspected and miscellaneous voxels that belonged to other regions, such as the cingulum bundle, were excluded.

2.6. Other measurements

Age, sex and level of education, depressive symptoms and normalized TBV were considered possible confounders. Depressive symptoms were assessed using the Center of Epidemiologic Studies on Depression Scale (CES-D) (Radloff, 1977). Functional independence was assessed using the Barthel Index (range 0–20) (Mahoney and Barthel, 1965). For assessment of vascular risk factors, structured questionnaires were used together with measurements of blood pressure taken on separate occasions. The risk factors included presence of hypertension (mean blood pressure $\geq 140/90$ mm Hg and/or use of anti-hypertensive medications) (Rosendorff, 2007), diabetes (treatment with antidiabetic drugs), hypercholesterolemia (treatment with lipid-lowering drugs) and smoking status.

2.7. Statistical analysis

Baseline characteristics were presented as mean \pm standard deviation (SD) and for the skewed parameters the median and interquartile ranges were calculated.

For the TBSS analyses, we assessed voxel-wise correlations between the skeletal DTI parameters (FA and MD) and cognitive performance on

several cognitive domains, while adjusting for age, sex, education, depressive symptoms and normalized TBV. To test whether these associations were independent of WMH and lacunes, we adjusted for WMH volume and number of lacunes in a second model. For the voxel-wise statistical analyses, we applied permutation-based statistical interference tool for non-parametric approach, with number of permutation tests set to 5000 (Nichols and Holmes, 2002). Significant clusters were identified using the threshold-free cluster enhancement with a p -value < 0.05 , corrected for multiple comparisons (Smith and Nichols, 2009).

For the ROI analyses, we computed regression coefficients of the mean FA, MD, AD and RD of the three ROI in the corpus callosum with cognitive performance, while adjusting for age, sex, education, depressive symptoms, normalized TBV, white matter hyperintensities and number of lacunes. Regression coefficients were presented as standardized β -values. Bonferroni corrections were applied.

3. Results

Demographic and neuroimaging characteristics are shown in Table 1. Mean age of the population ($n = 444$) was 65.3 years (SD 8.9) and 54.7% were male. Mean WM volume was 467.4 ml (SD 65.4). The largest part of the WM consisted of NAWM, with a median percentage of 98.6 (IQR 96.4–99.3). According to Fazekas visual rating scale, 10 participants (2.3%) had Fazekas score 0, 296 participants (66.7%) had Fazekas-score 1, 88 participants (19.8%) had Fazekas score 2 and 50 participants (11.3%) had Fazekas score 3. White matter hyperintensities

Table 1
Baseline characteristics of the study population.

Characteristics	$n = 444$
Demographics	
Age (years)	65.3 (8.9)
Male*	243 (54.7)
Only primary education*	44 (10)
CES-D scale	11.2 (9.5)
Mini mental state examination	28.1 (1.6)
Hypertension*	320 (72.1)
Diabetes*	61 (13.7)
Hypercholesterolemia*	194 (43.7)
Smokers, current*	69 (15.5)
Smokers, former*	239 (53.8)
Neuroimaging	
TBV, ml	1098.0 (120.6)
ICV, ml	1673.8 (158.2)
WMH volume, ml†	6.4 (3.3; 16.8)
White matter volume, ml	467.4 (65.4)
Lacunes*	102 (23.0)

Data represent N of subjects* (%), mean (SD), or median† (interquartile range). TBV: total brain volume; ICV: intracranial volume; WMH: white matter hyperintensities.

were predominately located in the frontal periventricular regions (Fig. 1). 13 participants (2.9% of the study population) were diagnosed with mild cognitive impairment.

Fig. 2 shows the relation between FA and the cognitive domains tested ($p < 0.05$, FWE-corrected for multiple comparisons). FA in the frontal, parietal, occipital, temporal but also in the infratentorial voxels of the skeleton was positively related to the cognitive index, attention and verbal memory performance. A lower FA in almost all regions was associated with higher scores on psychomotor speed and concept shifting (indicating lower performance). We found a similar distribution for the inverse association with MD and the cognitive domains. With regard to MMSE, visuospatial memory and fluency, no significant associations were found for FA and MD. A significant (p -corrected < 0.01) association was identified in almost all voxels of the skeleton in the relation between FA and cognitive index and concept shifting. The strongest significant (p -corrected < 0.01) relation between MD and psychomotor speed and cognitive index was

located in the frontal lobe and the corpus callosum. The relation between FA and MD and verbal memory was most outspoken along the whole course of the corpus callosum and the cingulum bundle (p -corrected < 0.01).

Additional adjustment for WMH and lacunes (Fig. 2B) weakened the relations between the FA and cognitive index, psychomotor speed, verbal memory and concept shifting, but remained present (p -corrected < 0.05). There were no associations between for FA and attention after additional adjustment for WMH and lacunes. There were no associations between MD and attention after additional adjustment for WMH and lacunes, while the associations between MD and psychomotor speed and concept shifting weakened but remained significant. Voxels with the highest significance for FA in relation to cognitive index, psychomotor speed, verbal memory and concept shifting were located in the corpus callosum (p -corrected < 0.01). In addition, FA in the cingulum bundle and corpus callosum remained highly associated with verbal memory performance (p -corrected < 0.01).

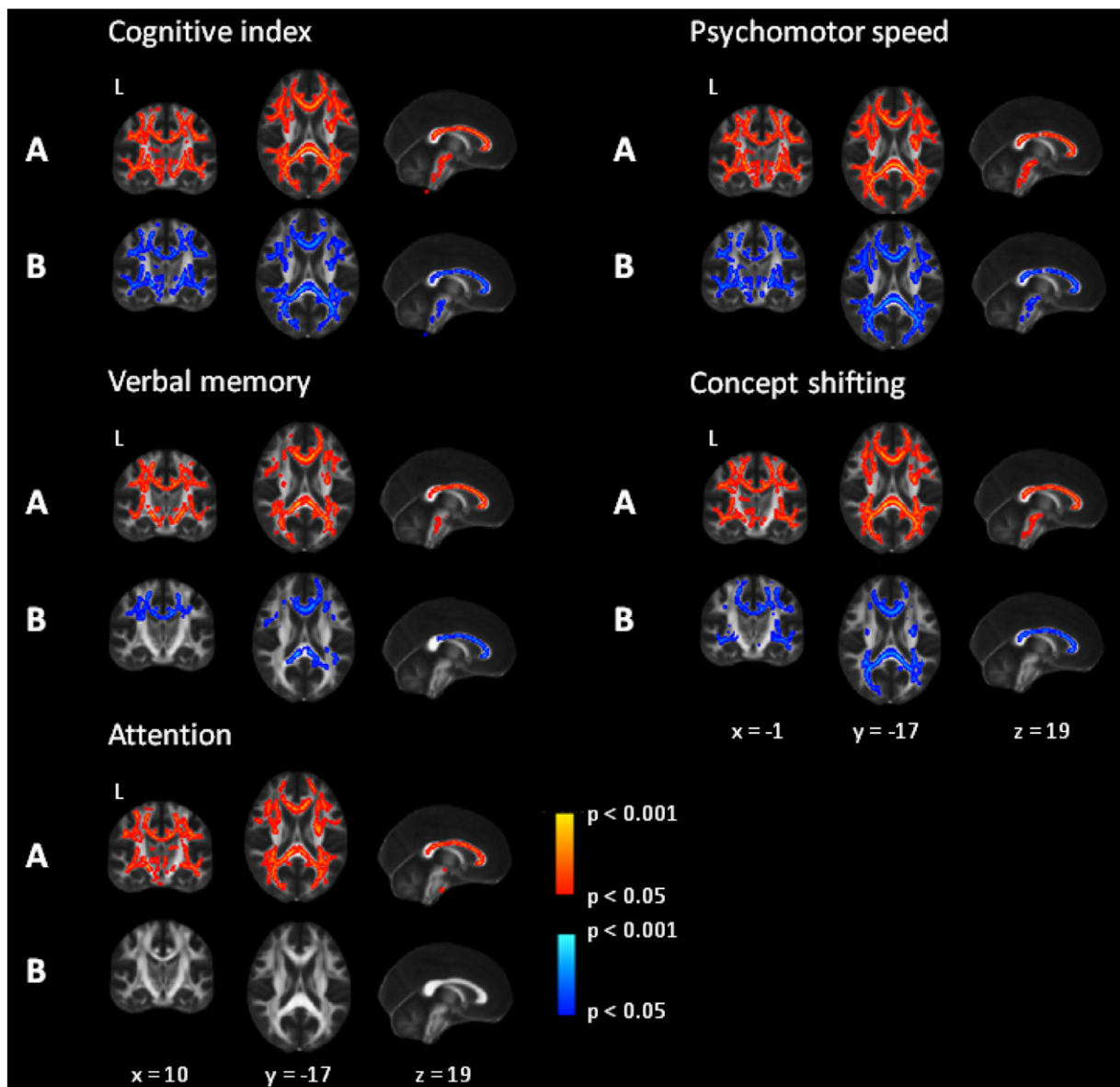


Fig. 2. Voxel-wise analysis of the relation between fractional anisotropy and the cognitive index and verbal memory performance and negatively associated with psychomotor speed, concept shifting and attention. A) Adjusted for age, sex, education, depressive symptoms and normalized TBV, depicted by red-yellow color thresholded at $p < 0.05$ and corrected for multiple comparisons and B) additional adjustment for white matter hyperintensities and lacunes, depicted by blue color thresholded at $p < 0.05$ and corrected for multiple comparisons. The statistical maps are superimposed onto the spatially normalized (Montreal Neurological Institute stereotactic space) T1 map.

Table 2
Association between the microstructural integrity of the corpus callosum and cognitive performance.

	Cognitive index	Verbal memory	Psychomotor speed	Concept shifting
Genu				
FA	.19*	.12	.16*	.16*
MD	-.19*	-.13	-.14*	-.11
AD	-.12	-.10	-.06	-.01
RD	-.19*	-.12*	-.16*	-.14*
Body				
FA	.14	.13*	.09	.15*
MD	-.16*	-.14*	-.10	-.09
AD	-.08	-.05	-.05	-.06
RD	-.16*	-.14*	-.10	-.13*
Splenium				
FA	.19*	.09	.18*	.19*
MD	-.15*	-.09	-.13	-.13*
AD	-.02	-.04	-.01	-.01
RD	-.18*	-.09	-.17*	-.18*

Standardized β -values adjusted for age, sex, education, depressive symptoms, normalized TBV, white matter hyperintensities and number of lacunes. FA: fractional anisotropy. MD: mean diffusivity. AD: axial diffusivity. RD: radial diffusivity.
* $p < .05$ (Bonferroni corrected).

As post-hoc analysis we analyzed the corpus callosum in more anatomical detail by segmenting it in three regions (Table 2). We found that microstructural integrity of genu and splenium of the corpus callosum related to cognitive index, but also with executive domains, psychomotor speed and concept shifting ($p < 0.05$ after Bonferroni corrections). The microstructural integrity of body was associated with verbal memory. We found no relations between microstructural integrity in corpus callosum and attention, visuospatial memory, MMSE and fluency. The associations with MD and cognitive performance were mainly driven by changes in RD, and not by changes in AD.

4. Discussion

In this study, we examined the relation between the microstructural integrity of the WM and cognitive performance in subjects with cerebral SVD. We demonstrated that low FA and high MD in multiple regions of the WM were associated with lower scores on cognitive performance. The corpus callosum showed the highest significant relation with cognitive function, especially in the genu and splenium. The microstructural integrity of the cingulum bundle showed the highest significant relation with verbal memory performance and the frontal WM with psychomotor speed.

A limitation is the cross-sectional nature of our study, which limits causal inference. The RUN DMC study has a longitudinal design and follow-up is currently being executed to evaluate the effect of progression of SVD on (changes in) cognitive performance (van Norden et al., 2011). In addition, we did not intentionally adjust for vascular risk factors, such as hypertension or diabetes, as they were considered a part of the causal chain between SVD and cognitive performance. Major strengths of the study included the large sample size, the single center design, the use of a single scanner and the high response rate. Furthermore, we manually segmented the WMH. Extensive neuropsychological assessment was performed by two investigators and all analyses were adjusted for potential confounders.

Structural abnormality of the white matter tracts has been found in Alzheimer's disease and mild cognitive impairment and has been demonstrated in a population-based cohort and a cohort of healthy adults (Acosta-Cabronero et al., 2010; Barrick et al., 2010; Damoiseaux et al., 2009; Vernooij et al., 2008; Zhuang et al., 2010). In patients with SVD, clinical manifestations of cognitive impairment are usually of a characteristic and fairly homogeneous 'subcortical' pattern and include psychomotor slowing due to impaired executive function, deficits of

attention, planning and set-shifting and forgetfulness (Roman et al., 2002). In this study, we demonstrated that in patients with SVD the white matter's microstructural integrity was associated with these measures of cognition.

We showed that WM integrity at specific locations was related to specific cognitive performance. The strongest significant relations between microstructural integrity and verbal memory performance were located in the cingulum bundle. This bundle, which connects the medial temporal lobe and the posterior cingulate cortex, is an important structure in verbal memory performance (Sepulcre et al., 2008; van der Holst et al., 2013). We also found verbal memory to be associated with the anterior parts of the corpus callosum. Episodic memory is partially dependent on interhemispheric interaction (Christman and Propper, 2001). Loss of microstructural integrity of the corpus callosum can lead to impaired interhemispheric interaction, resulting in impaired (verbal) memory performance. With regard to psychomotor speed, we found that the strongest significant relation with microstructural integrity was located in the corpus callosum and frontal lobe. The prefrontal-subcortical circuits are known to be involved in executive function, which affects the psychomotor speed (Roman et al., 2002). Corpus callosum has been related to global cognitive status and, based on a topographical organization, genu has been related to frontal-lobe-mediated executive function and attention (Jokinen et al., 2007), whereas splenium is associated with visuospatial construction (Fryer et al., 2008), which corresponds with its connection with the parietal, temporal and occipital regions (Huang et al., 2005). We found no relations between WM integrity and fluency and MMSE. This might be explained by the fact that MMSE is a too crude measure not designed for subcortical damage related function loss and hence not sensitive to detect subtle cognitive changes that correlate with macro- and microstructural SVD changes (Pasi et al., 2015).

The whole spectrum of cognitive disturbances in patients with SVD cannot solely be explained by the degree of WMH and lacunes. Our results show that the majority of the relations between microstructural integrity and cognitive performance were located in the NAWM. This suggests that the microstructural integrity of the NAWM has an important role in the cognitive disturbances in our subjects with SVD and might explain a part of the cognitive impairment beyond the SVD-visible on conventional MRI. Findings from functional and pathological studies in combination with our results suggest a disruption of cortical-cortical and cortical-subcortical connections, and a subsequent 'disconnection-syndrome' accounting for cognitive disturbances in patients with SVD (O'Sullivan et al., 2001a). In concordance with the findings from previous studies (van Norden et al., 2012; Vernooij et al., 2009), this suggests that microstructural integrity of the NAWM should also be taken into account when investigating the relation between SVD and cognitive function and that DTI should be considered part of the imaging protocol in future studies on cognitive performance.

The abnormalities in microstructural integrity of the NAWM are partially SVD-related, as our results showed that the presence of WMH and lacunes weakened the relation between the WM integrity and cognitive performance. Several explanations could be proposed by which SVD might influence this relation. First, it may be that these associations were, at least in part, explained by the presence of the coexisting WMH and not so much by the loss of integrity of the NAWM. Second, the structural changes of the NAWM could be caused by the same risk factors that are involved in the development of SVD, such as hypertension (Gons et al., 2012). This hypothesis is supported by the finding of increased blood-brain barrier permeability in the NAWM in subjects with SVD (Topakian et al., 2010). Finally, the observed association between the microstructural integrity of the NAWM and cognitive performance could reflect indirect damage to the NAWM by distant effects of WMH by means of antero-(Wallarian) or retrograde degeneration (Dziedzic et al., 2010; Thomalla et al., 2004).

In conclusion, our study showed that cognitive disturbances in elderly with SVD are related to the microstructural integrity of the

cerebral WM areas with WMH and lacunes, but also in NAWM, the largest part of the WM. Our results suggest that loss of microstructural integrity in the NAWM is part of the SVD-spectrum, which is not visible on conventional MRI. DTI could therefore serve as an additional tool to conventional MRI in order to investigate the cognitive consequences of cerebral SVD. If the predictive value is proven, DTI could possibly serve a surrogate marker for development of cognitive decline and dementia and could be a starting point for therapeutic trials aiming to prevent disease progression.

Conflicts of interest

The authors have no conflicts of interest.

Acknowledgements

F.E.d.L and E.J.v.D.: personal fellowships Dutch Brain Foundation (H04-12; F2009(1)-16); clinical fellowship Netherlands Organization Scientific Research (40-00703-97-07197); F.E.d.L. received a Vidi innovative grant from the Netherlands Organization for Scientific Research (grant number 016.126.351). This work was also supported by the 'Internationale Stichting Alzheimer Onderzoek'.

References

- Acosta-Cabronero, J., Williams, G.B., Pengas, G., Nestor, P.J., 2010. Absolute diffusivities define the landscape of white matter degeneration in Alzheimer's disease. *Brain* 133 (2), 529–539. <http://dx.doi.org/10.1093/brain/awp25719914928>.
- American Psychiatric Association, 2000. *Diagnostic Criteria from DSM-IV-TR*. American Psychiatric Association, Washington, D.C.
- Ashburner, J., Friston, K.J., 2005. Unified segmentation. *Neuroimage* 26 (3), 839–851. <http://dx.doi.org/10.1016/j.neuroimage.2005.02.01815955494>.
- Barrick, T.R., Charlton, R.A., Clark, C.A., Markus, H.S., 2010. White matter structural decline in normal ageing: a prospective longitudinal study using tract-based spatial statistics. *Neuroimage* 51 (2), 565–577. <http://dx.doi.org/10.1016/j.neuroimage.2010.02.03320178850>.
- Bloom, J.S., Hynd, G.W., 2005. The role of the corpus callosum in interhemispheric transfer of information: excitation or inhibition? *Neuropsychol. Rev.* 15 (2), 59–71. <http://dx.doi.org/10.1007/s11065-005-6252-y16211466>.
- Christman, S.D., Propper, R.E., 2001. Superior episodic memory is associated with interhemispheric processing. *Neuropsychol.* 15 (4), 607–616. <http://dx.doi.org/10.1037/0894-4105.15.4.60711761050>.
- Damoiseaux, J.S., Smith, S.M., Witter, M.P., Sanz-Arigita, E.J., Barkhof, F., Scheltens, P., Stam, C.J., Zarei, M., Rombouts, S.A., 2009. White matter tract integrity in aging and Alzheimer's disease. *Hum. Brain Mapp.* 30 (4), 1051–1059. <http://dx.doi.org/10.1002/hbm.2056318412132>.
- De Groot, J.C., de Leeuw, F.E., Oudkerk, M., van Gijn, J., Hofman, A., Jolles, J., Breteler, M.M., 2000. Cerebral white matter lesions and cognitive function: the Rotterdam Scan Study. *Ann. Neurol.* 47 (2), 145–151. <http://dx.doi.org/10.1093/annneu.47.2.145>.
- De Laat, K.F., Tuladhar, A.M., van Norden, A.G., Norris, D.G., Zwiers, M.P., de Leeuw, F.E., 2011. Loss of white matter integrity is associated with gait disorders in cerebral small vessel disease. *Brain* 134 (1), 73–83. <http://dx.doi.org/10.1093/brain/awq34321156660>.
- De Leeuw, F.E., de Groot, J.C., Achten, E., Oudkerk, M., Ramos, L.M., Heijboer, R., Hofman, A., Jolles, J., van Gijn, J., Breteler, M.M., 2001. Prevalence of cerebral white matter lesions in elderly people: a population based magnetic resonance imaging study. The Rotterdam Scan Study. *J. Neurol. Neurosurg. Psychiatry* 70 (1), 9–14. <http://dx.doi.org/10.1136/jnnp.70.1.91118240>.
- Della Nave, R., Foresti, S., Pratesi, A., Ginestroni, A., Inzitari, M., Salvadori, E., Giannelli, M., Diciotti, S., Inzitari, D., Mascalchi, M., 2007. Whole-brain histogram and voxel-based analyses of diffusion tensor imaging in patients with leukoaraiosis: correlation with motor and cognitive impairment. *A.J.N.R. Am. J. Neuroradiol.* 28 (7), 1313–1319. <http://dx.doi.org/10.3174/ajnr.A055517698534>.
- Dziedzic, T., Metz, I., Dallenga, T., König, F.B., Müller, S., Stadelmann, C., Brück, W., 2010. Wallerian degeneration: a major component of early axonal pathology in multiple sclerosis. *Brain Pathol.* 20 (5), 976–985. <http://dx.doi.org/10.1111/j.1750-3639.2010.00401.x20477831>.
- Erkinjuntti, T., 2002. Subcortical vascular dementia. *Cerebrovasc. Dis.* 13 (Suppl. 2), 58–60. <http://dx.doi.org/10.1159/00006119012451> [PubMed: 119012451].
- Fazekas, F., Chawluk, J.B., Alavi, A., Hurtig, H.I., Zimmerman, R.A., 1987. MR signal abnormalities at 1.5 T in Alzheimer's dementia and normal aging. *A.J.R. Am. J. Roentgenol.* 149 (2), 351–356. <http://dx.doi.org/10.2214/ajr.149.2.3513496763>.
- Fryer, S.L., Frank, L.R., Spadoni, A.D., Theilmann, R.J., Nagel, B.J., Schweinsburg, A.D., Tapert, S.F., 2008. Microstructural integrity of the corpus callosum linked with neuropsychological performance in adolescents. *Brain Cogn.* 67 (2), 225–233. <http://dx.doi.org/10.1016/j.bandc.2008.01.00918346830>.
- Gons, R.A., van Oudheusden, L.J., de Laat, K.F., van Norden, A.G., van Uden, I.W., Norris, D.G., Zwiers, M.P., van Dijk, E., de Leeuw, F.E., 2012. Hypertension is related to the microstructure of the corpus callosum: the RUN DMC study. *J. Alzheimers Dis.* 32 (3), 623–631. <http://dx.doi.org/10.3233/JAD-2012-12100622869466>.
- Grafton, S.T., Sumi, S.M., Stimac, G.K., Alvord Jr., E.C., Shaw, C.M., Nochlin, D., 1991. Comparison of postmortem magnetic resonance imaging and neuropathologic findings in the cerebral white matter. *Arch. Neurol.* 48 (3), 293–298. <http://dx.doi.org/10.1001/archneur.1991.005301500610191705796>.
- Huang, H., Zhang, J., Jiang, H., Wakana, S., Poetscher, L., Miller, M.I., van Zijl, P.C., Hillis, A.E., Wytko, R., Mori, S., 2005. DTI tractography based parcellation of white matter: application to the mid-sagittal morphology of corpus callosum. *Neuroimage* 26 (1), 195–205. <http://dx.doi.org/10.1016/j.neuroimage.2005.01.01915862219>.
- Jokinen, H., Ryberg, C., Kalsa, H., Ylikoski, R., Rostrup, E., Stegmann, M.B., Waldemar, G., Madureira, S., Ferro, J.M., van Straaten, E.C., Scheltens, P., Barkhof, F., Fazekas, F., Schmidt, R., Carlucci, G., Pantoni, L., Inzitari, D., Erkinjuntti, T., LADIS group, 2007. Corpus callosum atrophy is associated with mental slowing and executive deficits in subjects with age-related white matter hyperintensities: the LADIS Study. *J. Neurol. Neurosurg. Psychiatr.* 78 (5), 491–496. <http://dx.doi.org/10.1136/jnnp.2006.09679217028118>.
- Mahoney, F.I., Barthel, D.W., 1965. Functional evaluation: the Barthel Index: a simple index of independence useful in scoring improvement in the rehabilitation of the chronically ill. *Maryland State Med. J.* 14, 61–65.
- Nichols, T.E., Holmes, A.P., 2002. Nonparametric permutation tests for functional neuroimaging: a primer with examples. *Hum. Brain Mapp.* 15 (1), 1–25. <http://dx.doi.org/10.1002/hbm.105811747097>.
- Nitkunan, A., Charlton, R.A., McIntyre, D.J., Barrick, T.R., Howe, F.A., Markus, H.S., 2008. Diffusion tensor imaging and MR spectroscopy in hypertension and presumed cerebral small vessel disease. *Magn. Reson. Med.* 59 (3), 528–534. <http://dx.doi.org/10.1002/mrm.2146118224697>.
- O'Sullivan, M., Jones, D.K., Summers, P.E., Morris, R.G., Williams, S.C., Markus, H.S., 2001a. Evidence for cortical "disconnection" as a mechanism of age-related cognitive decline. *Neurology* 57 (4), 632–638. <http://dx.doi.org/10.1212/WNL.57.4.63211524471>.
- O'Sullivan, M., Morris, R.G., Huckstep, B., Jones, D.K., Williams, S.C., Markus, H.S., 2004. Diffusion tensor MRI correlates with executive dysfunction in patients with ischaemic leukoaraiosis. *J. Neurol. Neurosurg. Psychiatry* 75 (3), 441–447. <http://dx.doi.org/10.1136/jnnp.2003.01491014966162>.
- O'Sullivan, M., Summers, P.E., Jones, D.K., Jarosz, J.M., Williams, S.C., Markus, H.S., 2001b. Normal-appearing white matter in ischemic leukoaraiosis: a diffusion tensor MRI study. *Neurology* 57 (12), 2307–2310. <http://dx.doi.org/10.1212/WNL.57.12.230711756617>.
- Pasi, M., Salvadori, E., Poggesi, A., Ciolli, L., Del Bene, A., Marini, S., Nannucci, S., Pescini, F., Valenti, R., Ginestroni, A., Toschi, N., Diciotti, S., Mascalchi, M., Inzitari, D., Pantoni, L., VMCI Study Investigators, 2015. White matter microstructural damage in small vessel disease is associated with Montreal cognitive assessment but not with mini mental state examination performances: vascular mild cognitive impairment Tuscany study. *Stroke* 46 (1), 262–264. <http://dx.doi.org/10.1161/STROKEAHA.114.00755325395414>.
- Pierpaoli, C., Jezzard, P., Basser, P.J., Barnett, A., Di Chiro, G., 1996. Diffusion tensor MR imaging of the human brain. *Radiology* 201 (3), 637–648. <http://dx.doi.org/10.1148/radiology.201.3.89392098939209>.
- Radloff, L.S., 1977. The CES-D Scale: a self-report depression scale for research in the general population. *Appl. Psychol. Meas.* 1 (3), 385–401. <http://dx.doi.org/10.1177/014662167700100306>.
- Román, G.C., Erkinjuntti, T., Wallin, A., Pantoni, L., Chui, H.C., 2002. Subcortical ischaemic vascular dementia. *Lancet Neurol.* 1 (7), 426–436. [http://dx.doi.org/10.1016/S1474-4422\(02\)00190-142849365](http://dx.doi.org/10.1016/S1474-4422(02)00190-142849365).
- Rosendorff, C., 2007. Hypertension and coronary artery disease: a summary of the American Heart Association scientific statement. *J. Clin. Hypertens.* (Greenwich) 9 (10), 790–795. <http://dx.doi.org/10.1111/j.1751-7176.2007.tb00066.x17917507>.
- Sen, P.N., Basser, P.J., 2005. A model for diffusion in white matter in the brain. *Biophys. J.* 89 (5), 2927–2938. <http://dx.doi.org/10.1529/biophysj.105.06301616100258>.
- Sepulcre, J., Masdeu, J.C., Sastre-Garriga, J., Goñi, J., Vélaz-de-Mendizábal, N., Duque, B., Pastor, M.A., Bejarano, B., Villoslada, P., 2008. Mapping the brain pathways of declarative verbal memory: evidence from white matter lesions in the living human brain. *Neuroimage* 42 (3), 1237–1243. <http://dx.doi.org/10.1016/j.neuroimage.2008.05.03818585467>.
- Smith, S.M., Jenkinson, M., Johansen-Berg, H., Rueckert, D., Nichols, T.E., Mackay, C.E., Watkins, K.E., Ciccarelli, O., Cader, M.Z., Matthews, P.M., Behrens, T.E., 2006. Tract-based spatial statistics: voxelwise analysis of multi-subject diffusion data. *Neuroimage* 31 (4), 1487–1505. <http://dx.doi.org/10.1016/j.neuroimage.2006.02.02416624579>.
- Smith, S.M., Nichols, T.E., 2009. Threshold-free cluster enhancement: addressing problems of smoothing, threshold dependence and localisation in cluster inference. *Neuroimage* 44 (1), 83–98. <http://dx.doi.org/10.1016/j.neuroimage.2008.03.06118501637>.
- Thomalla, G., Glauche, V., Koch, M.A., Beaulieu, C., Weiller, C., Röther, J., 2004. Diffusion tensor imaging detects early Wallerian degeneration of the pyramidal tract after ischemic stroke. *Neuroimage* 22 (4), 1767–1774. <http://dx.doi.org/10.1016/j.neuroimage.2004.03.04115275932>.
- Topkian, R., Barrick, T.R., Howe, F.A., Markus, H.S., 2010. Blood-brain barrier permeability is increased in normal-appearing white matter in patients with lacunar stroke and leukoaraiosis. *J. Neurol. Neurosurg. Psychiatry* 81 (2), 192–197. <http://dx.doi.org/10.1136/jnnp.2009.17207219710048>.
- Van der Holst, H.M., Tuladhar, A.M., van Norden, A.G., de Laat, K.F., van Uden, I.W., van Oudheusden, L.J., Zwiers, M.P., Norris, D.G., Kessels, R.P., de Leeuw, F.E., 2013. Microstructural integrity of the cingulum is related to verbal memory performance in elderly with cerebral small vessel disease: the RUN DMC study. *Neuroimage* 65, 416–423. <http://dx.doi.org/10.1016/j.neuroimage.2012.09.06023032491>.
- Van Norden, A.G., de Laat, K.F., Gons, R.A., van Uden, I.W., van Dijk, E.J., van Oudheusden, L.J., Esselink, R.A., Bloem, B.R., van Engelen, B.G., Zwarts, M.J., Tendolkar, I., Olde-

- Rikkert, M.G., van der Vlugt, M.J., Zwiers, M.P., Norris, D.G., de Leeuw, F.E., 2011. Causes and consequences of cerebral small vessel disease. The RUN DMC study: a prospective cohort study. Study rationale and protocol. *B.M.C. Neurol.* 11, 29. <http://dx.doi.org/10.1186/1471-2377-11-2921356112>.
- Van Norden, A.G., de Laat, K.F., van Dijk, E.J., van Uden, I.W., van Oudheusden, L.J., Gons, R.A., Norris, D.G., Zwiers, M.P., de Leeuw, F.E., 2012. Diffusion tensor imaging and cognition in cerebral small vessel disease: the RUN DMC study. *Biochim. Biophys. Acta* 1822 (3), 401–407. <http://dx.doi.org/10.1016/j.bbadis.2011.04.00821549191>.
- Vermeer, S.E., Prins, N.D., den Heijer, T., Hofman, A., Koudstaal, P.J., Breteler, M.M., 2003. Silent brain infarcts and the risk of dementia and cognitive decline. *N. Engl. J. Med.* 348 (13), 1215–1222. <http://dx.doi.org/10.1056/NEJMoa02206612660385>.
- Vernooij, M.W., de Groot, M., van der Lugt, A., Ikram, M.A., Krestin, G.P., Hofman, A., Niessen, W.J., Breteler, M.M., 2008. White matter atrophy and lesion formation explain the loss of structural integrity of white matter in aging. *Neuroimage* 43 (3), 470–477. <http://dx.doi.org/10.1016/j.neuroimage.2008.07.05218755279>.
- Vernooij, M.W., Ikram, M.A., Tanghe, H.L., Vincent, A.J., Hofman, A., Krestin, G.P., Niessen, W.J., Breteler, M.M., van der Lugt, A., 2007. Incidental findings on brain MRI in the general population. *N. Engl. J. Med.* 357 (18), 1821–1828. <http://dx.doi.org/10.1056/NEJMoa07097217978290>.
- Vernooij, M.W., Ikram, M.A., Vrooman, H.A., Wielopolski, P.A., Krestin, G.P., Hofman, A., Niessen, W.J., Van der Lugt, A., Breteler, M.M., 2009. White matter microstructural integrity and cognitive function in a general elderly population. *Arch. Gen. Psychiatry* 66 (5), 545–553. <http://dx.doi.org/10.1001/archgenpsychiatry.2009.519414714>.
- Wardlaw, J.M., Smith, E.E., Biessels, G.J., Cordonnier, C., Fazekas, F., Frayne, R., Lindley, R.I., O'Brien, J.T., Barkhof, F., Benavente, O.R., Black, S.E., Brayne, C., Breteler, M., Chabriat, H., Decarli, C., de Leeuw, F.E., Doubal, F., Duering, M., Fox, N.C., Greenberg, S., Hachinski, V., Kilimann, I., Mok, V., Oostenbrugge, R., Pantoni, L., Speck, O., Stephan, B.C., Teipel, S., Viswanathan, A., Werring, D., Chen, C., Smith, C., van Buchem, M., Norrving, B., Gorelick, P.B., Dichgans, M., Standards for Reporting Vascular changes on nEuroimaging (STRIVE v1), 2013. Neuroimaging standards for research into small vessel disease and its contribution to ageing and neurodegeneration. *Lancet Neurol.* 12 (8), 822–838. [http://dx.doi.org/10.1016/S1474-4422\(13\)70124-823867200](http://dx.doi.org/10.1016/S1474-4422(13)70124-823867200).
- Xu, Q., Zhou, Y., Li, Y.S., Cao, W.W., Lin, Y., Pan, Y.M., Chen, S.D., 2010. Diffusion tensor imaging changes correlate with cognition better than conventional MRI findings in patients with subcortical ischemic vascular disease. *Dement. Geriatr. Cogn. Disord.* 30 (4), 317–326. <http://dx.doi.org/10.1159/00032049120881397>.
- Zhuang, L., Wen, W., Zhu, W., Trollor, J., Kochan, N., Crawford, J., Reppermund, S., Brodaty, H., Sachdev, P., 2010. White matter integrity in mild cognitive impairment: a tract-based spatial statistics study. *Neuroimage* 53 (1), 16–25. <http://dx.doi.org/10.1016/j.neuroimage.2010.05.06820595067>.
- Zwiers, M.P., 2010. Patching cardiac and head motion artefacts in diffusion-weighted images. *Neuroimage* 53 (2), 565–575. <http://dx.doi.org/10.1016/j.neuroimage.2010.06.01420600997>.