

PDF hosted at the Radboud Repository of the Radboud University Nijmegen

The following full text is a publisher's version.

For additional information about this publication click this link.

<http://hdl.handle.net/2066/119183>

Please be advised that this information was generated on 2021-01-20 and may be subject to change.

Recurrent syncope: a slow heart rate?

M. Boulaksil · D. Robbers-Visser · S. Westra ·
J. L. Smeets

Published online: 14 July 2013

© The Author(s) 2013. This article is published with open access at Springerlink.com

A 70-year-old female patient was admitted to the geriatrics department with an overall deterioration, including lethargy, and with recurrent syncope. She had no palpitations or chest pain or other symptoms preceding the syncopal episodes. She is known with a history of an anterior myocardial infarction more than 20 years ago and psychotic depression. Her current medication consisted of lithium 400 mg, olanzapine 10 mg and nortriptyline 50 mg, all once a day,

along with cardiac medication. Physical examination, initial laboratory tests and echocardiography did not demonstrate any abnormalities.

A 12-lead surface electrocardiogram on admission is shown in Fig. 1. What is your diagnosis?

Answer

You will find the answer elsewhere in this issue.

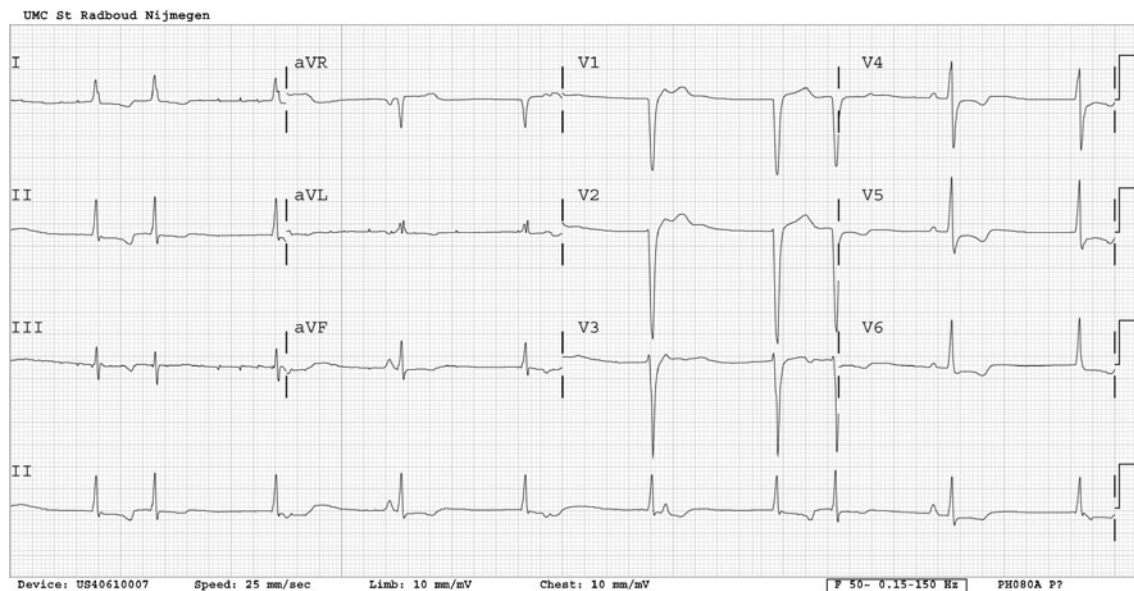


Fig. 1 Twelve-lead surface electrocardiogram on admission

M. Boulaksil (✉) · D. Robbers-Visser · S. Westra · J. L. Smeets
Department of Cardiology 670, Radboud University
Nijmegen Medical Centre, PO Box 9101,
6500 HB Nijmegen, the Netherlands
e-mail: m.boulaksil@gmail.com

Open Access This article is distributed under the terms of the Creative Commons Attribution License which permits any use, distribution, and reproduction in any medium, provided the original author(s) and the source are credited.