

The Journal of Laryngology & Otology

<http://journals.cambridge.org/JLO>


Additional services for *The Journal of Laryngology & Otology*:

Email alerts: [Click here](#)

Subscriptions: [Click here](#)

Commercial reprints: [Click here](#)

Terms of use : [Click here](#)



Two siblings with progressive, fluctuating hearing loss after head trauma, treated with cochlear implantation

M J F de Wolf, J Honings, F B M Joosten, L Hoefsloot, E A M Mylanus and C W R J Cremers

The Journal of Laryngology & Otology / Volume 124 / Issue 01 / January 2010, pp 86 - 89

DOI: 10.1017/S0022215109990296, Published online: 23 June 2009

Link to this article: http://journals.cambridge.org/abstract_S0022215109990296

How to cite this article:

M J F de Wolf, J Honings, F B M Joosten, L Hoefsloot, E A M Mylanus and C W R J Cremers (2010). Two siblings with progressive, fluctuating hearing loss after head trauma, treated with cochlear implantation. The Journal of Laryngology & Otology, 124, pp 86-89 doi:10.1017/S0022215109990296

Request Permissions : [Click here](#)

Two siblings with progressive, fluctuating hearing loss after head trauma, treated with cochlear implantation

M J F DE WOLF, J HONINGS, F B M JOOSTEN*, L HOEFSLOOT†, E A M MYLANUS, C W R J CREMERS

Abstract

Objective: Description of two siblings with unexplained, progressive, perceptive hearing loss after head trauma.

Design: Case report.

Subjects: Two siblings aged six and eight years old with bilateral, intermittent but progressive hearing loss.

Results: These patients had a c.1172G>A (p.Ser391Asn) mutation in the *SLC26A4* gene, which has not previously been reported and which caused Pendred or enlarged vestibular aqueduct syndrome. The diagnosis was based on the perceptive hearing loss, computed tomography findings and mutation analysis. The patients were each fitted with a cochlear implant because of their severe, progressive, perceptive hearing loss with deep fluctuations. The results were good.

Conclusion: Further testing for the presence of an enlarged vestibular aqueduct is recommended when children present with sudden progression in perceptive hearing loss, whether or not in combination with head trauma. Cochlear implantation is indicated in patients with persistent, progressive hearing loss that leads to deafness. Implantation can be undertaken successfully despite cochlear hypoplasia.

Key words: Pendrin protein; Sensorineural Hearing Loss; Head Injury; Child; Diagnosis

Introduction

When perceptive hearing loss in children follows a fluctuating course, it may have a hereditary cause. Besides DFNB1 (CX26, CX30), the most common hereditary form of hearing loss or deafness in childhood is the Pendred or enlarged vestibular aqueduct syndrome. This syndrome is estimated to account for 4.3–7.5 per cent of all cases of early childhood perceptive hearing loss or deafness.¹

Pendred syndrome was first described in 1896 by Vaughan Pendred, as persistent deafness in children combined with Goitre.² It comprises an autosomal recessive hereditary disorder which was originally characterised as perceptive hearing loss and disturbed thyroxin synthesis.^{3,4} In about 80 per cent of Pendred syndrome patients, struma develops in the first 10 to 20 years of life.⁵ As a result of partial deficiency in the organification of iodine, the perchlorate test is generally positive. Later, enlargement of the vestibular aqueduct became a more or less obligatory characteristic for diagnosis of the syndrome, in addition to perceptive hearing loss. After the recognition of mutations in the *SLC26A4* gene as the cause for the Deafness, it appeared that mutations in the same gene were also responsible for the enlarged vestibular aqueduct syndrome. Thus, the clinical spectrum of Pendred or enlarged vestibular aqueduct syndrome expanded.

This case report describes a patient with unexplained perceptive hearing loss and post-traumatic progression. Enlarged vestibular aqueduct syndrome was suspected. With the aid of computed tomography (CT) scanning of

the petrous bones and mutation analysis to detect the *SLC26A4* gene, the diagnosis was confirmed.

Case report

A six-year-old girl was referred to the Radboud University Medical Centre (UMC) Nijmegen ENT out-patient clinic because of bilateral, intermittent but progressive, perceptive hearing loss. Anamnesis revealed that, during episodes of diminished hearing, the child was also less secure on her feet. Her parents reported that there were periods of several days when she was profoundly deaf and unable to walk. Notably, the hearing loss had deteriorated following head trauma.

The patient's ENT medical history was negative for otitis media. Bilateral otoscopic findings were normal. The girl's hearing seemed normal until she failed the Ewing test. At the age of one and a half years, she had responded only to stimuli of 60–70 dB in the free field hearing test. Brainstem evoked response audiometry had confirmed bilateral perceptive hearing loss of about 60 dB. After bilateral hearing aid fitting at the age of two years, the patient's speech perception had improved strongly. At the age of four years and two months, her hearing loss had been 63 dB in the right ear and 77 dB in the left ear. At the age of five and a half years, these values had increased to >110 dB and 90 dB, respectively. At this time, speech perception was a maximum of 75 per cent at 95 dB with the hearing aid in the patient's left ear. Figure 1 shows the course of the patient's hearing loss over time. Figure 2

From the Department of Otorhinolaryngology, Donders Centre of Neuroscience, and the †Department of Human Genetics, Radboud University Nijmegen Medical Center, and the *Department of Radiology, Alysis Zorggroep, Location Rijnstate, Arnhem, The Netherlands.

Accepted for publication: 11 February 2009. First published online 23 June 2009.

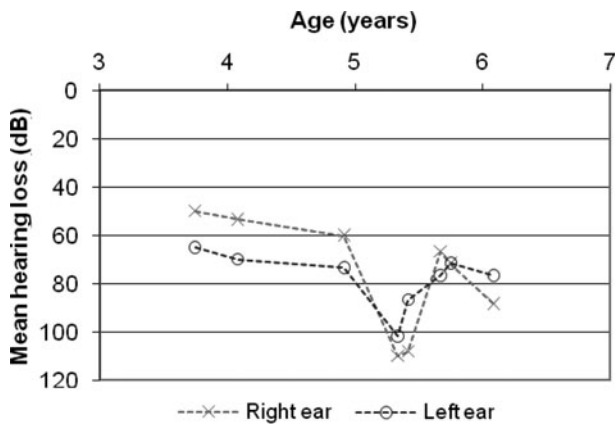


FIG. 1

Mean hearing loss in the patient's right and left ears over time (for 0.5, 1 and 2 kHz).

shows the course of the hearing loss over time for each ear. Vestibular testing at the age of five years, with the aid of electronystagmography and a rotatory chair, showed normal vestibular function. A general physical examination did not reveal any signs of struma.

Family anamnesis showed that the patient's parents were second cousins of Caucasian origin, without any hearing impairment. The patient's sister (two years older) was known to have asymmetrical, stable, perceptive deafness (Fletcher index of 90 dB on the right and 55 dB on the left).

The patient's fluctuating and progressive hearing loss, her unsteady balance and the occurrence of head trauma as a possible initiating factor prompted suspicion of enlarged vestibular aqueducts. Computed tomography scanning of the petrous bones revealed salient bilateral

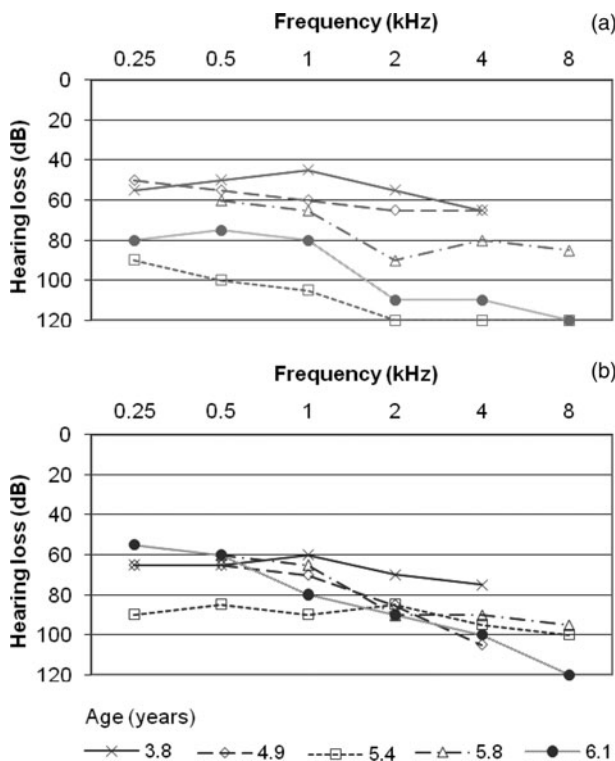
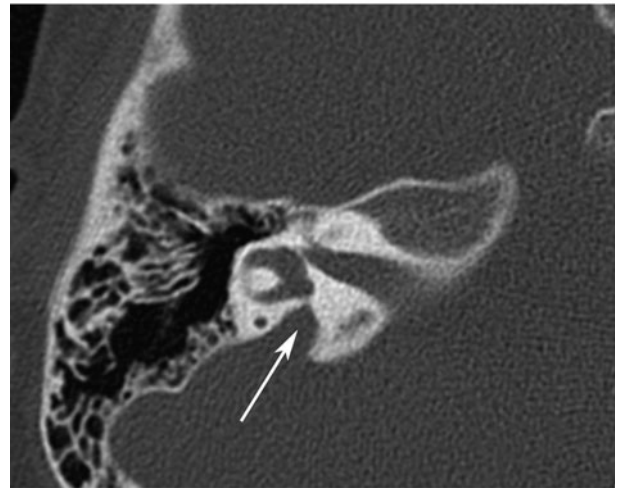
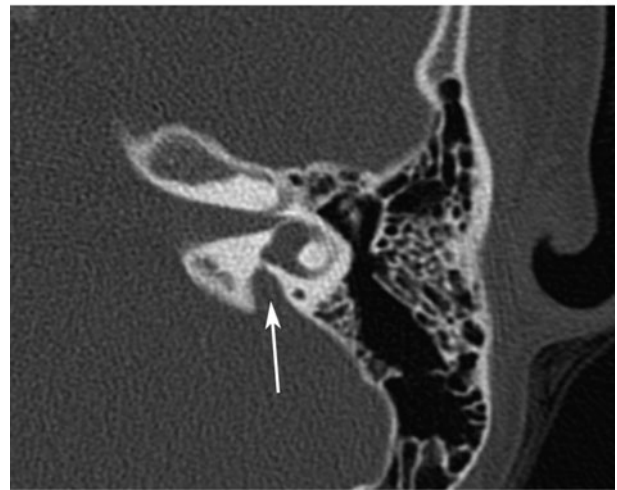


FIG. 2

Audiometric results in the patient's (a) right and (b) left ear, for various frequencies over time.



(a)



(b)

FIG. 3

Axial, high resolution computed tomography scan of the patient's temporal bones at the level of the vestibulum, showing enlarged vestibular ducts of (a) 4.6 mm on the right and (b) 2.5 mm on the left (arrows). A vestibular duct diameter of 1.5 mm is normal (measured at the centre of the duct).¹⁴

enlargement of the endolymphatic ducts and an incomplete number of turns in both cochleae (Figure 3). The fact that the patient's parents were second cousins and that their only other child had hearing impairment made it very likely that there was an autosomal recessive predisposition.

Mutation analysis identified a homozygous missense mutation (c.1172G>A (p.Ser391Asn)) in the *SLC26A4* gene in both the patient and her sister. Both parents appeared to be heterozygous carriers of the same mutation. This mutation has not previously been described. It concerns a relatively drastic change in the amino acid configuration of a conservative part of the protein. The diagnosis of Pendred or enlarged vestibular aqueduct syndrome was ultimately proven by mutation analysis.

It was decided to fit the patient with a cochlear implant (CI) on the right side (contralateral to the existing hearing aid) at the age of seven years and six months, because of her severe, progressive, perceptive hearing loss with deep fluctuations. Two months after implantation,

the patient's word score and speech score on the monosyllable identification test were 76 per cent. Six months post-implantation, her word and speech scores were 100 per cent at 60 dB and her Fletcher index was 25 dB. At one year and two months post-implantation, the patient's phoneme score with the CI increased to 91 per cent, while her Fletcher index remained stable at 25 dB.

The patient's thyroid levels were analysed at the age of seven years: her thyroid-stimulating hormone (TSH) level was 2.2 mU/l and her thyroxine concentration was 20 mU/l. The patient was referred to a paediatrician to monitor her thyroid biochemistry.

The patient's sister

The patient's sister was also diagnosed with Pendred syndrome. After a long period of stability, her hearing loss also deteriorated dramatically after head trauma, fluctuated and then gradually improved (with a Fletcher index of 93 dB on the right and 103 dB on the left). With the right hearing aid alone, this girl's speech recognition was 54 per cent, compared with 9 per cent with the left hearing aid alone. With bilateral hearing aids, her phoneme score was 75 per cent at 70 dB.

This patient received a CI at the age of 10 years. Two months after implantation, she achieved a phoneme score of 89 per cent at 70 dB with the CI. The scores with the CI were higher than the scores with her bilateral hearing aids immediately before implantation, and in agreement with the expectations of the audiological scores at that level of hearing loss.

At the age of 9.2 years, thyroid gland analysis for this patient showed a TSH level of 1.4 mU/l and a thyroxine concentration of 18 mU/l.

Discussion

Fluctuating, progressive, perceptive hearing loss in childhood or adolescence is a typical presentation in patients with enlarged vestibular aqueduct syndrome. In the present case, there was salient bilateral enlargement of the endolymphatic ducts and an incomplete number of turns in both cochleae (Mondini's malformation). Episodes of head trauma were invariably followed by periods of partial, transient deterioration of the perceptive hearing loss. Our patient's vertigo was also transitory.

The clinical presentation of patients with *SLC26A4* gene mutations is variable. Features range from nonsymptomatic, autosomal recessive, perceptive hearing impairment with enlarged vestibular aqueducts (DFNB4) to classical Pendred syndrome (profound childhood perceptive deafness and the development of struma in early childhood or adolescence). Azaiez *et al.* found that the hearing loss in patients with two mutant *SLC26A4* alleles was more severe than that in patients with no mutations or one mutant allele.⁶ Diverse mutations were found to be associated with different phenotypes and varying degrees of inner-ear pathology.⁶ Ongoing research into genotype-phenotype correlations in the most common *SLC26A4* mutations ('hotspot mutations') could help to match clinical and pathological features to specific mutations.

In the present case, a new mutation (c.1172G>A (p.Ser391Asn)) was found in the *SLC26A4* gene. In 1997, Pendred syndrome was discovered to be caused by mutations in the *SLC26A4* gene on the long arm of chromosome seven, which encodes for the transmembrane protein pendrin.⁷ Expression of pendrin was found in the endolymphatic duct and sac, where it probably plays a role in the regulation of endolymph composition, as a transmembrane anion transporter.⁸

There is considerable overall variation in the severity of the symptomatology of Pendred or enlarged vestibular aqueduct syndrome. For instance, the present case showed rapid progression of hearing loss over only a few years. Pendred syndrome patients generally have fluctuating, progressive, moderate to severe, perceptive hearing loss and disequilibrium symptoms.⁹ The syndrome can also be expressed as total deafness in early childhood, or sudden deafness in one ear in adolescence. The classical form of Pendred syndrome comprises severe early childhood deafness, cochlear dysplasia and enlarged endolymphatic ducts, with or without struma.^{5,10} Struma and decreased thyroid function can occur in approximately 50–80 per cent of children with Pendred or enlarged vestibular aqueduct syndrome.^{1,5}

It is assumed that one of the functions of the vestibular aqueduct is to minimise differences in intracranial pressure. An increase in intracranial pressure in an enlarged aqueduct, such as occurs in Pendred syndrome, may have a stronger effect on the cochlea than in vestibular aqueducts of normal diameter. Head trauma may cause a shockwave of endolymph from the endolymphatic sac through the duct into the vestibulum. Mixing of endolymph from the sac and duct with endolymph in the cochlea, which has different ion concentrations, may disrupt the action potential in the cochlea. In time, this may lead to progression of hearing loss. This might explain why head trauma in Pendred syndrome patients can cause deterioration in hearing loss. Jackler and De La Cruz observed the same clinical features and CT abnormalities in patients with enlarged vestibular aqueduct syndrome.¹¹ In an earlier report, the hearing loss in patients with enlarged vestibular aqueduct syndrome was described as progressive and stepwise, often triggered by relatively mild head trauma.¹² As yet, no studies have confirmed a correlation between the diameter of the vestibular aqueduct and the deterioration in hearing loss after head trauma. However, a recent study showed that the diagnosis of Pendred syndrome was related to poorer prognosis following hearing loss.¹³

- **This paper presents the natural course of hearing impairment in two siblings with Pendred syndrome, including deterioration following head injury**
- **Cochlear implantation can be undertaken successfully in this condition, despite cochlear hypoplasia**
- **A new mutation of the gene responsible for the enlarged vestibular aqueduct or Pendred syndrome is presented**
- **The authors discuss how to reach an early and correct otological and genetic diagnosis in such patients**

Cochlear implantation is indicated for persistent, progressive hearing loss that leads to deafness, and it can be applied successfully despite cochlear hypoplasia.¹⁴

Conclusion

When a child presents with sudden progression of perceptive hearing loss, imaging of the cochlea is indicated to detect or exclude enlargement of the vestibular aqueducts and hypoplasia of the cochlea.

When enlargement of the vestibular aqueducts is found, whether or not upon routine diagnostic preparation for cochlear implantation, *SLC26A4* gene mutation analysis is recommended to confirm the diagnosis and to identify any

autosomal recessive predisposition. Genetic counselling is then worthwhile in order to discuss such issues as the cause of symptoms. Nowadays, mutation analyses form part of the routine deoxyribonucleic acid diagnostic procedure.

Patients with enlarged endolymphatic ducts should be advised to avoid head trauma. This can be achieved by avoiding contact sports and other high risk activities. Referral to a paediatrician is recommended to analyse thyroid function. Supplementary thyroid hormones can be administered to treat hypothyroidism, and may even prevent struma. Cochlear implantation is indicated in patients with persistent, progressive hearing loss that leads to deafness. It can be applied successfully despite cochlear hypoplasia.¹⁵

References

- Fraser GR. Association of congenital deafness with goitre (Pendred's syndrome): a study of 207 families. *Ann Hum Genet* 1965;**28**:201–49
- Pendred V. Deaf-mutism and goitre. *Lancet* 1896;**ii**(Suppl. 2):532
- Deraemaeker R. Congenital deafness and goiter. *Am J Hum Genet* 1956;**8**:253–6
- Morgans ME, Trotter WR. Association of congenital deafness with goitre; the nature of the thyroid defect. *Lancet* 1958;**i**:607–9
- Cremers CWRJ, Admiraal RCJ, Huygen PLM, Bolder C, Everett LA, Joosten FBM *et al.* Progressive hearing loss, hypoplasia of the cochlea and widened vestibular aqueducts are very common features in Pendred's syndrome. *Int J Pediatr Otorhinolaryngol* 1998;**45**:113–23
- Azaiez H, Yang T, Prasad S, Sorensen JL, Nishimura CJ, Kimberling WJ *et al.* Genotype-phenotype correlations for SLC26A4-related deafness. *Hum Genet* 2007;**122**:451–7
- Everett LA, Glaser B, Beck JC, Idol JR, Buchs A, Heyman M *et al.* Pendred syndrome is caused by mutations in a putative sulphate transporter gene (PDS). *Nat Genet* 1997;**17**:411–22
- Everett LA, Morsli H, Wu DK, Green ED. Expression pattern of the mouse ortholog of the Pendred's syndrome gene (Pds) suggests a key role for pendrin in the inner ear. *Proc Natl Acad Sci U S A* 1999;**96**:9727–32
- Kunst HPM, Kremer H, Cremers CWRJ. Inherited syndromic hearing impairment. *Genetics for ENT Specialists*. London: Remedica, 2004;57–127
- Phelps PD, Coffey RA, Trembath RC, Luxon LM, Grossman AB, Britton KE *et al.* Radiological malformations of the ear in Pendred syndrome. *Clin Radiol* 1998;**53**:268–73
- Jackler RK, De La Cruz A. The large vestibular aqueduct syndrome. *Laryngoscope* 1989;**99**:1238–42
- Carlborg BI, Farmer JC Jr. Transmission of cerebrospinal fluid pressure via the cochlear aqueduct and endolymphatic sac. *Am J Otolaryngol* 1983;**4**:273–82
- Colvin IB, Beale T, Harrop-Griffiths K. Long-term follow-up of hearing loss in children and young adults with enlarged vestibular aqueducts: relationship to radiologic findings and Pendred syndrome diagnosis. *Laryngoscope* 2006;**116**:2027–36
- Valvassori GE, Clemis JD. The large vestibular aqueduct syndrome. *Laryngoscope* 1978;**88**:723–8
- Mylanus EA, Rotteveel LJ, Leeuw RL. Congenital malformation of the inner ear and pediatric cochlear implantation. *Otol Neurotol* 2004;**25**:308–17

Address for correspondence:
Dr M J F de Wolf,
Department of Otorhinolaryngology,
Radboud University Nijmegen Medical Centre,
PO Box 9101, 6500 HB, Nijmegen, The Netherlands.

Fax: 0031 24 354 02 51
E-mail: m.dewolf@kno.umcn.nl

Dr M J F de Wolf takes responsibility for the integrity of the content of the paper.
Competing interests: None declared
