

Expression of NF- κ B and COX-2 in Young Versus Older Patients with Sporadic Colorectal Cancer

Murdani Abdullah*, Aru W. Sudoyo*, Bethy S. Pranowo**, Diah Rini***, Bambang Sutrisna****, A. Aziz Rani*

* Department of Internal Medicine, Faculty of Medicine University of Indonesia - dr. Cipto Mangunkusumo Hospital, Jl. Diponegoro no. 71, Jakarta 10430, Indonesia.

** Department of Anatomical Pathology, Faculty of Medicine, Padjadjaran University - Hasan Sadikin Hospital, Bandung

*** Department of Anatomical Pathology, Faculty of Medicine, University of Indonesia - dr. Cipto Mangunkusumo Hospital, Jakarta. **** Department of Clinical Epidemiology, Faculty of Public Health, University of Indonesia, Depok.

Correspondence mail to: murdani@hotmail.com.

ABSTRACT

Aim: to distinguish the expression of NF- κ B and COX-2 between young and older group of sporadic colorectal cancer patients.

Methods: this was a comparative study between sporadic CRC patients aged 40 years or younger and patients aged 60 years or more. Expression of NF- κ B and COX-2 were assessed by immunohistochemical method using rabbit polyclonal antibodies against human p65 NF- κ B and COX-2 proteins.

Results: there were 98 cases of sporadic colorectal cancers between 1999 and 2007 obtained from the Department of Anatomical Pathology, Faculty of Medicine University of Indonesia, Jakarta and Department of Anatomical Pathology, Faculty of Medicine Padjadjaran University, Bandung. There were 60 patients aged 60 years or more and 38 patients aged 40 years or less. Most tumors were located in the distal colon. Positive expression of NF- κ B was found in 72 (73.5%) cases, whereas COX-2 expression was found in 48 (49.0%) cases. No significant difference of NF- κ B and COX-2 expression between young and older patients.

Conclusion: the expression of nuclear factor κ B (NF- κ B) in Indonesian patients with sporadic colorectal cancer was high. However, cyclooxygenase-2 (COX-2) was only expressed in half of patients. There was no significant difference of NF- κ B and COX-2 expressions between patients aged 40 years or less and patients aged 60 years or more. Further studies are needed to elaborate the role of inflammation in sporadic colorectal carcinogenesis.

Key words: sporadic colorectal cancer, young patient, inflammation, NF- κ B, COX-2.

INTRODUCTION

The prevalence of colorectal cancer (CRC) in Western population aged 50 years or less was 2-8%.^{1,2} However, epidemiological data in Indonesia has shown that the proportion of CRC patients aged 40 years or less was higher (more than 30%).³ Furthermore, studies in developed countries found that young onset CRC often associated with a positive family history.^{4,5} The pathogenesis of familial or hereditary CRC involved germ-line mutations of the so-called mismatch repair (MMR) genes and was named microsatellite instability pathway.⁶ In contrast, sporadic CRC follow chromosomal instability (CIN) pathway⁷ that involved somatic mutation in adenomatous poliposis coli (APC) gene and other mutations which has been described as adenoma-carcinoma sequence.⁸ Previous study in Indonesian young CRC patients did not find any positive family history and the expression of MMR proteins did not differ from older patients.⁹ It seems that colorectal carcinogenesis of young patients did not differ from elder patients and might follow a sporadic pathway.

Several clinical studies in the last two decades has shown that non-steroidal anti-inflammatory steroids, i.e. sulindac and cyclooxygenase-2 (COX-2) inhibitor, reduced the number and the size of adenomatous polyps.^{10,11} Further studies has focused in the role of COX-2 enzymes in the formation of colorectal adenoma. COX-2 expression was regulated by Wnt/APC/ β -catenin pathway which is a CIN pathway. In cells with normal APC, the expression of COX-2 was reduced at the translational level.¹² Additionally, COX-2 enzyme was not expressed in 61% of CRC patients with high MSI or

negative expression of MMR proteins.¹³ COX-2 enzyme is induced by epithelial injury as part of inflammatory response to infections or other stimuli.^{14,15} Cell injury induces the synthesis of prostaglandins which require COX enzymes. COX-2 has a role in early inflammation and also in tissue recovery and could be undetectable in normal tissue.¹⁶

Mutations in sporadic cancers are believed to occur in somatic cells following exposure to environmental carcinogenic agents. One of conditions that could provide microenvironmental milieu to induce malignant transformation of epithelial cells is chronic inflammation.¹⁷ Inflammatory-induced carcinogenesis pathway involved a transcription factor called nuclear factor-kappa B (NF- κ B)¹⁸ which is an important mediator of the growth and development of inflammatory-induced tumorigenesis.¹⁹

Immunohistochemical staining of COX-2 expression has been associated with other inflammatory markers, such as interleukin (IL)-1 β , IL-6 and subunit p65 NF- κ B both in the epithelial or stromal cells.²⁰ This suggested that inflammatory process play roles in sporadic colorectal carcinogenesis although the exact mechanism is not clear and might involved dysplastic epithelial cells rather than adenoma.²¹

Molecular studies of inflammatory markers in young patients with CRC in Indonesia are limited. In particular, there is no study assessing the role of NF- κ B and COX-2 in young CRC patients. This study was aimed to explore the expression pattern NF- κ B and COX-2 in Indonesian patients and to distinguish their expressions between young and older group of patients.

METHODS

Study Design and Subjects

The study was a comparison study between colorectal cancer patients aged 40 years or less and patients aged 60 years or more. Cases were selected from medical record in the Department of Anatomical Pathology in Cipto Mangunkusumo and Hasan Sadikin Hospitals between January 1998 and April 2008. Only cases with sufficient paraffin tissue materials were enrolled in this study.

Tissue Specimens and Preparation

Tissue specimens were taken at operation for histopathological confirmation of colorectal cancer and then were fixed in 4% buffered formaldehyde and embedded in paraffin wax. Four μ m sections were cut and rinsed with cold water. Sections then were placed onto glass slides and put in warm water (50°C). Next,

slides were placed in a hot plate (70°C) for 15 minutes and then were incubated over night at 35-40°C.

Immunohistochemical Staining of NF- κ B and COX-2

The expression of NF- κ B and COX-2 was evaluated using the avidin/biotin complex immunohistochemistry procedure. Rabbit polyclonal antibodies against human COX-2 protein (Cat No.#ab15191, Abcam, UK) and human NF- κ B p65 subunit (RelA) (Cat No.#ab7970, Abcam, UK) were employed as primary antibodies.

Tissue sections were sequentially deparaffinized and rehydrated through xylene and graded alcohol solutions. Afterward, slides were pre-treated with epitope retrieval system and were pre-heated in a microwave for 5 minutes. Sections then were immersed in phosphate buffer saline (PBS) for 5 minutes. Blocking of endogenous peroxidase activity was done by immersing the sections into a solution of 3% hydrogen peroxide plus methanol (1:9) for 10 minutes in refrigerator, and then were rinsed with PBS for 5 minutes. Slides were marked by a Pap pen and then put again in PBS. Next, slides were removed from PBS and were placed in a treatment chamber. Blocking solution was applied into each sections and the chamber was closed for 10 minutes.

Primary antibodies were diluted in distilled water with 1:100 for COX-2 and 1:150 for NF- κ B. Sections were then incubated with primary antibody in the treatment chamber for 45 minutes. After washing with PBS, antibody binding was detected by incubation with bitinylated secondary antibody for 10 minutes. Then the slides were washed again with PBS and incubated with straptavidin-horse radish peroxydase. Staining was developed by applying the chromogen 3,3 diaminobenzidine in distilled water and then counterstain with hematoxylin. Finally, specimens were dehydrated and mounted. Positive and internal negative controls were included in each staining. Internal negative control sections run without the addition of primary antibodies. Positive control was fibroblast cells known to have positive COX-2 expression.

Slide Readings

Intensity of staining was divided into 4 groups: 0: no staining; 1: weak staining, 2: moderate staining, 3: strong staining. Percentage counts of stained cells were scored as 0 (0%), 1 (<25%), 2 (26-50%), 3 (51-75%), and 4 (76-100). The final score were the sum of intensity and percentage counts scores, which were between 0 and 7. Tumors having a final score 3 or more were considered positive. All immunohistochemically stained slides were reviewed by two pathologists blinded from

clinical data (kappa values were 0.831 for NF- κ B staining and 0.898 for COX-2 staining).

Data Management and Analysis

Patients' characteristics and all variables were presented descriptively. Difference between groups was tested by using Chi-square test or Fisher's exact test. A *p* value of < 0.05 was considered significant. Analysis was done using the STATA version 9.0 software (STATA Corporation, TX, USA).

RESULTS

There were 108 cases of sporadic colorectal cancers between 1999 and 2007. Paraffin block archives could be obtained in 98 patients and they were enrolled in this study. Specimens were obtained from the Department of Anatomical Pathology, Faculty of Medicine University of Indonesia, Jakarta and Department of Anatomical Pathology, Faculty of Medicine Padjajaran University, Bandung.

Most patients were women with a ratio of 1.4:1 compare to men. There were 60 patients aged 60 years or more and 38 patients aged 40 years or less. The youngest patient was 14 years old and the oldest was 89 years old. Most tumors were located in the distal colon. There was no significant difference between both groups of patients in terms of sex, tumor location, clinical stage, histopathological type and grade. (Table 1)

Positive expression of NF- κ B was found in 72 (73.5%) cases, whereas COX-2 expression was found in 48 (49.0%) cases. There was no significant difference of NF- κ B in both groups of patients. COX-2 expression tended to be higher in patients aged 40 years or less, but the difference was not statistically significant. (Table 2)

DISCUSSION

Our current study did not show a significant difference of NF- κ B expression between young and older patients. In both groups, the expression of NF- κ B was very high (73%). Study in Wuhan, China also did not find a significant difference of RelA, a component of NF- κ B, between CRC patients aged 55 years or less and patients aged more than 55 years. Both groups showed RelA expression more than 85%.²²

The expression COX-2 in our study also did not differ between young and older patients. This result is quite similar with a study in Korea which found positive COX-2 expression in 46.2% of patients aged less than 60 years and 39.4% of patients aged 60 years or more.²³

The expression of COX-2 expression in young onset sporadic CRC was only sparsely studied in Western countries. COX-2 expression was not usually associated to young age, but to the presence of microsatellite instability (MSI). A study reported that MSI

Table 1. Characteristics of patients with sporadic colorectal cancer (n=98)

Clinical characteristics	≤ 40 years (n=38)		≥ 60 years (n=60)		p value ^a
	N	%	N	%	
Sex					
♦ Male	15	39.5	26	43.3	0.706
♦ Female	23	60.5	34	56.7	
Tumor Location					
♦ Proximal	12	31.6	14	23.3	0.368
♦ Distal	26	68.4	46	76.7	
Clinical Stage (TNM)					
♦ Early (I-II)	7	18.4	17	28.3	0.338
♦ Advanced (III-IV)	31	81.6	43	71.7	
Histopathological type					
♦ Adenocarcinoma	31	81.6	58	96.7	0.026
♦ Other type of adenocarcinoma	7	18.4	2	3.3	
Histopathological grade					
♦ Good	17	44.7	43	71.7	0.001
♦ Moderate	6	15.8	12	20.0	
♦ Poor	15	39.5	5	8.3	

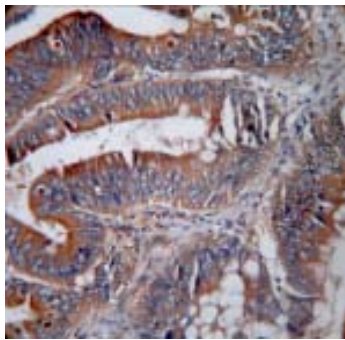
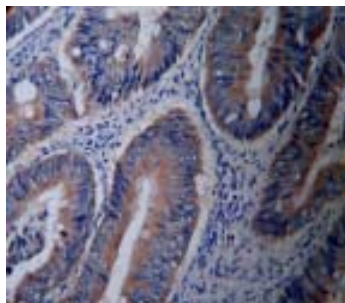
* Chi-square test

Table 2. Expression of NF- κ B and COX-2 in the study subjects

Variable	Age group		p value ^a
	≤ 40 years	≥ 60 years	
	n (%)	n (%)	
COX-2 expression			
♦ Positive	21 (55.3)	27 (45.0)	0.322
♦ Negative	17 (44.7)	33 (55.0)	
Total	38 (100)	60 (100)	
NF-κB expression			
♦ Positive	28 (73.7)	44 (73.3)	0.969
♦ Negative	10 (26.3)	16 (26.7)	
Total	38 (100)	60 (100)	

* Chi-square test

was more frequently found in patients aged 40 years or less compared to patients aged 41-60 years (18.3% vs. 6.6%; $p < 0.0001$).²⁴ Previous study in Indonesian patients found that expression of MMR proteins did not differ between young and older patients. The study evaluated two kinds of MMR proteins, namely MSH-2 and MLH-1. In both groups of patients, the expression of MSH-2 was not expressed in about 40% patients whereas MLH-1 was not expressed in more than 83% patients.²⁵ This result could be a potential explanation to the low expression of COX-2 in our current study.

**Figure 1.** Immunohistochemical staining of NF- κ B in colorectal cancer specimens (magnification x400)**Figure 2.** Immunohistochemical staining of COX-2 in colorectal cancer specimens (magnification x400)**CONCLUSION**

The expression of nuclear factor κ B (NF- κ B) in Indonesian patients with sporadic colorectal cancer was high. However, cyclooxygenase-2 (COX-2) was expressed in only about half of patients. Though there was no significant difference of NF- κ B and COX-2 expressions between patients aged 40 years or less and patients aged 60 years or more statistically, however the expression of COX-2 tend to increase among younger age. Further studies are needed to elaborate the role of inflammation in sporadic colorectal carcinogenesis.

REFERENCES

- Parramore JB, Wei JP, Yeh KA. Colorectal cancer in patients under forty: presentation and outcome. *Am Surg.* 1998;64:563-7.
- Lee PY, Fletcher WS, Sullivan ES, Vetto JT. Colorectal cancer in young patients: characteristics and outcome. *Am Surg.* 1994;60:607-12.
- Departemen, Kesehatan, RI. Laporan Tahunan Kanker: Direktorat Jendral Pelayanan Medik dan Perhimpunan Patologi Anatomik Indonesia. Jakarta: Depkes RI; 1995.
- Turkiewicz D, Miller B, Schache D, Cohen J, Theile D. Young patients with colorectal cancer: how do they fare? *ANZ J Surg.* 2001;71:707-10.
- Chung YF, Eu KW, Machin D, Ho JM, Nyam DC, Leong AF, et al. Young age is not a poor prognostic marker in colorectal cancer. *Br J Surg.* 1998;85:1255-9.
- Lynch HT, de-la-Chapelle A. Genetic susceptibility to non-polyposis colorectal cancer. *J Med Genet.* 1999;36:801-18.
- Breivik J. The evolutionary origin of genetic instability in cancer development. *Semin Cancer Biol.* 2005;15:51-60.
- Fearon ER, Vogelstein B. A genetic model for colorectal tumorigenesis. *Cell.* 1990;61:759-67.
- Sudoyo AW. Karakteristik molekular kanker kolorektal pada usia muda: Ekspresi MLH1 dan MSH2 sebagai indikator instabilitas mikrosatelit. Jakarta: Departemen Ilmu Penyakit Dalam FKUI; 2004.
- Giardiello FM, Hamilton SR, Krush AJ, Piantadosi S, Hyland IM, Celano P, et al. Treatment of colonic and rectal adenomas with sulindac in familial adenomatous polyposis. *N Engl J Med.* 1993;328:1313-6.
- Steinbach G, Lynch PM, Phillips RK, Wallace MH, Hawk E, Gordon GB, et al. The effect of celecoxib, a cyclooxygenase-2 inhibitor, in familial adenomatous polyposis. *N Engl J Med.* 2000;342:1946-52.
- Hsi L, Angerman-Stewart J, Eling TE. Introduction of full-length APC modulates cyclooxygenase-2 expression in HT-29 human colorectal carcinoma cells at the translational level. *Carcinogenesis.* 1999;20:2045-9.
- Karnes WE Jr, Shattuck-Brandt R, Burgart LJ, DuBois RN, Tester DJ, et al. Reduced COX-2 protein in colorectal cancer with defective mismatch repair. *Cancer Res.* 1998;58:5473-7.
- Smith WL, DeWitt DL, Garavito RM. Cyclooxygenases: structural, cellular, and molecular biology. *Annu Rev Biochem.* 2000;69:145-82.
- Subbaramaiah K, Telang N, Ramonetti JT, Araki R, DeVito B, Weksler BB, et al. Transcription of cyclooxygenase-2 is enhanced in transformed mammary epithelial cells. *Cancer Res.* 1996;56:4424-9.

16. Smith WL, Langenbach R. Why there are two cyclooxygenase isoenzymes. *J Clin Invest.* 2001;107:1491-5.
17. Lu H, Ouyang W, Huang C. Inflammation, a key event in cancer development. *Mol Cancer Res.* 2006;4:221-33.
18. Karin M, Cao Y, Greten FR, Li ZW. NF- κ B in cancer: from innocent bystander to major culprit. *Nature Rev Cancer.* 2002;2:301-10.
19. Karin M, Greten FR. NF- κ B: linking inflammation and immunity to cancer development and progression. *Nat Rev Immunol.* 2005;5:749-59.
20. Maihofner C, Charalambous MP, Bhambra U, Lightfoot T, Geisslinger G, N J Gooderham, et al. Expression of cyclooxygenase-2 parallels expression of interleukin-1 β , interleukin-6 and NF- κ B in human colorectal cancer. *Carcinogenesis.* 2003;24:665-71.
21. Itzkowitz SH, Yio X. Colorectal cancer in inflammatory bowel disease: the role of inflammation. *Am J Physiol Gastrointest Liver Physiol.* 2004;287:G7-G17.
22. Yu H-G, Yu L-L, Yang Y, Luo H-S, Yu J-P, Meier JJ, et al. Increased expression of RelA/Nuclear factor- κ B protein correlates with colorectal tumorigenesis. *Oncol.* 2003;65:37-45.
23. Lim SC, Lee TB, Choi CH, Ryu SY, Min YD, Kim KJ. Prognostic significance of cyclooxygenase-2 expression and nuclear p53 accumulation in patients with colorectal cancer. *J Surg Oncol.* 2008;97:51-6.
24. Morris M, Platell C, Iacopetta B. A population-based study of age-related variation in clinicopathological features, molecular markers and outcome from colorectal cancer. *Anticancer Res.* 2007;27(4C):2833-8.
25. Sudoyo AW, Karakteristik molekular kanker kolorektal pada usia muda: Ekspresi MLH1 dan MSH2 sebagai indikator instabilitas mikrosatelit. Jakarta: Departemen Ilmu Penyakit Dalam FKUI; 2004.