

Cetrorelix Suppression Test in the Diagnostic Work-up of Severe Hyperandrogenism in Adolescence

Marian de Man¹, Esther Derksen², Gerlach Pieters² and Hans de Boer¹

¹*Department of Internal Medicine, Rijnstate Hospital, Arnhem and*

²*Department of Endocrinology, St Radboud University, Nijmegen, The Netherlands*

ABSTRACT

Conventional diagnostic procedures failed to provide a definitive diagnosis in a 15 year-old girl presenting with severe hirsutism, oligomenorrhea, and markedly elevated serum testosterone levels. To examine whether androgen overproduction was luteinizing hormone (LH) dependent and thus likely of ovarian origin we performed a new test to suppress LH secretion based on the use of Cetrorelix, a short-acting gonadotropin-releasing hormone antagonist. Subcutaneous administration of Cetrorelix 250 µg once daily for 5 days resulted in partial suppression of serum LH and testosterone. The same dose administered twice daily for 5 days almost completely suppressed serum LH and testosterone, thereby supporting a diagnosis of ovarian androgen excess. This observation was confirmed by a positive human chorionic gonadotropin stimulation test and an MRI showing bilateral polycystic ovaries.

Conclusion: The Cetrorelix suppression test appears to be a promising instrument to help solve the differential diagnosis of severe hyperandrogenism in adolescence.

KEY WORDS

hirsutism, GnRH receptor antagonist

Reprint address:

H. de Boer, M.D., Ph.D.

Department of Internal Medicine

Ziekenhuis Rijnstate

Wagnerlaan 55

6800 TA Arnhem, The Netherlands

e-mail: hdeboer@alysis.nl

INTRODUCTION

Clinical evaluation, a standardized hormone analysis and pelvic ultrasound are usually sufficient to provide a definitive diagnosis in most women presenting with hirsutism, and oligo- or amenorrhea. In 80-90% of cases this work-up will lead to a diagnosis of polycystic ovary syndrome (PCOS)^{1,2}. If serum total testosterone is higher than 5 nmol/l rare causes of androgen excess, such as non-classic adrenal enzymatic deficiencies, hyperthecosis, and adrenal or ovarian tumors, should be considered^{3,4}. This differential diagnosis requires an extensive diagnostic work-up that will be necessary in about 5% of patients presenting with androgen excess. Androgen-producing tumors are very rare and occur in about one of 500 female patients presenting with signs and symptoms of androgen excess. The majority will be of ovarian origin. Some virilizing ovarian tumors are extremely difficult to localize because of their small size⁵.

After exclusion of ovarian abnormalities by abdominal or transvaginal ultrasound a search for adrenal causes is required. This comprises a dexamethasone suppression test, an adrenocorticotropin (ACTH) stimulation test, and computed tomography³. If this does not produce a definitive diagnosis, ¹³¹I-cholesterol scintigraphy may be helpful in some cases^{6,7}. Venous sampling of the ovaries and adrenals is usually a last resort option. It is an invasive procedure that even in experienced hands may remain inconclusive in 50% of cases, and in 5% is associated with complications such as infarction or bleeding⁸. In adolescent girls the failure and complication rates may be even higher due to technical difficulties related to the small size of adrenal and ovarian veins.

We describe a new test to suppress luteinizing hormone (LH) secretion which may be useful to localize the source of androgen overproduction in

adolescent females with marked androgen excess. The test is based on the use of Cetrorelix, a short-acting gonadotropin-releasing hormone (GnRH) receptor antagonist that suppresses LH secretion by blocking the pituitary GnRH receptor.

PATIENT REPORT

A 15 year-old girl presented with progressive hirsutism of recent onset. Menarche was at the age of 11 years, followed by a regular menstrual cycle for the first year. Thereafter, oligomenorrhea and hirsutism developed. Treatment with Diane35® (ethinyl estradiol 35 µg + cyproterone acetate 2 mg) produced a regular menstrual cycle, but hirsutism worsened progressively and eventually she needed to shave every other day. Body weight increased by 15-20 kg during this period. The patient's family history was negative for hirsutism. At presentation body height was 1.71 m, body weight 107 kg, body mass index (BMI) 36.5 kg/m², blood pressure 160/90 mm Hg, and waist circumference 106 cm. Hair growth was increased on the face, neck, lower abdomen and back and on the upper legs with a Ferriman-Gallwey score of 15 (normal <8). Acne was present on the face and the upper back. There was no clitoromegaly, nor signs indicative for Cushing's syndrome. Breast development was normal. Pending further analysis Diane35 was discontinued. Since then she remained amenorrheic. An extensive hormone analysis was performed from blood samples drawn between 08.00 and 10.00 h. Total testosterone was markedly elevated (8.0 nmol/l, normal range [NR] 0.2-2.9 nmol/l), whereas androstenedione (9.8 nmol/l, NR: 1.9-14.4 nmol/l), dehydroepiandrosterone (DHEA) (44 nmol/l, NR: 15-45 nmol/l), dehydroepiandrosterone sulfate (DHEAS) (7.7 nmol/l, NR: 4.0-10.0 nmol/l), 17-OH-progesterone (9.1 nmol/l, NR: 3.3-11.1 nmol/l), serum albumin and sex hormone binding globulin (30 nmol/l, NR: 18-114 nmol/l) were within the normal range. Serum estradiol was 169 pmol/l, with LH and follicle stimulating hormone (FSH) values of 9.3 U/l and 3.5 U/l, respectively. Morning cortisol was 0.65 µmol/l and ACTH 28 ng/l. Urinary cortisol excretion was 64 nmol/24 h (NR: 30-150 nmol/24 h). A 5-day dexamethasone suppression test (1 mg tid, for 5 days) reduced

reduced morning cortisol to 0.02 µmol/l without affecting serum androgens. Stimulation with ACTH (250 µg intravenously) produced a mild increase of 17-OH-progesterone from 5.8 nmol/l to 13.5 nmol/l (normal response <43 nmol/l). Marked abdominal obesity impaired ultrasound imaging. The ovaries appeared to be normal on transrectal ultrasonography, but again the imaging was poor. Computed tomography scan showed normal adrenals; the ovaries could not be identified. ¹³¹I-Norcholesterol imaging did not reveal increased uptake. To obtain evidence regarding the site of androgen production it was decided to suppress LH secretion by way of Cetrorelix, a short-acting luteinizing hormone releasing hormone (LHRH) antagonist. Cetrorelix is licensed to prevent premature LH surges in women undergoing controlled ovarian stimulation (COH)^{9,10}. It competitively blocks the binding of LHRH to its receptor, which causes a dose dependent suppression of LH and FSH release.

After permission from the patient and her parents, the Cetrorelix suppression test was performed. Cetrorelix 250 µg was administered subcutaneously once daily at 09.00 h for 5 days. Blood samples were taken at 08.30 h, 12.00 h and 16.00 h on the first day and at 08.30 h and 16.00 h on subsequent days. As shown in the left column of Figure 1, serum LH decreased from 11.1 U/l to 4.5 U/l within 8 hours but returned to its pre-test level 12 hours later. This pattern of short-term suppression followed by a partial escape several hours later was repeated during the next days. Suppression of serum testosterone was also incomplete, showing a saw-toothed pattern comparable to that of LH, with the exception that the nadir testosterone levels gradually decreased from 6.8 nmol/l on the first day to 4.8 nmol/l on the fifth day. To achieve more convincing evidence of LH dependency the test was repeated three weeks later with Cetrorelix 250 µg twice a day, administered at 09.00 h and 21.00 h. Blood sampling was started at 08.00 h and repeated every four hours during the first day. As shown in the right column of Figure 1, this improved LH suppression. Serum LH decreased from 12.8 U/l to 1.8 U/l within the first 20 hours, but then rose to 4-5 U/l and remained around this level during the following days. The LH escape was not as evident as during the once daily injection. Serum testoste-

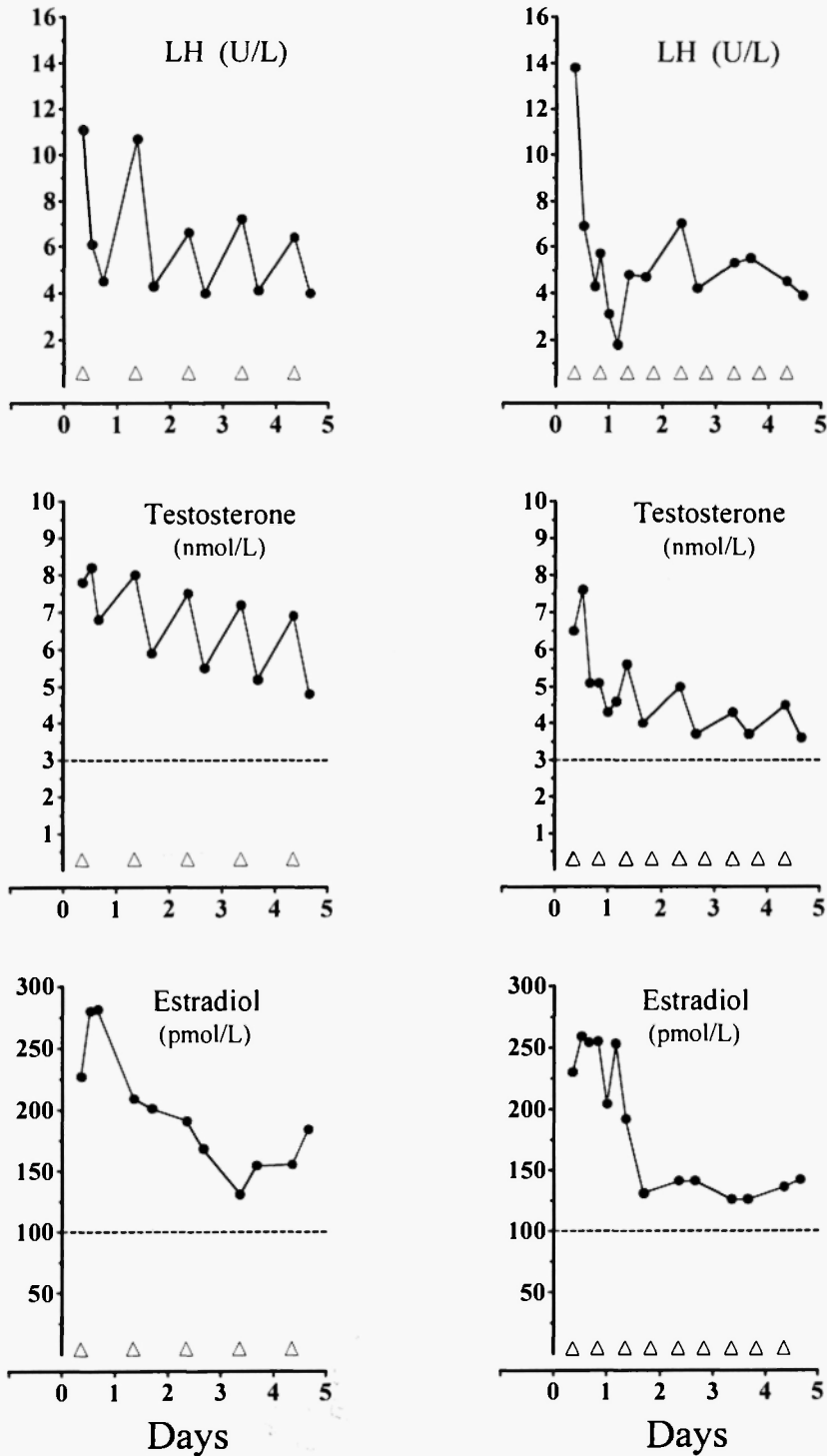


Fig. 1: Response to Cetorelix 250 µg subcutaneously, once a day (left column) and twice a day (right column). The dashed lines represent the upper normal limit for serum testosterone in women, and the upper normal estradiol limit in postmenopausal women, respectively.

rone decreased rapidly from 7.6 to 4.3 nmol/l during the first 24 hours, but then needed three days to reach its nadir of 3.6 nmol/l. Serum estradiol decreased to levels approaching postmenopausal values. Confirmation of LH dependency of testosterone production was obtained by performing an in-hospital dexamethasone/human chorionic gonadotropin test (Dex/HCG). Dexamethasone 0.5 mg was given every six hours for 7 days, and on the final three days this was combined with HCG 1,500 IU daily. Dexamethasone alone suppressed serum ACTH and cortisol to a value below the detection limit but did not affect serum androgen levels. After the addition of HCG serum testosterone rose rapidly from 7.8 to 17.4 nmol/l within 24 hours. This further supported a diagnosis of ovarian hyperandrogenism. Pelvic MRI showed bilateral polycystic ovaries, without evidence of a separate ovarian tumor. The data were found to be consistent with a diagnosis of PCOS. Venous sampling to rule out a small unilateral ovarian tumor was not performed because the additional information provided by this procedure would not outweigh the risks of hemorrhage or infarction that might occur. The patient was started on metformin 500 mg twice daily. Amenorrhea persisted despite continued treatment for 6 months. Therefore, it was decided to add the oral contraceptive Microgynon 50[®] (ethinylestradiol 50 µg and levonorgestrel 125 µg) in combination with cyproterone acetate 50 mg during the first 10 days of the cycle. This treatment was continued for one year and led to a decrease in serum testosterone from 9.1 to 3.3 nmol/l and a lowering of the Ferriman-Gallwey score from 15 to 6 (normal <8).

DISCUSSION

The present report suggests that the Cetrorelix suppression test may be useful in the diagnostic work-up of severe androgen excess in adolescence. Recently, it has been used successfully to assess the source of androgen excess in a postmenopausal woman¹¹. In contrast to its marked LH suppressive effects in postmenopause, a once daily injection of Cetrorelix 250 µg was insufficient to achieve adequate LH suppression in adolescence. Twice daily injection improved LH and testosterone suppres-

sion, but did not completely normalize serum testosterone. The results suggest that higher doses or more frequent injections are required.

Pilot studies designed to assess the optimal dose to prevent premature LH surges in women undergoing COH provide useful information regarding the dose necessary to obtain LH suppression of the degree required for diagnostic purposes¹²⁻¹⁶. Endogenous LH surges can be prevented by a single dose of Cetrorelix 5 mg, injected subcutaneously on the ninth day of the cycle. This decreased serum LH within 24 hours from 5.5 ± 1.9 to 0.2 ± 0.04 U/l, and the suppression lasted 5 days¹². Daily subcutaneous injection of Cetrorelix 1 mg, starting on the 7th day of the cycle, reduced serum LH to a mean of 1 U/l¹³. In a study designed to assess the minimal effective dose to prevent premature LH surges, daily doses ranging from 100-500 µg were tested¹⁴. Doses of 100 µg were not effective. Daily administration of Cetrorelix 250 µg and 500 µg both succeeded in suppressing endogenous LH surges; however, after the administration of 250 µg a minor increase in serum LH was observed 12 hours after injection. In our patient the once daily dose of 250 µg was associated with an LH escape of about 3 U/l above the preceding nadir value. This was considerable greater than the LH escape of 1 U/l in healthy women undergoing COH. The higher dose requirement for complete LH suppression in our patient could be related to altered LH secretion dynamics in patients with PCOS, or by age related differences in GnRH secretion. In adolescent females the GnRH pulse generator may be stronger than in females aged 20-40 years, which would explain the higher dose of Cetrorelix to antagonize endogenous GnRH. In patients with PCOS serum LH levels are relatively high due to an increase in LH pulse frequency and amplitude, caused either by increased hypothalamic secretion of GnRH, increased pituitary sensitivity to GnRH, or both^{3,15,16}. Hayes *et al.* compared the effects of a first generation GnRH antagonist on serum LH levels in patients with PCOS and normal women and found that post-suppression LH levels were 5-6 U/l in adult women with PCOS and 2-3 U/l in normal adult women¹⁵. Comparable results were obtained by Apter *et al.* who evaluated LH suppression in hirsute adolescent girls and develop-

mentally matched controls¹⁶. We therefore conclude that patients with PCOS require relatively high doses of GnRH antagonists to obtain maximal LH suppression. We speculate that Cetrorelix 500 µg twice daily will be sufficient to suppress LH below 2 mU/l in adolescence.

In conclusion, the Cetrorelix suppression test may become a useful instrument in the differential diagnosis of severe hyperandrogenemia of adolescence and early adulthood, provided that the dose to achieve maximal suppression of LH and testosterone is more exactly defined. As a diagnostic agent, GnRH antagonists offer several advantages compared to GnRH agonists¹⁷. The desired hormonal responses occur more rapidly, are readily reversible and are not accompanied by hot flashes or other clinically relevant side effects.

DISCLOSURE INFORMATION

Conflicts of interest: none.

Sponsoring: none.

REFERENCES

1. Azziz R, Sanchez LA, Knochenhauer ES, Moran C, Lazenby J, Stephens KC, Taylor K, Boots LR. Androgen excess in women; experience with over 1000 consecutive patients. *J Clin Endocrinol Metab* 2004; 89: 453-462.
2. Carmina E, Rosato F, Janni A, Rizzo M, Longo RA. Relative prevalence of different androgen excess disorders in 950 women referred because of clinical hyperandrogenism. *J Clin Endocrinol Metab* 2006; 91: 2-6.
3. Taylor AE. Polycystic ovary syndrome. *Endocrinol Metab Clin North Am* 1998; 27: 877-902.
4. O'Driscoll JB, Mamtara H, Higginson J, Pollock A, Kane J, Anderson DC. A prospective study of the prevalence of clear-cut endocrine disorders and polycystic ovaries in 350 patients presenting with hirsutism or androgenic alopecia. *Clin Endocrinol* 1994; 41: 231-236.
5. Pittaway DE. Neoplastic causes of hyperandrogenism. *Infert Reprod Med Clin North Am* 1991; 2: 531-545.
6. Taylor L, Ayers JWT, Gross MD, Peterson EP, Menon KMJ. Diagnostic considerations in virilization: iodomethyl-norcholesterol scanning in the localization of androgen secreting tumors. *Fertil Steril* 1986; 46: 1005-1010.
7. Kazerooni EA, Sisson JC, Shapiro B, Gross MD, Driedger A, Hurwitz GA, Mattar AG, Petry NA. Diagnostic accuracy and pitfalls of [iodine-131]6-beta-iodomethyl-19-norcholesterol (NP-59) imaging. *J Nucl Med* 1990; 31: 526-534.
8. Cohen I, Cuperman S, Altaras MM, Ben-Nun I, Goldberg E, Beyth Y. Combined ovarian vein catheterization with ovarian stimulation in the diagnosis of androgen overproduction. *Acta Obstet Gynecol Scand* 1992; 71: 245-248.
9. Huime JAF, Lambalk CB. Gonadotropin-releasing-hormone-receptor antagonists. *Lancet* 2001; 358: 1793-1803.
10. Mahutte NG, Arici A. Role of gonadotropin-releasing hormone antagonists in poor responders. *Fertil Steril* 2007; 87: 241-249.
11. de Boer H, de Man M, de Bruyn K, van Sorge A. Cetrorelix suppression test to assess the source of androgen overproduction in postmenopausal hirsutism. *Eur J Endocrinol* 2006; 155: 391-393.
12. Olivennes F, Fanchin R, Bouchard P, de Ziegler D, Taieb J, Selva J, Frydman R. The single or dual administration of the gonadotropin releasing hormone antagonist Cetrorelix in an in vitro fertilization-embryo transfer program. *Fertil Steril* 1994; 62: 468-476.
13. Diedrich K, Diedrich C, Santos E, Zoll C, al-Hasani S, Reissmann T, Krebs D, Klingmüller D. Suppression of the endogenous luteinizing hormone surge by the gonadotropin-releasing hormone antagonist Cetrorelix during ovarian stimulation. *Hum Reprod* 1994; 9: 788-791.
14. Albano C, Smitz J, Camus M, Riethmuller-Winzen H, Van Steirteghem A, Devroey P. Comparison of different doses of gonadotropin-releasing hormone antagonist Cetrorelix during controlled ovarian hyperstimulation. *Fertil Steril* 1997; 67: 917-922.
15. Hayes FJ, Taylor AE, Martin KA, Hall JE. Use of gonadotropin-releasing hormone antagonist as a physiologic probe in polycystic ovary syndrome: assessment of neuroendocrine and androgen dynamics. *J Clin Endocrinol Metab* 1998; 83: 2343-2349.
16. Apter D, Butzow T, Laughlin GA, Yen SSC. Accelerated 24-hour luteinizing hormone pulsatile activity in adolescent girls with ovarian hyperandrogenism: relevance to the developmental phase of polycystic ovarian syndrome. *J Clin Endocrinol Metab* 1994; 79: 119-125.
17. Pascale M, Pugeat M, Roberts M, Rousset H, Dechaud H, Dutrieux-Berger N, Tourniaire J. Androgen suppressive effect of GnRH agonist in ovarian hyperthecosis and virilizing tumours. *Clin Endocrinol* 1994; 41: 571-576.

