

PDF hosted at the Radboud Repository of the Radboud University Nijmegen

The following full text is a publisher's version.

For additional information about this publication click this link.

<http://hdl.handle.net/2066/58965>

Please be advised that this information was generated on 2021-09-25 and may be subject to change.

Osteonecrosis in patients with testicular tumours treated with chemotherapy

F. van den Berkmortel^{1*}, R. de Wit¹, J. de Rooy², P. DeMulder¹

Departments of ¹Medical Oncology (550) and ²Radiology, University Medical Centre St Radboud, PO Box 9101, 6500 HB Nijmegen, the Netherlands, tel.: +31 (0)24-3516 52 15, fax: +31 (0)24-354 07 88, e-mail: f.vandenberkmortel@onco.umcn.nl, * corresponding author

ABSTRACT

The role of antiemetics is invaluable in allowing cancer patients to complete, otherwise possibly intolerable, chemotherapy. In the Perugia Consensus Conference it was decided that the recommended antiemetic regimen in the prevention of acute emesis induced by a single high, low and repeated doses of cisplatin is a serotonin receptor antagonist plus dexamethasone.

We describe three testicular cancer patients who were cured with chemotherapy but developed bilateral osteonecrosis of the femoral head 17, 22 and 55 months after chemotherapy. It is very likely that the dexamethasone used in the antiemetic drug regimen contributed to the development of osteonecrosis in these patients.

Osteonecrosis is a serious side effect of antiemetic treatment with dexamethasone and this serious complication should be incorporated in the current guidelines. Patients should be informed about the risk of osteonecrosis when taking dexamethasone as an antiemetic drug. A recommendation to add corticosteroids to serotonin receptor antagonists only after demonstrated nausea in chemotherapy regimens with low-dose cisplatin (20 mg/m²) for five days seems justified.

INTRODUCTION

The role of antiemetics is invaluable in allowing cancer patients to complete, otherwise possibly intolerable, chemotherapy. With the use of serotonin receptor antagonists, a major breakthrough in antiemetic treatment, namely complete protection against vomiting, was achieved in 40 to 60%.¹ Combination with dexamethasone

was shown to increase complete protection against vomiting in 70 to 90% of patients.¹ Nowadays, a serotonin receptor antagonist plus dexamethasone is the regimen of choice in the prevention of acute emesis induced by single high and low and repeated doses of cisplatin.¹ In this report we present three patients who developed osteonecrosis of the femoral heads after treatment with chemotherapy for their testicular tumours.

CASE REPORTS

Patient A

A 29-year-old man with a previously unremarkable medical history underwent a low anterior resection with development of an anus praeter naturalis due to persistent bleeding because of a tumour in the cavum douglasi. In addition, a nephrostomy catheter in the right kidney was inserted because of a hydronephrosis with rectal urine loss due to a fistula. Pathological examination revealed a seminoma stage II which originated from an intra-abdominal testicle. Patient was treated with four cycles of BEP (bleomycin 30 mg days 2, 8 and 15, etoposide 100 mg/m² days 1 to 5, cisplatin 20 mg/m² days 1 to 5) between March and June 1991. After the second cycle the patient developed an urogenital infection due to an obstructed nephrostomy catheter. As antiemetics ondansetron 8 mg intravenously was given once or twice daily on days 1 to 5 in addition to dexamethasone 10 mg intravenously once daily on days 1 to 5. Thereafter, dexamethasone was administered orally twice daily for four days in a dose of 6 mg for the first two and 3 mg for the second two days.

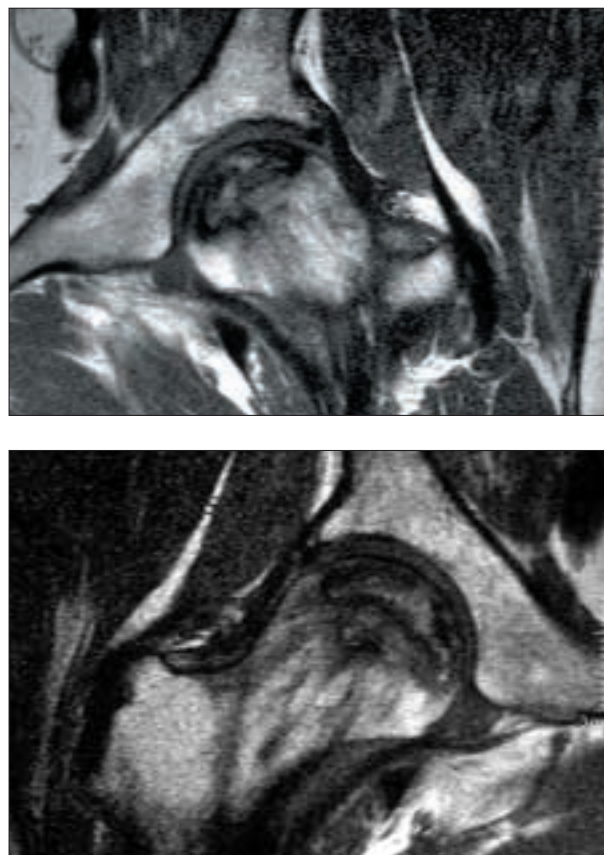
Diazepam was added to the antiemetic regimen due to persistent nausea and vomiting. In the first cycle the patient received 20 mg of dexamethasone a day only once because of vomiting. The total dose of steroids given was equivalent to 2.21 g of prednisolone.² In 1992 the fistula was closed as well as the anus praeter naturalis. After recovery from surgery the patient complained about erectile dysfunction. There were no signs of persistent or recurrent testicular cancer. In October 1995 the patient complained about pain in the right hip. In January 1996, bilateral osteonecrosis of the femoral heads was diagnosed on conventional radiographs and MRI (55 months after the end of chemotherapy). Initially a rotation osteotomy according to Sugioka was performed on the right side. In December 1998 treatment by bone impaction grafting after removal of the osteonecrotic bone was performed on the left side. Finally, in December 2000 the patient underwent total hip replacement on the right side.

Patient B

A 28-year-old man with stage IIA nonseminoma of the right testis with rising serum tumour marker levels after orchidectomy (good prognosis according to the International Germ Cell Consensus Classification Group (IGCCCG) classification) was treated with three cycles of BEP (bleomycin 30 mg days 2, 8 and 15, etoposide 100 mg/m² days 1 to 5, cisplatin 20 mg/m² days 1 to 5) and one cycle of EP (same regimen without bleomycin) from November 1998 until January 1999. Nausea and vomiting were controlled with a combination of ondansetron 8 mg and dexamethasone 10 mg intravenously during the first five days of the cycle. In addition dexamethasone was continued for an additional two days at a dose of 3 mg twice daily. Ondansetron 8 mg and dexamethasone 10 mg were also given once just prior to the second gift of bleomycin (day 8) in the first cycle at the outpatient clinic to treat existing nausea and vomiting. The total dose of steroids given to the patient during treatment was equivalent to 1.61 g of prednisolone.² Treatment was unremarkable except for one episode of leucopenic fever for which patient was admitted to hospital for a short period. Postchemotherapy restaging showed normal serum tumour markers in the presence of residual disease on abdominal CT scan. In March 1999, a retroperitoneal lymph node resection was performed. Pathological examination revealed mature teratoma. Thereafter, the patient has remained free of recurrence. In December 2000 (22 months after completion of chemotherapy) the patient reported progressive pain in his right hip. A radiograph of his right hip suggested signs of osteonecrosis of the femoral head. An MRI showed bilateral osteonecrosis of the femoral heads. A bone scan scintigraphy excluded the presence of metastatic disease. The bilateral femoral head necrosis has so far been managed conservatively.

Patient C

A 29-year-old man with stage IIA seminoma (IGCCCG: good risk) was treated with three cycles of BEP (bleomycin 30 mg days 2, 8 and 15, etoposide 100 mg/m² days 1 to 5, cisplatin 20 mg/m² days 1 to 5) given three-weekly between August and October 1999. During the first five days of every cycle, ondansetron 8 mg intravenously once or twice daily and dexamethasone 10 mg intravenously once daily were used as antiemetics. Dexamethasone was continued orally for an additional two days at a dose of 3 mg twice daily. He received a dose of steroids equivalent to 1.16 g of prednisolone over the three cycles of BEP (using a conversion rate of 0.8 mg dexamethasone = 5 mg prednisolone).² He achieved a complete remission. However, in March 2001 (17 months after completion of chemotherapy) the patient complained about pain in the left hip. Conventional radiographs as well as MRI (figure 1) showed bilateral hip osteonecrosis. Medical history was unremarkable with no prior steroid use. The BMI of 27.7 kg/m² and the use of four units of alcohol a day were the only other risk factors for avascular bone necrosis.



Figures 1A (right hip) and B (left hip)
Coronal T1-weighted spin echo MR images of both hips

A serpentine line of very low signal intensity demarcates a large area of low signal intensity in both femoral heads, representing osteonecrosis (Association de la Recherche de la Circulation Osseuse Stage III).

Decompression surgery was applied to the right hip. The left hip was treated conservatively.

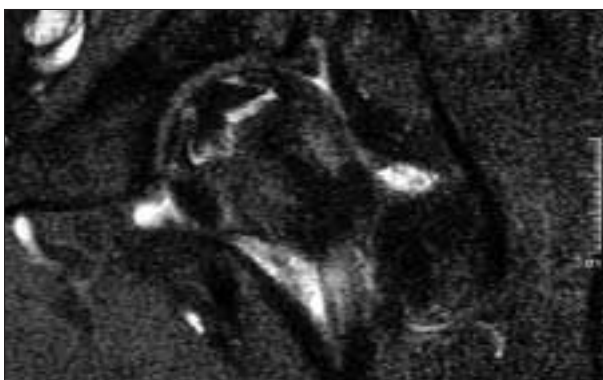
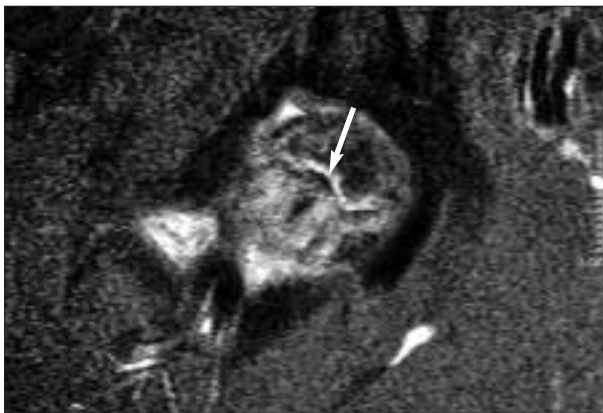
DISCUSSION

We report three patients who received chemotherapy because of testicular cancer and who developed bilateral osteonecrosis of the femoral heads.

Osteonecrosis is not a specific disease entity but the final common pathway of a number of conditions mostly leading to an impairment of the blood supply to the bone.³

Diseases or conditions associated with or leading to osteonecrosis are numerous (*table 1*).

The association between therapy for a malignancy and the development of osteonecrosis of the femoral head was first presented by Ihde and DeVita in 1975,⁴ a report followed by many other reports of patients developing osteonecrosis while being treated for Hodgkin's disease or lymphoma.^{5,7} In solid tumours, osteonecrosis is infrequently reported. The publications concern testicular cancer^{2,8-10}



Figures 1C (right hip) and D (left hip)
Coronal T2-weighted gradient echo, fat-suppressed MR images of the same patient

The serpentine line (black; see arrow) is now surrounded by a narrow zone of high signal intensity (oedema; white), known as 'the double-line sign'. This is considered highly specific for osteonecrosis.

Table 1

Conditions which can cause osteonecrosis of the femoral head^{2,5,26}

Trauma
Haemoglobinopathies: sickle-cell disease
Polycythaemia
Gaucher's disease
Fabry's disease
Caisson disease
Congenital and developmental conditions: Ehler-Danlos syndrome
Legg-Calvé-Perthes disease
Radiotherapy
Hypercortisolism: Cushing's disease
Corticosteroid medications
Hyperparathyroidism
Excessive alcohol consumption
Coagulation disorders
Hyperlipidaemia
Vasculitis: systemic lupus erythematosus
Giant cell arthritis
Gout and hyperuricaemia
Diabetes mellitus
Pregnancy

and breast cancer¹¹ and to a lesser extent endometrial cancer,¹¹ ovarian cancer¹² and prostate cancer. Despite the relative rarity of testicular cancer, approximately 75% of the reported cases in adults occurred in this group.⁸ Possible explanations for this include the lack of recognition in other patient groups and the specific effects of chemotherapy used to treat testicular cancer. Various manifestations of late vascular toxicity have been reported in survivors of testicular cancer. The most well-recognised occurrence of chronic small-vessel damage in patients treated with chemotherapy for testicular cancer is Raynaud's phenomenon, which occurs in 23 to 43% of the patients.¹³ Damage to the autonomic nervous system vessels caused by cisplatin or vinblastine (both known to have neurotoxic side effects) that innervates the peripheral smooth muscle is involved in the pathogenesis of Raynaud's phenomenon. Another example of vascular toxicity is the capillary damage of the nailfold which could be visualised by capillary microscopy, even in asymptomatic patients treated with bleomycin.¹⁴ It can be hypothesised that these vascular effects may contribute to the development of osteonecrosis. Although age is not a known risk factor for the development of osteonecrosis, it is striking that osteonecrosis is also described more frequently in Hodgkin patients who are generally of a similar young age to testicular cancer patients. Young patients probably have a more active lifestyle after treatment of their initial disease. More and active weight bearing on the femoral head will increase the risk of femoral head collapse leading

to a higher degree of complaints. Based on three reports^{15,16} in which testicular cancer patients were followed after chemotherapy, the crude incidence of osteonecrosis was estimated at 1.5% (95% confidence interval 0.9-2.1%). The incidence of asymptomatic osteonecrosis was 9% (confidence interval: 2-20%) in a small group of patients who previously received chemotherapy because of testicular cancer.¹⁷ The incidence of symptomatic osteonecrosis was 3.8% in the same group.

Corticosteroids, used as antiemetic therapy, are considered to be the main cause of the development of osteonecrosis in patients with solid tumours. In our report, all three patients were treated with dexamethasone combined with ondansetron as antiemetics. In the literature a few cases have been reported in which osteonecrosis developed after chemotherapy without previous administration of dexamethasone.^{9,18} This finding suggests that cytotoxic drugs contribute to the development of osteonecrosis. Several mechanisms are thought to play a role in the development of corticosteroid-induced osteonecrosis.¹⁹ Firstly, the number of adipocytes in the femoral head of rabbits treated with corticosteroids is increased.²⁰ This increase in adipocytes correlates with a higher intra-osseous pressure in the femoral head, probably because the efferent veins are compressed by the increased fat content and the afferent arterial flow continues (Sterling mechanism).³ Furthermore, apoptosis of osteoblasts as well as of osteoclasts is increased with the use of corticosteroids.²¹ Finally, corticosteroids stimulate the differentiation of bone marrow stem cells into adipocytes.²² This leads to a lower number of osteoblasts and therefore a decreased repair and remodelling of osteonecrotic bone.

There is no strict time-dose relationship between corticosteroids and the occurrence of osteonecrosis. Our patients were on corticosteroids in prednisone-equivalent doses of 1.16 to 2.21 g. In the literature, prednisone-equivalent doses ranging from 0.61 to 9.01 g have been reported.⁸ Although there are no studies that compare the risks of short to medium-acting steroids, such as prednisone with dexamethasone, it is likely that the latter places the patient at a higher risk due to longer serum and biological half-life. Winqvist *et al.*⁸ reviewed 28 patients with osteonecrosis after treatment for testicular cancer. In three patients onset of osteonecrosis was acute while in 23 patients it was delayed, by a mean of 26 months (range: 12-47 months), after chemotherapy. In our three patients osteonecrosis developed 17, 22 and 55 months after chemotherapy. Although the femoral head is affected most frequently Harper *et al.*⁹ reported a patient with testicular cancer who in addition to osteonecrosis of the femoral head also suffered from osteonecrosis of the scaphoid and both medial femoral condyles. In the study by Winqvist *et al.*⁸ bilateral femoral head involvement was found in 70%. In all our patients bilateral femoral head necrosis was

diagnosed. Control of emesis is important in protocol dose adherence. In a double-blind study 531 patients were randomised to one of four intravenous doses of dexamethasone (4-8-12-20 mg) in combination with 8 mg of ondansetron. Complete protection from vomiting was significantly superior in patients who received 20 mg compared with those who received 4 and 8 but not 12 mg.²³ In a meta-analysis of 3791 patients enrolled on 22 randomised trials in which dexamethasone plus a serotonin antagonist was compared with placebo treatment plus a serotonin antagonist²⁴ superiority of the dexamethasone arm was found. Although these steroid-associated complications are uncommon, they are devastating (sometimes even requiring total hip replacement) especially in young patients with potentially curable malignancy. The addition of dexamethasone to the antiemetic regime is inevitable to achieve optimal treatment. As no evident dose response has been documented, the lowest effective dose of dexamethasone should be used.

In the American Society of Cancer Oncology guidelines concerning antiemetics as well as in the Perugia Consensus Conference regarding the optimal antiemetic treatment¹ osteonecrosis due to corticosteroids is not mentioned. Although the development of osteonecrosis in patients treated with chemotherapy is probably multifactorial, the likely contribution of corticosteroids should have warranted the incorporation of this potential side effect in the guidelines. Patients should be informed about the increased risk of osteonecrosis when treated with chemotherapy for which dexamethasone is used for antiemetic treatment. In addition, osteonecrosis should be included in the differential diagnosis of patients who have been treated with chemotherapy and who present with hip pain. At the onset of hip complaints in a patient treated with corticosteroids, MRI should be performed if plain X-rays show no significant signs of any disease. In the late stages of osteonecrosis, radiographs and CT scanning are sufficient to prove the existence and the extension of the disease; MRI is then no longer necessary. Finally, a recommendation to add corticosteroids to serotonin receptor antagonists only after demonstrated nausea in chemotherapy regimes with low-dose cisplatin (20 mg/m²) for five days seems justified.

REFERENCES

1. Prevention of chemotherapy- and radiotherapy-induced emesis: results of Perugia Consensus Conference. Anti-emetic Subcommittee of the Multinational Association of Supportive Care in Cancer (MASCC). *Ann Oncol* 1998;9:811-9.
2. Virik K, Karapetis C, Droufakou S, Harper P. Avascular necrosis of bone: the hidden risk of glucocorticoids used as antiemetics in cancer chemotherapy. *Int J Clin Pract* 2001;55:344-5.