

chronic hepatitis B in China. Clin Infect Dis 2007; 44:541–8.

5. Kao JH, Chen PJ, Lai MY, Chen DS. Hepatitis B virus genotypes and spontaneous hepatitis B e antigen seroconversion in Taiwanese hepatitis B carriers. J Med Virol 2004; 72:363–9.
6. Kao JH, Wu NH, Chen PJ, Lai MY, Chen DS. Hepatitis B genotypes and the response to interferon therapy. J Hepatol 2000; 33:998–1002.
7. Cooksley WG, Piratvisuth T, Lee SD, et al. Peginterferon alpha-2a (40 kDa): an advance in the treatment of hepatitis B e antigen-positive chronic hepatitis B. J Viral Hepat 2003; 10: 298–305.
8. Hoofnagle JH, Seeff LB. Peginterferon and ribavirin for chronic hepatitis C. N Engl J Med 2006; 355:2444–51.

Reprints or correspondence: Prof. Jia-Horng Kao, Hepatitis Research Center and Graduate Institute of Clinical Medicine, National Taiwan University College of Medicine, 7 Chung-Shan S. Rd., Taipei 100, Taiwan (kjh@ha.mc.ntu.edu.tw).

**Clinical Infectious Diseases** 2007;44:1665–6  
© 2007 by the Infectious Diseases Society of America. All rights reserved. 1058-4838/2007/4412-0025\$15.00  
DOI: 10.1086/519700

## Zanamivir Treatment Is Equally Effective for Both Influenza A and Influenza B

TO THE EDITOR—We previously reported that oseltamivir was less effective against influenza B than it was against influenza A in a study of the 2002–2003 influenza season; these findings were similar to those in a report in 2007 by Sugaya et al. [1–3]. However, the effectiveness of another neuraminidase inhibitor, zanamivir, has not been compared between influenza A and influenza B. Therefore, we performed a preliminary study of the effectiveness of zanamivir for the treatment of 67 patients with influenza A and 100 patients with influenza B (with influenza being diagnosed using commercial antigen detection kits) [3, 4] during the 2001–2002, 2002–2003, 2003–2004, 2004–2005, and 2005–2006 seasons (table 1). The percentage of patients who were afebrile at 24 h or 48 h after the first inhalation of zanamivir was analyzed as a parameter of the effectiveness of zanamivir treatment. There was no significant difference between patients with influenza A and patients with influenza B with respect to the percentage of patients who were afebrile at 24 h (49.3% vs. 36%) or at 48 h (79.1% vs. 80%).

**Table 1. The percentage of afebrile patients at 24 h and 48 h after the first inhalation of zanamivir.**

Type of influenza	No. of female patients	No. of male patients	Age, mean years $\pm$ SD	No. (%) of afebrile patients	
				At 24 h	At 48 h
A ( <i>n</i> = 67)	42	25	37.9 $\pm$ 17.5	33 (49.3)	53 (79.1)
B ( <i>n</i> = 100)	61	39	31.6 $\pm$ 18.2	36 (36.0)	80 (80.0)

In our previous study, the mean duration of fever ( $\pm$ SD) in patients with influenza A and patients with influenza B was 31.2  $\pm$  23.7 h and 47.1  $\pm$  30.8 h, respectively, after the first dose of oseltamivir and 47.9  $\pm$  26.0 h and 65.4  $\pm$  32.8 h, respectively, after the onset of fever [3]. In addition, the mean duration of fever ( $\pm$ SD) after onset of fever was 82.4  $\pm$  36.0 h and 78.3  $\pm$  41.9 h in patients with influenza A and patients with influenza B, respectively, who were not treated with anti-influenza drugs [3].

Studies of in vitro antiviral activity of oseltamivir or zanamivir against laboratory strains of influenza virus that used culture and enzymatic assays have suggested that influenza B virus is less susceptible than influenza A virus to oseltamivir and zanamivir [5]. However, the reported difference of the mean inhibitory concentration of 50% between influenza A and B viruses was less for zanamivir (2.09 nM vs. 4.15 nM) than it was for oseltamivir (0.73 nM vs. 11.53 nM). These findings may explain our results in a clinical context, showing that oseltamivir is less effective against influenza B than it is against influenza A and that zanamivir is equally effective against both. We are now studying the effectiveness of zanamivir against influenza A and influenza B among a large number of patients identified during the 2006–2007 season. In conclusion, zanamivir is more effective than oseltamivir for the treatment of influenza B.

## Acknowledgments

**Potential conflicts of interest.** All authors: no conflicts.

**Naoki Kawai,<sup>1</sup> Hideyuki Ikematsu,<sup>1,2</sup> Norio Iwaki,<sup>1</sup> Osame Tanaka,<sup>1</sup> Yasuhito Yamanishi,<sup>1</sup> Nobuo Hirotsu,<sup>1</sup> and Seizaburo Kashiwagi<sup>3</sup>**

<sup>1</sup>Japan Physicians Association, Tokyo Medical Association, Tokyo, and <sup>2</sup>Department of Clinical Research, Hara-doi Hospital, and <sup>3</sup>Fukuoka Red Cross Blood Center, Fukuoka, Japan

## References

1. Sugaya N, Mitamura K, Yamazaki M, et al. Lower clinical effectiveness of oseltamivir against influenza B contrasted with influenza A infection in children. Clin Infect Dis 2007; 44:197–202.
2. Kawai N, Ikematsu H, Iwaki N, et al. Factors influencing the effectiveness of oseltamivir and amantadine for the treatment of influenza: a multicenter study from Japan of the 2002–2003 influenza season. Clin Infect Dis 2005; 40: 1309–16.
3. Kawai N, Ikematsu H, Iwaki N, et al. A comparison of the effectiveness of oseltamivir for the treatment of influenza A and influenza B: a Japanese multicenter study of the 2003–2004 and 2004–2005 influenza seasons. Clin Infect Dis 2006; 43:439–44.
4. Kawai N, Ikematsu H, Iwaki N, Hirotsu N, Kashiwagi S. Prevalence of influenza B during the 2004–2005 season in Japan. Clin Infect Dis 2006; 43:1226–8.
5. Boivin G, Goyette N. Susceptibility of recent Canadian influenza A and B virus isolates to different neuraminidase inhibitors. Antiviral Research 2002; 54:143–7.

Reprints or correspondence: Dr. Naoki Kawai, 4-9 Tonomachi, Gifu City, 500-8116, Japan (nkawai@city.gifu.med.or.jp).

**Clinical Infectious Diseases** 2007;44:1666  
© 2007 by the Infectious Diseases Society of America. All rights reserved. 1058-4838/2007/4412-0025\$15.00  
DOI: 10.1086/519700

## Halo Sign and Improved Outcome

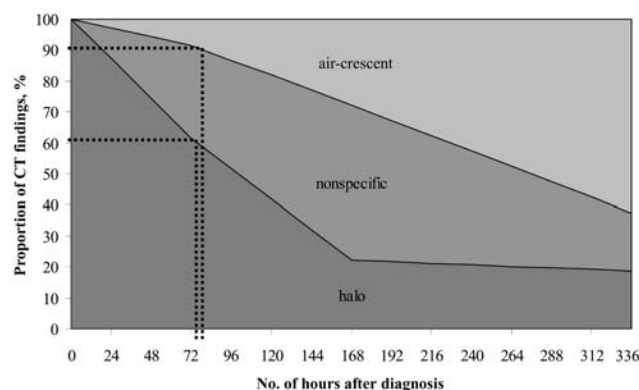
TO THE EDITOR—Greene et al. [1] described baseline chest CT imaging findings from 235 patients with invasive pulmonary aspergillosis who participated in a

previously published clinical trial that compared the efficacy of voriconazole therapy with that of amphotericin B therapy [2]. The “typical” CT images associated with invasive fungal disease are the halo sign and the air-crescent sign, which were present in 60.9% and 10.2% of patients, respectively [1]. The authors described 13 other image appearances that are considered to be less specific for invasive fungal disease. Interestingly, the presence of a halo sign at baseline was associated with a significantly higher global response rate and better survival. This difference in outcome was not explained by other factors, such as neutropenic status or underlying disease [1].

Caillot et al. [3, 4] noted that the halo sign was the earliest radiological manifestation of invasive pulmonary aspergillosis in neutropenic patients and that nonspecific images and the air-crescent sign became more prevalent later in the course of the disease (figure 1). Thus, the improved outcome experienced among patients with a halo sign observed by Greene et al. [1] could have been a result of the earlier initiation of antifungal therapy in the course of the fungal disease. This would also explain why improved outcome was observed regardless of whether patients were treated with voriconazole or amphotericin B.

Timing is crucial for successful therapy of invasive *Candida* infections [5], because the survival rate of patients treated immediately after blood cultures were obtained was better than that of patients in whom administration of antifungal therapy was delayed. There is no reason to assume that the management of other invasive fungal diseases would be any different. These observations underscore the importance of reducing the delay in the administration of effective treatment for patients with invasive fungal infection.

As indicated in figure 1, the frequencies of the halo sign and the air-crescent sign encountered in the study by Greene et al. [1] can be superimposed on the figure based on the study by Caillot et al. [4] and



**Figure 1.** The evolution of CT images of invasive pulmonary aspergillosis in sequential CT scans of the thorax, adapted from Caillot et al. [4]. The observed frequencies of the halo sign and the air-crescent sign in a study by Greene et al. [1] are superimposed on the figure based on the study by Caillot et al. [4].

likely correspond with a delay in diagnosis of ~72 h. Caillot et al. [4] obtained prompt CT imaging of patients in whom invasive aspergillosis was suspected, whereas the current clinical practice is more in line with the study by Greene et al. [1], in which a delay of several days before a CT was performed was not uncommon. Given the importance of early initiation of antifungal therapy, we should no longer accept a delay in obtaining the diagnostic information necessary for the optimum treatment of patients with suspected invasive fungal disease.

## Acknowledgments

**Potential conflicts of interest.** P.E.V. has received research funding from Pfizer, Gilead Sciences, Merck, Basilea, and Schering-Plough; has been a consultant for Pfizer and Schering-Plough; and has served on the speakers' bureau for Merck and Schering-Plough. J.P.D. has received research funding from AM-Pharma VA and Schering-Plough; has been a consultant for Janssen Pharmaceuticals, Gilead Sciences, and Pfizer; and has served on the speakers' bureau for Janssen Pharmaceuticals, Gilead Sciences, and Pfizer. L.V.D.: no conflicts.

Paul E. Verweij,<sup>1</sup> Lya van Die,<sup>2</sup>  
and J. Peter Donnelly<sup>3</sup>

Departments of <sup>1</sup>Medical Microbiology, <sup>2</sup>Radiology,  
and <sup>3</sup>Hematology, University Medical Center St.  
Radboud, Nijmegen, The Netherlands

## References

- Greene RE, Schlamm HT, Oestmann JW, et al. Imaging findings in acute invasive pulmonary

aspergillosis: clinical significance of the halo sign. *Clin Infect Dis* 2007; 44:373–9.

- Herbrecht R, Denning DW, Patterson TF, et al.; Invasive Fungal Infections Group of the European Organisation for Research and Treatment of Cancer and the Global Aspergillus Study Group. Voriconazole versus amphotericin B for primary therapy of invasive aspergillosis. *N Engl J Med* 2002; 347:408–15.
- Caillot D, Casasnovas O, Bernard A, et al. Improved management of invasive pulmonary aspergillosis in neutropenic patients using early thoracic computed tomographic scan and surgery. *J Clin Oncol* 1997; 15:139–47.
- Caillot D, Couaillier JF, Bernard A, et al. Increasing volume and changing characteristics of invasive pulmonary aspergillosis on sequential thoracic computed tomography scans in patients with neutropenia. *J Clin Oncol* 2001; 19: 253–9.
- Garey KW, Rege M, Pai MP, et al. Time to initiation of fluconazole therapy impacts mortality in patients with candidemia: a multi-institutional study. *Clin Infect Dis* 2006; 43: 25–31.

Reprints or correspondence: Dr. Paul E. Verweij, University Medical Center St. Radboud, PO Box 9101, Nijmegen 6500 HB, The Netherlands (p.verweij@mmb.umcn.nl).

**Clinical Infectious Diseases** 2007;44:1666–7

© 2007 by the Infectious Diseases Society of America. All rights reserved. 1058-4838/2007/4412-0026\$15.00  
DOI: 10.1086/519700

## Reply to Verweij et al.

TO THE EDITOR—Our thanks to Verweij et al. [1] for their cogent comments. Although data from our study [2] were not sufficient to independently establish that the patients in whom we identified a halo