

PDF hosted at the Radboud Repository of the Radboud University Nijmegen

The following full text is a publisher's version.

For additional information about this publication click this link.

<http://hdl.handle.net/2066/47993>

Please be advised that this information was generated on 2019-09-16 and may be subject to change.

Use of Onplants as Stable Anchorage for Facemask Treatment: A Case Report

He Hong^a; Peter Ngan^b; Han Guang Li^c; Liu Gong Qi^d; Stephen H.Y. Wei^e

Abstract: A hexagonal onplant of 7.7 mm diameter was placed on the palatal bone of the maxilla in an 11-year five-month-old female patient with a Class III malocclusion and midface deficiency. Elastic traction (400 g per side) was applied from a facemask to the onplant at 30° to the occlusal plane 12 hours per day for 12 months. The maxilla was found to have displaced forward and downward by 2.9 mm. The mandible was rotated downward and backward. There was a 3° increase in mandibular plane angle and an increase in the lower face height. Clinically, there was a significant improvement in midface esthetics, noted by an increase in fullness of the infraorbital region and correction of the skeletal discrepancy between the maxillary and mandibular jaw relationship. Contrary to the reports that use teeth rather than onplants as anchorage, there was no forward movement of the maxillary molars and minimal extrusion of the maxillary molars. These results suggest that onplants can be used as an extremely stable anchorage for maxillary orthopedic facemask treatment. (*Angle Orthod* 2005;75:453–460.)

Key Words: Orthodontics; Onplants; Maxillary protraction; Anchorage

INTRODUCTION

Protraction facemask has been used in the early treatment of Class III patients with maxillary deficiency or mandibular prognathism (or both).¹⁻³ The objective of the treatment is to displace the maxilla forward by the application of force from the facemask to the facial sutures through the dentition. However, clinical studies have shown that the occlusal changes are a combination of skeletal and dental changes that resulted in forward movement of the maxilla, proclination of the maxillary incisors, downward and backward rotation of the mandible, and the retroclination of the mandibular incisors.¹⁻⁷

Most of these studies used tooth-borne devices as an-

chorage for maxillary protraction. Significant anchorage loss has been reported using anchorage devices such as the maxillary expansion appliances, Nance and lingual arches.¹⁻⁶ These undesirable effects include excessive forward movement of maxillary molars and maxillary incisors and extrusion of the maxillary molars, especially in Class III patients with a maxillary arch length deficiency and open-bite tendency. There is a need for a device that can provide an extremely stable and fixed anchorage for maxillary orthopedics to allow a pure forward movement of the maxilla.

The use of ankylosed primary canines as anchorage for maxillary orthopedics is a viable alternative method.^{8,9} However, it limits the time available for treatment because the anchored teeth inevitably resorb as their permanent successors erupt. Osseointegrated implants are another viable adjunct to facemask therapy. Implants have been demonstrated to be biologically compatible with applied orthodontic forces.^{10,11} They have also been shown to resist orthopedic forces in animal models^{12,13} and clinical situations.¹⁴ However, patients who need orthodontic treatment generally have a complete dentition with no available sites for implant placement. Some investigators have used the retromolar area,¹⁵ zygomatic buttress,¹⁶ or palatal region¹⁷ as alternative sites. Umemori et al¹⁸ applied titanium miniplates to the mandibular corpus area and used them as anchorage for the intrusion of a mandibular posterior segment. Erverdi et al¹⁶ used zygomatic anchorage for the treatment of anterior open bite. Singer et al¹⁰ placed implants in the zygomatic buttress of the maxilla and used it as anchorage for facemask therapy. This is quite ideal because the fixture

^a Associate Professor and Chair, Department of Orthodontics and Key Lab for Oral Biomedical Engineering of Ministry of Education, School of Stomatology, Wuhan University, Wuhan, China.

^b Professor and Chair, Department of Orthodontics, School of Dentistry, West Virginia University, Morgantown, West Virginia.

^c Lecture Speaker, Department of Orthodontics, Wuhan University, School of Stomatology, Wuhan, China.

^d Associate Professor and Chair, Department of Oral and Maxillofacial Surgery, Wuhan University, School of Stomatology, Wuhan, China.

^e Professor and Dean Emeritus, Faculty of Dentistry, University of Hong Kong, Hong Kong.

Corresponding author: Peter Ngan, DMD, Department of Orthodontics, School of Dentistry, West Virginia University, 1076 Health Science Center North, PO Box 9480, Morgantown, WV 26506 (e-mail: pngan@hsc.wvu.edu).

Accepted: May 2004. Submitted: April 2004.

© 2005 by The EH Angle Education and Research Foundation, Inc.

TABLE 1. Changes of cephalometric measurements ($^{\circ}$ and mm) of onplant patient before treatment (T₁) and after 12 months of treatment with protraction facemask (T₂)

	T ₁	T ₂	T ₂ - T ₁
Maxillary position (SNA)	76.0	80.2	4.2
Mandibular position (SNB)	78.2	76.5	-1.7
Sagittal jaw relation (ANB)	-2.2	3.7	5.9
Palatal plane angle (Ans-Pns/SN)	11.2	8.8	-2.4
Mandibular plane angle (Tgo-M/SN)	36.8	39.0	2.2
Lower face height (Ans-Me)	65.2	68.8	3.6
Occlusal plane angle (OL/SN)	7.0	18.8	11.8
Overjet	-3.0	+2.0	5.0
Maxillary incisal angle (I ₁ -I ₂ /SN)	98.9	95.5	-3.4
Mandibular incisal angle (I ₁ -I ₂ /Tgo-M)	89.0	89.0	0.0
Maxillary length (Co-A)	77.9	83.9	6.0
Mandibular length (Co-Gn)	107.0	111.2	4.2
Maxillo-mandibular difference	29.1	27.3	1.8
Wits' analysis	-6.1	-1.0	5.1

was placed on basal bone rather than alveolar bone, and there were no adjacent tooth structures. The main disadvantage is the extent of the surgical procedure and the soft tissue irritation associated with the location of the fixture.

Use of onplants for orthodontic or orthopedic anchorage is a new area of research and investigations on this subject are limited. In 1995, Block and Hoffman¹⁹ reported the successful use of an onplant, a subperiosteal disk, as orthodontic anchorage in an experimental study in dogs and monkeys. An onplant is a relatively flat, disk-shaped fixture with a textured, hydroxyapatite-coated surface for integration with bone. These authors reported that the new device could resist continuous orthodontic force up to 11 oz. Feldman et al²⁰ presented the clinical procedures to produce rigid fixation for selected teeth with a palatal onplant. Janssens et al²¹ presented a case report on using onplant as orthodontic anchorage to extrude two impacted molars in a patient with tooth aplasia. The use of an onplant as absolute orthopedic anchorage for maxillary protraction has not been reported in the literature. The purpose of this case report is to report the use of an onplant as absolute anchorage for orthopedic facemask treatment in a young patient with a developing Class III malocclusion.

CASE REPORT

An 11-year five-month-old Chinese female was seen in the Department of Orthodontics School of Stomatology, Wuhan University, Wuhan, Hubei Province, China. Extraoral examination revealed a concave facial profile characterized by a maxillary retrusion with hypoplasia of the infraorbital region. Intraoral examination revealed an anterior crossbite with a reverse overjet of 3 mm (Figure 1). There was no anteroposterior centric relation discrepancy on closure. The transverse width was within normal limits with a dental crossbite in the premolar region. The maxillary midline was centered in the face and the mandibular midline was off two mm to the patient's left side. The maxillary

incisors were within normal limit (upper incisor to palatal plane = 110 $^{\circ}$), and the mandibular incisors were slightly retroclined (lower incisor to mandibular plane = 89 $^{\circ}$). The molar relationship was half-step Class III. There was crowding in both the maxillary and mandibular arches with a blocked-out maxillary right canine. Temporomandibular joint function was normal. There was no pain on palpation, no clicking, popping, or crepitus noise, and a normal range of motion.

Cephalometric analysis indicated a mild skeletal Class III pattern due to a retrusive maxilla (SNA = 76 $^{\circ}$, SNB = 78.2 $^{\circ}$, ANB = -2.2 $^{\circ}$). The occlusal plane was tilted 7 $^{\circ}$ to SN and the mandibular plane was 36.8 $^{\circ}$ to SN (Figure 2).

Treatment plan

The patient was concerned about her dental and facial esthetics. Two treatment plans were discussed with the patient and her parents. The first option was to delay treatment until growth was completed and then use orthodontic treatment in combination with orthognathic surgery to advance the maxilla. The second option was to use a facemask combined with orthodontic treatment to correct the anterior crossbite and improve facial esthetics. The patient chose to proceed with the latter because of a desire to improve her dentofacial appearance. The patient was informed that although facemask treatment may be able to correct the anterior crossbite, it did not eliminate the possibility that orthognathic surgery may eventually be needed to correct the jaw discrepancy. Because of the severe arch length deficiency in the maxillary arch, the use of an onplant as anchorage for maxillary protraction was suggested. The patient agreed to the placement of an onplant and treatment with maxillary protraction for approximately 12 months followed by fixed orthodontic appliances to eliminate crowding of the dentition.

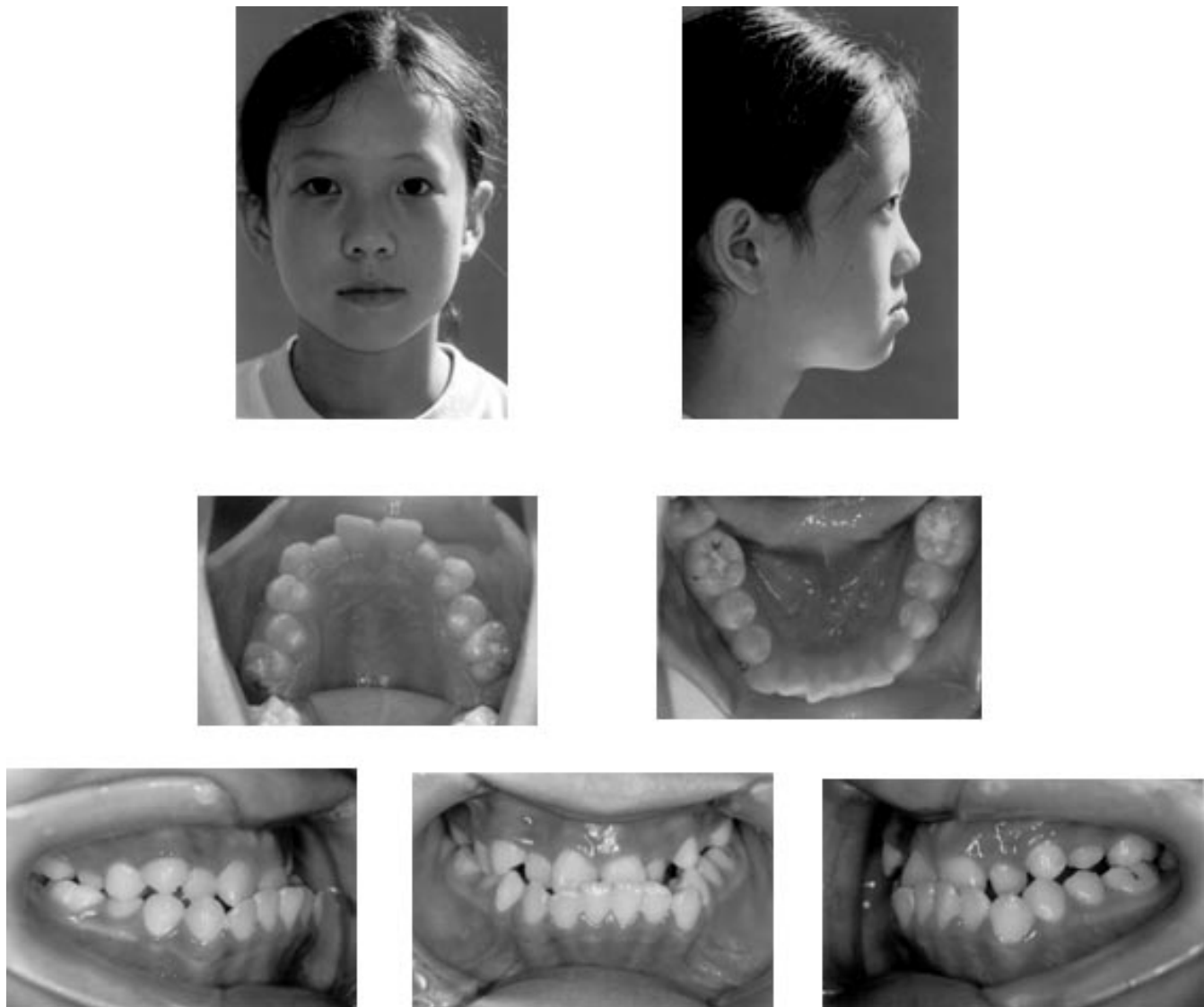


FIGURE 1. Pretreatment extra-oral and intra-oral photographs.

Treatment progress

A 7.7-mm hexagonal onplant (Nobel Biocare, Gotenberg, Sweden) was surgically placed on the flat part of the palatal bone near the maxillary molar region. An incision was made in the palatal mucosa from the premolar area toward the midline. The tissue was tunneled under in full-thickness fashion, past the midline to the eventual implantation site. The onplant was then slipped under the soft tissue and brought into position, and the incision was sutured. The onplant was placed as close to the midline as possible but not on the midsagittal maxillary suture, so as not to disturb lateral growth with the surgical operation. A vacuformed stent was worn for 10 days to place pressure on the onplant. This step was crucial to minimize the movement of onplant during osseointegration, which took approximately three to four months.

Once integration was achieved, the onplant was exposed,

its cover screw removed, and an open-tray impression was taken. A simulated implant was used in pouring the working cast. A transpalatal arch was attached to the onplant and soldered to a silver cast splint, which was connected to all the maxillary teeth (Figure 3A).

Maxillary protraction was started four months after placement of the onplant. A Petit facemask (Ormco Corporation, Glendora, Calif) was fitted with elastics that delivered approximately 400 g of force on each side (Figure 3B). The force was directed from the canine area, 30° from the occlusal plane, to counteract the anticlockwise rotation of the palatal plane. Patient was instructed to wear the facemask for 12 hours per day. Traction was continued for 12 months until sufficient clinical movement of the maxilla had been achieved to improve the midface esthetics. At the end of the protraction period, the onplant was removed using a surgical elevator. All surgical procedures were carried

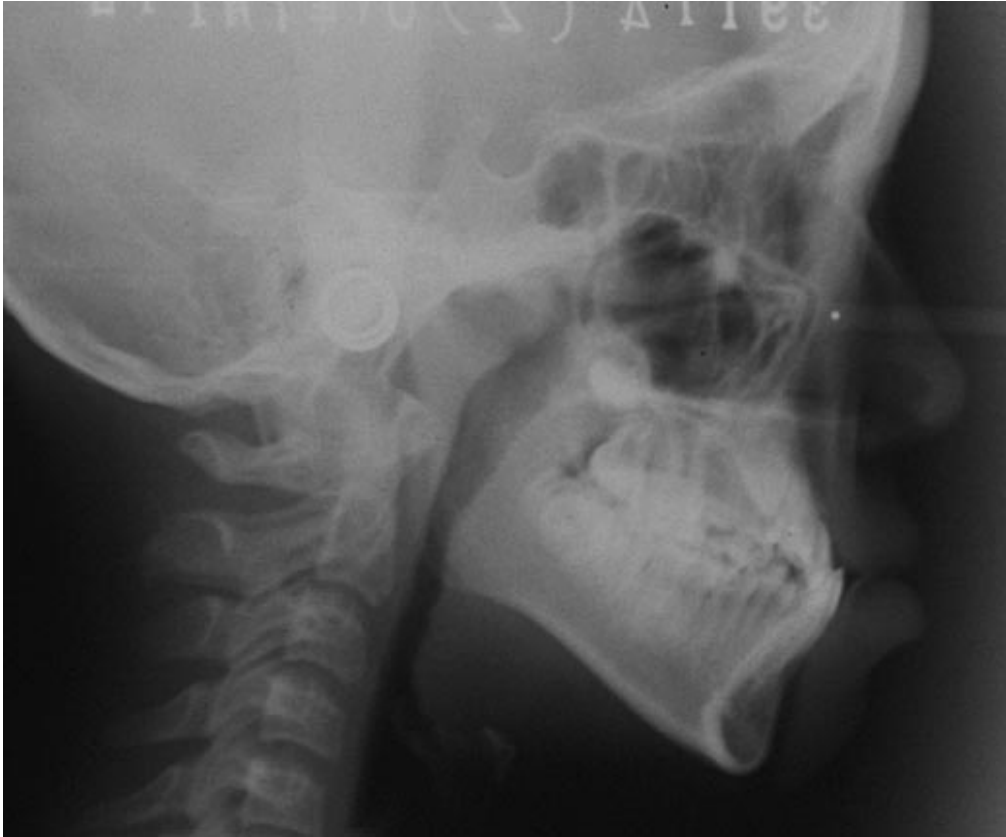


FIGURE 2. Pretreatment lateral cephalometric radiograph.

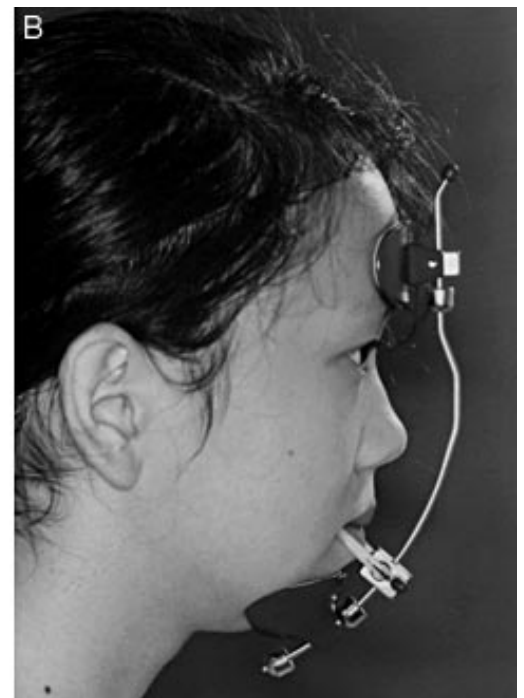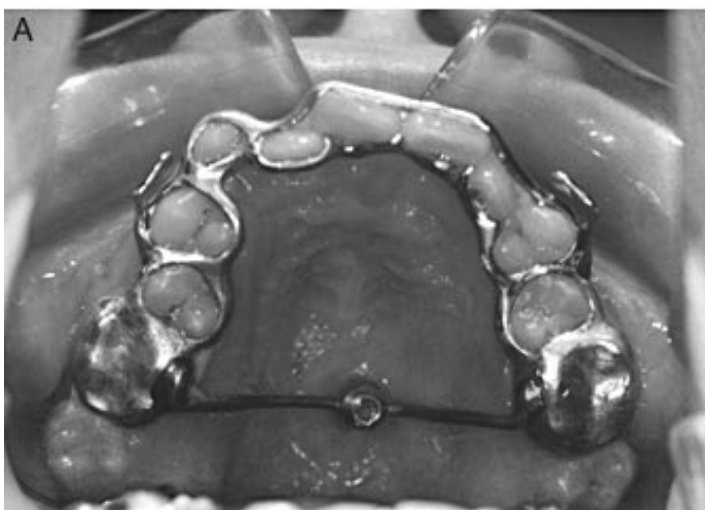


FIGURE 3. (A) Placement of onplant and cast splint as anchorage for maxillary protraction. (B) Protraction facemask with elastics pulling 30° forward and downward from the occlusal plane.

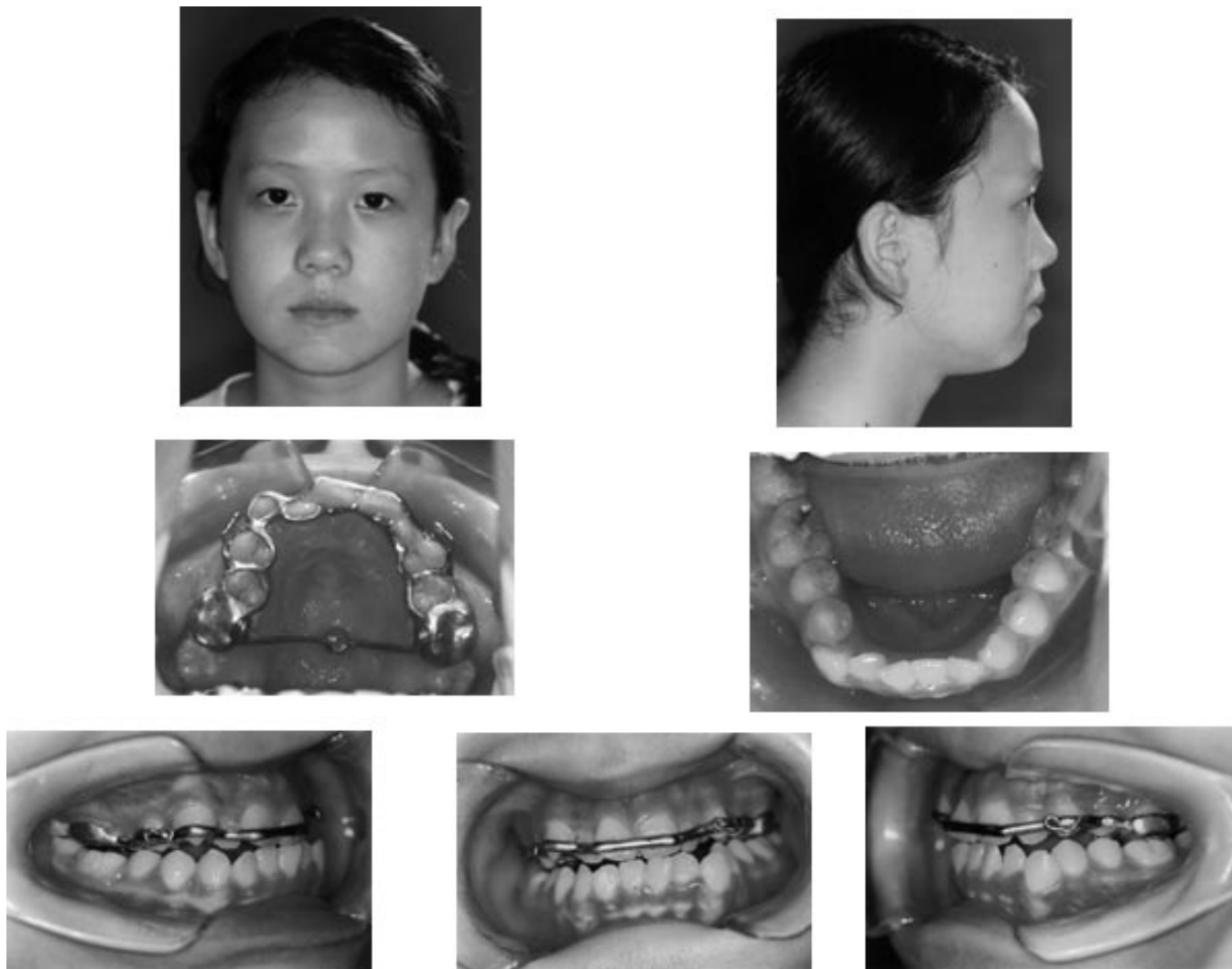

FIGURE 4. Twelve-month progress extra-oral and intra-oral photographs showing improvement in midface profile and overjet.

out under local anesthesia. The peri-onplant soft tissue healed uneventfully within two weeks. The patient's acceptance regarding surgical effects was positive, and postoperative pain and discomfort symptoms were negligible.

Discussion of treatment results

The application of an anteriorly directed force from a facemask to an osseointegrated onplant placed in the palatal bone resulted in a significant improvement in midface esthetics (Figures 4 and 5). This was noted by an increase in fullness of the infraorbital region and the correction of the skeletal discrepancy between the maxillary and mandibular jaw relationship (ANB from -2.2° to 3.7° , Wits from -6.1 mm to -1.0 mm). Pre- and post-treatment cephalometric radiographs were superimposed on the anterior cranial base structures at Sella as described by Bjork and Skieller²² to demonstrate the skeletal changes (Figure 6 and Table 1).

To verify whether the onplant was stable during application of orthopedic force, superimposition was also per-

formed on the lingual contour of the maxilla along ANS-PNS to detect any movement of the onplant.

The results showed no movement of the onplant during both the six-month and 12-month period of protraction. The onplant was then used as an internal reference point to measure spatial movement of the maxilla, which was found to have been displaced 2.9 mm horizontally and 2.9 mm vertically during the 12-month period of protraction. This movement is more than the average horizontal movement of two mm reported by other investigators using tooth-borne appliances as anchorage for a facemask alone or in combination with expansion techniques.¹⁻⁶

It has been shown that transverse expansion of the maxilla may result in an anterior movement of point A, and the whole maxillary complex may be movable up to seven to eight years of age.^{6,23} Because the maxilla articulates with nine other bones of the craniofacial complex, palatal expansion may disarticulate the maxilla and initiate cellular response in the sutures, allowing a more positive reaction

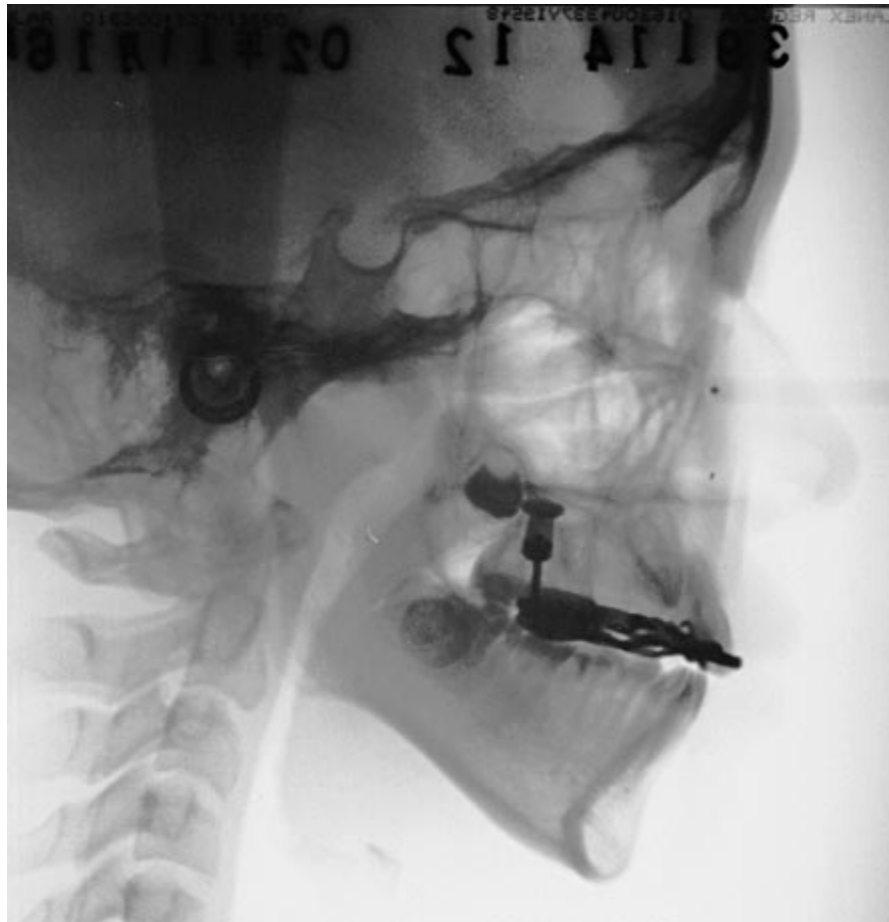

FIGURE 5. Six-month progress lateral cephalometric showing improvement in overjet.

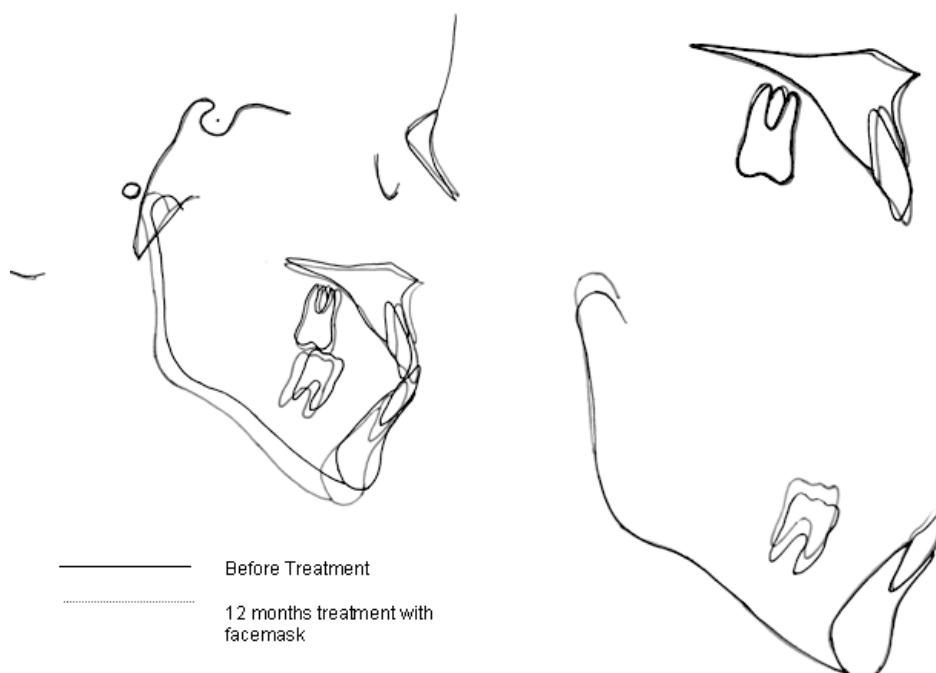


FIGURE 6. Superimposition of 12-month treatment radiograph with pretreatment radiograph.

to protraction forces.²⁴ It is therefore of interest to note that in the present case report, no transverse expansion was necessary to obtain a similar amount of displacement of the maxilla.

Superimposition of the pre- and post-treatment cephalometric radiographs on the lingual contour of the maxilla revealed no mesial movement of the maxillary molars. This is in contrast to maxillary protraction with tooth-borne appliances that usually results in mesial movement of maxillary molars and the loss of arch length.¹⁻⁶ The maxillary palatal plane angle was tipped 2.4° in an anticlockwise direction despite the 30° downward and forward pull of the facemask to counteract such a rotational effect. This is acceptable when protraction is carried out along the occlusal plane below the center of resistance of the maxilla.²⁵ Long-term studies with protraction facemask have shown that this effect was transient with the palatal plane and returns to normal inclination four years after completion of maxillary protraction.²⁶

The occlusal plane angle was increased 11.8°. Extrusion of the maxillary molars was not observed. This differs from facemask treatment with tooth-borne appliances where a change in the occlusal plane is a combination of downward movement of the posterior nasal spine and extrusion of maxillary molars.¹⁻⁶ The 3° increase in the SN-mandibular plane angle and an overall increase in the lower face height by 3.6 mm are similar to those reported by other investigators¹⁻⁷ and is caused by the downward movement of the maxilla and downward and backward rotation of the mandible. These transient changes are favorable for dental correction in brachyfacial individuals with deep overbite. Long-term studies showed a return of the mandibular plane angle to pretreatment level four years after protraction facemask treatment.²⁶

Long-term stability of early facemask treatment depends on the ability of treatment changes to compensate for subsequent growth, which is usually unfavorable. Elimination of dental changes such as extrusion and mesial movements of upper molars by using onplant as anchorage may be helpful in improving the stability of facemask treatment. Another advantage of using onplant as compared with implants as anchorage is that onplant can be placed anywhere on the anterior part of the hard palate. In contrast, placement of implants in this area creates a potential risk of damage to the roots of adjacent teeth because of the length of the implant fixtures available. Placement of an implant on the anterior part of the hard palate would not only have a risk of root damage of anterior teeth but also the risk of penetration of the nasal floor.

Clinicians should be aware that complications such as soft tissue irritation can develop after placement of an onplant. This irritation usually subsides over a two-month period. Other possible problems that could arise include the failure of integration and loosening of the onplant because of torsional force.²⁷

CONCLUSIONS

This is the first report of the orthopedic treatment of a young female patient with significant maxillary hypoplasia, using an onplant to achieve skeletal anchorage along with maxillary protraction to correct the anterior dental crossbite and improve the skeletal discrepancy.

ACKNOWLEDGMENT

This study was supported by the Foundation of Health Bureau in Hubei Province, JX1A13.

REFERENCES

1. Nartallo-Turley PE, Turley PK. Cephalometric effects of combined palatal expansion and facemask therapy on Class III malocclusion. *Angle Orthod.* 1998;68:217-224.
2. Baccetti E, McGill JS, Franchi L, McNamara JA Jr, Tollaro I. Skeletal effects of early treatment of Class III malocclusion with maxillary expansion and facemask therapy. *Am J Orthod Dentofacial Orthop.* 1998;113:333-343.
3. Ngan P, Yiu C, Hägg U, Wei SHY. Cephalometric and occlusal changes following maxillary expansion and protraction. *Eur J Orthod.* 1998;20:237-254.
4. Hägg U, Tse A, Bendeus M, Rabie BM. Long-term follow-up of early treatment with reverse headgear. *Eur J Orthod.* 2003;25:95-102.
5. Lertpitayakun P, Miyajima K, Kanomi R, Sinha PK. Cephalometric changes after long-term early treatment with facemask and maxillary intraoral appliance therapy. *Semin Orthod.* 2001;7:169-179.
6. Delaire J. Maxillary development revisited: relevance to the orthopedic treatment of Class III malocclusions. *Eur J Orthod.* 1997;19:289-311.
7. Hiyama S, Suda N, Ishii-Suzuki M, Tsuki S, Ogawa M, Suzuki S, Kuroda T. Effects of maxillary protraction on craniofacial structures and upper-airway dimension. *Angle Orthod.* 2002;72:43-47.
8. Kokich VG, Shapiro PA, Oswald R, Koskinen-Moffett L, Clarren SK. Ankylosed teeth as abutments for maxillary protraction: a case report. *Am J Orthod.* 1985;88:303-307.
9. da Silva Filho OG, Ozawa TO, Okada CH, Okada HY, Carvalho RM. Intentional ankylosis of deciduous canines to reinforce maxillary protraction. *J Clin Orthod.* 2003;37:315-320.
10. Singer SL, Henry PJ, Rosenberg I. Osseointegrated implants as an adjunct to facemask therapy: a case report. *Angle Orthod.* 2000;70:253-262.
11. Keles A, Erverdi N, Sezen S. Bodily distalization of molars with absolute anchorage. *Angle Orthod.* 2003;73:471-482.
12. Turley PK, Shapiro PA, Moffett BC. The loading of bioglass-coated aluminum oxide implants to produce sutural expansion of the maxillary complex in the pigtail monkey. *Arch Oral Biol.* 1980;25:459-469.
13. Smalley WM, Shapiro PA, Hohl TH, Kokich VG, Branemark PI. Osseointegrated titanium implants for maxillofacial protraction in monkeys. *Am J Orthod Dentofacial Orthop.* 1998;94:285-295.
14. Enacar A, Giray B, Pehlivanoglu M, Iplikcioglu H. Facemask therapy with rigid anchorage in a patient with maxillary hypoplasia and severe oligodontia. *Am J Orthod Dentofacial Orthop.* 2003;123:571-577.
15. Robert WE, Marshall KJ, Mozsary PG. Rigid endosseous implants utilized as anchorage to protract molars and close an atrophic extraction site. *Angle Orthod.* 1990;60:135-152.
16. Erverdi N, Tosun T, Keles A. A new anchorage site for the treat-

- ment of anterior open bite: zygomatic anchorage. A case report. *World J Orthod.* 2002;3:147–153.
17. Wehrbein H, Merz BR, Diedrich P. Palatal bone support for orthodontic implant anchorage: a clinical and radiological study. *Eur J Orthod.* 1999;21:65–70.
 18. Unemori M, Sugawara J, Mitani H, Nagasaka H, Kawamura H. Skeletal anchorage system for openbite correction. *Am J Orthod Dentofacial Orthop.* 1999;115:166–174.
 19. Block MS, Hoffman DR. A new device for absolute anchorage for orthodontics. *Am J Orthod Dentofacial Orthop.* 1995;107:251–258.
 20. Feldmann I, Feldmann H, Lundstrom F. Nobel Biocare onplants for orthodontic anchoring. A preliminary report on 10 patients. *J Parodontol Implant Oral.* 2000;19:361–371.
 21. Janssens F, Swennen G, Dujardin T, Glineur R, Malavez C. Use of an onplant as orthodontic anchorage. *Am J Orthod Dentofacial Orthop.* 2002;122:566–570.
 22. Bjork A, Skieller V. Facial development and tooth eruption. An implant study at the age of puberty. *Am J Orthod.* 1972;62:339–383.
 23. Haas AJ. Palatal expansion: just the beginning of dentofacial orthopedics. *Am J Orthod.* 1970;57:219–255.
 24. Baik HS. Clinical results of maxillary protraction in Korean children. *Am J Orthod Dentofacial Orthop.* 1995;108:583–592.
 25. Hata S, Itoh T, Nakagawa M, Kamogashira K, Ichikawa K, Matsumoto M, Chaconas SJ. Biomechanical effects of maxillary protraction in the craniofacial complex. *Am J Orthod Dentofacial Orthop.* 1987;91:305–311.
 26. Ngan PW, Hägg U, Yiu C, Wei SHY. Treatment response and long-term dentofacial adaptations to maxillary expansion and protraction. *Semin Orthod.* 1997;3:255–264.
 27. Celena F, Hochman MN. Absolute anchorage in orthodontics: direct and indirect implant-assisted modalities. *J Clin Orthod.* 2000;34:397–402.