

PDF hosted at the Radboud Repository of the Radboud University Nijmegen

The following full text is a publisher's version.

For additional information about this publication click this link.

<http://hdl.handle.net/2066/47428>

Please be advised that this information was generated on 2019-10-22 and may be subject to change.

Recurrent pancreatitis after trimethoprim-sulfamethoxazole rechallenge

M.W.J. Versleijen¹, A.H.J. Naber^{1*}, N.P. Riksen¹, G.J. Wanten¹, F.M.J. Debruyne²

Departments of ¹Gastroenterology and Hepatology, and ²Urology, Radboud University Nijmegen Medical Centre, PO Box 9101, 6500 HB Nijmegen, the Netherlands, tel.: +31 (0)24-361 47 60, fax: +31 (0)24-355 79 57, e-mail: T.Naber@mdl.umcn.nl, *corresponding author

ABSTRACT

We report a female patient who repeatedly developed pancreatitis after trimethoprim-sulfamethoxazole (TMP/SMX) use. During childhood she had undergone an ureterosigmoidostomy after which she had been on TMP/SMX 480 mg daily as prophylaxis for pyelonephritis for many years. The patient presented with abdominal pain caused by acute pancreatitis. No other cause, except for TMP/SMX use, could be identified. A causal relationship was confirmed by relapse of the pancreatitis after rechallenge. Our case is unique in demonstrating that acute pancreatitis related to the use of TMP/SMX may occur even after long-term treatment. We advise that the medication is discontinued immediately if a causal relationship with pancreatitis is suspected.

KEYWORDS

Co-trimoxazole, drugs, pancreatitis, rechallenge, trimethoprim-sulfamethoxazole

INTRODUCTION

Drug-related acute pancreatitis remains an uncommon clinical entity. Some cases of pancreatitis associated with the use of trimethoprim-sulfamethoxazole (TMP/SMX) have been reported previously (*table 1*).¹⁻⁶ In all of these, clinical symptoms occurred within days to weeks after the onset of treatment. We report a case that is unique in that acute pancreatitis occurred after many years of treatment with TMP/SMX. Furthermore, a causal relation was demonstrated by recurrent symptoms following drug rechallenge.

Table 1 Documented case reports of TMP/SMX-induced acute pancreatitis

Reference	Indication for TMP/SMX use	Daily TMP/SMX treatment (mg)	Onset (days) of pancreatitis after start of TMP/SMX	Onset of pancreatitis after rechallenge
1	Occipital abscess with <i>Nocardia asteroides</i>	960/4800	7	3
2	Urinary tract infection	320/1600	Only hepatitis after first exposure	'Several days' (hepatitis and pancreatitis)
3	Ear infection	320/1600	5	No rechallenge
4	Occipital abscess with <i>Nocardia</i>	1600/8000	42	No rechallenge
5	<i>Pneumocystis carinii</i> pneumonia (HIV pos.)	1280/6400	10	No rechallenge
6	<i>Pneumocystis carinii</i> pneumonia (HIV pos.)	900	6	No rechallenge

CASE REPORT

A 53-year-old woman presented with epigastric pain, radiating to the back. Her history revealed an ureterosigmoidostomy performed at the age of four years, according to the Coffey technique, because of extrophia vesicae. Next, she developed numerous episodes of pyelonephritis for which treatment with prophylactic antibiotics in the form of TMP/SMX (480 mg daily) had been initiated more than twenty years before. In addition, in later years hyperthyroidism and ulcerative colitis were diagnosed. Also, she developed a prolapsed uterus for which vaginal surgery was performed. At the time of presentation, she was not taking any drugs other than TMP/SMX.

The patient complained of continuous, left-sided epigastric pain, radiating to the back, which had been present for four days. The pain reminded her of an episode, one year earlier, during which she suffered from epigastric pain and nausea that increased after eating. At that time, the serum amylase had been normal.

During the current episode of epigastric pain she did not report nausea, vomiting or weight loss, and she had a good appetite. There was no alcohol or nicotine abuse. Physical examination was not remarkable, except for a mild tenderness in the epigastric region and some percussion pain in the left kidney region. There was no hepatosplenomegaly. Laboratory evaluation revealed an increase in the serum amylase, a metabolic acidosis and symptoms of inflammation (table 2). Other routine laboratory values were normal. Plain abdominal X-ray only showed a colon filled with faeces. Abdominal ultrasonography was not remarkable except for a uterus myomatosis. The pancreas could not be visualised due to air-filled intestines.

Gastroduodenoscopy showed no abnormalities, especially not in the peripapillary region. Therefore, the diagnosis of acute pancreatitis was made. The patient was treated conservatively (nil by mouth) and received paracetamol 1 g/6 h, as a suppository, for pain relief. Bicarbonate was provided to correct the metabolic acidosis, which was ascribed to bicarbonate loss through the ureterosigmoidostomy. TMP/SMX was continued. The clinical condition improved within three days and the CRP and serum amylase level decreased to 124 mg/l and 151 U/l respectively. On the fourth day the patient was discharged. A magnetic resonance cholangiopancreatography (MRCP), which was performed after discharge, showed no abnormalities, especially no bile stones. The pain gradually decreased. Since pancreatitis can be caused by TMP/SMX, this antibiotic was replaced by ciprofloxacin. Eventually, the abdominal symptoms disappeared completely.

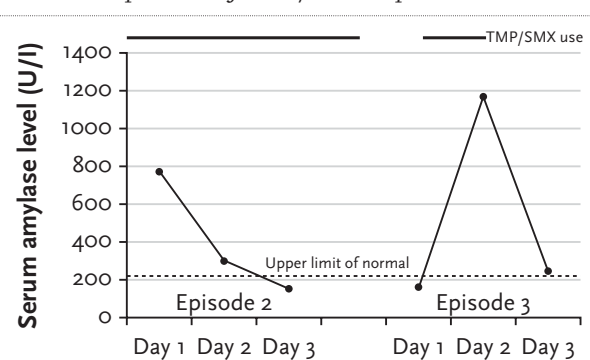
After some weeks of treatment with ciprofloxacin, the patient developed headaches, diarrhoea, fever and swollen axillary glands. Ciprofloxacin was stopped and TMP/SMX (480 mg twice a day) restarted. The serum amylase level was normal (156 U/l) on the day treatment was restarted (day 1, episode 3, figure 1). Within four days the epigastric pain recurred and the amylase level again increased to 1161 U/l (day 5, episode 3, figure 1). The diagnosis of a relapse of acute pancreatitis was made. TMP/SMX was now replaced by amoxicillin-clavulanic acid. After two days, the serum amylase decreased to 245 U/l and the epigastric pain disappeared. Because the patient developed abdominal discomfort while taking amoxicillin-clavulanic acid, trimethoprim was prescribed. In the following months she did not take any sulphonamides and did not have any further episodes of epigastric pain.

Table 2 Laboratory values at admission (day one, episode two)

CRP	141 mg/l
Amylase	782 (<220) U/l
pH	7.31
pO ₂	11.6 kPa
pCO ₂	5.1 kPa
Bicarbonate	18.9 mmol/l
Base excess	-6.8 mmol/l
Calcium	2.44 (2.20-2.60) mmol/l
Triglycerides	0.71 (0.8-2.0) mmol/l
Alkaline phosphatase	68 (<120) U/l
ASAT	25 (<40) U/l
ALAT	15 (<45) U/l
γGT	14 (<35) U/l

Normal values are given between brackets. CRP = C-reactive protein; ASAT = aspartate aminotranspeptidase; ALAT = alanine aminotranspeptidase; γGT = gamma glutamyl transpeptidase.

Figure 1 Serum amylase (Y-axis) in time in the absence or presence of TMP/SMX exposure



Since serum amylase was normal in the first episode of epigastric pain, this episode is not shown in the figure. Time between episode two and three is approximately two months. Day one of the second episode represents the visit to the emergency department because of epigastric pain. Day one of the third episode represents the day of restarting TMP/SMX.

DISCUSSION

Drugs are classified as having a definite relation with the development of pancreatitis if there is a temporal relationship between drug administration and the signs and symptoms of pancreatitis or a positive response to direct (re)challenge with the drug.⁷ Previous case reports have demonstrated/suggested an association between pancreatitis and TMP/SMX (*table 1*).¹⁻⁶ Sulfamethoxazole is generally held responsible since sulphonamide derivatives have been associated with pancreatitis while trimethoprim alone has not.^{8,9} A definite causal relationship between sulfamethoxazole administration and pancreatitis, shown by rechallenge, has only been demonstrated in a few cases.^{1,8} The pancreatitis-inducing mechanism remains unclear. An allergic reaction has been assumed.⁸

Here we report a patient who developed acute pancreatitis after having taken TMP/SMX for many years as prophylaxis for pyelonephritis. During her first episode of epigastric pain, the diagnosis of acute pancreatitis was considered, but based on her clinical condition and a normal serum amylase level, measured four days after the first symptoms, a diagnosis of gastric ulceration seemed more likely. Retrospectively, it seems probable that our patient had already suffered a bout of acute pancreatitis during that episode. During her second episode of epigastric pain, serum amylase levels were definitely elevated and acute pancreatitis was diagnosed. Known causes of acute pancreatitis include alcohol abuse, cholelithiasis, hyperlipidaemia, hypercalcaemia, pancreatic trauma, viral infections and drugs. Based on a negative history of alcohol abuse and pancreatic trauma, normal values of liver enzymes, triglycerides and calcium, and the absence of ulcers, bile stones and other liver or bile duct abnormalities on a plain abdominal X-ray, abdominal ultrasonography, gastro-duodenoscopy and MRCP, all of the above-mentioned causes could be excluded with the exception of drugs. This is supported by the fact that discontinuation of TMP/SMX treatment resulted in her symptoms disappearing completely. However, a causal relationship was finally confirmed when we observed a relapse of acute pancreatitis within four days of restarting TMP/SMX because of adverse effects to prophylaxis with ciprofloxacin. Since trimethoprim alone has not been associated with acute pancreatitis, we eventually decided to use trimethoprim as a prophylactic drug for pyelonephritis.

The interval between starting the cotrimoxazole and the onset of pancreatitis was long. For various drugs it is well known that complications do not occur immediately after the start of the drug therapy, as for instance for azathioprine. In a recent review paper it was stated that 'Cutaneous reactions are hypersensitivity reactions and they usually manifest immediately after exposure or re-exposure to the drug, unlike other adverse reactions, which might only manifest at high doses or after prolonged therapy'.¹⁰ The absence of a rash in the patient presented in this paper does not support the hypothesis of a hypersensitivity reaction as the cause of the pancreatitis.

Our case is unique in that it demonstrates a definite causal relationship between acute pancreatitis and TMP/SMX in a patient who had been taking this antibiotic continuously for more than 20 years. Based on this experience, we advise that this medication is immediately discontinued if a causal relationship with pancreatitis is highly suspected.

REFERENCES

1. Antonow DR. Acute pancreatitis associated with trimethoprim-sulfamethoxazole. *Ann Intern Med* 1986;104:363-5.
2. Brett AS, Shaw SV. Simultaneous pancreatitis and hepatitis associated with trimethoprim-sulfamethoxazole. *Am J Gastroenterol* 1999;94:267-8.
3. Alberti-Flor JJ, Hernandez ME, Ferrer JP, Howell S, Jeffers L. Fulminant liver failure and pancreatitis associated with the use of sulfamethoxazole-trimethoprim. *Am J Gastroenterol* 1989;84:1577-9.
4. Bartels RH, van der Spek JA, Oosten HR. Acute pancreatitis due to sulfamethoxazole-trimethoprim. *South Med J* 1992;85:1006-7.
5. Jost R, Stey C, Salomon F. Fatal drug-induced pancreatitis in HIV. *Lancet* 1993;341(8857):1412.
6. Floris-Moore MA, Amodio-Groton MI, Catalano MT. Adverse reactions to trimethoprim/sulfamethoxazole in AIDS. *Ann Pharmacother* 2003;37:1810-3.
7. Mallory A, Kern F Jr. Drug-induced pancreatitis: a critical review. *Gastroenterology* 1980;78:813-20.
8. Brazer SR, Medoff JR. Sulfonamide-induced pancreatitis. *Pancreas* 1988;3:583-6.
9. Rubin R. Sulfasalazine-induced fulminant hepatic failure and necrotizing pancreatitis. *Am J Gastroenterol* 1994;89:789-91.
10. Karpman E, Kurzrock EA. Adverse reactions on nitrofurantoin, trimethoprim and sulfamethoxazole in children. *J Urol* 2004;172:448-53.