

vasogenic edema as part of this secondary brain damage and as predictor of late neurodevelopmental outcome. Both, DWI and MRS provide not only a non-invasive insight into pathophysiological mechanisms of HI brain injury, they add significant improvement to the early diagnostic assessment of the asphyxiated neonate and to the prognostication of later outcome. This is especially important during the acute postnatal phase, when the child often is hardly amenable to clinical judgement.

MAGNETIC RESONANCE SPECTROSCOPY STUDIES OF EXPERIMENTAL PERINATAL ASPHYXIA

Ernest B. Cady, Dept. of Medical Physics and Bioengineering, University College London Hospitals, U.K.

³¹P MRS studies of infants who have suffered severe intrapartum cerebral hypoxia-ischaemia (HI) often exhibit normal energy metabolism for up to 24 hrs after resuscitation (1). Later, [phosphocreatine (PCr)]/[inorganic phosphate (Pi)], and eventually [adenosine triphosphate (ATP)], fall. This secondary energy failure (SEF) has been modelled in the newborn piglet (2). Recent studies have used this model to elucidate whether: a), intravenous magnesium sulphate (3) or cerebral hypothermia (4,5) were cerebroprotective; and b). ¹H MRS detected metabolic changes similar to those seen in newborn infants (6).

Spectra were acquired continuously from anaesthetised Large-White piglets (< 24 hr old) at 7 T using a 2.5 cm surface coil above the parietal lobes (2,6). Transient HI was induced by reversible, bilateral, carotid-artery occlusion and reducing FiO₂ to 0.12 until ATP was ~30% of baseline.

Quantitation of primary-insult and SEF severity showed magnesium sulphate did not ameliorate SEF (3). However, hypothermia (35°C for 12 hr) commenced at the start of resuscitation reduced both the extent of SEF (4) and the expected delayed rise in lactate (5). Concomitant with SEF development, ¹H MRS showed a rise in lactate and a slower decline in N-acetyl-aspartate peak-area ratios. Unlike [PCr]/[Pi], lactate peak-area ratios did not return to baseline during resuscitation.

The newborn-piglet model is useful for testing putative therapies. The clinical viability of cerebral hypothermia as a cerebroprotective is worth exploration. Cerebral lactate may prove a useful early marker of perinatal cerebral injury.

Acknowledgements. UCLH NHS Trust, The Medical Research Council, and Action Research for financial support.

References. 1. Azzopardi D et al (1989) *Pediatr Res* 25:445-451. 2. Lorek A et al (1994) *Pediatr Res* 36:699-706. 3. Penrice J et al (1997) *Pediatr Res* 41:443-447. 4. Thoresen M et al (1995) *Pediatr Res* 37:667-670. 5. Amess P N et al (1997) *Pediatr Res* 41:803-808. 6. Penrice J et al (1997) *Pediatr Res* 41:795-802.

IN VIVO ¹H MR SPECTROSCOPIC IMAGING AND DIFFUSION-WEIGHTED MRI IN EXPERIMENTAL HYDROCEPHALUS

K.P.J. Braun^{1,3}, R.A. de Graaf², W.P. Vandertop², R.H.J.M. Gooskens¹, C.A.F. Tulleken², K. Nicolay³
Dept. of Neurology¹ and Neurosurgery², and the Dept. of *in vivo* NMR³, Bijvoet Center for Biomolecular Research, Utrecht University, The Netherlands.

In order to investigate the severity and progression of ventricular dilatation, the occurrence of cerebral edema, and the localization of ischemic metabolic changes in hydrocephalus, *in vivo* ¹H MR

spectroscopic imaging (MRSI) and diffusion weighted MRI (DW MRI) were applied in 9 hydrocephalic rats at 1, 2, 4 and 8 weeks after injection of kaolin in the cisterna magna. Adiabatic single voxel ¹H MRS and MRSI pulse sequences and multislice DW spin-echo (4 *b* values) MRI experiments were performed on a 4.7 T magnet, while the rats were under anaesthesia and mechanically ventilated. Parametric images of the apparent diffusion coefficient (ADC) revealed a varying degree of ventriculomegaly in all rats, with different patterns of ventricular dilatation in time. Extracellular white matter edema, characterized by an increased ADC near the corpus callosum, sometimes extending into the external capsule, was only observed during the early stages of hydrocephalus, most extensively in cases of progressive ventriculomegaly. In gray matter regions of the cortex, caudate putamen and thalamus, ADC values were not changed compared to controls, suggesting that extracellular edema in hydrocephalus is confined to white matter. In spectra from control rats and one rat with a rapidly declining ventricular volume, no lactate could be detected. All other spectra of hydrocephalic rat brain showed a lactate peak, both in the early and late stages of hydrocephalus. Excessive T₂ prolongation of lactate was ruled out as a cause of the increased lactate resonance. In 2 cases of fatal hydrocephalus, lactate was abundantly observed throughout the whole brain. In all other hydrocephalic rats, at all time points after kaolin injection, lactate peaks were only detected in voxels containing cerebrospinal fluid, suggesting the accumulation of lactate in the ventricles, and / or an ongoing periventricular production of lactate as a consequence of cerebral ischemia in experimental hydrocephalus.

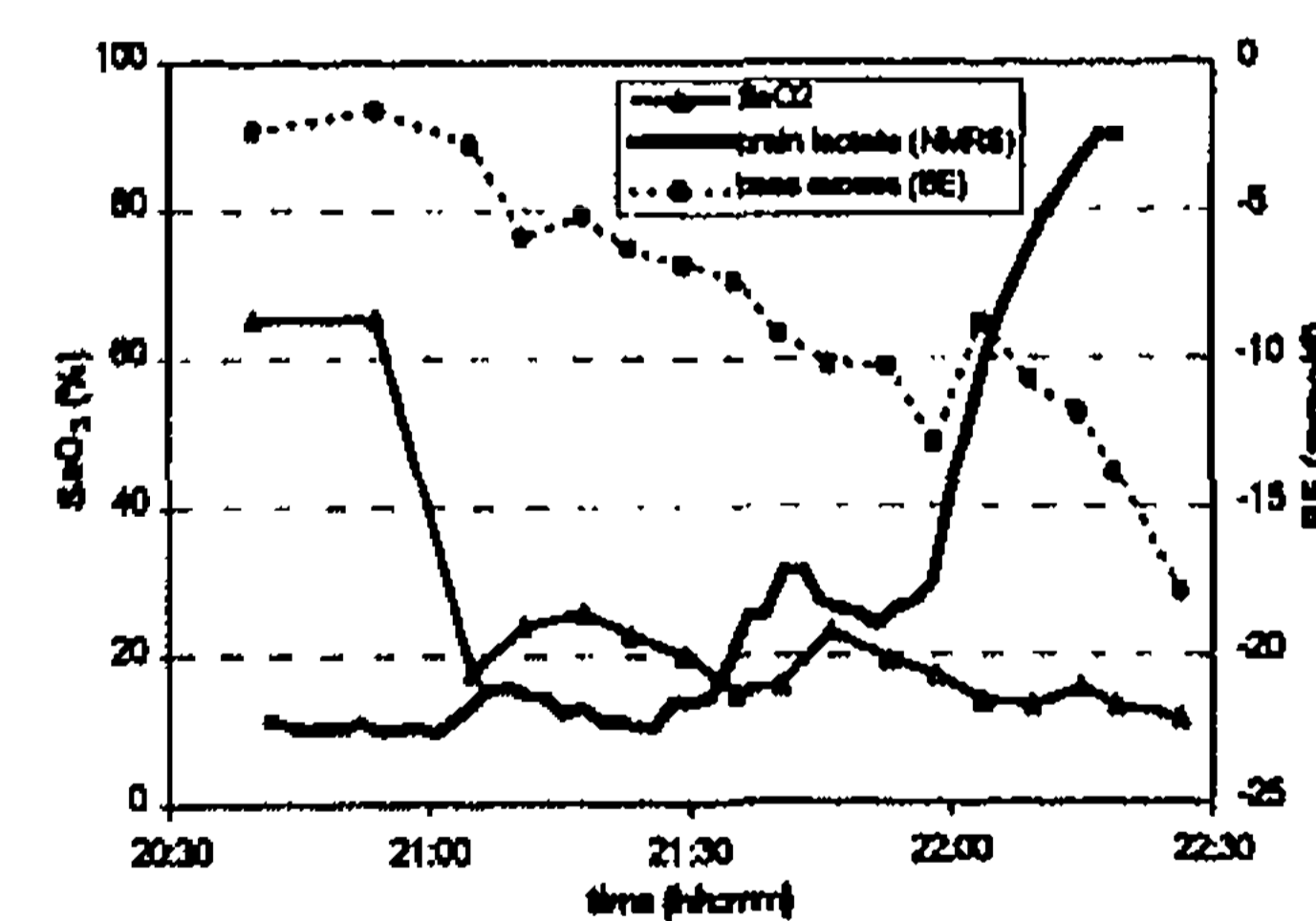
CEREBRAL LACTATE OF HYPOXIC FETAL LAMBS MEASURED BY ¹H-NMR SPECTROSCOPY

AM Van Cappellen van Walsum¹, A Heerschap², HW Jongsma¹, JG Nijhuis¹

¹Departments of Obstetrics & Gynaecology and ²Diagnostic Radiology, University Hospital Nijmegen, P.O. Box 9101, 6500 HB Nijmegen, The Netherlands

Introduction. Fetal hypoxia may result in neurological disability in post natal life. Fetal monitoring has the purpose to prevent fetal hypoxia. It is not known when fetal cerebral metabolism starts to deteriorate under hypoxic conditions. For optimal assessment of the fetal condition, more information is needed about the relation between cerebral metabolism and hypoxia. Elevated cerebral lactate in birth-asphyxiated infants is thought to predict neurological outcome¹. ¹H-Nuclear Magnetic Resonance Spectroscopy (¹H-NMRS) of the fetal brain enables us to get "in vivo" simultaneous sequential observations of cerebral metabolites, including lactate, in the same animal. In this study the relation between decreased fetal arterial oxygen saturation (SaO₂) and fetal cerebral compounds is investigated. **Subjects & Methods.** Under general anaesthesia five pregnant ewes of the Dutch Texel breed were operated between 120 and 128 days of gestation (term 147 days).

The fetal head was delivered by hysterotomy and fixed. The axillary artery was cannulated for frequent measurements of SaO₂, pH and base excess (BE). NMR experiments were performed at 1.5T. For localized NMR Spectroscopy a STEAM sequence was used (TR=2500 ms, TE=30 ms). The VOI was about 5cm³ located at the thalamus



level extending into both hemispheres. A surface coil was located on the vertex of the fetal head to receive the NMR signal in 2.5 min blocks. After baseline measurements the fetal SaO₂ was gradually reduced by lowering inspired oxygen of the ewe. **Results.** In all five fetal lambs cerebral NMR spectra showed signals assigned to inositol, choline, creatine, N-acetyl-aspartate (NAA) and lactate. The figure shows how lactate increased during hypoxia (SaO₂=10-20%) in a fetal lamb brain. At the end of the hypoxic period (pH=7.10, BE=-17 mmol/l) lactate was increased ten times as compared to normoxic control levels of about 0.5 mmol/l. Similar results were obtained for the other fetal lambs. **Conclusion.** Fetal cerebral lactate accumulation appears to be related to the progression of fetal hypoxia. These findings help to understand when fetal cerebral metabolism starts to deteriorate under hypoxic conditions (Supported by Nellcor Puritan Bennett Inc.).

1. J. Penrice et al. *Proton Resonance Spectroscopy of the brain in normal preterm and term infants, and early changes after perinatal hypoxia-ischemia. Pediatric research* 1996; 40: 6-14.