



Volumetric evaluation of CT images of adrenal glands in primary aldosteronism

M. S. Velema¹ · L. Canu^{1,2} · T. Dekkers¹ · A. R. M. M. Hermus¹ · H. J. L. M. Timmers¹ · L. J. Schultze Kool³ · H. J. M. M. Groenewoud³ · C. Jacobs⁴ · J. Deinum¹ · for the SPARTACUS Investigators

Received: 20 December 2020 / Accepted: 17 February 2021 / Published online: 5 March 2021
© Italian Society of Endocrinology (SIE) 2021

Abstract

Objectives To investigate whether adrenal volumetry provides better agreement with adrenal vein sampling (AVS) than conventional CT for subtyping PA. Furthermore, we evaluated whether the size of this contralateral adrenal was a prognostic factor for clinical outcome after unilateral adrenalectomy.

Methods We retrospectively analyzed volumes of both adrenal glands of the 180 CT-scans (88/180 with unilateral and 92/180 with bilateral disease) of the patients with PA included in the SPARTACUS trial of which 85 also had undergone an AVS. In addition, we examined CT-scans of 20 healthy individuals to compare adrenal volumes with published normal values.

Results Adrenal volume was higher for the left than the right adrenal (mean and SD: 6.49 ± 2.77 ml versus 5.25 ± 1.87 ml for the right adrenal; $p < 0.001$). Concordance between volumetry and AVS in subtyping was 58.8%, versus 51.8% between conventional CT results and AVS ($p = \text{NS}$). The volumes of the contralateral adrenals in the patients with unilateral disease (right 4.78 ± 1.37 ml; left 6.00 ± 2.73 ml) were higher than those of healthy controls reported in the literature (right 3.62 ± 1.23 ml $p < 0.001$; left 4.84 ± 1.67 ml $p = 0.02$). In a multivariable analysis the contralateral volume was not associated with biochemical or clinical success, nor with the defined daily doses of antihypertensive agents at 1 year follow-up.

Conclusions Volumetry of the adrenal glands is not superior to current assessment of adrenal size by CT for subtyping patients with PA. Furthermore, in patients with unilateral disease the size of the contralateral adrenal is enlarged but its size is not associated with outcome.

Keywords Adrenal gland neoplasms · Hyperaldosteronism · Tomography · X-ray computed · Primary aldosteronism · Diagnosis · CT-scanning · Diagnosis

Abbreviations

ADX	Adrenalectomy
APA	Aldosterone-producing adenoma
ARR	Aldosterone-to-renin ratio
AVS	Adrenal vein sampling
BAH	Bilateral adrenal hyperplasia
DDD	Defined daily doses

ICC	Intraclass correlation coefficient
MRAs	Mineralocorticoid receptor antagonists
PA	Primary aldosteronism

Introduction

Primary aldosteronism (PA) is an endocrine disorder caused by adrenal hypersecretion of aldosterone resulting in hypertension. PA is generally classified into two subtypes: aldosterone-producing adenoma (APA) and bilateral adrenal hyperplasia (BAH) which can be distinguished by adrenal CT-scan or adrenal vein sampling (AVS) [1]. APA is mainly treated by adrenalectomy (ADX), and BAH by mineralocorticoid receptor antagonists (MRAs).

Both subtyping procedures have their limitations, occasionally resulting in biochemical failure after ADX [2]. The concordance between CT and AVS results is disappointingly

✉ M. S. Velema
marieke.velema@radboudumc.nl

¹ Department of Internal Medicine, Radboud University Medical Center, Nijmegen, The Netherlands

² Department of Experimental and Clinical Biomedical Sciences, University of Florence, Florence, Italy

³ Department of Radiology and Nuclear Medicine, Radboud University Medical Center, Nijmegen, The Netherlands

⁴ Department of Health Evidence, Radboud University Medical Center, Nijmegen, The Netherlands

low, around 60% [3]. In the SPARTACUS (Subtyping Primary Aldosteronism: A Randomized Trial Comparing Adrenal Vein Sampling and Computed Tomography Scan) trial, the only study thus far that has compared outcome after both subtyping modalities in a randomized prospective design [2], this was even lower with 50%. However, clinical outcome of adrenalectomy is similar when therapy is based on either CT or AVS in the SPARTACUS study.

No consensus exists on the criteria for adrenal enlargement on CT scan. Furthermore, the complex shape of the adrenal glands can complicate the interpretation of the two-dimensional images of CT. At our center we use, as a rule of thumb, that the thickness of the adrenal body or limb must be 7 mm or more for diagnosing an adenoma or hyperplasia, provided that density and, if contrast is administered, contrast wash-out are compatible with adenoma [4, 5]. Applying the same cut-off for both adrenals seems questionable, considering the difference in size of the right and left adrenal that has been reported previously [4]. An alternative for conventional two-dimensional measurement of the adrenal glands is three-dimensional volumetric evaluation [4]. It has been shown before that in PA patients adrenal volumes are higher than in controls, irrespective of the presence of an APA or BAH [6].

In the SPARTACUS study 20% of patients were not biochemically cured after CT-guided adrenalectomy. This raised the question whether conventional CT-interpretation might miss contralateral adrenal enlargement or overestimates unilateral enlargement. The first aim of the present study was to investigate whether adrenal volumetry has better agreement with AVS than conventional CT. If so,

volumetry might provide superior prediction of successful ADX than conventional reading. The second aim was to investigate whether this contralateral adrenal is indeed enlarged, as described by Degenhart et al. [6]. Our last aim was to evaluate whether the size of the contralateral adrenal was a prognostic factor for outcome after ADX.

Materials and methods

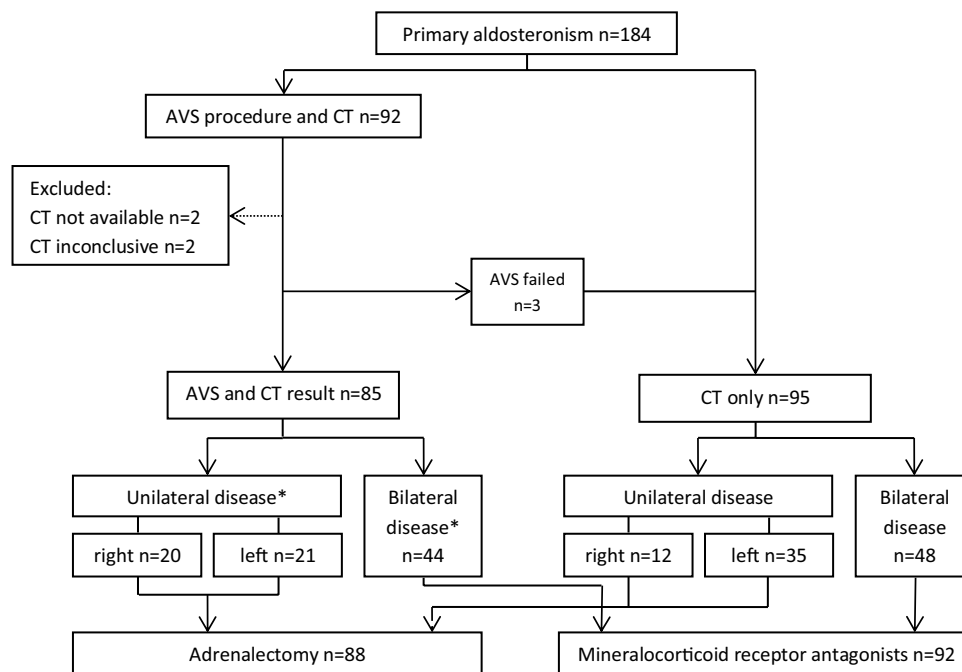
Patients

We analyzed the data from the SPARTACUS study in which 184 patients underwent adrenal CT-scanning and all had a clinical follow-up. In 92 of these patients an AVS was also performed (Fig. 1). Of these 92 patients, four were excluded, because CT-scans were inconclusive or not available. In another three patients AVS failed.

For this post-hoc analysis we included the 180 patients in whom CT result was available. PA was confirmed in all by salt loading test. In 85 patients AVS was used for subtyping, while in 95 patients subtyping was based on the results of the CT scan. Of all patients, 88 were treated by ADX and 92 by MRA-based treatment.

In addition, we used CT-scans from 20 healthy subjects without PA as controls. These adult participants had been screened for kidney donation and were included consecutively from 2018 back to 2017. No adrenal abnormalities had been described by the radiologist.

Fig. 1 Patient flow chart.
AVS=adrenal vein sampling.
*Based on AVS result



The purpose of this group was to check whether reported reference values for the volumes of normal adrenal glands [4] were applicable to patients at our center.

Study design

We performed a retrospective, observational study of CT-scans of adrenals of patients with PA. The images used to derive the data for this study have been collected in the framework of the randomized diagnostic multicenter SPARTACUS trial (registered at clinicaltrials.gov as NCT01096654) performed between July 2010 and August 2015 in 12 Dutch teaching and academic hospitals and 1 Polish hospital [2]. This trial compared adrenal CT and adrenal vein sampling for subtyping of PA. Briefly, patients randomized to CT or adrenal vein sampling underwent ADX if, respectively, unilateral adrenal enlargement or unilateral aldosterone hypersecretion with contralateral aldosterone suppression was demonstrated. All other patients received MRA-based treatment. All patients were further treated with conventional antihypertensive drugs according to a treatment algorithm targeting normal blood pressure. Approval for this study was obtained from institutional review boards of all participating centers, and informed consent was obtained from all participants. For the control cohort of CT-scans of 20 kidney donation participants our Ethics Committee judged that no detailed review was warranted given the non-intrusive and non-experimental character of the study. All CT-scans were anonymized before volumetric measurement.

CT examinations

Because the CT-scans were carried out in different centers, CT-scanners from different manufacturers were used (Table S1). The slice thickness ranged from 0.75 mm to 5 mm (0.75 $n=13$, 0.90 $n=3$, 1.0 $n=100$, 1.5 $n=1$, 2.0 $n=16$, 2.5 $n=3$, 3.0 $n=42$, 5.0 $n=2$).

In the cohort of healthy kidney donors all CT-scans were made according to a protocol in which the Toshiba Aquilion Precision CT-scanner was used (slice thickness 1 mm).

Conventional adrenal measurement on CT-scan

Adrenal glands with a transversal diameter of 7 mm or more of lesions in the body or limb on CT as judged by a radiologist were considered enlarged, indicating an adenoma or hyperplasia [2, 5].

Volumetry

For the current analysis, we measured volumes of both adrenals using an in-house developed annotation workstation (CIRRUS Essentials, Diagnostic Image Analysis

Group, Nijmegen, the Netherlands). Volumetric analysis was performed by two observers (MV $n=90$ and LC $n=90$), both endocrinologists and both trained by a radiologist with expertise in the field of adrenal disorders. Scans were randomly assigned to one of two observers (MV and LC). They were blinded for both AVS results and previous CT interpretations. We used the images from the venous phase when available ($n=167$) and the images without contrast enhancement in other cases ($n=13$). We performed volumetry at standard abdominal settings with a window width of 360 and a window level of 60. We used axial slices. We outlined the adrenals manually at twofold magnification. In the slices between those who were manually outlined, the software program calculated the expected demarcations of the adrenal. Then, we adapted these automatically generated lines when deemed appropriate. Finally the CIRRUS software calculates the volume in milliliters by adding the volumes determined of each slice.

For interobserver and intraobserver reliability, the analysis was performed twice by the two observers in 30 randomly selected CT-scans of patients with PA. The time between evaluations of the same CT by one and the same observer was at least 3 weeks.

In the cohort of healthy kidney donors, volumetry was carried out by an endocrinologist (MV) similarly, using the venous phase.

Statistical analysis

For clinical outcomes after ADX we used the PASO criteria [7]: complete biochemical success was defined as correction of hypokalemia (if present pre-surgery) and normalization of the aldosterone-to-renin ratio (ARR); in patients with a raised ARR post-surgery, aldosterone should be suppressed in a confirmatory test. Complete clinical success was defined as a normal blood pressure without the aid of antihypertensive medication. Total adrenal volume was defined as right plus left adrenal volumes. We expressed intensity of antihypertensive medication as defined daily doses (DDD, <https://www.whocc.no/ddd>). We compared the right and the left adrenal volumes with a paired-samples t test.

For the interobserver and intraobserver reliability analysis of the volume measurements we calculated an intraclass correlation coefficient (ICC) using a two-way mixed model, characterized by absolute agreement (single measures). ICC values ranging between 0 and 1 can be interpreted as follows: <0.4 poor agreement; 0.40 – 0.74 fair to good agreement, and ≥ 0.75 excellent agreement [8].

We compared measured volumes with published data on adrenal volumes in healthy subjects [4] with a one sample t test. In addition, we explored whether these reported reference values for adrenal volumes of these healthy individuals were applicable for Dutch people using a different

CT-scanner with a different protocol. For this purpose, we used the cohort of 20 kidney donors and compared the measured adrenal volumes with the reference values [4] with a one sample *t* test.

We considered the best cut-off value for enlargement of the adrenal gland by volumetry the value which yielded the best concordance with AVS result for the subtyping of PA. For this purpose, we calculated this concordance for every 0.125 SD volume in addition to the expected mean volume based on gender and side of the adrenal (from the expected mean up to plus three SD) [4]. The concordances between AVS and conventional CT and AVS and volumetry were compared with a Chi-square test. We performed a subgroup analysis for CT slice thickness (≤ 1 mm or > 1 mm).

To determine the predictive value of the contralateral adrenal volume we performed multivariable binary logistic regression analysis with the outcome after ADX (complete biochemical and complete clinical success yes/no) as dependent variable and univariate multivariable linear analysis with DDD after ADX as the dependent variable. The candidate predictors for outcome which, based on literature, could be associated with adrenal volume were included in the model: age, side, gender, CT slice thickness (≤ 1 mm or > 1 mm) and weight. We used backward stepwise Wald regression in which each step consisted of removing the variable with the smallest contribution to the model until only variables with $p < 0.05$ remained. To compare age and weight between the patients with unilateral versus bilateral disease, we used an unpaired *t* test.

p values of < 0.05 were considered to indicate statistical significance. All analyses were performed with the use of SPSS statistics 22.0 for Windows (SPSS, Inc., Chicago, IL). All results are given as mean \pm SD unless stated otherwise.

Results

Baseline characteristics of all patients with PA

The majority of the PA patients were male (78.9%) (Table 1). Unilateral disease, defined by either CT or AVS, was present in 88/180 patients, while bilateral disease was diagnosed in 92/180 patients (Fig. 1). There were no differences in weight and age between the patients with unilateral versus bilateral disease.

After ADX 73/88 (83.0%) patients had complete biochemical cure and 13/88 (14.8%) patients had complete clinical success.

Interobserver and intraobserver reliability

The ICC between both observers (MV and LC, $n = 30$) was 0.938 (95% CI 0.851–0.975) for the right adrenal and 0.937

Table 1 Baseline characteristics

Characteristics	All patients ($n = 180$)
Male, n (%)	142 (78.9)
Age, years	53.2 (9.6)
Polish, n (%)	32 (17.8)
BMI, kg/m ² , median (IQR)	28.4 (25.7–32.0)
Systolic ambulatory blood pressure 24 h, mmHg	146.1 (18.2)
Diastolic ambulatory blood pressure 24 h, mmHg	90.1 (11.1)
DDD antihypertensive medication, median (IQR)	3 (2–4)
DDD MRAs, median (IQR)	0 (0–0.6)
Serum potassium, mEq/l	3.5 (0.5)
ARR, pmol/mU ($n = 105$) ^a	194 (79–233)
Post SLT plasma aldosterone, pmol/l, median (IQR) ($n = 158$) ^b	412 (290–678)

Data presented as mean (SD) unless stated otherwise. Aldosterone ng/dl to pmol/l conversion factor 27.74

BMI body mass index, AVS adrenal vein sampling, DDD defined daily doses, ARR aldosterone-to-renin ratio, SLT salt loading test intravenously

^aIn $n = 75$ renin activity was measured

^bIn $n = 24$ post-SLT urinary aldosterone were measured

(95% CI 0.849–0.974) for the left adrenal. The ICC of intra-observer reliability of MV was 0.987 (95% CI 0.968–0.995, $n = 30$) for the right adrenal and 0.946 (95% CI 0.87–0.978, $n = 30$) for the left adrenal. The ICC of intraobserver reliability of LC was 0.945 (95% CI 0.869–0.978, $n = 30$) for the right adrenal and 0.924 (95% CI 0.820–0.969, $n = 30$) for the left adrenal.

Comparison of adrenal volumes of healthy individuals with published normal values

The adrenal volumes of our 20 subjects without adrenal disease were comparable with published normal values for adrenal volumes of healthy subjects by Schneller et al. (for men 5.18 ml versus 4.58, for women 3.79 versus 3.57, both $p > 0.05$, see Table S2) [4].

Measurements of adrenal volumes in PA patients

The adrenal volume in all 180 patients was 1.24 ml (95% CI 1.57–0.92) lower for the right adrenal (5.25 ± 1.87 ml) than for the left adrenal (6.49 ± 2.77 ml) (Table 2). The volume of the contralateral adrenals in the patients with left unilateral disease was 4.78 ml ± 1.37 , whereas this was 6.00 ml ± 2.73 in patients with right unilateral disease. Table 2 shows that these differences were similar in the patients in whom unilateral disease was established by CT or AVS. The volumes

Table 2 Adrenal volumes

	<i>n</i>	Right adrenal	Left adrenal	<i>p</i> value
All patients				
Total	180	5.25 ± 1.87	6.49 ± 2.77	< 0.001
Unilateral right	32	6.09 ± 1.98	6.00 ± 2.73	0.92
Unilateral left	56	4.78 ± 1.37	7.15 ± 2.84	< 0.001
Bilateral	92	5.24 ± 2.01	6.26 ± 2.69	< 0.001
AVS group^a				
Total	88	5.42 ± 2.22	6.83 ± 3.08	< 0.001
Unilateral right	20	6.17 ± 1.74	6.57 ± 2.60	0.40
Unilateral left	21	4.89 ± 1.80	7.43 ± 3.26	< 0.001
Bilateral	44	5.35 ± 2.55	6.66 ± 3.23	< 0.001
CT only group^b				
Total	92	5.10 ± 1.50	6.19 ± 2.43	< 0.001
Unilateral right	12	6.04 ± 2.41	5.05 ± 2.78	0.27
Unilateral left	35	4.70 ± 1.05	6.98 ± 2.60	< 0.001
Bilateral	48	5.15 ± 1.41	5.91 ± 2.08	0.004

Volumes (ml) are mean ± SD of adrenal glands on CT-scan as measured by volumetry. Unilateral and bilateral means unilateral and bilateral adrenal disease

AVS adrenal vein sampling

^aSubtyping based on AVS results

^bSubtyping based on CT results

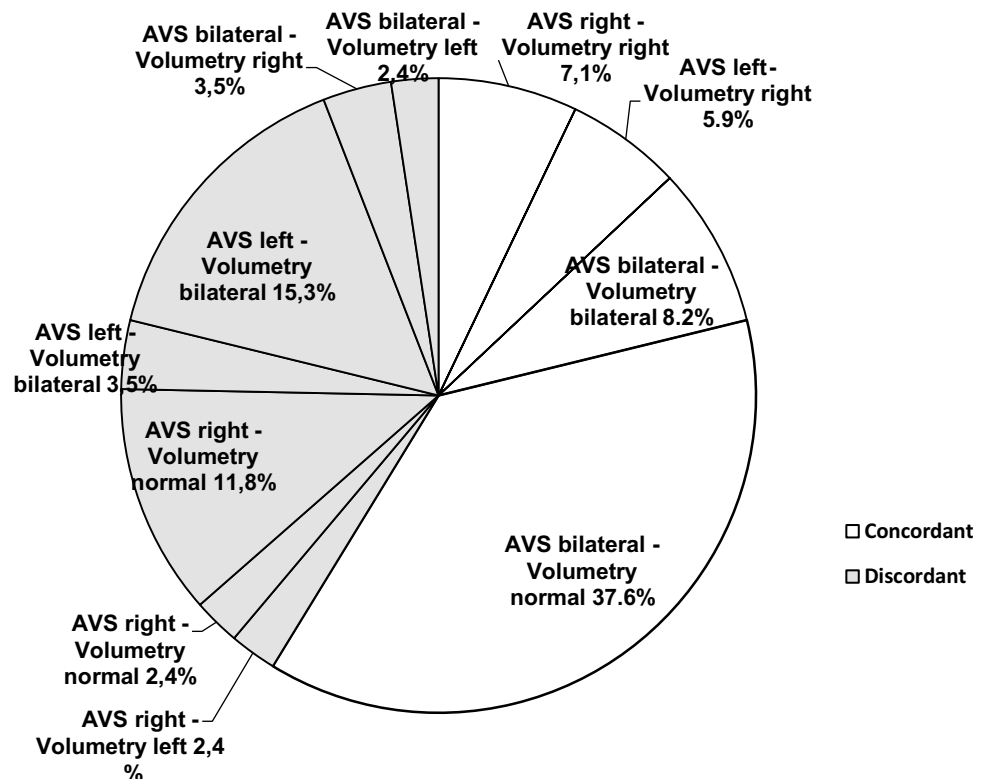
of the contralateral adrenals were higher than the published reference volumes of adrenal glands in healthy subjects [5] (mean difference right 1.16 ml, 95% CI 0.17–2.17; left 1.16 ml, 0.79–1.52).

In subgroup analysis for gender the volumes of the contralateral adrenal in patients with unilateral disease remained higher than the published reference volumes of both left and right adrenal glands in healthy men. This was also the case in women regarding the right contralateral gland but not for the left contralateral gland (Table S3).

Concordance of subtyping based on volumetry with AVS results

We reached the best concordance with AVS results for subtyping PA at a cut-off level for enlargement of the adrenal gland at an expected volume + 2.125 SD (based on published reference values, see Statistics) [5]. With this cut-off value the concordance was 58.8% (50/85, 95% CI 47.6–69.4) for the classification of unilateral right, unilateral left or bilateral disease (Fig. 2). For the subgroup with a CT slice thickness of ≤ 1 mm the concordance was 57.8% and for the subgroup with a CT slice thickness of > 1 mm the concordance was 60.7%. For the conventional CT results this concordance with AVS was 51.8% (44/85, 95% CI 40.7–62.7) and not significantly different from the concordance of volumetry

Fig. 2 Concordance of adrenal vein sampling and volumetry results regarding subtype classification (*n* = 85)



with AVS ($p=0.43$), also not in the subgroup analysis for CT slice thickness.

The overlap of the adrenal volumes of both sides was substantial between right and left unilateral disease and bilateral disease (Fig. 3).

Volume of contralateral adrenal and outcome after ADX

The volume of the contralateral adrenal gland was not significantly associated with complete biochemical or clinical success, nor with DDD (data not shown). We found also no association for weight, CT slice thickness and laterality. Gender was a significant predictor for complete clinical success with an odds ratio of 9.0 (95% CI 2.44–33.24). Female had a lower DDD than male (0.84; 95% CI 0.12–1.56 versus 2.13; 95% CI 1.69–2.57). Gender was not associated with biochemical success.

Discussion

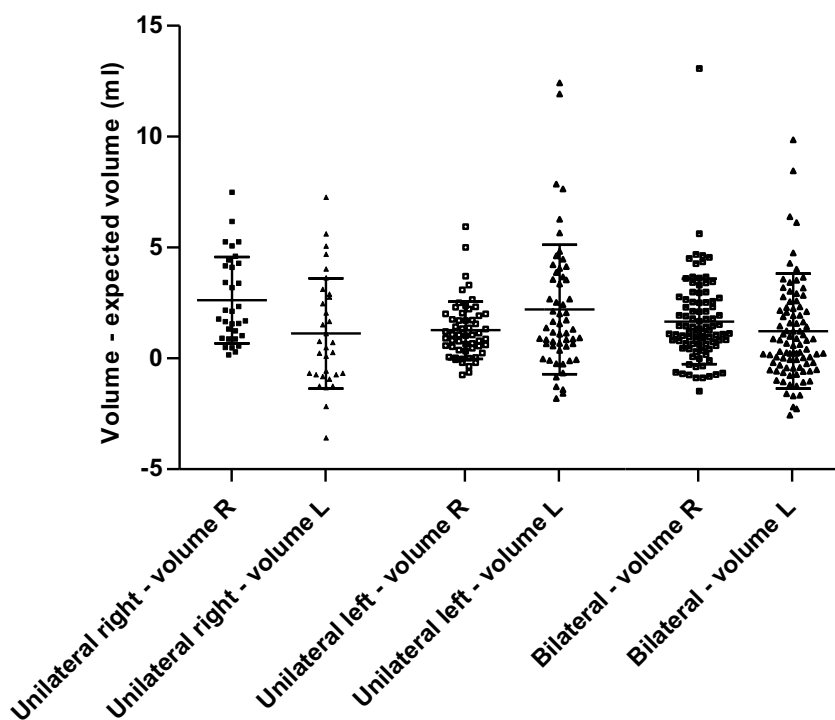
The two main findings of our study are that volumetry of adrenals on CT-scan for subtyping of PA seems to be no improvement compared to conventional CT measurements and that the size of the contralateral adrenal is not associated with outcome after ADX. In addition, we confirm the findings of Degenhart et al. [6], that the contralateral adrenal

gland is enlarged in unilateral disease and that on average, like in healthy subjects [4], the left adrenal gland is larger than the right one. To our knowledge, this is the first study in which results of volumetry of adrenals in PA are related to clinical parameters and outcome after ADX and in which the concordance of volumetry as a subtyping modality with AVS is explored.

In the SPARTACUS trial it was remarkable that, although the distribution of right and left unilateral disease was fairly equal for the AVS results (respectively, $n=20$ and $n=21$), it was not for the CT in the same group (respectively, $n=6$ and $n=39$) [2], regarding the patients included in this study ($n=85$). We speculated that the discordance between both conventional subtype modalities might be the result of underdetection of an enlarged right adrenal or over-detection of an enlarged left adrenal based on conventional CT measurements, given the higher volume of the left adrenal in healthy subjects [6] as well as in patients with PA. However, this hypothesis is not supported by our results. In our study, for example, in patients with bilateral disease according to AVS, the volume of the left adrenal was 1.31 ml higher on average than the right one, suggesting that the criteria for adrenal enlargement should be side- (and perhaps gender-) specific. However, the concordance between AVS and CT does not substantially improve when applying age- and gender adjusted volume CT-based measurement.

Degenhart et al. already suggested that volumetry is not very promising for subtyping PA [6]. The concordance of

Fig. 3 Vertical scatter plot of the measured adrenal volumes on CT of both sides according to subtype minus the expected value based on healthy subjects. Subtype was based on AVS ($n=85$) or conventional CT results. Mean and SD are presented. *R* right, *L* left



Subtype according to AVS or conventional CT result and sides of adrenal gland

volumetry with AVS results was indeed not superior to the concordance between conventional CT measurements and AVS. The disappointing concordance between volumetry and AVS can be explained by the limitations of CT scan for the adequate detection of adrenal adenomas or hyperplasia in PA, which also apply in case of volumetry: first of all the detection of non-functional adenomas, which are indistinguishable from an APA. Adrenal incidentalomas are present in 2.5 to 10% of the abdominal CT-scans in patients without (the suspicion of) adrenal disease, increasing with age [1, 9–11]. Secondly, APAs or hyperplasia may also be too small to be detected. For this reason the Endocrine Society guideline recommends AVS for subtyping PA in most cases [1]. Obviously, also limitations of AVS affect this concordance negatively.

It is known that, although biochemical remission will be achieved in most cases, a majority of patients (63%) after ADX still needs antihypertensive medication [7]. Female patients need less medication and more of them have complete clinical cure. This is in line with earlier findings [12–15]. So, female gender could be an incentive to proceed to surgery.

The enlarged contralateral adrenal, the opposite of what is seen in cortisol-producing adenomas, where the contralateral gland is atrophic, is in line with histopathological findings of hyperplasia and nodularity of the zona glomerulosa in some patients with an APA in the adjacent cortex [16], suggesting the presence of an unknown trigger of cell proliferation [6]. Although most patients are cured after ADX, in some patients the enlarged contralateral adrenal might also be the result of inadequate subtyping. An enlarged contralateral gland is also in line with APA and BAH being two ends of a spectrum [17]. Considering these two possible explanations for an enlarged contralateral adrenal it could be hypothesized that patients with an enlarged contralateral adrenal have worse outcome after ADX. However, we could not conform this hypothesis with our results. The adrenal volumes of our PA patients were slightly lower than published by Degenhart et al. [6]. It might be that the volume is higher in this previous study, because these patients had been suffering from PA for a longer time. Regarding the similarity of the volumes in healthy subjects measured in Germany and in our center, it is unlikely that the differences in software and interobserver variability have had a substantial impact on the volumes.

The strengths of this study are the excellent agreement between observers, the low intraobserver variability and the high number of patients. Also, the prospective design of the original SPARTACUS trial provided a complete set of data and the observers were blinded for these data. A limitation of our study is the use of different CT-scans and CT protocols, as a result of the multicenter character of the original study. However, this reflects clinical practice and it is unlikely that this had a substantial impact on our results,

because we used similar software for volumetry. A higher slice thickness will result in a slightly less precise estimate, but seems not to affect our results as supported by our subgroup analyses for CT slice thickness. Secondly, we used normative data from healthy subjects from a German study that used different software. A different population might affect the measured volume. We overcame this by comparing the adrenal volumes of the healthy subjects without adrenal disease with these published normal values, showing similar results.

Furthermore, although we could determine concordance with AVS results, it was impossible to draw a firm conclusion regarding diagnostic accuracy in subtyping of PA, due to the lack of a gold standard [2]. The last limitation is that there is no validated cut-off value for an enlarged adrenal. We overcame this by calculating the cut-off value corresponding with the best concordance with AVS results [4].

In conclusion, volumetry of the adrenal glands provides no additional value to current assessment of adrenal size for subtyping patients with PA, nor in predicting outcome after ADX.

Supplementary Information The online version contains supplementary material available at <https://doi.org/10.1007/s40618-021-01540-5>.

Acknowledgements We thank Liën Coolen for her contribution to this study and Jacques Lenders for his comments on the manuscript. The members of for the SPARTACUS Investigators: T. Dekkers, A. Prejbisz, L. J. S. Kool, H. J. M. M. Groenewoud, M. Velema, W. Spiering, S. Kołodziejczyk-Kruk, M. Arntz, J. Kądziela, J. F. Langenhuijsen, M. N. Kerstens, A. H. van den Meiracker, B. J. van den Born, F. C. G. J. Sweep, A. R. M. M. Hermus, A. Januszewicz, A. F. Ligthart-Naber, P. Makai, G. J. van der Wilt, J. W. M. Lenders, J. Deinum.

Funding The authors state that this work has not received any funding.

Declarations

Conflict of interest On behalf of all authors, the corresponding author states that there is no conflict of interest. Data reported in this paper is available upon request from JD. JD's department is partner of the H2020 project ENS@T-HT (Grant 633983).

Guarantor The scientific guarantor of this publication is Jaap Deinum.

Statistics and biometry Hans Groenewoud kindly provided statistical advice for this manuscript. One of the authors has significant statistical expertise. No complex statistical methods were necessary for this paper.

Informed consent Only if the study is on human subjects: written informed consent was obtained within the Spartacus trial from subjects (patients) in this study. For the control cohort of CT-scans of 20 kidney donation participants our Ethics Committee judged that no detailed review was warranted given the non-intrusive and non-experimental character of the study.

Ethical approval Institutional Review Board approval was obtained for the original Spartacus study. For the control cohort of CT-scans

of 20 kidney donation participants our Ethics Committee judged that no detailed review was warranted given the non-intrusive and non-experimental character of the study.

Study subjects or cohorts overlap Some study subjects or cohorts have been previously reported in the Spartacus trial: Dekkers et al. [2].

Methodology The original study was prospective. This was a post-hoc analysis. The original study was a randomised controlled trial. This was a post-hoc analysis was a diagnostic study. Multicenter study.

References

- Funder JW, Carey RM, Mantero F, Murad MH, Reincke M, Shibata H, Stowasser M, Young WF Jr (2016) The management of primary aldosteronism: case detection, diagnosis, and treatment: an endocrine society clinical practice guideline. *J Clin Endocrinol Metab* 101:1889–1916
- Dekkers T, Prejbisz A, Kool LJS, Groenewoud H, Velema M, Spiering W, Kolodziejczyk-Kruk S, Arntz M, Kadziela J, Langenhuijsen JF, Kerstens MN, Van Den Meiracker AH, Van Den Born BJ, Sweep F, Hermus A, Januszewicz A, Ligthart-Naber AF, Makai P, Van Der Wilt GJ, Lenders JWM, Deinum J (2016) Adrenal vein sampling versus CT scan to determine treatment in primary aldosteronism: an outcome-based randomised diagnostic trial. *Lancet Diabetes Endocrinol* 4:739–746
- Kempers MJ, Lenders JW, Van Oudeheusden L, Van Der Wilt GJ, Schultze Kool LJ, Hermus AR, Deinum J (2009) Systematic review: diagnostic procedures to differentiate unilateral from bilateral adrenal abnormality in primary aldosteronism. *Ann Intern Med* 151:329–337
- Schneller J, Reiser M, Beuschlein F, Osswald A, Pallauf A, Riester A, Tietze JK, Reincke M, Degenhart C (2014) Linear and volumetric evaluation of the adrenal gland—MDCT-based measurements of the adrenals. *Acad Radiol* 21:1465–1474
- Vincent JM, Morrison ID, Armstrong P, Reznick RH (1994) The size of normal adrenal glands on computed tomography. *Clin Radiol* 49:453–455
- Degenhart C, Schneller J, Osswald A, Pallauf A, Riester A, Reiser MF, Reincke M, Beuschlein F (2017) Volumetric and densitometric evaluation of the adrenal glands in patients with primary aldosteronism. *Clin Endocrinol (Oxf)* 86:325–331
- Williams TA, Lenders JWM, Mulatero P, Burrello J, Rottenkolber M, Adolf C, Satoh F, Amar L, Quinkler M, Deinum J, Beuschlein F, Kitamoto KK, Pham U, Morimoto R, Umakoshi H, Prejbisz A, Kocjan T, Naruse M, Stowasser M, Nishikawa T, Young WF Jr, Gomez-Sanchez CE, Funder JW, Reincke M (2017) Outcomes after adrenalectomy for unilateral primary aldosteronism: an international consensus on outcome measures and analysis of remission rates in an international cohort. *Lancet Diabetes Endocrinol* 5:689–699
- Fleiss J (1986) *The design and analysis of clinical experiments*. Wiley, New York
- Comlekci A, Yener S, Ertilav S, Secil M, Akinci B, Demir T, Kebapcilar L, Bayraktar F, Yesil S, Eraslan S (2010) Adrenal incidentaloma, clinical, metabolic, follow-up aspects: single centre experience. *Endocrine* 37:40–46
- Ferreira EV, Czepielewski MA, Faccin CS, Accordi MC, Furtado AP (2005) Prevalence of adrenal incidentaloma at computed tomography (chest and abdominal) in a general hospital in Brazil. *Arq Bras Endocrinol Metabol* 49:769–775
- Bovio S, Cataldi A, Reimondo G, Sperone P, Novello S, Berruti A, Borasio P, Fava C, Dogliotti L, Scagliotti GV, Angeli A, Terzolo M (2006) Prevalence of adrenal incidentaloma in a contemporary computerized tomography series. *J Endocrinol Invest* 29:298–302
- Pang TC, Bambach C, Monaghan JC, Sidhu SB, Bune A, Delbridge LW, Sywak MS (2007) Outcomes of laparoscopic adrenalectomy for hyperaldosteronism. *ANZ J Surg* 77:768–773
- Tresallet C, Salepcioglu H, Godiris-Petit G, Hoang C, Girerd X, Menegaux F (2010) Clinical outcome after laparoscopic adrenalectomy for primary hyperaldosteronism: the role of pathology. *Surgery* 148:129–134
- Walz MK, Gwosdz R, Levin SL, Alesina PF, Suttrop AC, Metz KA, Wenger FA, Petersenn S, Mann K, Schmid KW (2008) Retroperitoneoscopic adrenalectomy in Conn's syndrome caused by adrenal adenomas or nodular hyperplasia. *World J Surg* 32:847–853
- Zarnegar R, Young WF Jr, Lee J, Sweet MP, Kebebew E, Farley DR, Thompson GB, Grant CS, Clark OH, Duh QY (2008) The aldosteronoma resolution score: predicting complete resolution of hypertension after adrenalectomy for aldosteronoma. *Ann Surg* 247:511–518
- Boulkroun S, Samson-Couterie B, Dzib JF, Lefebvre H, Louiset E, Amar L, Plouin PF, Lalli E, Jeunemaitre X, Benecke A, Meatchi T, Zennaro MC (2010) Adrenal cortex remodeling and functional zona glomerulosa hyperplasia in primary aldosteronism. *Hypertension* 56:885–892
- Nanba AT, Nanba K, Byrd JB, Shields JJ, Giordano TJ, Miller BS, Rainey WE, Auchus RJ, Turcu AF (2017) Discordance between imaging and immunohistochemistry in unilateral primary aldosteronism. *Clin Endocrinol (Oxf)* 87:665–672

Publisher's Note Springer Nature remains neutral with regard to jurisdictional claims in published maps and institutional affiliations.