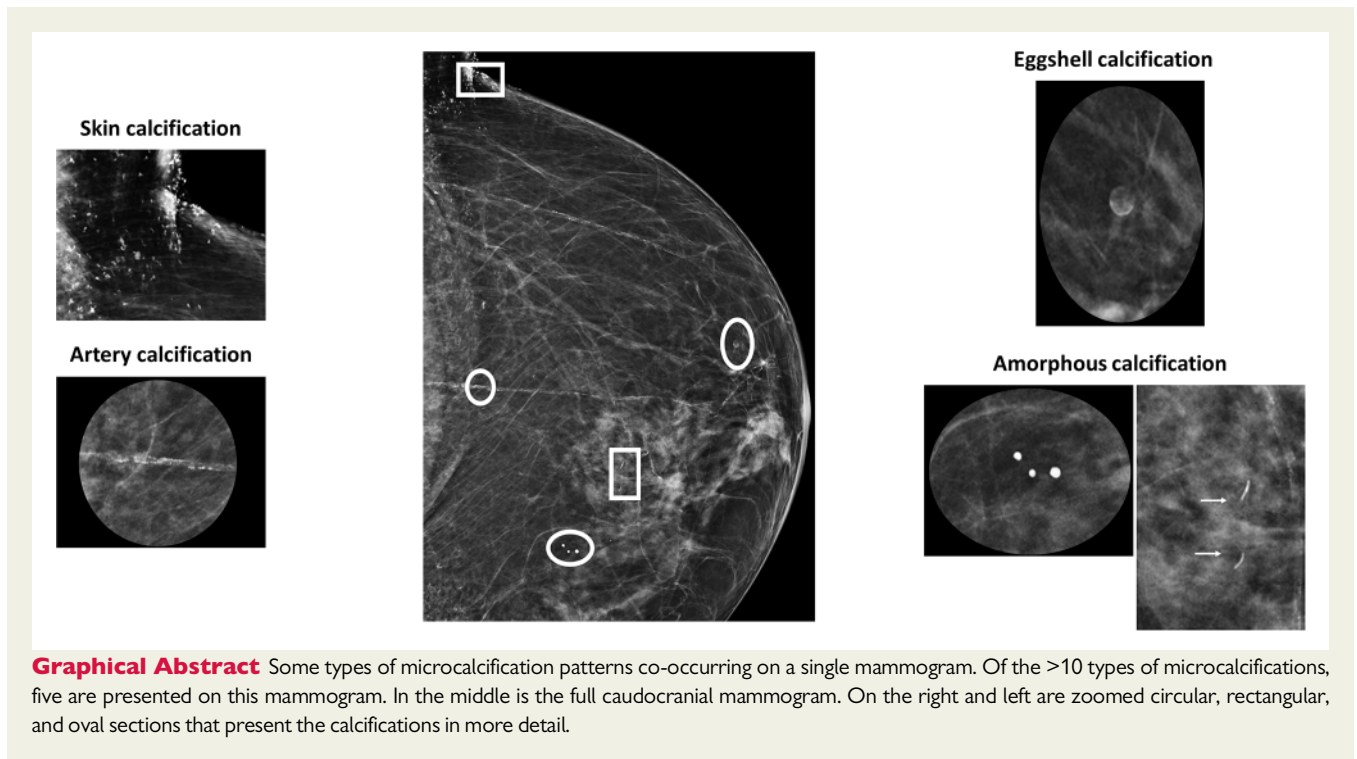


# Mammograms to catch many birds with one stone

Angela H.E.M. Maas <sup>1,\*</sup> and Pim A. de Jong<sup>2</sup>

<sup>1</sup>Department of Cardiology, Radboud University Medical Center, Nijmegen, The Netherlands; and <sup>2</sup>Department of Radiology, University Medical Center Utrecht and Utrecht University, The Netherlands

This editorial refers to ‘Mammographic features are associated with cardiometabolic disease risk and mortality’, by F. Grassmann et al., doi:10.1093/eurheartj/ehab502.



Timely prevention of diseases is high on the list of priorities in health-care. Computed tomography (CT) imaging of vascular calcification as a sign of subclinical atherosclerosis by measuring the coronary artery calcium (CAC) score has become a major step forward in early preventive strategies in patients at elevated/intermediate cardiovascular

risk.<sup>1,2</sup> The use of breast arterial calcifications (BACs) on mammograms as a screening tool for cardiovascular disease has been subject to debate for many years as this could be very efficient and cost effective.<sup>3–5</sup> In this issue of the *European Heart Journal*, Grassmann et al. investigated whether the presence of microcalcifications on

The opinions expressed in this article are not necessarily those of the Editors of the *European Heart Journal* or of the European Society of Cardiology.

\*Corresponding author. Radboud University Medical Center, Geert Grooteplein-Zuid 10, Route 616, 6525GA Nijmegen, The Netherlands. Tel: +31 24 3614533, Email: [angela.maas@radboudumc.nl](mailto:angela.maas@radboudumc.nl)

© The Author(s) 2021. Published by Oxford University Press on behalf of the European Society of Cardiology.

This is an Open Access article distributed under the terms of the Creative Commons Attribution-NonCommercial License (<http://creativecommons.org/licenses/by-nc/4.0/>), which permits non-commercial re-use, distribution, and reproduction in any medium, provided the original work is properly cited. For commercial re-use, please contact [journals.permissions@oup.com](mailto:journals.permissions@oup.com)

mammograms is associated with cardiometabolic risk in a large prospective mammographic screening cohort of 57 867 women (KARMA) and 49 583 of their sisters in Sweden.<sup>6</sup> They found that the number of microcalcifications as assessed by an automated algorithm was positively associated with an elevated cardiovascular risk and mortality by using ICD (International Classification of Disease) codes. This was not found however in women who were not known to have cardiometabolic diseases. This association was not observed for breast density, which was inversely associated with cardiometabolic risk. The latter is not surprising as breast density decreases after the menopause, when cardiovascular risk gradually increases in women. The authors state that assessment of microcalcifications may be a helpful and novel technique to assess cardiometabolic risk. The investigators are to be praised for this effort in a large dataset of patients. However, there are many limitations to mention that urge us to mitigate this enthusiasm.

## The mystery of breast calcifications

Formation of tiny calcifications in the breast is highly prevalent, heterogeneous in origin, and about a dozen types of patterns have been described. The large majority of these calcifications are not associated with breast cancer, except for the most worrisome ductal calcifications that are associated with ductal carcinoma *in situ* and breast cancer. Outside the ducts, breast calcifications can develop in the lobules, in the tunica media of small arteries (BACs), in the skin, and basically anywhere in the fat and glandular tissue. These different small calcifications are common and often co-occur in a single breast (*Graphical Abstract*).<sup>7</sup> The authors used a commercial algorithm in which they are scientifically and financially involved, but from the paper and the references it remains unclear what they measured. Although calcification processes share common mechanisms, their clinical significance in various vascular and non-vascular beds is very different.

## The 'bone former' and cardiovascular disease

What if the algorithm measured all type of breast calcifications simultaneously? It is evident that the ability to form bone and calcifications is diverse in the population, with 'bone formers' and 'bone losers' at opposite ends of the spectrum. Ectopic calcifications are highly prevalent and also well known outside the breast in our vascular system. It has been hypothesized that strong bone formation and ectopic mineralization was once beneficial, but became detrimental in an ageing population.<sup>8</sup> It has indeed been shown that the ability to form excessive bone outside the skeleton in common disorders such as osteoarthritis and diffuse idiopathic skeletal hyperostosis is associated with vascular calcifications and cardiovascular events.<sup>9</sup> Currently, it is speculative whether the ability to form bone needs to be inhibited in 'bone formers' to prevent cardiovascular disease and organ failure.

## Ductal microcalcifications and cardiovascular disease

What if the algorithm measured only clusters of dangerous ductal microcalcifications? That would suggest that there is an intrinsic link between ductal breast carcinoma and cardiovascular disease. Given the important roles of metabolism and our immune system for health and disease, it could well be that breast tissue ductal calcifications and vascular disease share some common pathways. Whether this would explain the strength of the observed associations is uncertain. The authors found that breast calcifications, cardiometabolic risk, and breast cancer in KARMA women showed similarities to their sisters. Although cardiovascular risk as well as breast cancer have genetic traits, common pathways are as yet unclear. Women with BRCA1/2 mutations may be at increased risk for cardiovascular disease as a result of an abnormal ability to repair DNA, but it is unclear what specific genetics were tested in the current study.<sup>10</sup>

## Medial arterial calcification and cardiovascular disease

What if the algorithm is confounded by BACs? It is well known that BACs are associated with age, and cardiometabolic, hormonal, and reproductive factors.<sup>3,4,11</sup> We previously showed that age, diabetes and parity are the strongest predictors of BAC and that the aetiology of BACs and coronary artery calcifications is importantly different.<sup>3,12</sup> It seems likely that the algorithm used in the present study was disturbed by the presence of BACs, as is also seen in the figures. These calcifications can be tiny or large, and they can also evolve into regression patterns with many small clusters.<sup>13</sup> It is likely that the associations are diluted and that clinically more useful predictive value is contained in the mammograms.

BACs are a specific form of arterial calcification located in the media of the vessel wall. It is crucial to understand that these calcifications are not atherosclerotic, but thin circular calcifications of the internal elastic lamina and tunica media. These calcifications are also common in the carotid siphon and at this location they are the strongest predictor of stroke.<sup>14</sup> They are also common in the leg arteries in patients with genetic syndromes, renal dysfunction, diabetes, and ageing.<sup>15</sup> Here they predict amputations. A plausible mechanism is that the 'Windkessel function' of our arterial system is disturbed by these calcifications and that the high pulse pressure leads to organ failure. This is possibly supported by the association with heart failure as observed by Grassmann *et al.* Although much uncertainty exists as to whether these calcifications need to be removed from our blood vessels, some drugs have been able to modify the process and can be used to test the hypothesis.<sup>16,17</sup>

## The way forward

We need to better understand what we measure on a mammogram. This means a movement from the number of clusters of unknown microcalcifications towards an automated dedicated measurement of ductal microcalcification and BAC. Such an 'Agatston score for mammography' could turn the promising but weak signals into more

powerful absolute risk predictors and identify women at risk to prevent adverse cardiovascular outcomes.

**Conflict of interest:** A.H.E.M.M. has no conflicts to declare. The Department of Radiology of the UMC Utrecht receives research support from Philips Healthcare. P.A.d.J. is a consultant to InoZyme and Sanifit.

## References

- Qazi AH, Zallaghi F, Torres-Acosta N, Thompson RC, O'Keefe JH. Computed tomography for coronary artery calcification scoring: mammogram for the heart. *Prog Cardiovasc Dis* 2016;**58**:529–536.
- Shaw LJ, Min JK, Nasir K, Xie JX, Berman DS, Miedema MD, Whelton SP, Dardari ZA, Rozanski A, Rumberger J, Bairey Merz CN, Al-Mallah MH, Budoff MJ, Blaha MJ. Sex differences in calcified plaque and long-term cardiovascular mortality: observations from the CAC Consortium. *Eur Heart J* 2018;**39**:3727–3735.
- Maas AHM, van der Schouw YT, Beijerinck D, Deurenberg JJM, Mali WPTHM, van der Graaf Y. Arterial calcifications seen on mammograms: cardiovascular risk factors, pregnancy and lactation. *Radiology* 2006;**240**: 33–38.
- Hendriks EJE, Beulens JWJ, Mali WPTHM, Beijerinck D, van der Graaf Y, de Jong PA, van der Schouw YT. Breast arterial calcifications and their association with incident cardiovascular disease and diabetes: the Prospect-EPIC cohort. *J Am Coll Cardiol* 2015;**65**:859–860.
- Bui QM, Daniels LB. A review of the role of breast arterial calcification for cardiovascular risk stratification in women. *Circulation* 2019;**139**:1094–1101.
- Grassmann F, Yang H, Eriksson M, Azam S, Hall P, Czene K. Mammographic features are associated with cardiometabolic disease risk and mortality. *Eur Heart J* 2021;**42**:3361–3370.
- Smithuis R, Pijnappel R. Differential of Breast Calcifications. <https://radiologyassist.ant.nl/breast/calcifications/differential-of-breast-calcifications> (26 June 2021).
- Bartstra JW, Mali WVP, Spiering W, de Jong PA. Abdominal aortic calcification: from ancient friend to modern foe. *Eur J Prev Cardiol* 2020;doi: 10.1177/2047487320919895.
- Oudkerk SF, Mohamed Hoessein FAA, Mali WPTHM, Öner FC, Verlaan JJ, de Jong PA, Kinney GL, Hokanson J, Lynch D, Silverman EK, Budoff MJ, Regan EA. Subjects with diffuse idiopathic skeletal hyperostosis have an increased burden of coronary artery disease: an evaluation in the COPDGene cohort. *Atherosclerosis* 2019;**287**:24–29.
- Arts-de Jong M, Maas AH, Massuger LF, Hoogerbrugge N, de Hullu JA. BRCA1/2 mutation carriers are potentially at higher cardiovascular risk. *Crit Rev Oncol Hematol* 2014;**91**:159–171.
- Hendriks EJ, de Jong PA, van der Graaf Y, Mali WP, van der Schouw YT, Beulens JW. Breast arterial calcifications: a systematic review and meta-analysis of their determinants and their association with cardiovascular events. *Atherosclerosis* 2015;**239**:11–20.
- Maas AH, van der Schouw YT, Atsma F, Beijerinck D, Deurenberg JJM, Mali WP, van der Graaf Y. Breast arterial calcifications are correlated with coronary artery calcifications, but their aetiology is predominantly different. *Eur J Radiol* 2007;**63**: 396–400.
- Hendriks EJ, de Jong PA, Beulens JW, Mali WP, van der Schouw YT, Beijerinck D. Medial arterial calcification: active reversible disease in human breast arteries. *JACC Cardiovasc Imaging* 2015;**8**:984–985.
- Vos A, Van Hecke W, Spliet WG, Goldschmeding R, Isgum I, Kockelkoren R, Bleys RL, Mali WP, de Jong PA, Vink A. Predominance of nonatherosclerotic internal elastic lamina calcification in the intracranial internal carotid artery. *Stroke* 2016;**47**:221–223.
- Losurdo F, Ferraresi R, Ucci A, Zanetti A, Clerici G, Zambon A. Association of infrapopliteal medial arterial calcification with lower-limb amputations in high-risk patients: a systematic review and meta-analysis. *Vasc Med* 2021;**26**:164–173.
- Kranenburg G, de Jong PA, Bartstra JW, Lagerweij SJ, Lam MG, Ossewaarde-van Norel J, Risseeuw S, van Leeuwen R, Imhof SM, Verhaar HJ, de Vries JJ, Slart RHJA, Luurtsema G, den Harder AM, Visseren FLJ, Mali WP, Spiering W. Etidronate for prevention of ectopic mineralization in patients with pseudoxanthoma elasticum. *J Am Coll Cardiol* 2018;**71**:1117–1126.
- Raggi P, Bellasi A, Bushinsky D, Bover J, Rodriguez M, Ketteler M, Sinha S, Salcedo C, Gillotti K, Padgett C, Garg R, Gold A, Perelló J, Chertow GM. Slowing progression of cardiovascular calcification with SNF472 in patients on hemodialysis: results of a randomized phase 2b study. *Circulation* 2020;**141**: 728–739.