

# Supraperiosteal Flap Technique Versus Mucoperiosteal Flap Technique in Cleft Palate Surgery

THOMAS S. LEENSTRA, D.D.S.,  
GEN-IKU KOHAMA, D.D.S., PH.D.,  
ANNE M. KUIJPERS-JAGTMAN, D.D.S., PH.D.,  
HANS PETER M. FREIHOFFER, M.D., D.D.S., PH.D.

Recent animal experiments have shown that palatal repair without denudation of bone leads to a superior dento-alveolar development. The aim of this clinical study was to evaluate the peri- and postoperative course and the dento-alveolar development of the deciduous dentition in Japanese ULCP, and CP patients up to 5 years after two different types of palatal repair. One of the methods, the Kohama (1991) supraperiosteal flap technique, is performed without denudation of the bony palate, while the other, the Wardill (1937) push-back technique, results in areas of denuded bone. It was concluded that the supraperiosteal technique can be performed successfully in approximately the same amount of time as the push-back technique. Re-epithelialization of the wound areas after supraperiosteal repair takes about 1 week, which is one third of the time associated with healing after the push-back technique. Arch depth of the deciduous dentition after the supraperiosteal technique is superior compared to the push-back technique. The question of whether or not the supraperiosteal technique produces more favorable dento-alveolar development than the mucoperiosteal technique in the permanent dentition in humans has to be elucidated in future research.

KEY WORDS: *cleft palate, humans, surgery, wound healing*

Forty years ago, Graber (1954) reported detrimental effects of cleft palate repair on facial growth in humans. Today, surgery is considered one of the major factors causing disturbances in facial growth in cleft palate patients (Ross, 1987a, b; Ross and Johnston, 1972). Soft-tissue management is thought to be particularly responsible for affecting maxillary growth. The quantity and distribution of scar tissue after healing of the soft tissues seems to be the principal factor responsible for growth inhibition (Ross, 1987b).

Animal experiments have been carried out to elucidate the effect of surgery on maxillary growth. Bardach et al. (1988), Bardach and Kelly (1988), and Bardach (1990) concluded from a series of studies in rabbits and Beagle dogs that lip closure produces increased lip pressure that could be an important factor in craniofacial growth aberration. Herfert (1954, 1956, 1958) concluded from a split-mouth study on five Beagle dogs that the raising of palatal mucoperiosteum and the

presence of denuded palatal bone after palatoplasty resulted in maxillary growth impairment. In a series of studies following Herfert's design, Kremenak et al. (1967, 1970) and Kremenak (1984) found that unilateral excision of a strip of mucoperiosteum adjacent to the posterior deciduous teeth resulted in maxillary growth inhibition.

In the studies of Wijdeveld et al. (1989, 1991), palatal surgery as described by von Langenbeck was simulated in Beagle dogs of different ages in a nonbony cleft model, resulting in a narrowing of the dental arch, which became apparent only after shedding of the teeth. Histologic evaluation showed that the composition of the scar tissue in the experimental groups remained different from the normal mucoperiosteum, irrespective of the age at which surgery was performed. The scar tissue covering the lateral wound areas adjacent to the posterior teeth lacked large blood vessels and elastic fibers, and showed a mainly transverse orientation of collagenous fibers. Scar tissue was also attached to the underlying bone by Sharpey's fibers. Furthermore, it was noticed that the mucoperiosteum was continuous with the periodontal ligament. These factors might result in a medially directed tensile force on the teeth in operated dogs. These authors suggested that prevention of scar-tissue attachment to the underlying bone might lead to more favorable dento-alveolar development.

Leenstra et al. (1995a) were able to prevent scar-tissue attachment to underlying bone by modifying the technique of palatal repair. In Beagle dogs, closure of a mucoperiosteal palatal cleft was performed using a modified partially split-flap technique, in which denudation of palatal bone was

---

Dr. Leenstra is affiliated with the Department of Orthodontics, University of Nijmegen, The Netherlands. Dr. Kohama is Professor and Head of the Department of Oral and Maxillo-Facial Surgery, Sapporo Medical University, Japan. Dr. Kuijpers-Jagtman is Professor and Head of the Department of Orthodontics, and Director of the Cleft Palate Center, University Hospital Nijmegen, The Netherlands. Dr. Freihofer is Professor and Head of the Department of Oral and Maxillo-Facial Surgery, University of Nijmegen, The Netherlands.

Submitted January 1996; Accepted June 1996.

Reprint requests: Dr. A.M. Kuijpers-Jagtman, University of Nijmegen, Department of Orthodontics, P.O. Box 9101, 6500 HB Nijmegen, The Netherlands.

avoided. The latter technique is a combination of a mucosal-palatal-flap technique used by Perko (1974, 1979) and the von Langenbeck technique. In a follow-up study on growing Beagle dogs, Leenstra et al. (1995b) found normal dento-alveolar development in a group operated on using this modified partially split-flap technique.

The histologic tissue features found by Wijdeveld et al. (1991) after a von Langenbeck procedure and by Leenstra et al. (1995a) after closure without denudation of bone were supported by an earlier histologic study by Densho (1982), who created five different types of palatal wounds in rats. He reported scar-tissue attachment after healing of wounds in which mucoperiosteum was removed, and consequently palatal bone was exposed. Fourteen days after surgery, the borderline between bone and mucoperiosteum of wounds, in which only the upper layer of the mucoperiosteum was removed, was comparable to the control side.

It has been suggested that palatal surgery without denudation of bone has a positive effect on dento-alveolar development in primates (Perko, 1974) and in humans (Perko, 1979). Therefore, the aim of this study was to evaluate the perioperative and postoperative course and the dento-alveolar development of the deciduous dentition in Japanese ULCP and CP patients up to 5 years after two different types of palatal closure: the suprapariosteal flap technique described by Kohama (1991) without denudation of bone, or the push-back technique described by Wardill (1937) resulting in denuded bone.

## METHOD

The study evaluated 138 patients born between 1974 and 1990 with a complete unilateral cleft lip and palate (UCLP,  $n = 65$ ), and those with a cleft palate only (CP,  $n = 73$ ). The patients were treated at the Department of Oral and Maxillo-Facial Surgery, Sapporo Medical University, Sapporo, Japan. The UCLP group did not receive preoperative orthopedic treatment before lip closure. Lip closure, using the Tennison-Randall technique (Randall, 1959) for complete cleft lips, or the Millard procedure (Millard, 1976) for complete and incomplete cleft lips, was performed at a mean age of 3 months. The palate was closed in one stage in both groups. In the UCLP group, 35 patients (25 ♂; 10 ♀) were treated using a suprapariosteal technique (SP), and 30 patients (18 ♂; 12 ♀) using a mucoperiosteal technique (MP). In the CP group, 33 patients (13 ♂; 20 ♀) were treated using the SP technique and 40 patients (17 ♂; 23 ♀) using the MP technique. In all groups, palatal repair was performed at the mean age of 17 months. Dento-alveolar development was evaluated annually using dental casts until 5 years after surgery. At least three dental casts were available for each patient.

## Surgical Procedures

### *Suprapariosteal Technique Described by Kohama*

After standard preparation of cleft palate patients for surgery, the oral cavity is disinfected with Isogine® (Meiji Seika

Kaisha, Japan). Thereafter, 2 to 4 mL Xylocaine® (lidocaine hydrochloride 0.4 mg/mL + adrenaline 0.0125 mg/mL; Astra, Japan) is injected suprapariosteally into the palatal mucoperiosteum. Incisions are made bilaterally for suprapariosteal preparation of the palatal flaps starting at the alveolar process distal to the deciduous first molar, proceeding anteriorly along the highest lateral part of the palatal vault, extending to the mesial side of the deciduous canine (Fig. 1). In UCLP patients, the incisions follow the dental arch to the cleft. The incision of the larger segment is located distally to the incisive foramen to avoid damage of the incisive papilla. In CP patients, straight incisions from the mesial side of the deciduous canine to the most anterior point of the cleft are performed. The incisions described above are performed with a #11 blade, which is held almost parallel to the palatal bone. The angle of the blade to the palatal bone (i.e., 0 degrees or more), controls the area of the mucoperiosteum that will be split. Ideally, the split area has to be at least the width of the cleft, but the maximum width is determined by the location of the greater palatine neurovascular bundle. If the split area is judged to be sufficient, incisions reaching the bone laterally to the bundle are carried out. Then incisions are made on the medial edges of the cleft of the hard palate to separate the nasal from the oral mucosa. The medial edge of the soft palate and the remaining hard palate is freshened by removing a very thin strip of mucosa. Vertical incisions to the bone are made distal to the primary first molars, curving outwards or laterally posterior to the maxillary tuberosity and extended to the pharynx in the buccal mucosa. Then the combined mucoperiosteal and suprapariosteal flap is created by elevation of the remaining mucoperiosteum, containing the neurovascular bundle, from the bone. Infracturing of the pterygoid hamulus, mobilization and suturing of the nasal mucosa, reconstruction of the levator veli palatini muscles, and suturing of the oral flaps are performed by following standard procedures. After posterior movement, the oral flap is sutured to the nasal mucosa and the vomer. Thereafter, the palate is covered with gauze impregnated with antibiotic Achromycin® ointment (Lederle, Japan) to prevent infection of the gauze. The gauze is kept in place by suturing a preoperatively constructed acrylic plate to the palate. Plate and gauze are removed 1 week postoperatively.

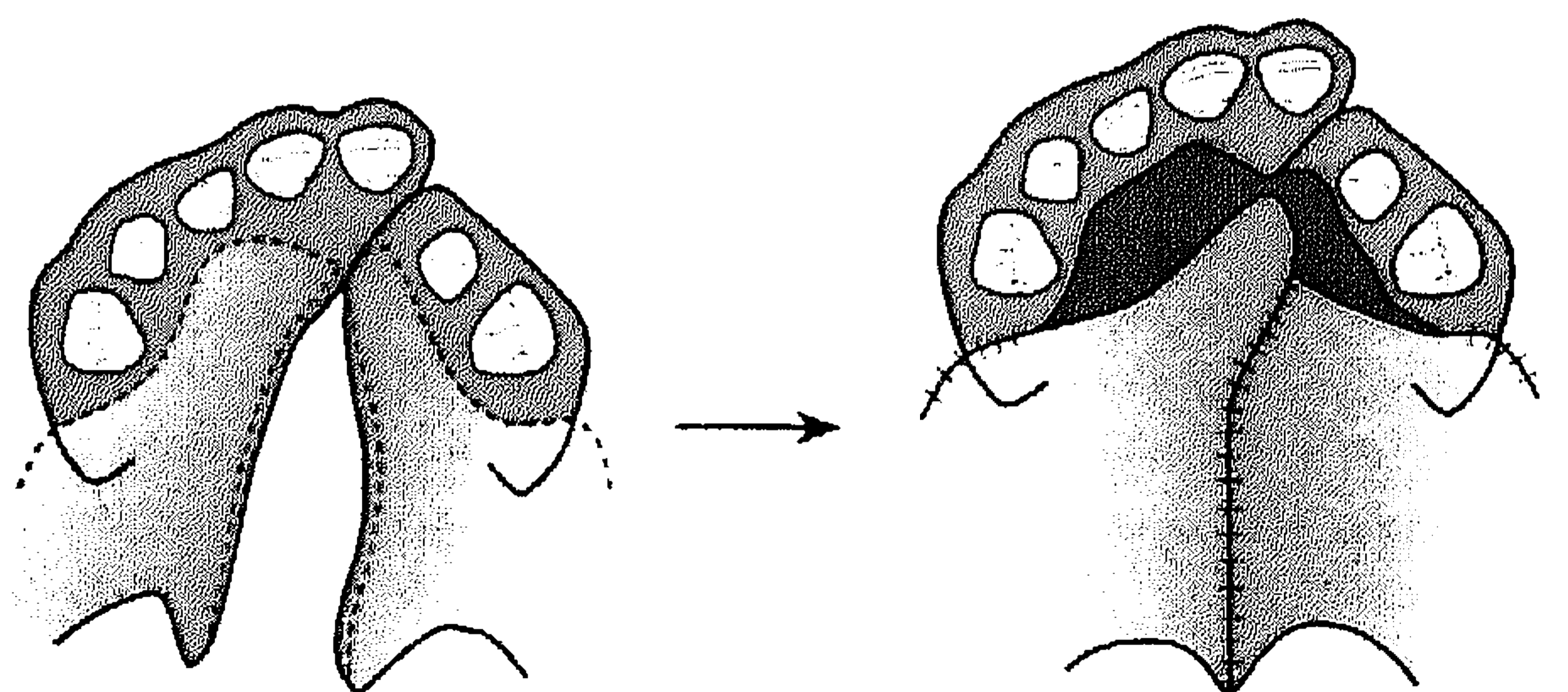


FIGURE 1 Schematic drawing of the Kohama suprapariosteal technique for UCLP patients. After surgery no denuded bone is present.

**Mucoperiosteal Technique Described by Wardill**

In Sapporo, the push-back technique, as described by Wardill, was used as the mucoperiosteal technique before the supraperiosteal technique was introduced in 1980. This mucoperiosteal technique was performed in the same way as the supraperiosteal technique except for the splitting of the mucoperiosteum to produce areas of denuded bone. A detailed description of the push-back technique is provided in Wardill (1937).

**General Information**

General information related to the palatal surgery was obtained from the files from the patients and from oral information given by the surgeons. This included hospitalization period, duration of the palatal repair, amount of blood loss, peri- and postoperative complications, combinations with other kinds of surgery, and duration of wound healing.

**Arch Dimensions**

The following landmarks were defined on the preoperative dental casts (Fig. 2):

- incisal point (I): top of the alveolar crest where the incisive papilla and the labial frenulum meet or the midpoint between the central incisors (if available)
- canine points (C,C'): tops of the alveolar crest where the lateral sulcus and the lateral frenulum meet
- tuberosity points (T,T'): the most posterior points of the maxillary tuberosities

- midpoint (M): midpoint of the line connecting the points T and T'
- greater segment point (g): most medio-anterior point of the greater segment at the margin of the cleft
- lesser segment point (l): most medio-anterior point of the lesser segment at the margin of the cleft
- c,c' points: points at intersection of the margin of the cleft and the line connecting the points C and C'
- t,t' points: points at the intersection of the margin of the cleft and the line connecting the points T and T'

The following landmarks were used to measure the following distances:

- arch widths: the distances between C and C' and T and T'
- anterior, middle, and posterior cleft widths: distances between g and l, c and c', and t and t'
- arch depth: distance between I and M

The following landmarks were defined postoperatively on the dental casts for the deciduous dentition (Fig. 3):

- incisal point (I): midpoint between the central incisors
- gingiva points (c,c',m1,m1',m2,m2'): center points at the palatal gingival margin of the deciduous canines, and of the deciduous first and second molars
- tuberosity points (T,T'): the most posterior points of the maxillary tuberosities
- midpoint (m): midpoint of the line connecting the points m2 and m2'
- midpoint (M): midpoint of the line connecting the points T and T'

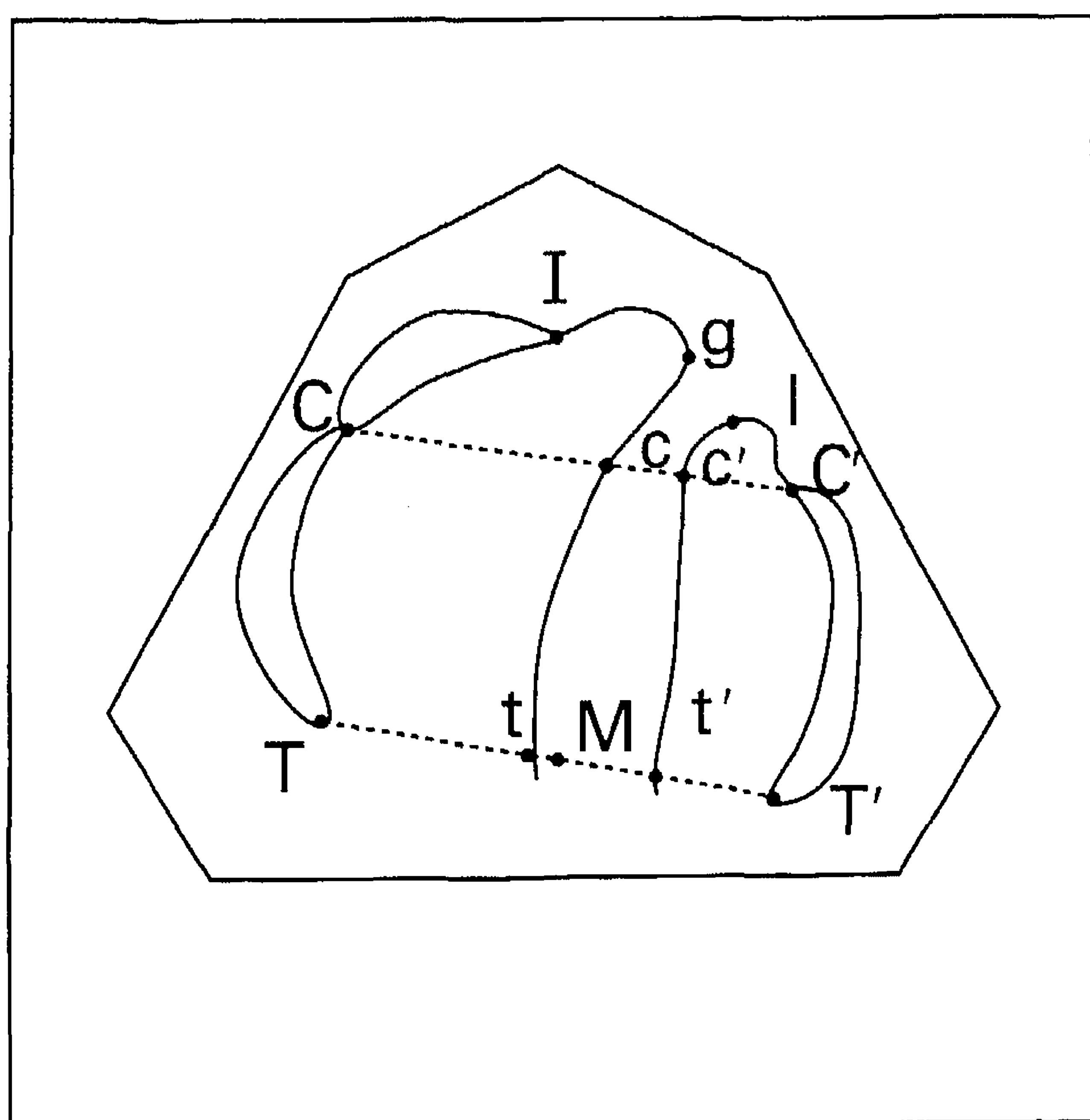


FIGURE 2 Schematic drawing of a preoperative dental cast with measuring points.

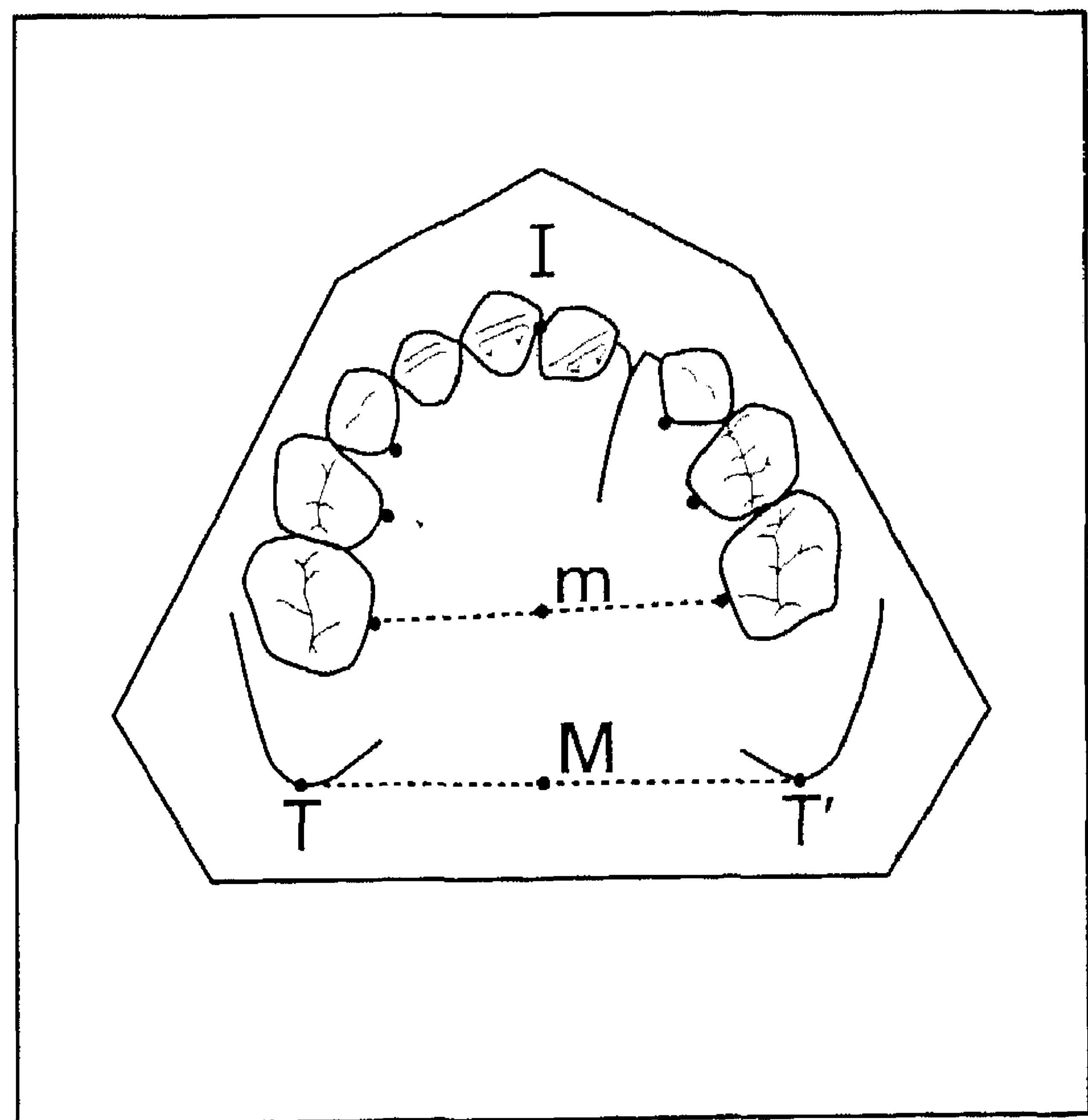


FIGURE 3 Schematic drawing of a postoperative dental cast with measuring points.

The following landmarks were used to measure the following distances:

- transverse distances: the distances between c and c', m1 and m1', m2 and m2', and T and T'
- arch depths: the distances between I, and m and/or M

All measurements were performed by one observer using a digital caliper (Digimatic CD-15D; Mitutoyo, U.K.). To determine the measurement error, 20 presurgical and 20 postsurgical dental casts were measured twice by the same observer with a time interval of 1 month.

### Statistical Analysis

The preoperative comparability of the treatment groups was tested using a *t* test on the variables gl, cc', tt', and by two-way ANOVA on the variables CC', TT', and IM. Interaction between cleft type and technique on the preoperative values was tested using a two-way ANOVA. Treatment differences were tested using a three-way ANOVA while correcting for possible influences of cleft type and sex.

## RESULTS

### General Information

All patients were hospitalized 1 week prior to palatal surgery for extensive medical examination. The palatal repair was not combined with other surgical interventions. In all groups, the time needed for surgery was about 1 hour. The extra time needed for splitting of the mucoperiosteum in the SP technique was about 5 minutes. The perioperative blood loss was approximately 20 to 30 mL for both techniques, so blood transfusion was never necessary. None of the patients suffered from complications during or after surgery. Wound healing was evaluated until 4 weeks after surgery. Re-epithelialization was completed after approximately 1 week in the SP groups and after about 3 weeks in the MP groups. All patients were released in good condition 2 weeks after surgery but visited the outpatient clinic every week until 4 weeks after surgery.

### Dental Casts Measurements

#### Reproducibility of the Method

The preoperative measurements had an average duplicate measurement error of 0.13 mm (range, 0.07–0.18 mm). The average duplicate measurement error of the postoperative measurements was 0.11 mm (range, 0.02–0.19 mm). The accuracy of the method was considered to be acceptable.

#### Measurements

The preoperative measurements are summarized in Table 1. No significant differences were found between the SP and the MP group of the UCLP patients nor between those of the CP patients. The arch width (i.e., CC' and TT') was significantly larger in the UCLP group compared with the CP group. The arch depth (IM) was larger in the CP group. No statistically significant interactions were found between the technique of palatal repair and the type of cleft (i.e., CP or UCLP).

The results of the dental cast measurements after surgery are presented in Table 2. The results of the arch width (cc') and the arch depth (IM) are presented in graphic display in Figures 4 and 5. The arch depths of the SP groups were larger than those of the MP groups. Except for the first year after surgery, the arch depths of the CP groups were larger than those of the UCLP groups. No significant differences in arch width were found except for the distance m1m1' measured in the fifth year after palatal repair, which was wider in the SP group. A sex difference was found in about one quarter of all measurements, the values for boys being larger than for girls.

## DISCUSSION

In this study, the perioperative and postoperative course as well as the development of the deciduous dentition in UCLP and CP patients was investigated up to 5 years after palatal closure using the Kohama supraperiosteal flap technique or the Wardill push-back technique. The essential difference between these two surgical techniques is that the Wardill technique results in areas of denuded bone, while the Kohama technique does not.

TABLE 1 T Test on the Preoperative Comparability of the Variables gl, cc', and tt' and Two-Way ANOVA on the Variables CC', TT', and IM

Variable	UCLP Patients						CP Patients						Test Results Significant Difference
	SP Technique			MP Technique			SP Technique			MP Technique			
	n	X	SD	n	X	SD	n	X	SD	n	X	SD	
gl	23	2.6	3.4	17	2.2	2.6	—	—	—	—	—	—	NS
cc'	23	5.7	4.5	17	6.4	3.9	—	—	—	—	—	—	NS
tt'	23	10.7	2.8	17	9.7	1.9	—	—	—	—	—	—	NS
CC'	23	31.8	3.2	17	32.6	3.6	15	30.5	1.3	19	30.2	2.5	UCLP > CP
TT'	23	36.8	3.3	17	37.1	2.4	15	35.7	2.5	19	35.6	2.9	UCLP > CP
IM	23	28.4	2.0	17	28.2	1.6	15	30.1	2.1	19	29.5	2.2	CP > UCLP

Mean (X) and standard deviation (SD) are presented in mm. Differences are given at  $p < .05$  level. NS = not significant.

TABLE 2 Test Results of Three-Way ANOVA According to Technique of Palatal Repair, Cleft Type and Sex

Variable	Year	UCLP Patients										CP Patients										Test Results Significant Difference				
		SP Technique					MP Technique					SP Technique					MP Technique									
		n	$\bar{X}$	SD	n	$\bar{X}$	SD	n	$\bar{X}$	SD	n	$\bar{X}$	SD	n	$\bar{X}$	SD	n	$\bar{X}$	SD	n	$\bar{X}$		SD			
c'	1	12	22.2	3.4	3	20.6	1.8	5	23.2	3.3	1	27.1	-	2	22.8	1.8	7	22.1	2.2	4	21.5	2.6	5	21.7	1.4	NS
m1m1'	1	12	25.0	3.1	3	23.2	1.8	5	25.7	3.5	1	30.3	-	2	25.8	1.3	7	22.1	2.2	4	22.7	3.0	5	23.8	2.5	NS
m2m2'	1	4	28.4	2.9	-	-	-	3	28.9	3.7	-	-	-	1	30.5	-	3	26.9	2.4	3	26.6	4.2	1	30.7	-	NS
Im	1	4	21.5	1.4	-	-	-	4	21.2	3.0	-	-	-	1	22.7	-	4	22.1	1.9	3	20.1	1.6	1	21.7	-	NS
IM	1	12	29.5	2.3	3	27.6	4.1	5	29.3	2.8	1	25.0	-	2	33.1	0.4	7	31.0	1.9	4	28.0	1.9	5	27.1	1.8	SP>MP
cc'	2	20	22.8	2.8	9	21.4	3.1	6	24.4	3.5	7	19.7	4.4	12	22.4	2.1	15	22.0	1.8	7	22.3	2.4	10	22.5	1.2	♂>♀
m1m1'	2	20	25.3	2.9	9	24.2	3.2	6	26.5	4.8	7	22.1	4.5	12	23.7	2.7	15	23.8	2.1	7	24.3	3.9	10	23.5	2.0	NS
m2m2'	2	16	29.3	2.7	5	29.4	1.5	6	30.6	5.1	5	25.5	4.8	11	27.3	3.2	13	27.6	1.8	7	27.5	4.0	9	27.5	4.9	NS
Im	2	16	21.7	1.7	5	21.8	0.9	6	22.4	2.9	5	21.6	1.7	11	22.4	1.6	13	22.3	1.6	7	23.0	2.5	9	21.5	1.5	NS
IM	2	20	31.3	1.7	9	29.7	2.9	6	30.2	2.7	7	27.3	1.9	12	32.3	2.4	15	32.0	1.8	7	31.6	2.1	10	30.8	1.9	SP>MP, CP>UCLP, ♂>♀
cc'	3	17	22.8	2.5	6	20.3	2.1	9	23.7	2.5	9	19.3	3.9	9	22.3	2.1	15	21.8	1.9	8	23.1	1.5	15	21.1	1.8	♂>♀
m1m1'	3	16	25.2	2.8	6	22.7	3.0	9	24.9	4.3	8	21.4	4.6	9	24.0	3.0	15	23.6	2.1	8	24.6	2.2	15	22.0	2.8	♂>♀
m2m2'	3	17	29.2	3.2	5	27.8	2.7	9	28.5	4.7	8	25.7	5.1	9	28.0	2.8	15	26.9	2.4	8	27.9	2.6	15	26.4	3.7	♂>♀
Im	3	17	21.9	1.4	5	20.8	0.9	9	22.0	3.5	8	21.9	1.1	9	22.6	2.3	15	22.1	1.6	8	21.7	2.2	15	21.6	1.5	ns
IM	3	16	32.1	1.5	6	29.5	2.8	9	29.8	3.0	9	29.5	1.9	9	33.6	2.5	15	33.5	2.4	8	30.7	2.1	15	31.6	2.3	SP>MP, CP>UCLP
cc'	4	14	22.5	2.5	4	20.5	2.5	6	24.0	2.9	7	19.9	3.4	6	22.0	1.8	11	21.8	2.0	8	23.2	2.0	11	21.0	2.2	♂>♀
m1m1'	4	13	24.6	3.2	4	22.2	3.3	6	25.5	5.2	7	21.6	3.7	6	23.2	3.3	11	23.7	2.3	7	24.8	2.8	10	22.2	3.1	♂>♀
m2m2'	4	14	28.4	2.6	3	28.9	1.2	6	29.3	5.3	7	24.5	4.3	6	26.4	3.3	11	27.3	2.2	8	28.4	3.2	11	26.9	3.5	ns
Im	4	13	22.0	1.7	3	21.7	1.1	6	23.4	4.7	7	22.1	1.3	6	22.8	1.7	11	22.0	1.6	8	21.8	1.7	11	21.8	1.8	ns
IM	4	12	33.2	1.8	4	30.3	4.0	6	30.7	2.6	7	29.9	1.8	6	35.5	2.9	11	34.7	2.1	8	32.3	2.0	11	32.9	2.8	SP>MP, CP>UCLP
cc'	5	12	22.4	2.4	3	19.8	2.9	11	20.9	3.6	6	20.4	3.6	5	22.4	1.2	8	21.6	2.4	4	24.9	1.0	5	20.7	3.2	♂>♀
m1m1'	5	11	24.5	3.0	3	21.6	4.4	10	21.5	3.8	6	22.2	4.0	5	24.1	2.4	8	23.3	2.8	2	23.0	0.1	5	20.9	4.2	SP>MP
m2m2'	5	12	27.5	2.5	3	25.8	6.4	11	25.9	3.1	6	24.8	5.3	5	26.7	2.9	8	26.9	2.1	4	27.6	2.8	5	25.6	5.1	ns
Im	5	11	22.8	1.8	3	21.6	2.4	11	23.4	4.3	6	22.2	1.4	5	21.6	0.9	8	21.8	2.3	4	21.7	2.2	5	21.7	0.6	ns
IM	5	11	33.9	3.9	3	31.4	5.9	11	31.3	3.0	6	31.0	2.7	5	37.5	3.1	8	36.5	3.0	4	34.2	2.4	5	35.8	3.5	SP>MP, CP>UCLP

Mean ( $\bar{X}$ ) and standard deviation (SD) are presented in mm. Differences are given at the  $p < .05$  level. NS= not significant.

No differences in hospitalization period, perioperative blood loss, or complications during or after surgery were found between the two techniques. Although the cleavage of the mucoperiosteum took about 5 minutes extra time, the average overall time needed for surgery was comparable for both techniques. When no denuded bony areas were present after operation (SP technique), re-epithelialization was completed after approximately 1 week. This was in contrast to the MP

technique, in which it took 3 weeks for epithelialization over the former denuded areas. The healing of the flaps and the short re-epithelialization time in the SP group were also found in experimental studies by Leenstra et al. (1995a, b).

Our postoperative measurements showed that the arch depths (IM) in the SP groups were significantly larger compared to the MP groups. This might be explained by differences in scar tissue in the anterior part of the palate. This assumption is based

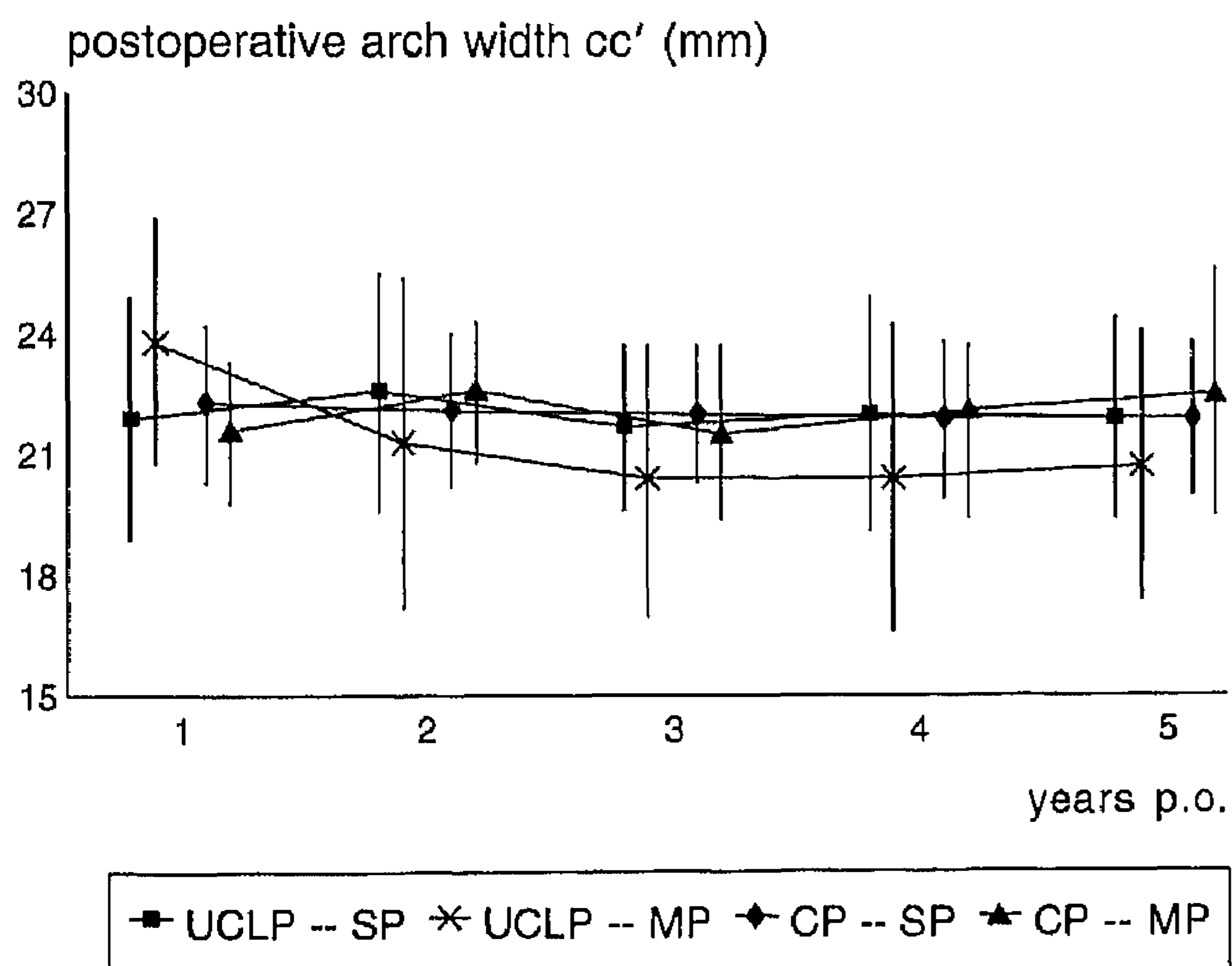


FIGURE 4 Graphic display of the arch width (cc') until 5 years after palatal repair.

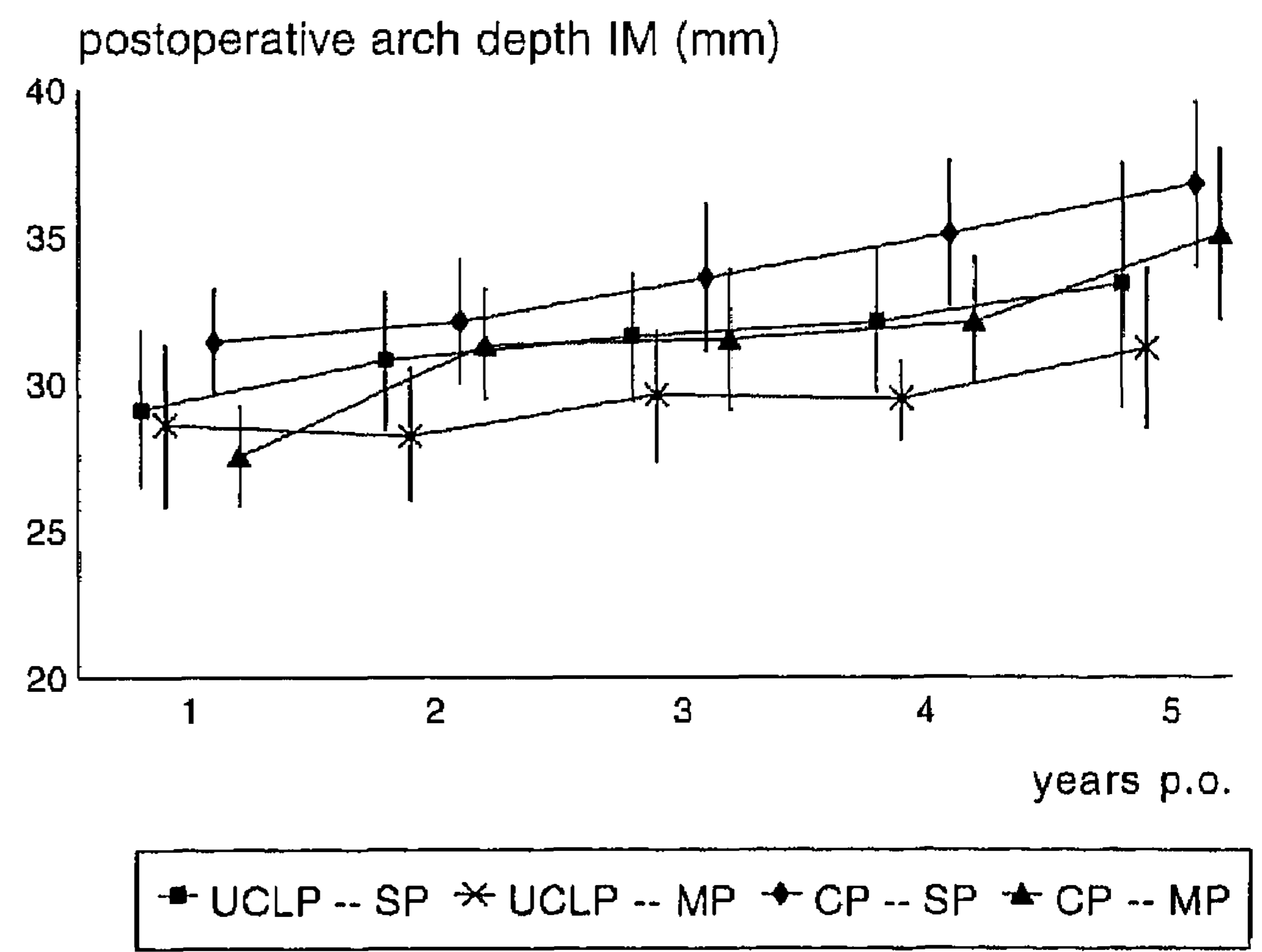


FIGURE 5 Graphic display of the arch depth (IM) until 5 years after palatal repair.

on animal studies showing that scar tissue covering denuded bony areas differs in structure, composition, and outline compared to scar tissue in wound areas where the deeper layer of the mucoperiosteum remained *in situ* (Densho, 1982; Wijdeveld et al., 1991; Leenstra et al., 1995b). Since the described surgical techniques are push-back procedures, the scar-tissue areas are located mainly in the anterior parts of the palate. Differences in scar tissue might have led to a greater tensile force in the MP group, resulting in sagittal-growth inhibition. Lip closure was performed at the age of 3 months using two different techniques: the Tennison-Randall technique (Randall, 1959) for complete cleft lips or the Millard procedure for complete and incomplete lips. The preoperative measurements prior to cleft palate repair at the mean age of 17 months showed no differences between the SP and the MP group of the UCLP patients, so the technique of lip repair was considered not to be a confounder in this study.

Except for the first year after surgery, arch depth (IM) was significantly smaller in the UCLP groups compared to the CP groups. This was also found in the study of Honda et al. (1995) and might be explained by the increased pressure from the reconstructed lip following cheiloplasty. Mazaheri et al. (1971), however, did not find significant differences in arch depth between these two types of operated clefts.

Except for the fifth year after palatal repair in which the distance  $m_1m_1'$  was wider in the SP groups, there were no significant differences in arch width. This is supported by the studies in Beagle dogs of Wijdeveld et al. (1989), in which the narrowing of the dental arch after a von Langenbeck palatal repair became only apparent after shedding of the teeth, at least in dogs. The reason for this might be that the scar tissue results in a tensile force in a medial direction on the teeth. This could lead to an eruption in a medial rather than a lateral direction during transition.

Considering the study of Leenstra et al. (1995b), in which no negative effects on dento-alveolar development in Beagle dogs were found after palatal repair using a modified partially split technique, it might be speculated that the arch width of the permanent dentition of the SP groups will show a better development than that of the MP groups. However, to elucidate this, this group has to be followed until maturity.

In about one quarter of all the measurements, the values for boys were larger than for girls. Considering sexual dimorphism, this outcome is not surprising.

From the results of the present study, it can be concluded that the Kohama supraperiosteal technique can be performed successfully in almost equal time as the Wardill push-back technique. Re-epithelialization of the wound areas after supraperiosteal repair takes about one third of the time compared to the healing after the mucoperiosteal technique. The sagittal maxillary development of the primary dentition after the SP technique is superior compared to the MP technique. Future research is needed to elucidate the question of whether or not the SP technique favors dento-alveolar development in the permanent dentition in humans.

## REFERENCES

- BARDACH J. The influence of cleft lip repair on facial growth. *Cleft Palate J* 1990;27:76-78.
- BARDACH J, KELLY KM. Role of animal models in experimental studies of craniofacial growth following cleft lip and palate repair. *Cleft Palate J* 1988;25:103-113.
- BARDACH J, KELLY KM, JAKOBSEN JR. Simultaneous cleft lip and palate repair: an experimental study in Beagles. *Plast Reconstr Surg* 1988;82:31-39.
- DENSHO S. Histological and scanning electron microscopic studies on the healing process of various surgical wound in young rats (Japanese language; English abstract). *Sapporo Med J* 1982;51:243-260.
- GRABER TM. The congenital cleft palate deformity. *J Am Dent Assoc* 1954; 48:375-395.
- HERFERT O. Experimenteller Beitrag zur Frage der Schädigung des Oberkiefers durch vorzeitige Gaumenspalatoperation. *Dtsch Zahn-Mund-Kieferheilk* 1954;20:369-380.
- HERFERT O. Tierexperimentelle Untersuchungen über die biologische Wertigkeit von Brückenlappen (Axhausen) und Stiellappen (Palatinallappen) bei der Gaumenplastik. *Dtsch Zahn-Mund-Kieferheilk* 1956;24:112-120.
- HERFERT O. Fundamental investigations into problems related to cleft palate surgery. *Br J Plast Surg* 1958;11:97-105.
- HONDA Y, SUZUKI A, OHISHI M, TASHIRO H. Longitudinal study on the changes of maxillary arch dimensions in Japanese children with cleft lip and/or palate: infancy to 4 years of age. *Cleft Palate Craniofac J* 1995; 32:149-155.
- KOHAMA G. Comparison of a modified mucosal flap-, with a mucoperiosteal flap push-back technique in palatal repair (Japanese language). *Jpn Cleft Palate J* 1991;16:151-160.
- KREMENAK CR. Physiological aspects of wound healing: contraction and growth. *Otolaryngol Clin North Am* 1984;17:437-453.
- KREMENAK CR, OLIN WH, HUFFMAN WC. Growth of maxillae after palatal surgery: I. *Cleft Palate J* 1967;4:6-17.
- KREMENAK CR, OLIN WH, HUFFMAN WC. Growth of maxillae after palatal surgery: II. *Cleft Palate J* 1970;7:719-736.
- LEENSTRA TS, MALTHA JC, KUIJPERS-JAGTMAN AM, SPAUWEN PHM. Wound healing in Beagle dogs after palatal repair without denudation of bone. *Cleft Palate Craniofac J* 1995a;32:362-370.
- LEENSTRA TS, KUIJPERS-JAGTMAN AM, MALTHA JC, FREIHOFFER HPM. Palatal surgery without denudation of bone favours dento-alveolar development in dogs. *J Oral Maxillofac Surg* 1995b;24:440-444.
- MAZAHERI M, HARDING RL, COOPER JA, MEIER JA, JONES TS. Changes in arch form and dimensions of cleft patients. *Am J Orthod* 1971;60:19-33.
- MILLARD DR JR. *Cleft craft: the evolution of its surgery. I. The unilateral deformity.* Boston: Little, Brown, 1976.
- PERKO MA. Primary closure of the cleft palate using a palatal mucosal flap: an attempt to prevent growth impairment. *J Maxillofac Surg* 1974;2:40-43.
- PERKO MA. Two-stage closure of cleft palate. *J Maxillofac Surg* 1979;7:76-80.
- RANDALL P. A triangular flap operation for the primary repair of unilateral cleft of the lip. *Plast Reconstr Surg* 1959;23:331-347.
- ROSS RB. Treatment variables affecting facial growth in complete unilateral cleft lip and palate. Part 1. Treatment affecting growth. *Cleft Palate J* 1987a;24:15-23.
- ROSS RB. Treatment variables affecting facial growth in complete unilateral cleft lip and palate. Part 6. Techniques of palate repair. *Cleft Palate J* 1987b;24:64-70.
- ROSS RB, JOHNSTON MC. *Cleft lip and palate.* Baltimore: Williams & Wilkins, 1972.
- WARDILL WEM. The technique of operation for cleft palate. *Br J Surg* 1937; 25:117-130.
- WIJDEVELD MGMM, GRUPPING EM, KUIJPERS-JAGTMAN AM, MALTHA JC. Maxillary arch dimensions after palatal surgery at different ages on Beagle dogs. *J Dent Res* 1989;68:1105-1109.
- WIJDEVELD MGMM, MALTHA JC, GRUPPING EM, DE JONGE J, KUIJPERS-JAGTMAN AM. A histological study of tissue response to simulated palatal surgery at different ages on Beagle dogs. *Arch Oral Biol* 1991;36:837-843.