

Neurofibroma in the articular disc of the temporomandibular joint: a case report

Philip A. Van Damme¹, Hans Peter M. Freihofer¹, Peter C. M. De Wilde²

¹Department of Oral and Maxillofacial Surgery (Head: Prof. H. P. M. Freihofer, MD, DMD, PhD),

²Department of Pathology (Head: Prof. D. J. Ruiter, MD, PhD), University Hospital Nijmegen St Radboud, Nijmegen, The Netherlands

SUMMARY. In classical Von Recklinghausen neurofibromatosis (Type I), skeletal defects occur as a result of abnormalities of derivatives of the neuroectoderm and mesoderm. Temporomandibular joint (TMJ) disorders caused by neurofibroma in the joint capsule or disc have not been reported previously in the English language literature. A case of neurofibroma in the TMJ articular disc in a 29-year-old woman with neurofibromatosis Type I is presented.

INTRODUCTION

Multiple neurofibromatosis was first described by Tilesius in 1793 (Adekeye et al., 1984). In 1849, the entity was reported by Smith, but was more extensively described by Von Recklinghausen in 1882 (Von Recklinghausen, 1882; McLoughlin et al., 1991). Classical Von Recklinghausen neurofibromatosis (Type I) is an autosomal dominant disorder with an incidence of 1 per 2000-3300 live births (Riccardi, 1981; D'Ambrosio et al., 1988; Fleury, 1989; Gorlin et al., 1990; Geist et al., 1992).

Skeletal defects such as aplasia, dysplasia, or local bone atrophy, due to neurofibroma and osteoporosis, occur as a result of abnormalities of derivatives of the neuroectoderm and the mesoderm. In some patients, central 'cystic' lesions of bone, resulting from expansive growth of neurofibromas within the medullary cavity, are seen (Fleury, 1989; Gorlin et al., 1990; Van Damme and Mooren, 1994).

The main features in the head and neck region include neurofibroma of cranial nerves III, V, VII and VIII, enlargement of cranial nerve foramina I, V, VIII, plexiform neurofibroma of the external ear, bony craniofacial anomalies, e.g. absence of sphenoid bone, ethmoid and maxillary hypoplasia, facial asymmetry, hypertrophy and atrophy of facial bones, radiolucent bone defects or 'cysts', involvement of superior or inferior alveolar nerve, and widened mandibular canal and mental foramen (Holt, 1987; Meinecke, 1987; McLoughlin et al., 1991). Hypoplasia of the mandibular ramus with radiolucency in the sigmoid notch and hypoplasia of the temporal and mandibular components of the TMJ have been reported (Koblin and Reil, 1975; Müller and Sloatweg, 1981). Temporomandibular joint dysfunction and neurofibromatosis were linked in a French case report, but TMJ disorders caused by neurofibroma in the joint capsule or disc

have not been reported previously in the English language literature (Pasturel et al., 1989).

CASE REPORT

In 1990, a 24-year-old woman was referred by her family dentist to the department of Oral and Maxillofacial Surgery of the Nijmegen University Hospital, The Netherlands, because of facial asymmetry and complaints of pain in the left TMJ region and difficulty with chewing.

She was known to have Von Recklinghausen neurofibromatosis since 1982 and was being treated elsewhere by a dermatologist, ophthalmologist and neurologist. There were no hearing disorders and her family history was negative for neurofibromatosis.

She was operated on elsewhere in 1983 for an 'odontogenic myxoma' of the left half of the mandible. In 1985, a malformation of the left mandibular condyle, angle and distal cortex was found, and the complete left facial half was considered hypotrophic. Because of pain in the left mandible, tooth 38 was surgically removed. In 1988, pain in the left masseter muscle and restriction of movement in the left TMJ were reported for the first time.

When seen first in our department in 1990, there was facial asymmetry and irregularity in the contour on the left side with absence of the molars in the left half mandible and there was hypertrophic scar tissue in the floor of the mouth. The patient had multiple neurofibromata on the skin of her trunk and fewer on the skin of the extremities and face. Eight café-au-lait spots, with a diameter of 1.5 cm or more, were present. On ophthalmological examination, Lisch nodules were discovered.

In 1991, the left temporal contour deficit was corrected by autologous calvarial bone transplan-

tation and later on in the same year mandibular symmetry was restored by bone transposition from the left to the right side. The mandibular periosteum on the left side was clinically hyperplastic. Histopathological examination of a specimen revealed neurofibroma. A biopsy of the floor of the mouth also proved to be a neurofibroma. In 1995 (29-years-old), the patient presented again with pain and tenderness in the left TMJ region. On auscultation, crepitation could be heard. Active mouth opening was 40 mm interincisally (i.i.). Computer tomography (CT) scanning showed hardly any TMJ space on the left side. Conservative therapy (acrylic splint) was started. This was unsuccessful; the pain did not improve. Intra-articular local anaesthesia had an immediate positive effect on the pain and mouth opening (>45 mm i.i.). The left TMJ was therefore explored, with the diagnosis of TMJ discopathy. At operation, the capsule was extremely loose, allowing greater movements of the condylar head than normal. The upper and lower joint compartments were shown to be separated by a thin fibrous disc with a perforation at the dorso-lateral aspect (Fig. 1a). The loose attachment of the periosteum and the hyperlaxity of the soft tissues were striking. The condyle was hypoplastic and had an irregular surface (Fig. 1b). The glenoid fossa and articular tubercle were rather flat but smooth. The disc was removed (Fig. 2) and sent for histopathological examination. It was replaced by an autologous cartilaginous aural concha graft. The condylar surface was smoothed, and a drain was left in situ for 3 days. Intermaxillary fixation with elastics

between eyelets was applied for a 2 week period. Five weeks later, maximum mouth opening was 36 mm i.i.; left lateral movement was 13 mm, while right lateral movement was only 4 mm. The pain had diminished to an acceptable level.

Surprisingly, the outcome of the histopathological examination of the articular disc specimen was a neurofibroma (Fig. 3). Revision of the 1983 'odontogenic myxoma' specimen of the left mandibular half revealed a neurofibroma with myxomatous features.

DISCUSSION

All articles on neurofibromatosis in the head and neck deal with facial skeletal asymmetry (*Kragh et al., 1960; Mukherji, 1974; Adekeye et al., 1984, Maceri and Saxon, 1984; Griffith et al., 1985*). In some cases, combinations with different disorders and/or syndromes complicate the distinctive facial appearance, e.g. Noonan and Noonan-like syndrome, Gorlin's syndrome, giant cell lesions, hyperparathyroidism (*Mendez, 1985; Meinecke, 1987; Gorlin et al., 1990; Van Damme and Mooren, 1994*).

The French case report concerns a 20-year-old female patient with histopathologically confirmed neurofibroma in the capsule of the right TMJ (*Pasturel et al., 1989*). According to the description, the patient had a distinctive facial appearance compatible with the features of our patient and the descriptions of *Koblin and Reil (1975)* and *Kaplan and Rosenblatt (1985)*. It is not evident whether this

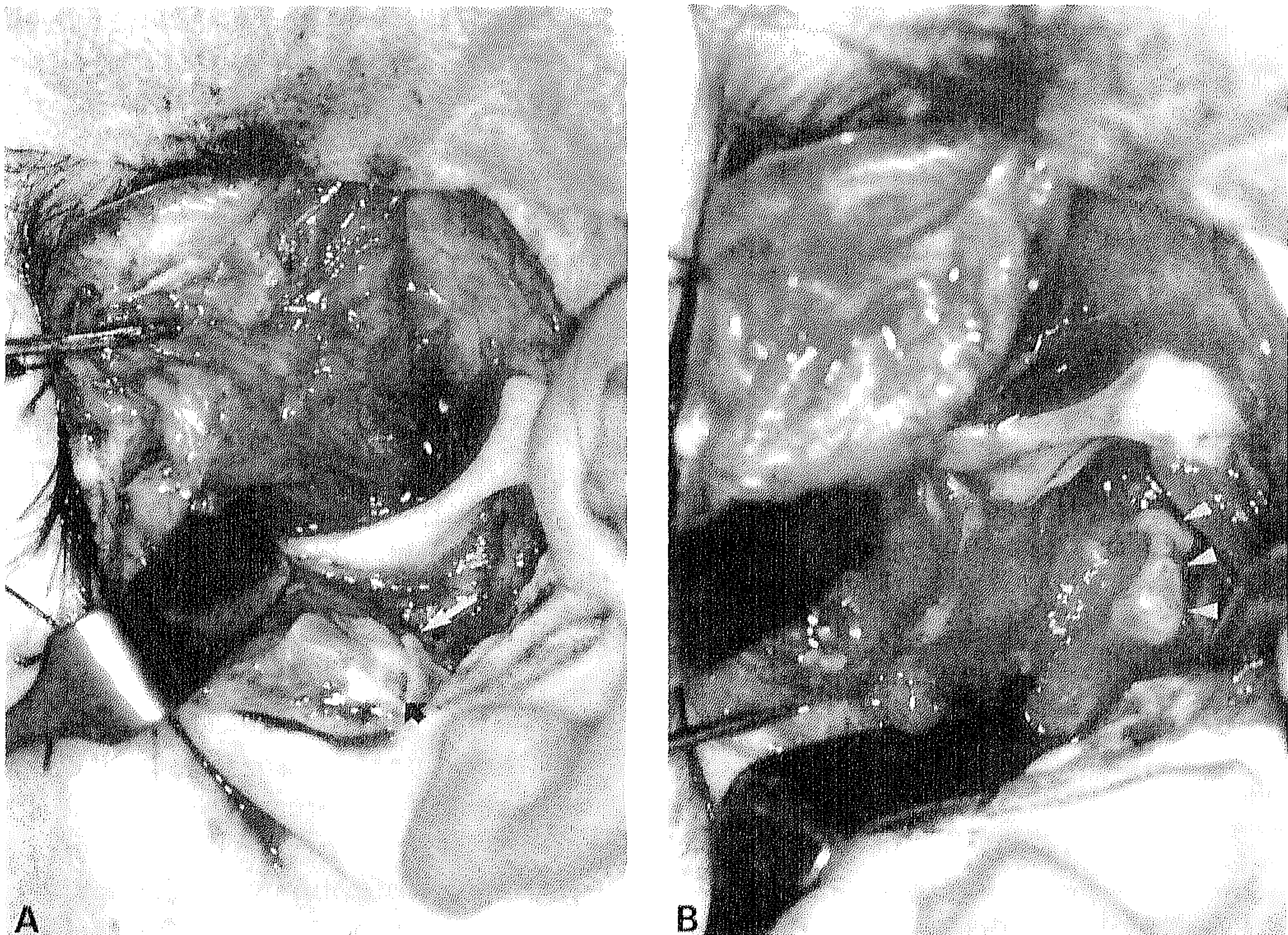


Fig. 1 – (A) Intraoperative view of opened left temporomandibular joint with thin fibrous disc separating upper and lower joint space (arrows). (B) Detail after disc extirpation. Note the loose capsula and hypoplastic condylar head (arrow heads).

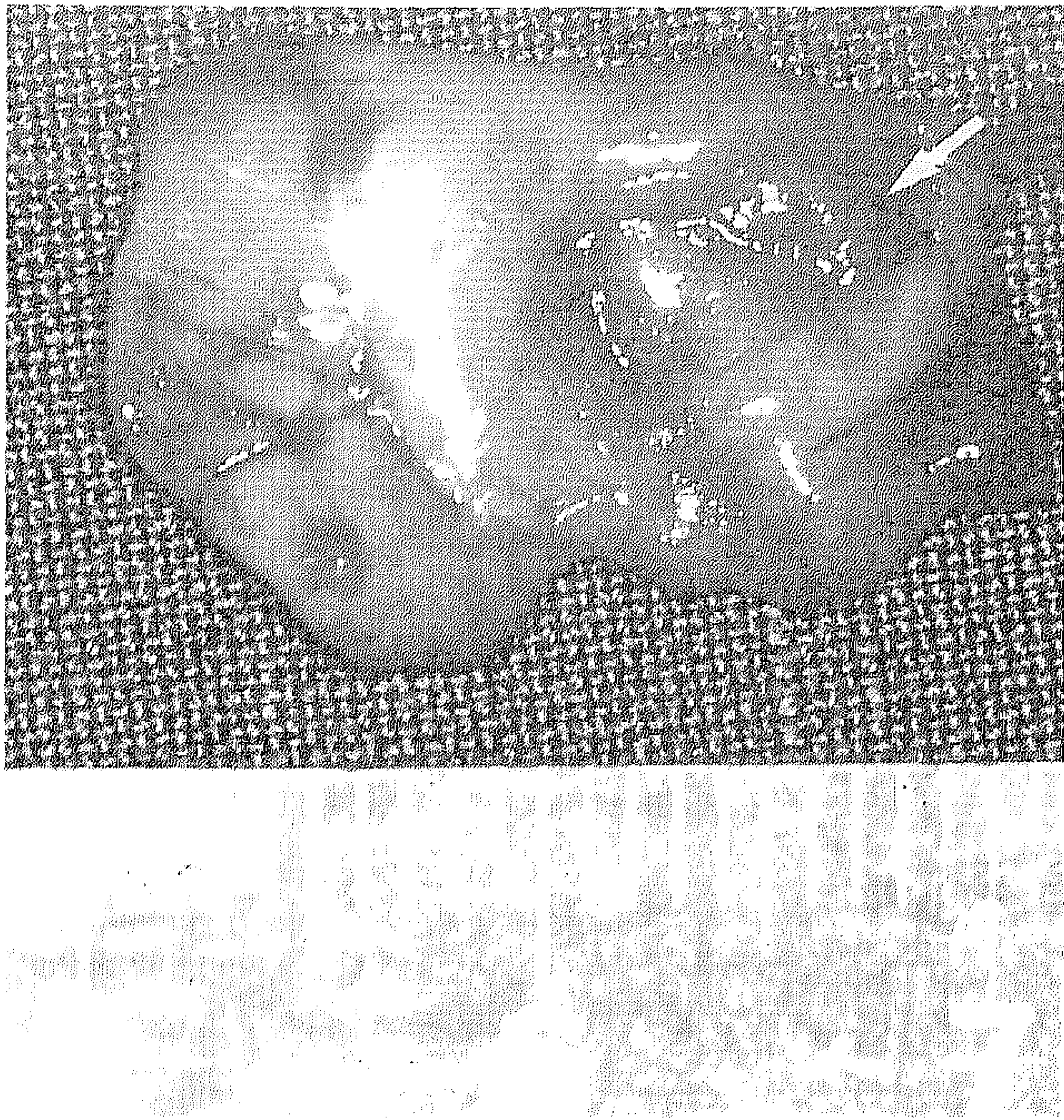

Fig. 2 – The removed disc with perforation at the dorsolateral aspect (arrow).

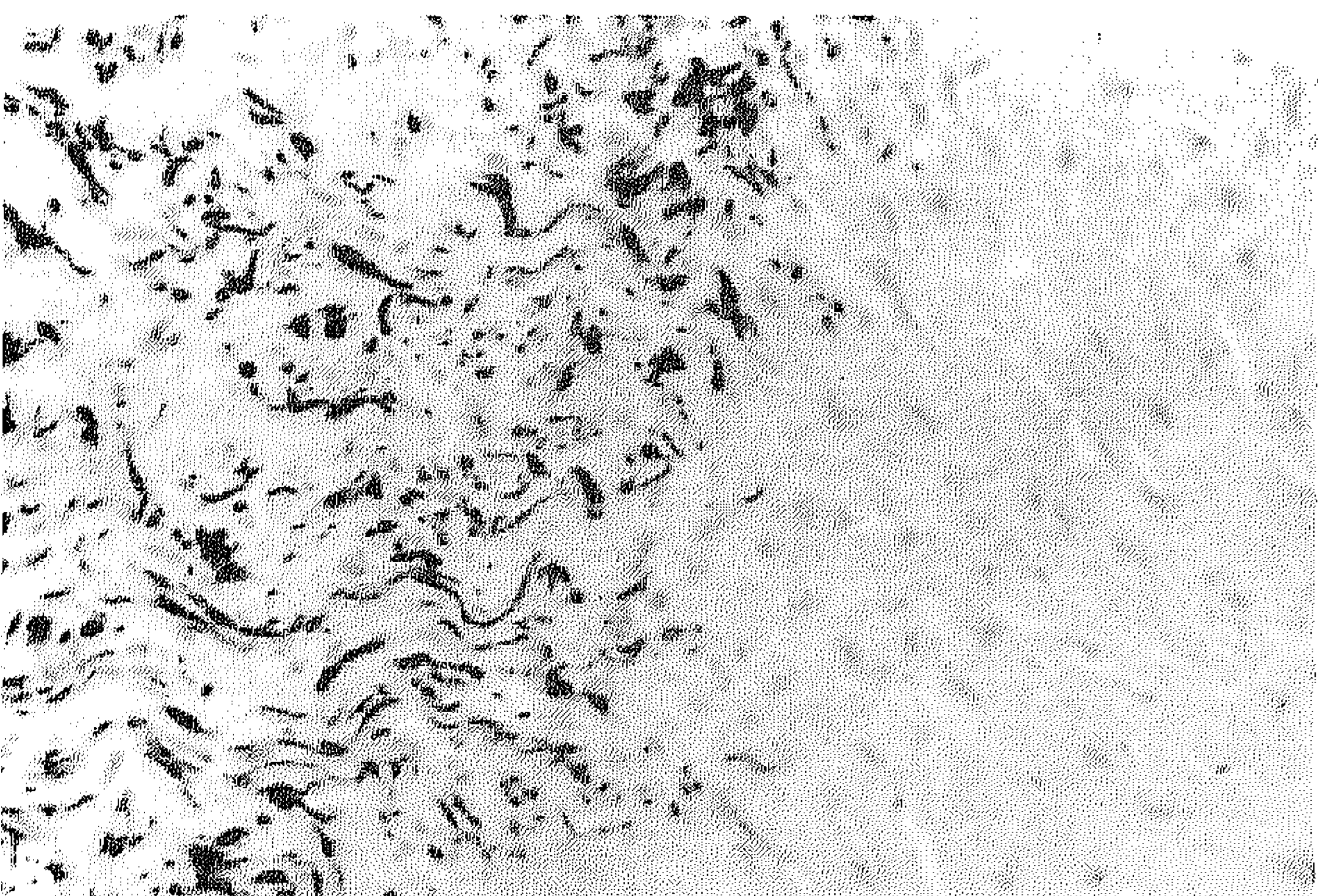
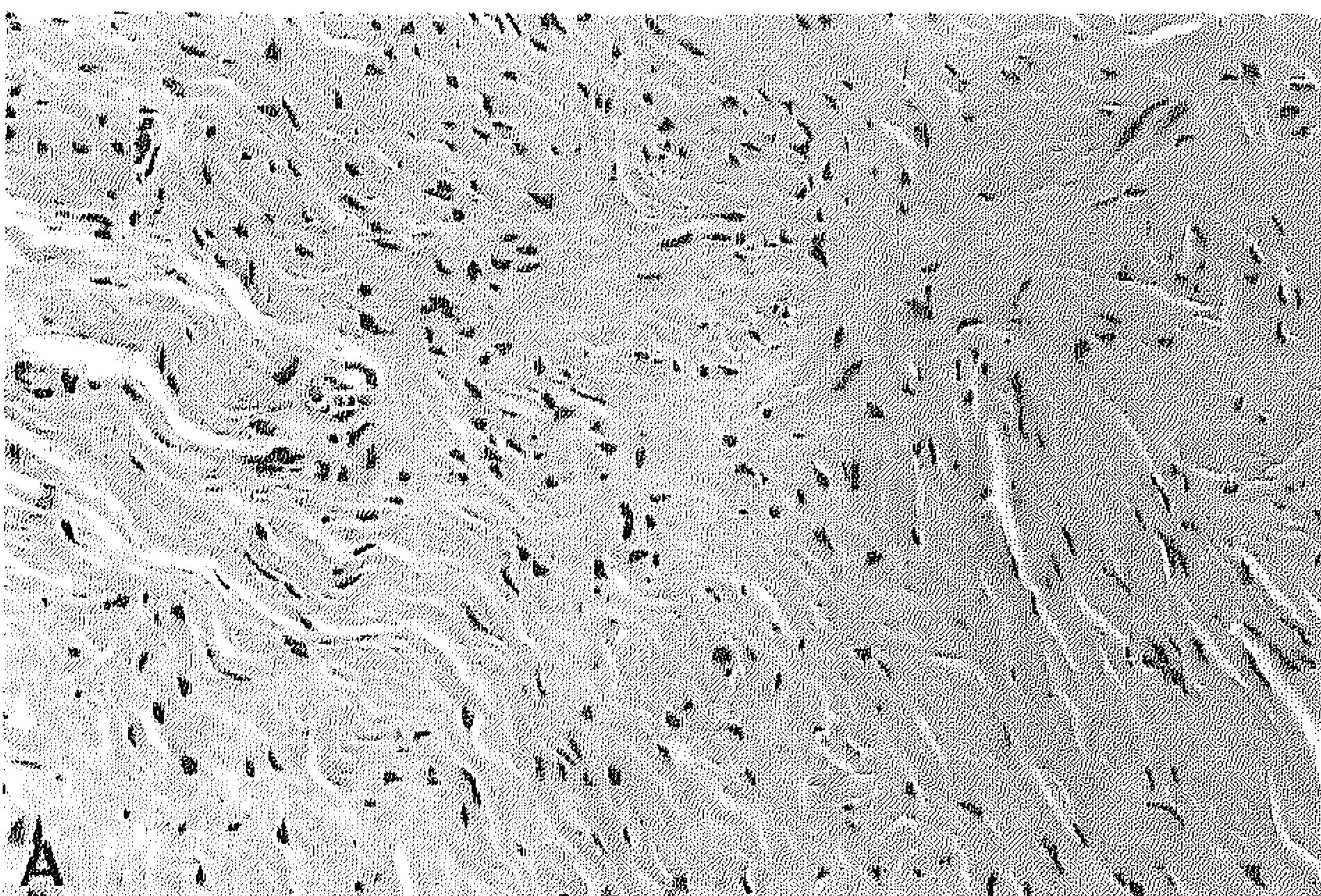


Fig. 3 – (A) Neurofibroma of the articular disc. Transition between the dense connective tissue of the articular disc (on the right side) and the more cell rich neurofibroma, composed of proliferating axons and Schwann cells (on the left side), Haematoxylin-Eosin (HE). (B) The same area immunohistochemically stained with antibodies directed against S100 protein. The proliferating Schwann cells express the S100 protein (left side), whereas the fibroblasts of the articular disc do not express this protein (on the right side).

neurofibroma originated in the capsule of the joint or was an ingrowth from the temporal area. Cutaneous (plexiform) neurofibroma in the cheek, the external ear, or the semilunar notch, can grow directly into structures belonging to the TMJ. In the French case a visible tumour existed. In our case, preoperatively, there was no clinical or CT evidence of neurofibroma in the joint or surrounding area. During surgery, again no macroscopical signs of neurofibroma were noticed. Histopathological examination revealed neurofibromatosis. Involvement of the capsule or articular disc has not been reported without visible or palpatory presence of neurofibromata in this region. *Rittersma et al.* (1972) described two cases of neurofibromatosis with radiologically widened TMJ space, deepening of the semilunar notch, hypoplasia of the condyle and flattening of the glenoid fossa. It seems possible that these are signs of neurofibroma in the joint, but the area was not explored. *Müller and Slootweg* (1981) reported four cases of facial asymmetry caused by mandibular hypoplasia and increased depth of the sigmoid notch in relation to histologically proven neurofibroma. *Sailer* (1973) reported one case of mandibular asymmetry associated with perimandibular 'haemangioma' in relation to neurofibromatosis. In this case there was also deepening of the semilunar notch, hypoplasia of the left condyle and flattening of the glenoid fossa. *Mukherji* (1974) described four patients with local neurofibroma in the head and neck region with hyperplastic changes in the underlying bone and fibromyxomatous change in the tumour, with considerable dilatation of blood vessels. During the operations on our patient no excessive bleeding was encountered. We questioned the diagnosis of an 'odontogenic myxoma' of the left mandibular half in our case. Revision of the histopathological material of the 'odontogenic myxoma' revealed a neurofibroma with myxomatous features. This suggested that the pain may also have originated from neurofibromatous involvement of the trigeminal nerve. The left TMJ dysfunction and pain were initially attributed to the asymmetry due to the early loss of mandibular molars on the left side, and/or the transposition of the left temporal muscle. The test with local anaesthesia, however, indicated a different cause. It is probable that the pain was caused by the perforation in the disc. Perforation and neurofibroma of the disc seem aetiologically linked. Unlike other disc-position-related functional TMJ disorders, it is questionable whether nuclear magnetic resonance (NMR) examination would have elucidated the presence of this neurofibroma. As for the therapy, incomplete removal of neurofibromata does not induce malignant transformation of the residual tumour, or negatively influence the growth rate (*Kragh et al.*, 1960; *Maceri and Saxon*, 1984; *Griffith et al.*, 1985).

When one is confronted with a patient with a

TMJ disorder known to have classical neurofibromatosis, a neurofibroma of the articular disc and/or capsule may be responsible. It should be either confirmed or excluded by NMR, fine needle aspiration biopsy (ultrasound guided), arthroscopy and/or surgical exploration. When a positive diagnosis is made a more aggressive course of action than the average treatment for TMJ disorder must be considered.

Acknowledgements

We would like to thank Dr. E. N. Robertson for correcting the English and Ms J. Baas-Kalée for typing the manuscript.

References

- Adekeye, E. O., A. Abiose, R. A. Ord:* Neurofibromatosis of the head and neck: clinical presentation and treatment. *J. Max.-Fac. Surg.* 12 (1984) 78-85
- D'Ambrosio, J. A., R. P. Langlais, R. S. Young:* Jaw and skull changes in neurofibromatosis. *Oral Surg.* 66 (1988) 391-396
- Fleury, P.:* Neurofibromatosis, genetic and clinical aspects. *Ned. Tijdschr. Geneesk.* 133 (1989) 2279-2283
- Geist, J. R., D. L. Gander, S. J. Stefanac:* Oral manifestations of neurofibromatosis types I and II. *Oral Surg.* 73 (1992) 376-382
- Gorlin, R. J., M. M. Cohen Jr., L. S. Levin:* Syndromes of the head and neck. 3rd Ed, Oxford University Press, New York 1990
- Griffith, B. H., V. L. Lewis, P. McKinney:* Neurofibromas of the head and neck. *Surg. Gynecol. Obstet.* 160 (1985) 534-538
- Holt, G. R.:* Von Recklinghausen's neurofibromatosis. *Otolaryngol. Clin. North Am.* 21 (1987) 179-193
- Kaplan, P., B. Rosenblatt:* A distinctive facial appearance in neurofibromatosis Von Recklinghausen. *Am. J. Med. Genet.* 21 (1985) 463-470
- Koblin, I., B. Reil:* Changes of the facial skeleton in cases of neurofibromatosis. *J. Max.-Fac. Surg.* 3 (1975) 23-27
- Kragh, L. V., E. H. Soule, J. K. Masson:* Neurofibromatosis (Von Recklinghausen's disease) of the head and neck: cosmetic and reconstructive aspects. *Plast. Reconstr. Surg.* 25 (1960) 565-573
- Maceri, D. R., K. G. Saxon:* Neurofibromatosis of the head and neck. *Head Neck Surg.* 6 (1984) 842-850
- McLoughlin, P. M., A. J. Dickenson, B. S. Avery:* Gorlin's syndrome and Von Recklinghausen's disease occurring in one family. *Br. J. Oral Maxillofac. Surg.* 29 (1991) 189-193
- Meinecke, P.:* Evidence that 'Neurofibromatosis-Noonan syndrome' is a variant of Von Recklinghausen neurofibromatosis. *Am. J. Med. Genet.* 26 (1987) 741-745
- Mendez, H. M. M.:* The neurofibromatosis-Noonan syndrome. *Am. J. Med. Genet.* 21 (1985) 471-476
- Mukherji, M. M.:* Giant neurofibroma of the head and neck. *Plast. Reconstr. Surg.* 53 (1974) 184-189
- Müller, H., P. J. Slootweg:* Maxillofacial deformities in neurofibromatosis. *J. Max.-Fac. Surg.* 19 (1981) 89-95
- Pasturel, A., A. Bellavoit, D. Cantaloube, J. P. Dandrau, P. Perichaud, G. Payement:* Dysfonctionnement des A.T.M. et neurofibromatose. A propos d'un cas (Temporomandibular joint dysfunction and neurofibromatosis. A case report). *Rev. Stomatol. Chir. Maxillofac.* 90 (1989) 17-19
- Riccardi, V. M.:* Von Recklinghausen neurofibromatosis. *N. Engl. J. Med.* 305 (1981) 1617-1626
- Rittersma, J., L. P. Ten Kate, P. Westerink:* Neurofibromatosis with mandibular deformities. *Oral Surg.* 33 (1972) 718-727
- Sailer, H. F.:* Mandibular asymmetry associated with perimandibular haemangiomas. *J. Max.-Fac. Surg.* 1 (1973) 104-109
- Van Damme, Ph. A., R. E. C. M. Mooren:* Differentiation of multiple giant cell lesions, Noonan-like syndrome and (occult) hyperparathyroidism. Case report and review of the literature. *Int. J. Oral Maxillofac. Surg.* 23 (1994) 32-36
- Von Recklinghausen, F.:* Über die multiplen Fibrome der Haut und ihre Beziehung zu den multiplen Neuromen. August Hirschwald, Berlin 1882.

Dr. Ph. A. Van Damme, MD, DMD

University Hospital Nijmegen St. Radboud
Department of Oral and Maxillofacial Surgery
PO Box 9101
NL 6500 HB Nijmegen
The Netherlands

Paper received: 4 March 1996

Accepted: 25 July 1996