







Unresolved–Disorganized Attachment is Associated With Smaller Hippocampus and Increased Functional Connectivity Beyond Psychopathology

Marie-José van Hoof ^{1,2} Madelon Riem ³ Amy Garrett ⁴ Nienke Pannekoek,⁵ Nic van der Wee ^{2,6} Marinus van IJzendoorn ^{7,8,9} and Robert Vermeiren ^{1,2,10}

¹Curium-LUMC, Department of Child and Adolescent Psychiatry, Leiden University Medical Center, Leiden, the Netherlands

²Leiden Institute for Brain and Cognition (LIBC), Leiden, the Netherlands

³Department of Medical and Clinical Psychology, Tilburg University, Tilburg, the Netherlands

⁴Department of Psychiatry, University of Texas Health Science Center, San Antonio, Texas, USA

⁵SU/UCT MRC Unit on Risk and Resilience in Mental Disorders, Department of Psychiatry, Stellenbosch University, Stellenbosch, South Africa

⁶Department of Psychiatry, Leiden University Medical Center, Leiden University, Leiden, the Netherlands

⁷Faculty of Social and Behavioural Sciences, Leiden University, Leiden, the Netherlands

⁸Department of Psychology, Education, and Child studies, Erasmus University, Rotterdam, the Netherlands

⁹Primary Care Unit, Department of Public Health and Primary Care, School of Clinical Medicine, University of Cambridge, Cambridge, United Kingdom

¹⁰Department of Child and Adolescent Psychiatry, VU University Medical Center, Amsterdam, The Netherlands

Loss and abuse in children can lead to unresolved–disorganized (UD) attachment. How this condition relates to brain structure and functional connectivity (FC) is unknown. We therefore aimed to investigate gray matter volume (GMV) and resting state functional connectivity (RSFC) correlates of UD attachment in adolescents. Based on previous neuroimaging studies of trauma effects, we hypothesized that the structure of the amygdala and hippocampus and the FC of the latter would be linked to UD attachment. Anatomical and RSFC data were collected from a mixed group of adolescents ($N = 74$) with symptoms of posttraumatic stress disorder (PTSD) related to childhood sexual abuse (CSA), anxiety/depressive symptoms, and without psychiatric disorder as part of the Emotional Pathways' Imaging Study in Clinical Adolescents (EPISCA). Bilateral volumes of the amygdala and hippocampus were measured using the FMRIB Software Library, and RSFC of the hippocampus was assessed using seed-based correlation. UD attachment was measured using the Adult Attachment Interview. Hierarchical regression and correlation were used to assess the associations between UD status (continuous and categorical), brain structure, and FC, adjusting for a general psychopathology factor, puberty stage, gender, age, and IQ. UD attachment was associated with a smaller left hippocampal volume, $R^2 = .23$, and a higher level of FC between the hippocampus and the middle temporal gyrus and lateral occipital cortex. The associations among UD attachment, specific brain structure, and FC across psychopathological classifications shows promise for dimensional complements to the dominant classificatory approach in clinical research and practice.

The loss of an attachment figure or the abuse within an attachment relationship are adverse childhood events that may have

Correspondence concerning this article should be addressed to Marie-José van Hoof, Curium-LUMC, Department of Child and Adolescent Psychiatry, Leiden University Medical Center, Leiden, The Netherlands; Leiden Institute for Brain and Cognition (LIBC), Leiden University, The Netherlands; PO Box 15, 2300 AA LEIDEN, The Netherlands. E-mail: M.J.van_Hoof@lumc.nl

© 2019 The Authors. *Journal of Traumatic Stress* published by Wiley Periodicals, Inc. on behalf of International Society for Traumatic Stress Studies. View this article online at www.onlinelibrary.com
 DOI: 10.1002/jts.22432

This is an open access article under the terms of the Creative Commons Attribution-NonCommercial License, which permits use, distribution and reproduction in any medium, provided the original work is properly cited and is not used for commercial purposes.

lifelong somatic, psychiatric, and psychosocial consequences for the individual (Anda et al., 2006; Felitti et al., 1998). From an attachment theory perspective (Bowlby, 1969, 1980; Hesse, 2016), loss and abuse increase the likelihood of unresolved–disorganized (UD) attachment: The child may show signs of current mental impact from loss of loved ones or abuse, or the child may apply contradictory approach–avoidance strategies to relationships with parents or other attachment figures. For example, the child may simultaneously display proximity-seeking and avoidant behaviors. This UD attachment is considered a (momentary) breakdown of an organized strategy to deal with stressful situations. It results from abuse or another traumatic experiences within the attachment relationship, thus confronting the child with a paradox, as the parent is both

a source of comfort and fear at the same time for the child (Lyons-Ruth & Jacobvitz, 2016). Not all children are able to resolve these traumatic attachment experiences. Some adolescents show signs of disorientation and disorganization while discussing early traumatic attachment events, indicating that they are still overwhelmed by the trauma or loss experience (Hesse, 2016; Lyons-Ruth & Jacobvitz, 2016). This UD mental representation may negatively impact current and future attachment relationships and the transition to adult functioning (Hesse & Main, 2000).

Previous research has indicated that experiences of loss and abuse increase an individual's risk for psychopathology, including posttraumatic stress disorder (PTSD) as well as anxiety or depressive disorders (Cloitre et al. 2009; Gospodarevskaya, 2013; McLaughlin, Sheridan, & Lambert, 2014). This may be at least partially attributable to the profound adverse effects of early life stress on brain development, particularly the hippocampus, a stress-sensitive brain region that plays a role in the regulation of the hypothalamic–pituitary–adrenal (HPA) axis. Previous studies have found evidence for a smaller hippocampal volume in healthy adults who report experiences of abuse but not in children who have experienced abuse (Calem, Bromis, McGuire, Morgan, & Kempton, 2017; Hart & Rubia, 2012; Riem, Alink, Out, Van IJzendoorn, & Bakermans-Kranenburg, 2015; Rinne-Albers, Van der Wee, Lamers-Winkelmann, & Vermeiren, 2013). A reduced hippocampal volume has also been found in adults with PTSD (Chen & Etkin, 2013). Studies examining brain structure in patients with anxiety and depressive disorders have shown diverging results, from a larger amygdala volume to a smaller left hippocampal volume (DeBellis et al., 2000; Koolschijn, Van IJzendoorn, M. H., Bakermans-Kranenburg, & Crone, 2013; MacMillan et al., 2003; Pechtel, Lyons-Ruth, Anderson, & Teicher, 2014; Schmaal et al., 2016). It is, however, possible that experiences of trauma account for hippocampal abnormalities in patients with PTSD, anxiety, and depressive disorders, as a reduced hippocampal volume has been found in maltreated individuals regardless of psychopathology. In addition to structural differences, abnormalities in resting-state functional connectivity (RSFC) of the hippocampus have been found in individuals with childhood adversity (Philip et al., 2013) and in a variety of neuropsychiatric disorders known to be related to childhood adversity, such as PTSD (Tursich et al., 2015), depression, and anxiety (Veer et al., 2010). More specifically, individuals who have experienced childhood adversity with or without psychopathology show aberrant resting-state connectivity between the amygdala and frontal regions (for a review, see Teicher, Samson, Anderson, & Ohashi, 2016; Teicher & Samson, 2016). However, there is a lack of research examining the role of attachment in structural and functional brain abnormalities in adolescents with psychopathology, possibly because simultaneous assessment of psychopathology and attachment representations in adolescents is scarce (Van Hoof, van Lang, Speekenbrink, van IJzendoorn, & Vermeiren, 2015).

Attachment is best described as the innate system that motivates humans to develop an affective bond with a protective caregiver as a secure haven and a safe base to explore the environment (Bowlby, 1969). Caregiver protection against dangers and stresses along with stimulation of exploration shape the child's emotion regulation and the ability to build trusting relationships with others (Cassidy, 2016). According to attachment theory, interactions with attachment figures in childhood develop into inner-working models of the self and others (Bretherton & Munholland, 2016). Attachment in adolescents and adults can be assessed with the well-validated Adult Attachment Interview (AAI; Hesse, 2016; Main, Kaplan, & Cassidy, 1985), which asks respondents for current mental representations of childhood attachment experiences. In the case of adversity such as loss of an attachment figure or the experience of child abuse, attachment representations may be characterized as UD (Hesse, 2016; Lyons-Ruth & Jacobvitz, 2016), indicated by incoherent (i.e., disoriented and disorganized) speech in response to questions about losses or other potentially traumatic events, independent from assessed psychopathology. This UD representation is considered a transdiagnostic risk factor that may increase vulnerability to a range of psychiatric disorders. Indeed, the authors of a meta-analysis found UD attachment had a prevalence of 43% in combined clinical samples, with elevated rates of unresolved loss and trauma in all clinical groups (Bakermans-Kranenburg & van IJzendoorn, 2009).

Some studies point to an association between disorganized attachment and structural brain abnormalities. For example, maltreatment reported in the AAI was associated with smaller hippocampal volume in a study that used female adult twin pairs (Riem et al., 2015). Recently, Lyons-Ruth, Pechtel, Yoon, Anderson, and Teicher (2016) showed that both maternal and infant components of disorganized attachment interaction in infancy were associated with increased left amygdala volume later in adulthood in a sample of impoverished, highly stressed families. However, it is yet unknown whether attachment representation as assessed with the “gold standard” AAI (Hesse, 2016; Main et al., 1985) is associated with structural brain abnormalities. Moreover, whereas there is sparse literature on the association between attachment and brain morphology, studies on attachment representation and functional connectivity in the brain are lacking. Examining how UD attachment relates to brain structure and functional connectivity will extend previous neuroimaging research on childhood trauma as previous studies have assessed trauma retrospectively and have not examined whether or not it matters if the trauma has been resolved. Unresolved–disorganized attachment represents a current state of mind with respect to childhood attachment experiences. It is yet unknown how this current state relates to brain measures.

Although there is evidence that UD attachment increases vulnerability to psychopathology in general, it is unknown how unresolved trauma relates to the abnormalities in brain structure and function that are commonly found in patients

with psychopathology (Caspi et al., 2014; Lahey et al., 2017). In the current study, we therefore examined whether UD attachment is related to brain abnormalities across multiple psychiatric diagnoses. Thus, we applied a dimensional approach to examine gray matter and resting-state abnormalities related to UD attachment across different psychopathological conditions. Although traditionally psychiatric disorders have been viewed as categorical psychopathological conditions, recent research shows accumulating evidence for a dimensional approach of psychopathology and points to overarching features and transdiagnostic factors. This dimensional approach to the structure of psychopathology may explain high levels of comorbidity among mental disorders. However, clinical neuroscience has not kept pace with these advances (Zald & Lahey, 2017). Neuroimaging studies examining biomarkers for psychopathological conditions point to similar structural and functional brain abnormalities across psychopathological conditions (Zald & Lahey, 2017). These shared brain abnormalities may be explained by high levels of comorbidity or shared transdiagnostic risk factors, such as UD attachment.

Therefore, the aim of the present study was to investigate whether UD attachment representation is associated with gray matter volume (GMV) of the hippocampus and amygdala in a sample of adolescents, after adjusting for psychiatric symptomatology. We chose the hippocampus and amygdala as regions of interest based on previous studies showing abnormalities in these regions in individuals with experiences of childhood trauma. In addition, we examined whether brain regions that show structural alterations related to UD attachment are also associated with different functional resting state connectivity. In sum, we examined the neural correlates of unresolved loss or trauma as assessed using the AAI (Main et al., 1985). Our hypothesis was that UD attachment would be correlated with a smaller hippocampal volume and a larger amygdala (Brenning & Braet, 2013; Brown & Morey, 2012) and that brain structures associated with UD attachment would also show alterations in functional connectivity.

Method

Participants and Procedure

The current study involved 74 participants from the Emotional Pathways' Imaging Study in Clinical Adolescents (EPISCA, $N = 77$; Van Hoof et al., 2015). They were recruited according to specified inclusion and exclusion criteria (Van den Bulk et al., 2013; Van Hoof et al., 2015; see Supplemental Material) and available coded AAIs (Main et al., 1985). Dropout was due to anomalous magnetic resonance imaging (MRI) findings ($n = 2$), technical scanning problems, or poor imaging data quality ($n = 2$). Within this group, there were 21 adolescents with PTSD related to childhood sexual abuse (CSA), 28 adolescents with anxiety and/or depressive disorders (DEP), and 25 nonclinical adolescents (CNTR). All adolescents with experiences of CSA had PTSD. Some adolescents in the DEP

and CNTR group had been exposed to other types of trauma (see Supplemental Material) but not to CSA. Inclusion criteria for the CSA group were having experienced sexual abuse during their lifetime more than once by one or more perpetrators in- or outside the family, and being referred for treatment. See Van Hoof and colleagues (2015) for a detailed description. The sample was originally recruited based on whether they had experienced CSA, had an anxiety and/or depressive disorder, or had no clinical symptoms in order to be able to compare groups cross-sectionally (see Van den Bulk et al., 2013). In the current study, the CSA, DEP, and CNTR groups were analyzed together as the aim was to examine whether UD attachment was related to brain abnormalities across multiple psychiatric diagnoses.

Power analysis using G*power (linear multiple regression) showed that the power needed to examine effects of UD and the general psychopathology factor (GPF) on brain structure was met with an alpha value set to .05 and a power of .80, with an expected medium effect size $f = 0.15$ (Calem et al., 2017) and two predictors (UD and GPF), with a required sample size of 68.

The study sample comprised 63 females (85.1%), with 18 in the CSA group, 24 in the DEP group, and 21 in the CNTR group. Participants' mean age was 15.42 years ($SD = 1.67$, range: 12–20), and they had a total mean IQ of 103.28 ($SD = 8.89$, range: 81–119). Regarding cultural background, 1.4% of participants were Asian (CSA, $n = 1$), 93.2% were Caucasian (CSA, $n = 20$; DEP, $n = 25$; CNTR, $n = 24$), 1.4% were Surinamese (DEP, $n = 1$), and 2.7% were Latin-American (DEP, $n = 2$). Four adolescents (5.4%; $n = 2$ CSA and $n = 2$ DEP) reported stable selective serotonin reuptake inhibitor use ($n = 3$ fluoxetine, $n = 1$ sertraline). Puberty stage was assessed using the Pubertal Development Scale (PDS; Petersen, Crockett, Richards, & Boxer, 1988) according to the following categories: prepubertal (CSA, $n = 1$), midpubertal (CNTR, $n = 5$), late pubertal (CSA, $n = 7$; DEP, $n = 11$; CNTR, $n = 12$), postpubertal (CSA, $n = 10$; DEP, $n = 9$; CNTR, $n = 5$). Information about pubertal status was missing for 10 participants; for these participants, pubertal status was imputed using gender and age. Attachment and clinical characteristics of the original larger total sample (Van den Bulk et al., 2013; $N = 77$), not using imaging data, have been reported separately (Van Hoof et al., 2015).

Written informed assent and consent was obtained from all adolescents and their parents. Participants received financial compensation, including travel expenses. The medical ethics committee of the Leiden University Medical Center approved this study. After adolescents and their parents gave assent and consent to participate in the EPISCA study, they filled out questionnaires (usually at home), and were tested for IQ and interviewed for classification of any disorder, according to the fourth edition of the *Diagnostic and Statistical Manual of Mental Disorders (DSM-IV)*, as well as attachment representation at the clinic in separate appointments. Scanning was usually performed separate from the aforementioned diagnostics, depending on availability of the scanner.

Measures

Attachment. The AAI (Main et al., 1985; see Supplemental Material) is a clinician-administered semistructured interview, validated for adolescents, that takes approximately 1 hr to administer. The AAI asks interviewees what and how they think about their relationship with parents or other primary caregivers in their youth, how these experiences have influenced them, how their actual relationship with parents or other primary caregivers is, and whether there were any experiences of illness, separation, fear, trauma, or loss. Interviewees are asked to give specific examples to support each evaluation. The coherence of the narrative rather than its autobiographical content is of most importance.

After transcription and coding of the AAI according to the manual (Hesse, 2016) by a certified coder, an attachment representation classification can be given. In organized attachment representations, there is one coherent mental strategy regarding attachment figures, either secure–autonomous or insecure. In UD attachment representations, different mental strategies concerning attachment figures are used simultaneously or sequentially, often contradicting one another, which becomes apparent when coding the narrative. The AAI includes a dimensional subscale entitled Unresolved for Loss or Trauma; AAI narratives are assigned scores on this dimension between 1 and 9, with a score of 9 indicating verbal behavior with highly incoherent speech characteristics in the narrative around loss or trauma experiences. A scale score for Unresolved Loss or Trauma of 5.5 or above also renders an individual UD (see Supplemental Material).

General psychopathology factor. To control for the effects of psychopathology, we decided to use the GPF. The GPF represents the lesser-to-greater severity of psychopathology associated with negative emotionality (Tackett et al., 2013), compromised brain integrity (Caspi et al., 2014), lower IQ, higher levels of negative affectivity, and lower levels of effortful control shown in 1,954 children between 6 and 8 years of age from a birth cohort (Jaddoe et al., 2012; Neumann et al., 2016). The GPF shows a significant single nucleotide polymorphism (SNP) heritability of 38% ($SE = 0.16$), $p = .008$. The use of the GPF has also demonstrated validity in girls (Lahey et al., 2015) and in young adolescents (Patalay et al., 2015). In our sample, the GPF was estimated using parent and self-report measurements for behavioral and emotional problems in children and adolescents: the Youth Self Report (YSR; Achenbach, 1991a; Verhulst, Ende, & van der Koot, 1997), Child Behavior Checklist (CBCL; Achenbach, 1991b; Verhulst, Ende, & van der Koot, 1996), Revised Child Anxiety and Depression Scale (RCADS; Chorpita, Yim, Moffitt, Umemoto, & Francis, 2000; Oldehinkel, 2000), Trauma Symptom Checklist for Children (TSCC; Briere, 1996), Children's Depression Inventory (CDI; Kovačs, 1992), and Adolescent Dissociative Experiences Scale (A-DES; Armstrong, Putnam, Carlson, Libero, & Smith, 1997). Principal component analysis was performed

using these scales and appropriate subscales, and one component explaining 61.6% was extracted, all loadings $> .56$ (see Supplementary Table S3). Factor scores were calculated in order to estimate the GPF (Franke, 2016; Lahey et al., 2012; Lahey, Zald et al., 2017; Lahey, Krueger, Rathouz, Waldman, & Zald, 2017). See Supplemental Material for a detailed description of the questionnaires used to estimate the GPF.

Image data acquisition. Images were acquired on a Philips 3T MRI system (Philips Healthcare; Best, the Netherlands), equipped with a SENSE-8 head coil. Scanning took place at the Leiden University Medical Center. Prior to scanning, all participants were prepared for scanning by lying in a dummy scanner and hearing scanner sounds. For each participant, a sagittal 3-dimensional gradient-echo T1-weighted image was acquired (repetition time = 9.8 ms; echo time = 4.6 ms; flip angle = 8°; 140 sagittal slices; no slice gap; field of view = 256 × 256 mm; 1.17 × 1.17 × 1.2 mm voxels; duration = 4:56 min) as part of a larger, fixed imaging protocol. Resting-state functional MRI (fMRI) data were acquired, using T2*-weighted gradient-echo echo-planar imaging (160 whole-brain volumes; repetition time 2,200 ms; echo time 30 ms; flip angle 80°; 38 transverse slices; no slice gap; field of view 220 mm; in-plane voxel size 2.75 × 2.75 mm; slice thickness 2.72 mm; total duration of the resting-state run = 6 min). Participants were instructed to lie still with their eyes closed and not to fall asleep.

Data Analysis

Hippocampal and amygdala volumes. Volumes of the left and right hippocampus and amygdala were assessed using FMRIB's Integrated Registration and Segmentation Tool (FIRST; Patenaude, Smith, Kennedy, & Jenkinson, 2011), part of FSL FMRIB's Software Library (FMRIB, n.d.; Smith et al., 2004). Hippocampal volumes were extracted after affine registration to standard space and subcortical structure segmentation. Registrations and segmentations were visually inspected, and no errors were observed. After hippocampal volume extraction, the *fsstats* program was used to assess volumes of the left and right hippocampus and amygdala. Brain tissue volume, normalized for participant head size, was estimated with SIENAX (Smith, De Stefano, Jenkinson, & Matthews, 2001; Smith, 2002). Brain and skull images were extracted from the single whole-head input data (Jenkinson, Bannister, Brady, & Smith, 2002). The brain image was then affine-registered to MNI152 space (Jenkinson et al., 2002), after which tissue-type segmentation with partial volume estimation was carried out in order to calculate total brain volume, including separate estimates of volumes of gray matter, white matter, peripheral gray matter, and ventricular CSF (Zhang, Brady, & Smith, 2001). Volumes of the left and right hippocampus and amygdala and total brain volume (mm^3) were exported to SPSS.

First, four hierarchical regression analyses with left and right hippocampal volume and left and right amygdala volume were

performed with the GPF, sex, composite score age/pubertal status (see Supplemental Material), total IQ score, and whole-brain volume in Step 1, and unresolved loss or trauma (categorical UD vs. non-UD and unresolved continuous scale in two separate models) in Step 2. All participants were included in the UD versus non-UD comparison, and analyses were performed with the clinical groups combined, as the aim of the study was to apply a dimensional approach. In addition to age, pubertal status was also included because variance in pubertal status may be related to different brain structures than variance in age. A composite score for age and pubertal status was calculated to control for multicollinearity (Giedd et al., 2006). Statistics indicated no multicollinearity, largest variance inflation factor ≤ 1.20 , tolerance $> .83$. The four hierarchical regression analyses were repeated with the GPF as an additional covariate in the first step. Vertex analysis was performed using firstutils (Patenaude et al., 2011) in order to localize and visualize effects of unresolved status. Exploratory whole-brain VBM analyses were performed.

Functional connectivity. Contrasts of interest were the parameter estimates corresponding to the regressor of the region that was significantly related to unresolved loss and trauma (a subregion of the left hippocampus; see Figure 2), which represents functional connectivity with that region. Thus, the left hippocampus was used as the seed region. After transforming the mask to native space, the mean time series for each participant was extracted from the left hippocampus using *fslmeants*. The time series was then used as a regressor in the model. In addition, CSF, white matter, and the global signal (see Supplemental Material) were added as regressors to the model in order to reduce the influence of artifacts caused by physiological signal sources on the results (Fox & Raichle, 2007). The temporal derivative of each regressor was added to the model, which resulted in eight regressors in each model. Motion parameters were also added to the model. First-level analyses were performed in native space. These first-level contrast images and the corresponding variance images were transformed to standard space and submitted to second-level mixed-effects group whole-brain analyses. The positive and negative correlations between hippocampal connectivity and unresolved loss and trauma score were assessed as were the contrasts of (a) UD larger than non-UD and (b) UD smaller than non-UD. Thus, we contrasted UD with non-UD and applied a dimensional analysis of UD. We included the GPF, composite score for age and pubertal status, sex, and IQ as confound regressors in the model. The statistical images were corrected for multiple comparisons at the cluster level in FSL, with a cluster-forming threshold of $Z > 2.3$ and a cluster-corrected significance of $p < .050$ (Worsley, 2001). This threshold was chosen to balance Type I and Type II error, as has been recommended (Hopfinger, 2017; Slotnick, 2017). Harvard-Oxford cortical structural atlas was used to localize hippocampal connectivity.

Table 1

Psychiatric Symptom Scores for the Whole Sample, Measured With the Youth Self-Report, Child Behavior Checklist, Revised Child Anxiety and Depression Scale, Trauma Symptom Checklist for Children, Children's Depression Inventory, and Adolescent Dissociative Experiences Scale

Clinical Characteristic	<i>M</i>	<i>SD</i>	Range
Depression	12.84	9.17	0–40
Posttraumatic stress	34.13	22.72	0–98
Anxiety	25.88	14.96	0–70
Dissociation	1.44	1.42	0–6.37
Internalizing–youth report	18.78	11.13	0–44
Internalizing–parent report	13.60	9.68	0–42
Unresolved attachment	2.40	1.18	1–8

Results

Clinical Sample Characteristics

See Table 1 for the clinical sample characteristics. Based on the AAI (Cassidy, 2016), 36.5% of the adolescents in the sample were classified as secure (CNTR, $n = 13$; DEP, $n = 11$; CSA, $n = 3$), 41.9% as dismissive (CNTR, $n = 11$; DEP, $n = 1$; CSA, $n = 9$), and 21.6% as UD (CNTR, $n = 1$; DEP, $n = 6$; CSA, $n = 9$). Unresolved–disorganized attachment was found in 16 (21.6%) participants. Of these unresolved participants, six adolescents had anxiety and/or depressive disorders, and nine had CSA-related PTSD. See Supplementary Table S1 for psychopathology scores for the separate groups (CSA-PTSD, internalizing, control, and U vs. non-U).

Volumetric measurement of amygdala and hippocampus.

Hierarchical regression analyses showed a significant effect of UD versus non-UD on left hippocampal volume, $F(5, 68) = 3.94$, $p = .003$, $R^2 = .17$, but not on right hippocampal volume or on amygdala volume (left or right; see Supplementary Table S2). Hierarchical regression analyses were repeated with the GPF as an additional covariate. Again, there was a significant effect of the categorical UD versus non-UD on left hippocampal volume beyond psychopathology, $F(6, 67) = 3.37$, $p = .014$, $R^2 = .23$. Participants who were classified as UD showed a smaller left hippocampal volume ($M = 3,574.33$, $SD = 510.99$ for UD; $M = 3,921.81$, $SD = 344.29$ for non-UD). The effect of UD remained significant after excluding one control participant with UD status. Hierarchical regression analysis with the continuous variable unresolved for loss or trauma (U) as predictor did not show a significant effect of U on bilateral hippocampal volumes beyond psychopathology (see Table 2). No effect was found regarding UD versus non-UD on right hippocampal volume (see Table 2) or in the hierarchical regression analyses with the amygdala as the dependent variable (see Table 3). Vertex analysis to localize and visualize the effect of UD in specific subfields of the hippocampus did not reach conventional levels

Table 2

Results of Hierarchical Regression Analyses With Hippocampal Volume as the Dependent Variable, Adjusting for Sex, Age/Pubertal Status, Total IQ Score, General Psychopathology Factor (GPF) in Step 1 and Unresolved Loss or Trauma Status in Step 2

Variable	Left Hippocampus					Right Hippocampus				
	<i>B</i>	<i>SE</i>	β	<i>p</i>	ΔR^2	<i>B</i>	<i>SE</i>	β	<i>p</i>	ΔR^2
Step 1					.16*					.14
Sex	-195.73	132.21	-.17	.143		-277.48	140.85	-.23	.053	
Age–puberty ^a	-4.90	43.83	-.01	.911		9.87	46.70	.03	.833	
WBV	0.00	0.01	.00	.970		0.00	0.00	.10	.407	
TIQ	16.38	5.15	.36	.002		12.27	5.49	.25	.029	
GPF	19.99	47.76	.05	.677		-7.20	50.88	-.02	.888	
Step 2					.03					.03
UD vs. non-UD	-282.99	111.64	-.29	.014		-197.54	122.45	-.19	.111	
U continuous	-262.78	158.58	-.20	.102		-274.67	169.08	-.20	.109	

Note. WBV = whole-brain volume; TIQ = total intelligence quotient; UD = unresolved–disorganized attachment (categorical); U = unresolved loss or trauma (continuous).

^aComposite score of age and puberty status.

**p* < .05.

of statistical significance, *p* < .100, when corrected for multiple comparisons. The hippocampal region of interest is shown in Figure 1. An exploratory whole-brain analyses yielded no results.

Resting-State Functional Connectivity

Analyses of RSFC showed that unresolved loss or trauma was positively related to connectivity between the left hippocampus and the right middle temporal gyrus (MTG) and the lateral occipital cortex (LOC), cluster size = 654 voxels; peak *Z* = 3.55; MNI coordinates *x*, *y*, *z* (mm) = 40, -60, 10 (see Figure 2). In addition to the analysis with the dimensional measure of UD, we contrasted UD versus non-UD, but there was no significant

difference in hippocampal connectivity between the UD versus the non-UD group.

Discussion

The aim of this study was to investigate whether UD attachment representation as assessed with the AAI was associated with different volumes of hippocampus and amygdala as well as with related differential connectivity in hippocampus- or amygdala-based RSFC networks in adolescents with CSA-related PTSD, anxiety and/or depressive disorders, and those without psychiatric symptoms. As recent research shows accumulating evidence for a dimensional approach of psychopathology and points to overarching features and transdiagnostic

Table 3

Results of Hierarchical Regression Analyses With Amygdala Volume as the Dependent Variable, Adjusting for Sex, Age/Pubertal Status, Total IQ Score, and General Psychopathology Factor (GPF) in Step 1 and Unresolved Loss or Trauma Status in Step 2

Variable	Left Amygdala					Right Amygdala				
	<i>B</i>	<i>SE</i>	β	<i>p</i>	ΔR^2	<i>B</i>	<i>SE</i>	β	<i>p</i>	ΔR^2
Step 1					.07					.03
Sex	-131.26	70.93	-.23	.069		95.77	86.26	-.14	.271	
Age–puberty	27.32	23.52	.15	.249		14.67	28.60	.07	.610	
WBV	0.00	.00	.10	.412		0.00	0.00	-.80	.513	
TIQ	2.06	2.76	.09	.458		0.14	3.36	.01	.966	
GPF	6.83	25.62	.03	.790		11.87	31.16	.05	.704	
Step 2					.02					.03
UD vs. non-UD	79.68	61.94	-.16	.203		-109.89	75.06	-.18	.148	
U continuous	-6.78	86.80	-.01	.938	.00	39.08	105.46	-.05	.712	.00

Note. WBV = whole-brain volume; TIQ = total intelligence quotient; UD = unresolved–disorganized attachment (categorical); U = unresolved loss or trauma (continuous).

^aComposite score of age and puberty status.

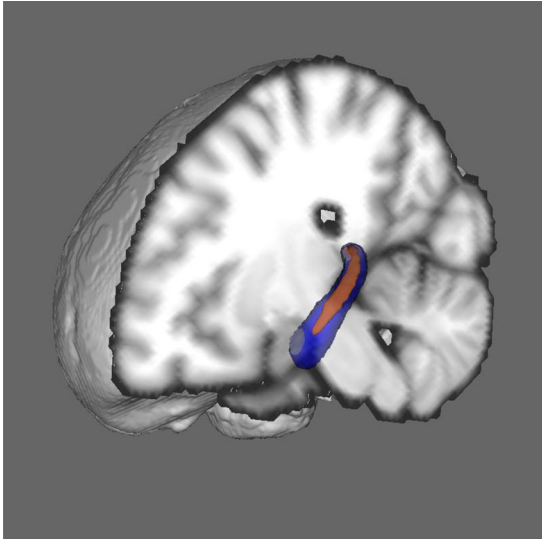


Figure 1. Red shading shows reduced hippocampal volume in adolescents with an unresolved-disorganized (UD) status compared to adolescents without a UD status, $p < .100$ (corrected for multiple comparisons). Blue shading shows study-specific mask of the left hippocampus.

factors, we applied a dimensional approach to examine gray matter and resting-state abnormalities related to UD attachment across different psychopathological conditions. Unresolved versus resolved group status was associated with a significantly smaller left hippocampal volume after adjusting for general psychopathology, puberty status, age, gender, and IQ. In addition, there was a positive correlation between UD attachment score and left hippocampal functional connectivity with the right MTG and LOC. No associations were found between UD attachment and right hippocampus or amygdala volumes.

Our findings are consistent with research showing that UD attachment is a transdiagnostic risk factor that increases vulnerability to psychopathology in general. Moreover, these findings indicate that hippocampal abnormalities previously found in patients with PTSD, depression, or anxiety disorders are not a specific biomarker for individual mental disorders but instead are common to several disorders and could be related to etiological factors rooted in childhood attachment experiences.

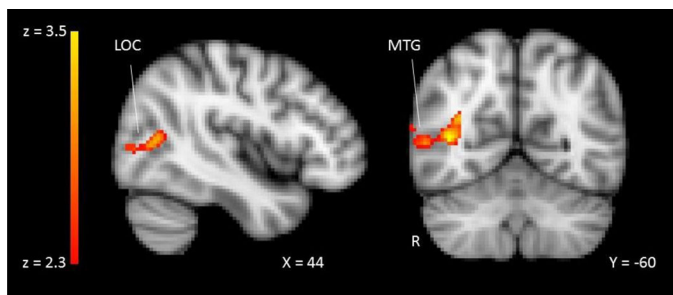


Figure 2. Results of the resting-state functional connectivity analysis. Unresolved loss and trauma are positively associated with connectivity between the left hippocampus and the middle temporal gyrus (MTG) and the lateral occipital cortex (LOC). Cluster thresholded $Z > 2.3$, $p < .050$.

The hippocampus is one of the most stress-sensitive structures in the brain as it modulates the HPA axis responsiveness to stress (Bernard, Lind, & Dozier, 2014). Early-life stress, such as child abuse and neglect, may reduce the number of hippocampal glucocorticoid receptors, prevent neurogenesis, and distort synaptic pruning (Sapolsky, Krey, & McEwan, 1985; Sapolsky, Uno, Rebert, & Finch, 1990). In response to stress, the hypothalamus releases corticotrophin-releasing hormone and arginine vasopressin. This leads to the secretion of adrenocorticotrophic hormone and increased cortisol release. When cortisol binds to glucocorticoid receptors in the hippocampus, hypothalamus, and the pituitary, inhibitory feedback is given, which returns the system to homeostasis (Koss & Gunnar, 2018). Damage to the hippocampus results in reduced glucocorticoid-mediated feedback control of the HPA axis, leading to hyper- or hyporesponsiveness to mild stressors (McCrory, De Brito, & Viding, 2011), which in turn may explain poor emotion regulation and increased risk for psychopathology in individuals with unresolved trauma.

We found smaller left hippocampal volume in the UD versus organized adolescent group. This finding is in line with previous findings showing a smaller left hippocampal volume in adults with experiences of maltreatment (Riem et al., 2015). Maltreatment-related PTSD in children, however, was not shown to be related to hippocampal volume in a meta-analytic study (Woon & Hedges, 2008); additionally, a study on the neurobiological effects of poor caregiving in orphanage-reared children did not demonstrate a smaller hippocampus (Tottenham et al., 2010). One explanation could be that the sexual and physical abuse reported in the current study took place from early childhood to adolescence, a developmental period that is most sensitive to the negative effects of maltreatment (Riem et al., 2015). Thus, the timing of the abuse may matter. Also, the reported abuse was often severe, cumulative, and protracted, and the treatment gap between the abuse and start of treatment was sometimes rather large (Van Hoof et al., 2015), all of which may have negatively impacted the hippocampal volume due to severe and prolonged stress. Moreover, neuroanatomic findings according to age in adolescents may already more closely resemble those in adults than in children. Another plausible explanation may be that UD attachment indeed constitutes a different concept than PTSD or maltreatment and shows different findings in relation to the brain when general psychopathology has been controlled for.

In addition, we found that UD attachment was related to the left hippocampus functional connectivity with the MTG and the LOC. In a meta-analysis, Sabatinelli and colleagues (Sabatinelli et al., 2011) found activation in both regions related to processing of emotional information. The LOC has been shown to be implicated in higher-level visual processing, including emotional scene perception, whereas the MTG seems to be associated with the processing of emotional faces, including faces provoking social aversion (Krause et al., 2016). However, enhanced connectivity among the hippocampus, MTG, and LOC was found during rest, which is surprising as

the MTG and LOC are not part of the limbic or default-mode network. Thus, our finding indicates that UD attachment is related to atypical hippocampal limbic or default-mode network connectivity. Future studies should investigate whether neural processing of emotions in individuals with UD attachment is due to their unresolved status or psychopathology, as altered MTG and LOC activity may also be associated with atypical processing of emotional stimuli of various kinds. Also, individuals with UD attachment may be more vulnerable to associate negative emotional stimuli with their current mental representation of traumatic sexual and/or physical experiences or past losses. The smaller hippocampal volume associated with unresolved loss or trauma may indicate a less-effective HPA-axis feedback loop (Gupta & Morley, 2014) leading to a lowered threshold for experiencing stress through perceptions or memories of loss or trauma.

Contrary to our hypothesis, we did not find an association between UD attachment and amygdala volumes. Our adolescent sample showed left hippocampal reduction but no (left) amygdala enlargement, as would have been in line with what was reported by Lyons-Ruth and colleagues (Lyons-Ruth et al., 2016), who found an association with both maternal and infant disorganization (but not child abuse per se), with larger left amygdala volume in adolescence in a sample of impoverished, highly stressed families. One explanation for the absence of the relation between unresolved status and amygdala volume in the current study is that acute threat and anxiety rather than childhood trauma could be related to amygdala enlargement. This is consistent with neuroimaging studies on affective disorders (Rinne-Albers et al., 2013; Van den Bulk, 2015) and suggested by normal development of hippocampus and amygdala (Tottenham & Sheridan, 2010).

A previous study that used the same sample but did not include the AAI showed that abnormal amygdalar connectivity related to diminished gray matter of the basolateral and centrolateral subnuclei in the amygdala was associated with psychopathology (Aghajani et al., 2016). In contrast, the current study removed variance associated with psychopathology; therefore, it makes sense that amygdala abnormalities were not detected. The unique contribution of UD attachment on top of this psychopathology seems only related to hippocampal volume and hippocampal functional connectivity with the MTG and LOC, which are involved in visual processing.

To the best of our knowledge, this was the first study to link adolescent attachment status to amygdala and hippocampal volumes and GMV in the adolescent brains of both clinical and nonclinical individuals. There are, however, some limitations to consider. The generalizability of results may be limited due to the fairly small sample size and the restricted ranges of age, IQ, gender, and ethnicity. Also, this is a cross-sectional study, so reversed causality can easily shape the interpretation of results, and definitive conclusions about cause and effects cannot be drawn. Finally, to be rendered UD on the AAI, one must have experienced (interpersonal) trauma or loss that is volunteered in responding to some loss- and trauma-related questions on

the AAI. Without such a trigger for narrative incoherence in the speech around loss or trauma, it is only possible to rate the individual on the continuous or categorical UD variable as showing the absence of unresolved status. In conclusion, our study suggests that across diagnoses, UD attachment is associated with structural and functional connectivity abnormalities of the hippocampus, a brain structure involved with regulation of the HPA axis, memory consolidation, and emotion regulation.

References

- Achenbach, T. M. (1991a). *Manual for the Youth Self-Report and 1991 profile*. Burlington, VT: University of Vermont, Department of Psychiatry.
- Achenbach, T. M. (1991b). *Manual for the Child Behavior Checklist/4–18 and 1991 profile*. Burlington, VT: University of Vermont, Department of Psychiatry.
- Aghajani, M., Veer, I. M., Van Hoof, M. J., Rombouts, S. A. R. B., Van der Wee, N. J. A., & Vermeiren, R. R. J. M. (2016). Abnormal functional architecture of amygdala-centered networks in adolescent posttraumatic stress disorder. *Human Brain Mapping, 37*, 1120–1135. <https://doi.org/10.1002/hbm.23093>
- Anda, R. F., Felitti, V. J., Bremner, J. D., Walker, J. D., Whitfield, C., Perry, B. D., . . . Giles, W. H. (2006). The enduring effects of abuse and related adverse experiences in childhood. *European Archives of Psychiatry and Clinical Neuroscience, 256*, 174–186. <https://doi.org/10.1007/s00406-005-0624-4>
- Armstrong, J. G., Putnam, F. W., Carlson, E. B., Libero, D. Z., & Smith, S. R. (1997). Development and validation of a measure of adolescent dissociation: The Adolescent Dissociative Experiences Scale. *The Journal of Nervous and Mental Disease, 185*, 491–497. <https://doi.org/10.1097/00005053-199708000-00003>
- Bakermans-Kranenburg, M. J., & van IJzendoorn, M. H. (2009). The first 10,000 Adult attachment interviews: Distributions of adult attachment representations in clinical and non-clinical groups. *Attachment and Human Development, 11*, 223–263. <https://doi.org/10.1080/14616730902814762>
- Bernard, K., Lind, T., & Dozier, M. (2014). Neurobiological consequences of neglect and abuse. In J. E. Korbin, & K. D. Krugman (Eds.), *Handbook of child maltreatment: Contemporary issues in research and policy* (pp. 205–223). Dordrecht, the Netherlands: Springer.
- Bowlby, J. (1969). *Attachment and loss, vol. I. Attachment*. London, United Kingdom: Hogarth Press.
- Bowlby, J. (1980). *Attachment and loss, vol. III. Loss*. New York, NY: Basic Books.
- Brenning, K. M., & Braet, C. (2013). The emotion regulation model of attachment: An emotion-specific approach. *Personal Relationships, 20*, 107–123. <https://doi.org/10.1111/j.1475-6811.2012.01399.x>
- Bretherton, I., & Munholland, K. A. (2016). The internal working model construct in light of contemporary neuroimaging research. In J. Cassidy & P. R. Shaver (Eds.), *Handbook of attachment: Theory, research, and clinical application* (3rd ed.; pp. 63–88). New York, NY: The Guilford Press.
- Briere, J. (1996). *Trauma Symptom Checklist for Children (TSCC) professional manual*. Odessa, FL: Psychological Assessment Resources.
- Brown, V. M., & Morey, R. A. (2012). Neural systems for cognitive and emotional processing in posttraumatic stress disorder. *Frontiers in Psychology, 3*(449), 1–14. <https://doi.org/10.3389/fpsyg.2012.00449>
- Calem, M., Bromis, K., McGuire, P., Morgan, C., & Kempton, M. J. (2017). Meta-analysis of associations between childhood adversity and hippocampus and amygdala volume in non-clinical and general

- population samples. *Neuroimage: Clinical*, 14, 471–479. <https://doi.org/10.1016/j.nicl.2017.02.016>
- Caspi, A., Houts, R. M., Belsky, D. W., Goldman-Mellor, S. J., Harrington, H., Israel, S., . . . Moffitt, T. (2014). The *p* factor: One general psychopathology factor in the structure of psychiatric disorders? *Clinical Psychological Science*, 2, 119–137. <https://doi.org/10.1177/2167702613497473>
- Cassidy, J. (2016). The nature of the child's ties. In J. Cassidy & P. R. Shaver (Eds.), *Handbook of attachment: Theory, research, and clinical applications* (3rd ed.; pp. 3–24). New York, NY: The Guilford Press.
- Chen, A. C., & Etkin, A. (2013). Hippocampal network connectivity and activation differentiates post-traumatic stress disorder from generalized anxiety disorder. *Neuropsychopharmacology*, 38, 1889–1898. <https://doi.org/10.1038/npp.2013.122>
- Chorpita, B. F., Yim, L., Moffitt, C., Umemoto, L. A., & Francis, S. E. (2000). Assessment of symptoms of *DSM-IV* anxiety and depression in children: A revised child anxiety and depression scale. *Behavioral Research and Therapy*, 38, 835–855. [https://doi.org/10.1016/s0005-7967\(99\)00130-8](https://doi.org/10.1016/s0005-7967(99)00130-8)
- Cloitre, M., Stolbach, B. C., Herman, J. L., van der Kolk, B., Pynoos, R., Wang, J., & Petkova, E. (2009). A developmental approach to complex PTSD: Childhood and adult cumulative trauma as predictors of symptom complexity. *Journal of Traumatic Stress*, 22, 399–408. <https://doi.org/10.1002/jts.20444>
- DeBellis, M. D., Casey, B. J., Dahl, R. E., Birmaher, B., Williamson, D. E., Thomas, K. M., . . . Ryan, N. (2000). A pilot study of amygdala volumes in pediatric generalized anxiety disorder. *Biological Psychiatry*, 48, 51–57. [https://doi.org/10.1016/s0006-3223\(00\)00835-0](https://doi.org/10.1016/s0006-3223(00)00835-0)
- Felitti, V. J., Anda, R. F., Nordenberg, D., Williamson, D. F., Spitz, A. M., Edwards, V., . . . Marks, J. S. (1998). Relationship of childhood abuse and household dysfunction to many of the leading causes of death in adults: The Adverse Childhood Experiences (ACE) Study. *American Journal of Preventive Medicine*, 14, 245–258. <https://doi.org/10.1016/j.amepre.2019.04.001>
- fMRIB. (n. d.). *fMRIB software library* (Version 6.0). Retrieved from <https://fsl.fmrib.ox.ac.uk/fsl/fslwiki>
- Fox, M. D., & Raichle, M. E. (2007). Spontaneous fluctuations in brain activity observed with functional magnetic resonance imaging. *Nature Reviews Neuroscience*, 8, 700–711. <https://doi.org/10.1038/nrn2201>
- Franke, B. (2016). Heritability of a general psychopathology factor in the population: Potential implications for classification and treatment. *The Journal of the American Academy of Child & Adolescent Psychiatry*, 55, 1016–1017. <https://doi.org/10.1016/j.jaac.2016.10.003>
- Giedd, J. N., Clasen, L. S., Lenroot, R., Greenstein, D., Wallace, G. L., Ordaz, S., . . . Chrousos, G. P. (2006). Puberty-related influences on brain development. *Molecular Cell Endocrinology*, 254–255, 154–62. <https://doi.org/10.1016/j.mce.2006.04.016>
- Gospodarevskaya, E. (2013). Post-traumatic stress disorder and quality of life in sexually abused Australian children. *Journal Child Sexual Abuse* 22, 277–296. <https://doi.org/10.1080/10538712.2013.743953>
- Gupta, D., & Morley, J. E. (2014). Hypothalamic-pituitary adrenal (HPA) axis and aging. *Comprehensive Physiology*, 4, 1495–1510. <https://doi.org/10.1002/cphy.c130049>
- Hart, H., & Rubia, K. (2012). Neuroimaging of child abuse: A critical review. *Frontiers in Human Neuroscience*, 6(5), 1–24. <https://doi.org/10.3389/fnhum.2012.00052>
- Hesse, E. (2016). The Adult Attachment Interview: Protocol, method of analysis, and selected empirical studies: 1985–2015. In J. Cassidy & P. R. Shaver (Eds.), *Handbook of attachment research and clinical applications* (3rd ed.; pp. 553–597). New York, NY: The Guilford Press.
- Hesse, E., & Main, M. (2000). Disorganized infant, child, and adult attachment: Collapse in behavioral and attentional strategies. *Journal of the American Psychoanalytic Association*, 48, 1097–1127; discussion, 1175–1187. <https://doi.org/10.1177/00030651000480041101>
- Hopfinger, J. B. (2017). Replication and innovation versus a perfect “.05.” *Cognitive Neuroscience*, 8, 145–146. <https://doi.org/10.1080/17588928.2017.1297296>
- Jaddoe, V. W. V., van Duijn, C. M., Franco, O. H., van der Heijden, A. J., van IJzendoorn, M. H., de Jongste, J. C., . . . Hofman, A. (2012). The Generation R Study: Design and cohort update, 2012. *European Journal of Epidemiology*, 27, 739–756. <https://doi.org/10.1007/s10654-012-9735-1>
- Jenkinson, M., Bannister, P., Brady, M., & Smith, S. (2002). Improved optimization for the robust and accurate linear registration and motion correction of brain images. *NeuroImage*, 17, 825–841. <https://doi.org/10.1006/nimg.2002.1132>
- Koolschijn, C., Van IJzendoorn, M. H., Bakermans-Kranenburg, M. J., & Crone, E.A. (2013). Hippocampal volume and internalizing behavior problems in adolescence. *European Neuropsychopharmacology*, 23, 622–628. <https://doi.org/10.1016/j.euroneuro.2012.07.001>
- Koss, K. J., & Gunnar, M.R. (2018). Annual research review: Early adversity, the hypothalamic-pituitary-adrenocortical axis, and child psychopathology. *The Journal of Child Psychology and Psychiatry*, 59, 327–346. <https://doi.org/10.1111/jcpp.12784>
- Kovačs, M. (1992). *Children's Depression Inventory (CDI) manual*. New York, NY: Multi-Health Systems.
- Krause, A. L., Borchardt, V., Li, M., van Tol, M. -J., Demenescu, L. R., Strauss, B., . . . Walter, M. (2016). Dismissing attachment characteristics dynamically modulate brain networks subserving social aversion. *Frontiers in Human Neuroscience*, 10(77), 114. <https://doi.org/10.3389/fnhum.2016.00077>
- Lahey, B. B., Applegate, B., Hakes, J. K., Zald, D. H., Hariri, A. R., & Rathouz, P.J. (2012). Is there a general factor of prevalent psychopathology during adulthood? *Journal of Abnormal Psychology*, 121, 971–977. <https://doi.org/10.1037/a0028355>
- Lahey, B. B., Krueger, R. F., Rathouz, P. J., Waldman, I. D., & Zald, D. H. (2017b). A hierarchical causal taxonomy of psychopathology across the life span. *Psychology Bulletin*, 143, 142–186. <https://doi.org/10.1037/bul0000069>
- Lahey, B. B., Rathouz, P. J., Keenan, K., Stepp, S. D., Loeber, R., & Hipwell, A. E. (2015). Criterion validity of the general factor of psychopathology in a prospective study of girls. *The Journal of Child Psychology and Psychiatry* 56, 415–422. <https://doi.org/10.1111/jcpp.12300>
- Lahey, B. B., Zald, D. H., Perkins, S. F., Villalta-Gil, V., Werts, K. B., Van Hulle, C. A., . . . Waldman, I. D. (2017). Measuring the hierarchical general factor model of psychopathology in young adults. *International Journal of Methods in Psychiatry Research*, e1593, 1–9. <https://doi.org/10.1002/mp.1593>
- Lyons-Ruth, K., & Jacobvitz, D. (2016). Attachment disorganization from infancy to adulthood: Neurobiological correlates, parenting contexts, and pathways to disorder. In J. Cassidy & P. R. Shaver (Eds.), *Handbook of attachment: Theory, research, and clinical applications* (3rd ed.; pp. 667–695). New York, NY: The Guilford Press.
- Lyons-Ruth, K., Pechtel, P., Yoon, S. A., Anderson, C. M., & Teicher, M. (2016). Disorganized attachment in infancy predicts greater amygdala volume in adulthood. *Behavioral Brain Research*, 308, 83–93. <https://doi.org/10.1016/j.bbr.2016.03.050>
- MacMillan, S., Szeszko, P. R., Moore, G. J., Madden, R., Lorch, E., Ivey, J., Rosenberg, D. R. (2003). Increased amygdala: Hippocampal volume ratios associated with severity of anxiety in pediatric major depression. *Journal of Child and Adolescent Psychopharmacology*, 13, 65–73. <https://doi.org/10.1089/104454603321666207>

- Main, M., Kaplan, N., & Cassidy, J. (1985). Security in infancy, childhood and adulthood: A move to the level of representation. In I. Bretherton & E. Waters (Eds.), *Growing points in attachment theory and research: Monographs of the Society for Research in Child Development* (Vol. 50, pp. 66–106). Chicago, IL: University of Chicago Press.
- McCrory, E., De Brito, S. A., & Viding, E. (2011). The impact of childhood maltreatment: A review of neurobiological and genetic factors. *Frontiers in Psychiatry*, 2, 48. <https://doi.org/10.3389/fpsy.2011.00048>
- McLaughlin, K. A., Sheridan, M. A., & Lambert, H. K. (2014). Childhood adversity and neural development: Deprivation and threat as distinct dimensions of early experience. *Neuroscience & Biobehavioral Reviews Journal*, 47, 578–591. <https://doi.org/10.1016/j.neubiorev.2014.10.012>
- Neumann, A., Pappa, I., Lahey, B. B., Verhulst, F. C., Medina-Gomez, C., Jaddoe, V. W., . . . Tiemeier, H. (2016). Single nucleotide polymorphism heritability of a general psychopathology factor in children. *The Journal of the American Academy of Child and Adolescent Psychiatry*, 55, 1038–1045. <https://doi.org/10.1016/j.jaac.2016.09.498>
- Oldehinkel, A. J. (2000). *Nederlandstalige vertaling van de Revised Child Anxiety and Depression Scale (RCADS)*. [Dutch translation of the Revised Child Anxiety and Depression Scale (RCADS)] Groningen: the Netherlands.
- Patalay, P., Fonagy, P., Deighton, J., Belsky, J., Vostanis, P., & Wolpert, M. (2015). A general psychopathology factor in early adolescence. *British Journal of Psychiatry* 207, 15–22. <https://doi.org/10.1192/bjp.bp.114.149591>
- Patenaude, B., Smith, S. M., Kennedy, D., & Jenkinson, M. (2011). A Bayesian model of shape and appearance for subcortical brain. *NeuroImage* 56, 907–922. <https://doi.org/10.1016/j.neuroimage.2011.02.046>
- Pechtel, P., Lyons-Ruth, K., Anderson, C. M., & Teicher, M. H. (2014). Sensitive periods of amygdala development: The role of maltreatment in preadolescence. *NeuroImage*, 97, 236–244. <https://doi.org/10.1016/j.neuroimage.2014.04.025>
- Petersen, A. C., Crockett, L., Richards, M., & Boxer, A. (1988). A self-report measure of pubertal status: Reliability, validity and initial norms. *Journal of Youth Adolescence* 17, 117–133. <https://doi.org/10.1007/bf01537962>
- Philip, N. S., Sweet, L. H., Tyrka, A. R., Price, L. H., Bloom, R. F., & Carpenter, L. L. (2013). Decreased default network connectivity is associated with early life stress in medication-free healthy adults. *European Neuropsychopharmacology* 23, 24–32. <https://doi.org/10.1016/j.euroneuro.2012.10.008>
- Riem, M. M. E., Alink, L. R. A., Out, D., Van IJzendoorn, M. H., & Bakermans-Kranenburg, M. J. (2015). Beating the brain about abuse: Empirical and meta-analytic studies of the association between maltreatment and hippocampal volume across childhood and adolescence. *Developmental Psychopathology*, 27, 507–520. <https://doi.org/10.1017/S095457941500>
- Rinne-Albers, M. A. W., Van der Wee, N. J. A., Lamers-Winkelmann, F., & Vermeiren, R. R. J. M. (2013). Neuroimaging in children, adolescents, and young adults with psychological trauma. *European Child and Adolescent Psychiatry*, 22, 745–755. <https://doi.org/10.1007/s0078701304101>
- Sabatinelli, D., Fortune, E. E., Li, Q., Siddiqui, A., Krafft, C., Oliver, W. T., . . . Jeffries, J. (2011). Emotional perception: Meta-analyses of face and natural scene processing. *NeuroImage*, 54, 2524–2533. <https://doi.org/10.1016/j.neuroimage.2010.10.011>
- Sapolsky, R. M., Krey, L. C., & McEwen, B. S. (1985). Prolonged glucocorticoid exposure reduces hippocampal neuron number: Implications for aging. *Journal of Neuroscience* 5, 1222–1227. <https://doi.org/10.1523/jneurosci.05-05-01222.1985>
- Sapolsky, R. M., Uno, H., Rebert, C. S., & Finch, C. E. (1990). Hippocampal damage associated with prolonged glucocorticoid exposure in primates. *Journal of Neuroscience*, 10, 2897–2902. <https://doi.org/10.1523/jneurosci.10-09-02897.1990>
- Schmaal, L., Veltman, D. J., van Erp, T. G. M., Samann, P. G., Frodl, T., Jahanshad, N., . . . Hibar, D. P. (2016). Subcortical brain alterations in major depressive disorder: Findings from the ENIGMA Major Depressive Disorder working group. *Molecular Psychiatry*, 21, 806–812. <https://doi.org/10.1038/mp.2015.69>
- Slotnick, S. D. (2017). Cluster success: fMRI inferences for spatial extent have acceptable false-positive rates. *Cognitive Neuroscience*, 8, 150–155. <https://doi.org/10.1080/17588928.2017.1319350>
- Smith, S. M. (2002). Fast robust automated brain extraction. *Human Brain Mapping*, 17, 143–155. <https://doi.org/10.1002/hbm.10062>
- Smith, S. M., De Stefano, N., Jenkinson, M., & Matthews, P. M. (2001). Normalized accurate measurement of longitudinal brain change. *Journal of Computer Assisted Tomography*, 25, 466–475. <https://doi.org/10.1097/00004728-200105000-00022>
- Smith, S. M., Jenkinson, M., Woolrich, M. W., Beckman, C. F., Behrens, T. E. J., Johansen-Berg, H., . . . Matthews, P. M. (2004). Advances in functional and structural MR image analysis and implementation as FSL. *NeuroImage*, 23, S208–S219. <https://doi.org/10.1016/j.neuroimage.2004.07.051>
- Tackett, J. L., Lahey, B. B., van Hulle, C., Waldman, I., Krueger, R. F., & Rathouz, P. J. (2013). Common genetic influences on negative emotionality and a general psychopathology factor in childhood and adolescence. *Journal of Abnormal Psychology*, 122, 1142–1153. <https://doi.org/10.1037/a0034151>
- Teicher, M. H., & Samson, J. A. (2016). Annual research review: Enduring neurobiological effects of childhood abuse and neglect. *Journal of Child Psychology and Psychiatry*, 57, 241–266. <https://doi.org/10.1111/jcpp.12507>
- Teicher, M. H., Samson, J. A., Anderson, C. M., & Ohashi, K. (2016). The effects of childhood maltreatment on brain structure, function and connectivity. *Nature Reviews Neuroscience*, 17, 652–666. <https://doi.org/10.1038/nrn.2016.111>
- Tottenham, N., Hare, T. A., Quinn, B. T., McCarry, T. W., Nurse, M., Gilhooly, T., . . . Casey, B. J. (2010). Prolonged institutional rearing is associated with atypically large amygdala volume and difficulties in emotion regulation. *Developmental Science*, 13, 46–61. <https://doi.org/10.1111/j.1467-7687.2009.00852.x>
- Tottenham, N., & Sheridan, M. A. (2010). A review of adversity, the amygdala and the hippocampus: A consideration of developmental timing. *Frontiers in Human Neuroscience*, 3, 68. <https://doi.org/10.3389/fpsy.2009.0068.2009>
- Tursich, M., Ros, T., Frewen, P. A., Klutsch, R. C., Calhoun, V. D., & Lanius, R. A. (2015). Distinct intrinsic network connectivity patterns of post-traumatic stress disorder symptom clusters. *Acta Psychiatrica Scandinavica*, 132, 29–38. <https://doi.org/10.1111/acps.12387>
- Van den Bulk, B. G. (2015). *The affective amygdala: Towards a better understanding of adolescent depressive and anxiety disorders (Unpublished doctoral dissertation)*. Leiden University, Leiden, the Netherlands.
- Van den Bulk, B. G., Koolschijn, P. C. M. P., Meens, P. H. F., Van Lang, N. D. J., Van der Wee, N. J. A., Rombouts, S. A. R. B., . . . Crone, E. A. (2013). How stable is activation in the amygdala and prefrontal cortex in adolescence? A study of emotional face processing across three measurements. *Developmental Cognitive Neuroscience*, 4, 65–76. <https://doi.org/10.1016/j.dcn.2012.09.005>
- Van Hoof, M. J., Van Lang, N. D. J., Speekenbrink, S., Van IJzendoorn, M. H., & Vermeiren, R. R. J. M. (2015). Adult Attachment Interview differentiates adolescents with childhood sexual abuse from those with clinical depression and non-clinical controls. *Attachment & Human Development*, 17, 354–375. <https://doi.org/10.1080/14616734.2015.105042>
- Veer, I. M., Beckmann, C. F., Van Tol, M. J., Ferraini, L., Milles, J., Veltman, D. J., . . . Rombouts, S. A. R. B. (2010). Whole brain resting-state analysis

- reveals decreased functional connectivity in major depression. *Frontiers in Systems Neuroscience*, 4, 1–10. <https://doi.org/10.3389/fnsys.2010.00041>
- Verhulst, F. C., Ende, J., & van der Koot, J. M. (1996). *Handleiding voor de CBCL/4-18 [Manual for the CBCL/4-18]*. Rotterdam, the Netherlands: Department of Child and Adolescent Psychiatry, Sophia Children's Hospital/Erasmus University.
- Verhulst, F. C., Ende, J., & van der Koot, H. M. (1997). *Handleiding voor de Youth Self-Report (YSR)*. [Manual for the Youth Self-Report (YSR)]. Rotterdam, the Netherlands: Department of Child and Adolescent Psychiatry, Sophia Children's Hospital/Erasmus University.
- Woon, F. L., & Hedges, D.W. (2008). Hippocampal and amygdala volumes in children and adults with childhood maltreatment-related posttraumatic stress disorder: A meta-analysis. *Hippocampus*, 18, 729–736. <https://doi.org/10.1002/hipo.20437>
- Worsley, K. J. (2001). Statistical analysis of activation images. In P. Jezzard, P. M. Matthews, & S. M. Smith (Eds.), *Functional MRI: An introduction to methods* (pp. 251–270). New York, NY: Oxford University Press.
- Zald, D. H., & Lahey, B. B. (2017). Implications of the hierarchical structure of psychopathology for psychiatric neuroimaging. *Biological Psychiatry*, 2, 310–317. <https://doi.org/10.1016/j.bpsc.2017.02.003>
- Zhang, Y., Brady, M., & Smith, S. (2001). Segmentation of brain MR images through a hidden Markov random field model and the expectation-maximization algorithm. *IEEE Transactions on Medical Imaging*, 20, 45–57. <https://doi.org/10.1109/42.906424>