

Neth Heart J (2020) 28:51
<https://doi.org/10.1007/s12471-019-01320-0>



Lead detour

L. M. van den Broek · S. W. Westra · R. Evertz · M. Boulaksil 

Published online: 12 August 2019
 © The Author(s) 2019

A 48-year-old male was brought to our Emergency Department after a car accident due to syncope. His medical history included paroxysmal atrial fibrillation and a bicuspid aortic valve requiring aortic valve replacement with a mechanical prosthesis. At presentation, the electrocardiogram showed a new third-degree atrioventricular block. It was decided to implant a dual-chamber pacemaker, but the procedure was more challenging than expected. Fig. 1 shows the position of the leads at the end of the procedure. What is your diagnosis?

Answer

You will find the answer elsewhere in this issue.

Conflict of interest L.M. van den Broek, S.W. Westra, R. Evertz and M. Boulaksil declare that they have no competing interests.

Open Access This article is distributed under the terms of the Creative Commons Attribution 4.0 International License (<http://creativecommons.org/licenses/by/4.0/>), which permits unrestricted use, distribution, and reproduction in any medium, provided you give appropriate credit to the original author(s) and the source, provide a link to the Creative Commons license, and indicate if changes were made.

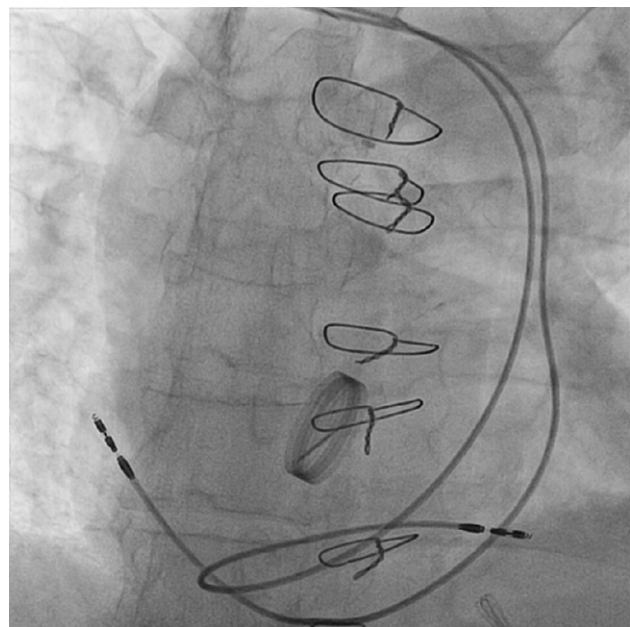


Fig. 1 Radiograph showing final lead position in our patient

L. M. van den Broek · S. W. Westra · R. Evertz ·
 M. Boulaksil (✉)
 Department of Cardiology, Radboud University Medical
 Centre, Nijmegen, The Netherlands
 m.boulaksil@gmail.com