



Single Case Report

The black box of global aphasia: Neuroanatomical underpinnings of remission from acute global aphasia with preserved inner language function



Joanna Sierpowska ^{a,b,c,d,*}, Patricia León-Cabrera ^{c,d}, Àngels Camins ^e,
 Montserrat Juncadella ^f, Andreu Gabarrós ^g and
 Antoni Rodríguez-Fornells ^{c,d,h}

^a Radboud University, Donders Institute for Brain, Cognition and Behaviour, Nijmegen, The Netherlands

^b Radboud University Medical Center, Donders Institute for Brain Cognition and Behaviour, Department of Medical Psychology, Nijmegen, The Netherlands

^c Cognition and Brain Plasticity Group [Bellvitge Biomedical Research Institute – IDIBELL], Barcelona, Spain

^d Dept. of Cognition, Development and Educational Psychology, Campus Bellvitge, University of Barcelona, Barcelona, Spain

^e Institut de Diagnòstic per la Imatge, Centre Bellvitge, Hospital Universitari de Bellvitge, Barcelona, Spain

^f ENTIA, Fundació de Neurorehabilitació i Recerca Cognitiva, Barcelona, Spain

^g Hospital Universitari de Bellvitge (HUB), Neurosurgery Section, Campus Bellvitge, University of Barcelona – IDIBELL, Barcelona, Spain

^h Catalan Institution for Research and Advanced Studies, ICREA, Barcelona, Spain

ARTICLE INFO

Article history:

Received 10 December 2019

Reviewed 12 February 2020

Revised 11 April 2020

Accepted 16 June 2020

Action editor Roberto Cubelli

Published online 3 July 2020

Keywords:

Global aphasia

Inner speech

ABSTRACT

Objective: We studied an unusual case of global aphasia (GA) occurring after brain tumor removal and remitting one-month after surgery. After recovering, the patient reported on her experience during the episode, which suggested a partial preservation of language abilities (such as semantic processing) and the presence of inner speech (IS) despite a failure in overt speech production. Thus, we explored the role of IS and preserved language functions in the acute phase and investigated the neuroanatomical underpinnings of this severe breakdown in language processing.

Method: A neuropsychological and language assessment tapping into language production, comprehension, attention and working memory was carried out both before and three months after surgery. In the acute stage a simplified protocol was tailored to assess the limited language abilities and further explore patient's performance on different semantic tasks. The neuroanatomical dimension of these abrupt changes was provided by perioperative structural neuroimaging.

Results: Language and neuropsychological performance were normal/close to normal both before and three months after surgery. In the acute stage, the patient presented severe difficulties with comprehension, production and repetition, whereas she was able to correctly perform tasks that requested conceptual analysis and non-verbal operations.

* Corresponding author. Radboud University, Donders Centre for Cognition, Radboud University Medical Center, Department of Medical Psychology, Montessorilaan 3, Room 02.26, P.O. Box 9104, 6500 HE, Nijmegen, The Netherlands.

E-mail address: j.sierpowska@donders.ru.nl (J. Sierpowska).

<https://doi.org/10.1016/j.cortex.2020.06.009>

0010-9452/© 2020 The Author(s). Published by Elsevier Ltd. This is an open access article under the CC BY license (<http://creativecommons.org/licenses/by/4.0/>).

After recovering, the patient reported that she had been able to internally formulate her thoughts despite her overt phonological errors during the episode. Structural neuroimaging revealed that an extra-axial blood collection affected the middle frontal areas during the acute stage and that the white matter circuitry was left-lateralized before surgery.

Conclusions: We deemed that the global aphasia episode was produced by a combination of the post-operative extra-axial blood collection directly impacting left middle frontal areas and a left-lateralization of the arcuate and/or uncinated fasciculi before surgery. Additionally, we advocate for a comprehensive evaluation of linguistic function that includes the assessment of IS and non-expressive language functions in similar cases.

© 2020 The Author(s). Published by Elsevier Ltd. This is an open access article under the CC BY license (<http://creativecommons.org/licenses/by/4.0/>).

1. Introduction

I have thoughts that I can't manage to translate into sounds.

Martino Sclavi in his book *The Finch in My Brain* about post-neurosurgical recovery (Sclavi, 2017).

Global aphasia (GA) is the most severe form of aphasia, affecting virtually all facets of language production and comprehension. The prognosis of language recovery is usually poor in the affected patients. In some cases, this form of language impairment may evolve into a less severe (although still chronic) aphasic syndrome. Interestingly, it has been shown that, despite failures in overt speech production, individuals with milder forms of aphasia may have preserved inner speech (IS), defined as the subjective experience of speaking in one's head (IS, Fama, Hayward, Snider, Friedman, & Turkeltaub, 2017; Fama, Henderson, et al., 2019; Fama, Snider, et al., 2019). For instance, aphasic patients with anomia often frustratingly experience that they can “say or hear the correct words in their mind” despite failing to produce them out loud (Fama et al., 2017). Indeed, there is some evidence that IS and overt speech can dissociate in aphasia (Geva et al., 2011), indicating that the two are at least partially independent functions. Further, recent theoretical models assume that IS can have different levels of information specification, from full articulatory and phonological specification (concrete or expanded IS) to only semantics without specific formulation and articulation (abstract or condensed) (see Fernyhough, 2004; Geva et al., 2011; Geva and Fernyhough, 2019; Grandchamp et al., 2019). In this respect, we use the term to refer to the subjective experience of verbalizing in one's head, independent from overt speech that can vary from the experience of a voice percept with precise articulatory specification (expanded inner speech) to a conceptual message without articulatory specification (condensed inner speech, see Grandchamp et al., 2019; Loevenbruck et al., 2018).

The concept of IS has generated an intriguing and unresolved debate in linguistics. It is argued whether language and thought processes are functionally inseparable or not (Gleitman & Papafragou, 2005; Sokolov, 2012; Vygotsky, 1987). The “lingualism” theory suggests that there is no thought

without language (Sapir, 1941; Whorf, 1956; Wittgenstein, 1922, p. 196, see also Vicente & Martinez Manrique, 2011), whereas the “language of thought” stream proposes that language is inessential to private thought (Fodor, 1975; for a review; Hermer-Vazquez, Spelke, & Katsnelson, 1999, see also; Edwards, Ellams, & Thompson, 1976). According to the first theory, mental operations such as mental calculation per se are supported by IS (Hermer-Vazquez et al., 1999; Sokolov, 2012), whereas the other standpoint proposes that the brain may hold these processes separately (Basso, De Renzi, Faglioni, Scotti, & Spinnler, 1973; Hamsher et al., 1991). Recently, this controversy has been revived in the light of recent anatomo-functional observations. For example, results from voxel-lesion symptom mapping studies in patients and functional imaging studies (using fMRI) using linguistic and non-linguistic tasks in healthy participants have provided partial evidences in support of both views (Baldo et al., 2005; Fedorenko & Varley, 2016; Geva et al., 2011).

Evidence of whether individuals with GA preserve their IS ability is rather scarce (Bek, Blades, Siegal, & Varley, 2010). In order to address this gap of knowledge, we present an unusual case of an individual who presented GA in the first few days after brain tumor removal but maintained a good level of performance in tasks requiring conceptual analysis and non-verbal operations. Captivatingly, she fully recovered within the first month after surgery and could report on her subjective experience while dealing with GA, which suggested a preserved IS. We explored the neuroanatomical underpinnings that sustained her recovery from the GA episode and put them together with her objectively measured language performance and subjective reports, during and after the episode.

2. Method

2.1. Case presentation

TD, a 35 year old, right-handed woman, was admitted to the Neurosurgery Department of the Bellvitge Academic Hospital as a candidate for brain tumor resection (diffuse astrocytoma, WHO, II). TD was in a stable partnership in a city of moderate size and was a mother of two. She accomplished secondary school (10 years of formal education), being a Spanish speaker

with a high level of Catalan (qualifying as a Spanish–Catalan bilingual) and some knowledge of English. The study protocol was accepted by the Hospital Universitari of Bellvitge Ethical Committee in accordance with the principles of the Declaration of Helsinki and the participant signed the informed consent for the participation in the study. As this report is a case study, no part of the study procedures or analyses were pre-registered in a time-stamped, institutional registry prior to the research being conducted.

We report all data exclusions, all exclusion criteria, whether exclusion criteria were established prior to data analysis, and all measures in the study. All data reported formed part of standard medical care. In this sense, MRI, neuropsychological, and language perioperative testing was performed before surgery, intrasurgically and from 3 to 7 months after the surgical intervention. In terms of behavioral testing – given that this report concerns the acute post-surgical global aphasia episode, we included bedside assessment results as a centric point of our focus. Additionally, we added baseline and early recovery scores for comparison. With regard to the neuroimaging data, a standard medical care protocol included a set of anatomical and functional images, but, for this report, we included only the pre-surgical Diffusion and T1 weighted images, the T1-weighted and Fluid-Attenuated Inversion Recovery Sequence (FLAIR) during the acute post-surgical stage and an anatomical, T1 weighted image at 7 months post-surgery. We excluded the intrasurgical results from the present report. No exclusion criteria were established prior to data analysis, given that all the results were previously used for clinical purposes.

The conditions of our ethics approval do not permit public archiving of the data supporting this study, according to the corresponding ethics committee of our hospital (Comite Ètic d'Investigació Clínica, Bellvitge Hospital). Readers seeking access to this data should contact the lead author (JS). Access will be granted to named individuals in accordance with ethical procedures governing the reuse of sensitive data. Specifically, the person responsible of the research team should be willing to sign a document in which they commit to maintain confidentiality with regard to the shared dataset.

2.2. Neuropsychological and language assessment

The presurgical and post-surgical (3 months after surgery) neuropsychological and language assessment involved a preset collection of standardized tests used at the Neurology Ward of Hospital Universitari de Bellvitge for all brain surgery candidates. Following this, we measured: handedness (Edinburgh Inventory, Oldfield, 1971), verbal comprehension (Token Test, De Renzi and Faglioni, 1978), semantic (animals) and phonological (letter p) verbal fluency, attention and working memory (Digit Span from the WAIS – Wechsler Adult Intelligence Scale) (Wechsler, 1997) and naming (Boston Naming Task, Goodglass and Kaplan, 2001) and a home-made simplified version of the picture-naming task, composed by 60 black and white drawings selected from a standard stimuli database (Snodgrass & Vanderwart, 1980, see also: Havas et al., 2015). After establishing that TD was Spanish–Catalan bilingual, a handful of additional tasks was added allowing to test both languages intraoperatively, as well as her language

switching profile (Rodríguez-Fornells et al., 2012) and abilities (for more details on this task, please consult our previous work: Sierpowska et al., 2013, 2018). Spanish normative data for these tasks was obtained from the Neuronorma database by Peña-Casanova and collaborators (Peña-Casanova, 2005; Peña-Casanova, Quinones-Ubeda, Gramunt-Fombuena, Aguilar, et al., 2009; Aranciva et al., 2012; Casals-Coll et al., 2013) and from the Spanish adaptation of the Wechsler Memory scale III edition (Wechsler, 2004). In the acute post-surgical stage (4 days after surgery), the neuropsychologist team intended to evaluate TD using the same protocol. However, given the patient's unstable condition, the assessment was readapted to a more approachable form and also repeated three days later (7th day post-surgery, consult Table 1 for a more comprehensive overview). In this sense, an attempt to perform the Token test was undertaken showing a very poor performance and, thus, a sentence comprehension task was proposed as well (TBR – Test de Barcelona Revisado) (Peña-Casanova, 2005). In the task of repetition of words and non-words, non-words were substituted by syllables and syllable pairs to maximally simplify the stimuli set and in this way, make it more approachable to the patient. Automated series naming was measured by weekdays naming (spoken) and counting to ten (both spoken and written) (all tests included in the TBR) to test for automated speech output and to scan for possible language switching errors. Additionally, two semantic matching tasks were carried out: Pyramids and Palm Trees (PPT, Howard and Patterson, 1992) and Environmental Sound Recognition Task (Bozeat, Lambon Ralph, Patterson, Garrard, & Hodges, 2000). These latter tasks were useful to ensure if the hidden (semantic) facets of language processing are still preserved despite the breakdown in overt language production. Attention, short term and working memory were measured by a Symbol Search task (included in the WAIS) and Corsi Cubes. The Symbol Search (cancellation) task also allowed to rule out the possible appearance of hemineglect. With regard to motor function evaluation, measures of unilateral and bilateral posture sequences and imitation were implemented (see Table 1 for more details).

Legal copyright restrictions prevent public archiving of the test materials used in the study, which can be obtained from the copyright holders in the cited references.

2.3. Clinical neuroimaging data acquisition and analyses

Anatomical (T1-weighted and diffusion tensor) images were collected at the Hospital Universitari de Bellvitge before surgery allowing the presurgical damage assessment and support intraoperative neuronavigation. Given the delicate condition of TD in the acute post-surgical stage it was only possible to acquire a short protocol including T1 and Fluid Level Attenuation Imaging Resonance (FLAIR). Seven months after surgery, structural neuroimaging was acquired again for the post-surgical follow-up. In this report we show only the T1 weighted data. The scanner used was the Philips Intera 1.5-T system with a maximum field gradient strength of 76 mT/m. T1-weighted images were acquired using: slice thickness 1.1 mm, number of slices 150, TR 25 msec, TE 4.6 msec, flip angle 30°, matrix 320 × 320, FOV 240 mm, and voxel size .75 × .75 × 1.1 mm.

Table 1 – Language, cognitive and motor function assessment results at baseline (before surgery), in the acute post-surgical stage (4 days (D4) or 7 days (D7) after surgery) and during early recovery (3 months after surgery).

Function (test)	Baseline		Acute	Early recovery
Production/naming				
Boston naming test	ss = 10	n/s		ss = 10
Naming herself and her partner's by the first name	n/a	0/2 (D4)		n/a
Written naming				
■ Objects	n/a	1/2 (semantic paraphasia) (D4)		n/a
■ Body parts	n/a	4/4 (paragrammia) (D4)		n/a
Writing				
■ Automatic (weekdays)	n/a	Impaired, paragrammias (D4)		n/a
■ Copy	n/a	Preserved (D4)		n/a
Semantic matching				
Pyramids and palm trees	n/a	■ 49/52 (D7)		n/a
Sound-to-picture matching	n/a	■ 38/48 (D7)		n/a
Musical instruments – Sound-to-picture matching	n/a	■ 12/12 (D7)		n/a
Automated series				
Counting				
■ Catalan	■ 10/10	■ n/s		■ 10/10
■ Spanish	■ 10/10	■ Spoken: 3/10 (D4), ■ 4/10 (D7) Written: 7/16 (a considerable number of phonological and language switching errors) (D4)		■ 10/10
Months				
■ Catalan	■ 12/12	■ n/s		■ 11/12
■ Spanish	■ 12/12	■ n/s		■ 12/12
Weekdays				
■ Catalan	■ 7/7	■ n/s		■ 7/7
■ Spanish	■ 7/7	■ 0/7 (D4)		■ 7/7
Vowels				
Orophonatory praxis	n/a	■ A-E-U (D4 & D7) ■ 5/20 (D4); 10/20 (D7)		n/a
Repetition				
Non-words	8/8	n/s		8/8
Words	n/a	1/10 (D4)		n/a
Syllables	n/a	1/3 (D4); 1/8 (D7); 1/8 (D7)		n/a
Numbers	n/a	■ Spanish: 3/10 (D4) ■ Spanish: 4/10 (D7) (a considerable number of phonological errors, e.g., “tete” for “siete”)		n/a
Comprehension				
The token test	ss = 9	■ n/s (D4); ss = 2 (D7); rs = 20/36 ^a		ss = 7
Follow simple orders	n/a	■ 3/6 (D4); 3/6 (D7) (follows up to 3 instructions)		n/a
Follow complex orders	n/a	■ 4/8 (D4)		n/a
Verbal fluency				
■ Semantic (animals)	ss = 8	n/a		ss = 10
■ Phonological (p)	ss = 8	n/a		ss = 9
Attention and/or Short term memory				
Digit span forward	ss = 10	n/s		ss = 8
Symbol search ^b	n/a	30/30 (D4)		n/a
Visual span (Corsi cubes)	n/a	3/9 (D4); points up to 3 written digits in correct order		n/a
Working memory				
Digit span backward	ss = 8	n/s		ss = 7
Praxis				
■ Posture imitation	n/a	5/5 (D4)		n/a
■ Unilateral posture sequences	n/a	5/5 (Right), 4/5 (Left) (D4)		n/a
■ Bilateral reciprocal coordination	n/a	4/4 (D4)		n/a
■ The fist-edge-palm task	n/a	1/2 (Right), 1/2 (Left) (D4 & D7)		n/a
■ Tapping	n/a	2/2 (Right), 2/2 (Left) (D4 & D7)		n/a
■ Graphic alteration	n/a	2/2 (Right, dominant hand only) (D4)		n/a
■ Graphic loops	n/a	2/2 (Right, dominant hand only) (D4)		n/a

n/a, not assessed; n/s, not suitable given the person's condition and/or failed at start; ss, scalar score; rs, raw score.

^a Specific scores in the token test in the acute stage: part 1 (all tokens) 7/7, part 2 (big tokens) 4/4, part 3 (big and small tokens) 3.5/4, part 4 (only big tokens) 1.5/4, part 5 (big and small tokens) 0/4, part 6 (Only big tokens) 4/13.

^b Symbol search was implemented by crossing out circles from a set of shapes.

Diffusion weighted images (DWI) were obtained using a single-shot echo planar imaging sequence. Diffusion gradients were applied along 16 directions using a b-value of 0 and 800 sec/mm². The DWI sequences were acquired in the axial plane with 60 contiguous sections, a 2-mm section thickness (voxel size 1.63 × 1.63 × 2 mm), no intersection gap, TR 15,600 msec, TE 79 msec, FOV 170 × 234 mm², and matrix 84 × 117.

T1-weighted and FLAIR images allowed us to visualize the brain tumor and post-surgical edema/cavity location. DWI data allowed us to visualize 7 major language-related white matter tracts: the three segments of the arcuate fasciculus (AF; fronto-temporal, parieto-temporal and fronto-parietal connections), the inferior longitudinal fasciculus (ILF), the inferior fronto-occipital fasciculus (IFOF), the uncinate fasciculus (UF) and the frontal aslant tract (FAT). The tracts were visualized for both hemispheres and carried out according to the anatomical landmarks comprised in WM atlas (Catani and Thiebaut de Schotten, 2008), for more specific

details please consult the following previous reports (François et al., 2016; Sierpowska et al., 2015, 2017, 2019).

3. Results

3.1. Brain tumor location and major language-related white matter organization

The discrete brain lesion was located within the middle frontal gyrus (MFG) and subjacent white matter (see Fig. 1, left panel). Preoperatively, diffusion tensor imaging (DTI) analyses revealed that the major white tracts belonging to the ventral (IFOF, ILF and UF) and dorsal (AF) language processing systems were well-preserved within the left hemisphere. However, the same tracts organization in the right hemisphere showed that the fronto-temporal connection of the AF was missing (see Fig. 1), which can be classified as the most extreme type of left

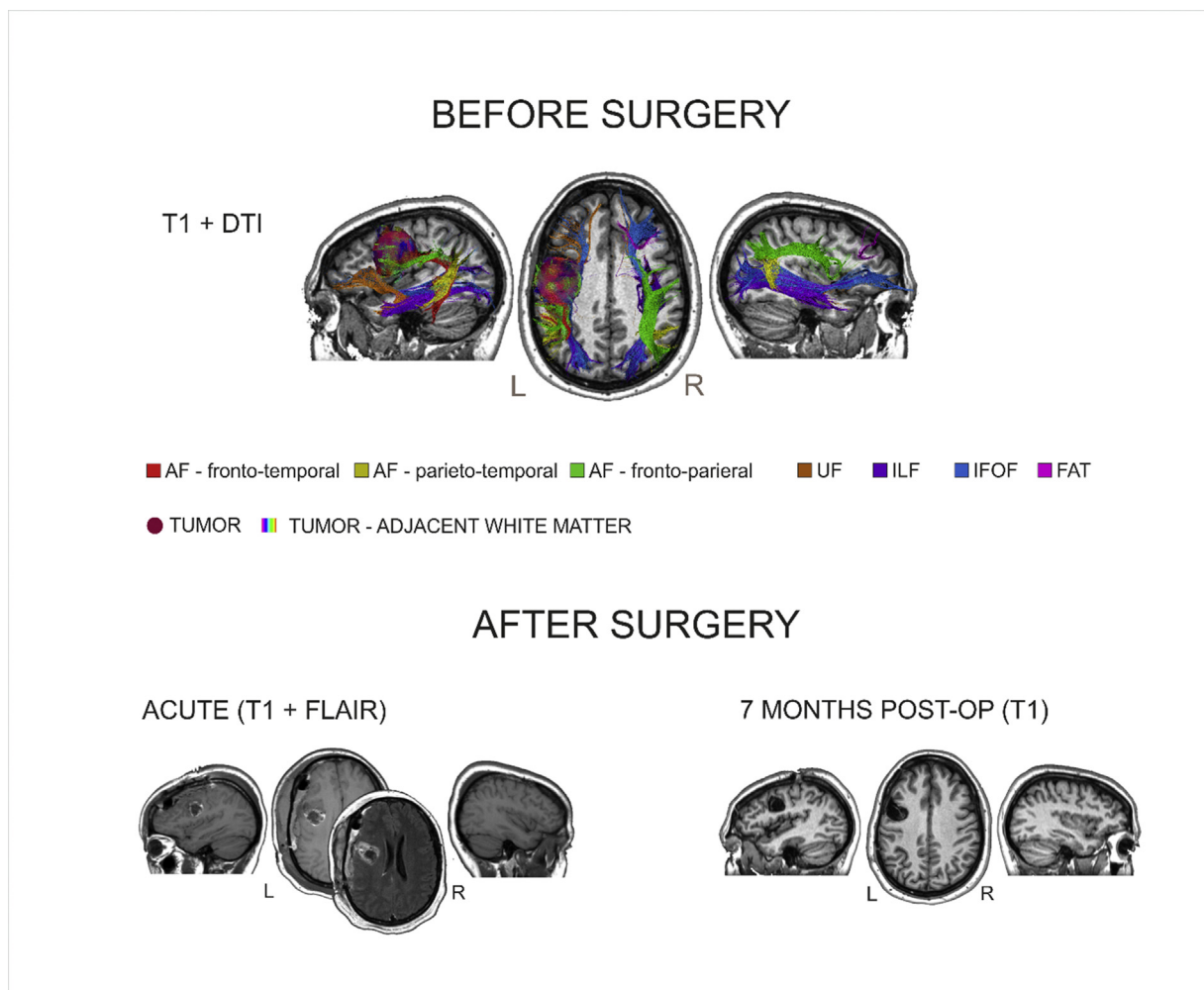


Fig. 1 – Lesion and postsurgical cavity anatomical location before and after surgery (both the acute and early recovery). Notice the white matter language-related tracts organization before surgery (upper section) and the presence of the pericavitary, subdural extra-axial blood collection in the acute stage of recovery (lower section, left panel), T1 = T1 – weighted structural image, DTI = Diffusion Tensor Imaging, FLAIR = Fluid-Attenuated Inversion Recovery Sequence, AF = arcuate fasciculus, UF = uncinate fasciculus, ILF = inferior longitudinal fasciculus, IFOF = inferior fronto-occipital fasciculus, FAT = frontal aslant tract.

lateralization of the AF (according to [Catani, Jones, & ffytche, 2005](#)). Also in the right hemisphere, the UF was only scarcely represented. The frontal aslant tract (FAT) was not found within the left hemisphere and was underrepresented on the right side.

3.2. Neuropsychological and language assessment before surgery

According to a fine-grained evaluation before surgery, TD scored within the normal range in naming, comprehension, short term memory, working memory and verbal fluency (see [Table 1](#)). She did not report any difficulties in sensory and motor functioning. Surgery itself was performed using brain mapping (sensory, motor, language naming and language switching) with precise intraoperative anatomical neuro-navigation. During the awake surgical phase, TD could successfully communicate with the team and showed a good performance in the intraoperative tasks.

3.3. Bedside neuropsychological and language assessments

Unexpectedly, in the bedside assessment 2 days after surgery, TD presented severe difficulties at virtually all levels of spoken communication: production, repetition, and comprehension, meeting the diagnostic criteria of GA ([Table 1](#)). Her speech difficulties at motor level were representative of both apraxia of speech and dysarthria and TD's attempts to communicate required a huge effort and eventually lead to frustration, which was both observed by the neuropsychologist as well as expressed by the patient after recovery (see the transcript of her testimony at the end of this section). However, the patient did not present signs of hemiparesis (see [Table 1](#) for motor function assessment scores and [Fig. 2](#) for an original image of TD's handwriting). During both the hospital stay and the first days at home, TD tried to communicate with her spouse through drawings and gap-fill exercises designed by him (see [Fig. 2](#)). Both of these home-made tasks revealed severe errors in phonological processing, such as phonological (phonemic) and neologistic paraphasias in writing and language-switching errors (see [Fig. 2A](#)). Structural neuroimaging revealed that in this acute, post-surgical phase, a portion of the left MFG was lesioned during tumor resection (see [Fig. 1](#), middle panel). Additionally, a subdural extra-axial blood collection temporarily affected a considerable part of the MFG – adjacent pericavarian areas (including white matter) and provoked a slight midline shift, which aggravated the patient's condition even after excision which was of a relatively small size. During the post-surgical recovery, TD was treated with corticosteroids (in line with our institution practice).

In the follow-up neuroimaging assessment (7 months after surgery), structural data confirmed the disappearance of the extra-axial blood collection and the midline shift ([Fig. 1](#), lower section, right panel). At the same time, TD successfully returned to a normal neuropsychological and language status ([Table 1](#)). Consequently, she reported on her subjective experience during the acute stage of GA. TD stated being aware that her family and medical team members were

constantly trying to communicate with her but that she could not understand them, corroborating a severe disruption in language comprehension (see also [Table 1](#), for her performance in the Token Task). She also reported that she was able to formulate thoughts and even to internally elaborate the messages she wanted to convey, but that she could not utter them. Importantly, TD was aware of her errors when she attempted to communicate, in her own words: *When I was writing and it was incorrect, I knew it was incorrect and that was when I was getting angry and I was saying to myself: I don't want to write anymore or to do anything else* (original transcript in Spanish: *Cuando escribía y lo escribía mal, yo sé que lo escribía mal y entonces es cuando me daba rabia y decía: no quiero escribir más ni nada ya*). A score of 49 out of 52 in the Pyramids and Palm Trees Test 7 days post-surgery confirmed her ability to correctly match appropriate pictorial representations, and thus access the semantic representations. The use of these tasks was particularly useful, since, in this way, we could assess semantic processing bypassing the difficulties in auditory comprehension and overt speech production. During the same acute GA episode, she was also able to successfully complete non-verbal exercises, such as completing simple sequences of symbols that follow a certain rule (triangle–circle–square, triangle–circle–square [Fig. 2B](#)).

4. Discussion and clinical relevance

This uncommon case of acute global aphasia shows a great potential of language functional recovery after surgery compromising the integrity of the left MFG vicinity. Moreover, it clearly supports that verbal and non-verbal tasks may be selectively affected by focal brain lesions, explores the limits of covert versus overt language production and opens new, alluring questions about the role of IS in GA. Visual inspection of the presurgical structural neuroimaging data showed that the left lateralization of the AF was among the most prominent features of the patient's brain structural organization. Given that it is highly likely that the acute post-operative pericavarian blood collection hindered the correct transfer of information with the left dorsal stream for language, we could assume that the right hemispheric analogs of the dorsal system were less aptly equipped to compensate for language impairments. In addition to the leftward AF lateralization, the frontal aslant tract (FAT) was scarcely present in both hemispheres. This could explain the motor component of TD speech difficulties, given the growing evidence on the involvement of the FAT in lexical selection, language planning, production and speech motor control ([Chernoff et al., 2018](#); [Dick, Garic, Graziano, & Tremblay, 2019](#); [Halai, Woollams, & Lambon Ralph, 2017](#); [Kemerdere et al., 2016](#); [Kinoshita et al., 2015](#); [Sierpowska et al., 2015](#)). On the other hand, the pathological switching instances, as appearing in the gap-fill exercises during the acute post-surgical phase, may be explained by the impact of the pericavarian blood collection on the left middle and inferior frontal areas. Pathological language switching was observed as an aftermath of a similar tumor resection involving this region, the left MFG (see [Sierpowska et al., 2013](#)). The present report nicely builds on the very recent study by [Finkl et al. \(2019\)](#) showing that core language-

utterances (also confirmed by the fact that TD was able to repeat Corsi cubes sequences and follow up simple instructions up to the point when these surpassed a critical level of complexity). This observation suggests that in similar cases, it would be beneficial to carry out a more thorough exploration of working memory and include a naming test, where patients can point to the image of a named object (e.g., from the Cambridge Semantic Battery, [Adlam, Patterson, Bozeat, & Hodges, 2010](#)) to assess comprehension at a single word level. Another useful addition could be a task for comprehension of simple sentences controlled for syntactic complexity.

Additionally, with regards to the dorsal processing system, a recent report by [Fama et al. \(2017\)](#) conveyed that dorsal stream lesions (as is most probably the case in the present study) correlate with a high proportion of subjectively-reported successful IS in patients with aphasia (see also [Geva et al., 2011](#), for similar, voxel-lesion symptom mapping results). Interestingly, several evidences suggest that TD might have had preserved IS during the acute stage of GA. Her good semantic matching results (PPT and Environmental sounds test) and attempts of response in informal gap-fill exercises and formal testing support at least partial preservation of lexical access and/or utterances that she intended to produce despite her phonological errors in formal testing (i.e., in writing and in repetition). The preservation of word retrieval despite articulatory output impairments has been thought to underlie the preservation of IS in other aphasic patients ([Fama et al., 2017](#)). Additionally, according to TD's reported subjective experience, she was able to internally elaborate conceptual messages.

An interesting point in support of potentially preserved IS in TD may also be provided by her awareness of the phonological errors, which we find particularly puzzling. Observing this, one might be prone to consider the preservation of error monitoring in language production in TD as an indirect proof of the existence of accurate internal representations (e.g., “the expected word or lexical output”) that are needed to detect the mismatch between the internal covert production (or writing output in this case) and the expected correct item. Most models in language production indeed assume the existence of mechanisms allowing for the self-monitoring of one's own speech production ([Dell, 1985](#); [Levitt, 1983, 1989](#); [Motley, Baars, & Camden, 1983](#); [Postma, 2000](#)). However, it is unclear to what extent feedforward models of error monitoring are required for successful IS ([Gallagher, 2004](#); [Jones & Fernyhough, 2007](#); [Möller, Jansma, Rodriguez-Fornells, & Münte, 2007](#); but see; [Whitford et al., 2017](#)). As an example, error awareness is possible without proper word retrieval, as it has been reported in tip-of-tongue language production states. Also relevant in this respect, [Fernyhough \(2004\)](#) suggested that IS can take different forms, varying from containing fully specified information (semantic, syntactic and phonological) to only semantics, which would imply that having an accurate phonological and/or articulatory representation is not a necessary condition for IS. Similarly, [Grandchamp et al. \(2019\)](#) recently proposed a neurocognitive model in which IS can vary along a condensation dimension, from condensed IS (without articulatory specification) to expanded IS (involving articulatory specification and the

perception of a voice percept), and argue that expanded forms of IS entail verbal monitoring through internal feedforward models. Altogether, it remains unclear to which extent the presence of error monitoring in TD could be indirectly speaking in favor of preserved IS.

With regards to the motor aspects of the postoperative neurological profile of TD's – it is worth noting that the global aphasia did not occur together with hemiparesis, which adds to a handful of similar reported cases (see: [Pai, Krishnan, Prashanth, & Rao, 2011](#), [Shindo et al., 2013](#); [Paik & Kim, 2014](#)). As an additional comment, it is worth considering that the errors in TD's handwriting (e.g., letter substitutions) might be attributed to the damage of the Exner's area (BA6). This region located in the “foot” of the MFG is considered to be “a graphic image motor center”, where the abstract, orthographic representations are converted into motor representations ([Exner, 1881](#)). Along this line and in brain tumor population specifically, [Roux et al. \(2009\)](#) reported that direct electrical stimulation of BA6 resulted either in impaired handwriting or an incapacity of combining handwriting with other language tasks. However, we are rather skeptical with this interpretation – indeed, we reiterate that a variety of written language production errors including also language switching and neologisms suggest rather a general breakdown in phonological processing and/or control mechanisms. Finally, it is important to note that none of the errors in written production were of a visual nature (i.e., named incorrectly due to an ill-defined image), but it was difficult to discern if any of TD's errors was of orthographic nature.

Summing up, we consider that the evidence points to a partial preservation of language function during the GA episode and infer that some form of IS was involved. At the same time, we admit that inference based on subjective reports is not enough to unequivocally conclude in favor of preserved IS. We nevertheless consider that the present case study hints at the conception that overt language production tasks may not be predictive of the actual functional status of individuals with severe aphasia. There may still be a silent, covert reality that is usually left unassessed. We advocate for a fine-grained behavioral testing (for example, by using the Varieties of inner speech questionnaire, [McCarthy-Jones & Fernyhough, 2011](#) and/or selected subtest of the Cambridge Semantic battery, [Adlan et al., 2010](#)) in order to understand the extent to which IS and other non-expressive language abilities are preserved in patients with GA.

Author statement

Joanna Sierpowska: Conceptualization, Methodology, Formal analysis, Investigation, Visualization, Writing- Original draft preparation, Writing – Review & Editing.

Patricia León-Cabrera: Conceptualization, Writing – Original draft preparation, Writing – Review & Editing.

Àngels Camins: Methodology, Investigation, Resources, Writing – Review & Editing.

Montserrat Juncadella: Methodology, Investigation, Resources, Writing – Review & Editing.

Andreu Gabarrós: Methodology, Investigation, Resources, Writing – Review & Editing, Supervision.

Antoni Rodríguez-Fornells: Conceptualization, Methodology, Writing- Original draft preparation, Writing – Review & Editing, Supervision.

Funding

This research was supported by grant PSI2013-43516-R of the Spanish Ministry of Economy and Competitiveness awarded to ARF. JS and PLC were funded by the Spanish Government Predoctoral Grants for the University Lecturers Training (FPU12/04117 – JS and FPU15/05554 – PLC). None of these funding sources had any involvement in the conduct of the research or the preparation of the article.

Declaration of Competing Interest

The authors declare no competing interests.

Acknowledgments

The authors would like to thank the presented person and her partner for a willingness to share their experience and clinical data, our colleague researchers: Wolfram Hinzen, Mackenzie Fama, Claudia Peñaloza, Juliana Baldo and Vitória Piai for their constructive remarks with regards to this report, as well as Harry Nye for text correction.

REFERENCES

- Adlam, A.-L. R., Patterson, K., Bozeat, S., & Hodges, J. R. (2010). The Cambridge semantic memory test battery: Detection of semantic deficits in semantic dementia and Alzheimer's disease. *Neurocase*, 16(3), 193–207.
- Aranciva, F., Casals-Coll, M., Sanchez-Benavides, G., Quintana, M., Manero, R. M., Rognoni, T., et al. (2012). Spanish normative studies in a young adult population (NEURONORMA young adults project): Norms for the Boston naming test and the token test. *Neurología*, 27(7), 394–399. <https://doi.org/10.1016/j.nrl.2011.12.016>.
- Baldo, J. V., Dronkers, N. F., Wilkins, D., Ludy, C., Raskin, P., & Kim, J. (2005). Is problem solving dependent on language? *Brain and Language*, 92(3), 240–250. <https://doi.org/10.1016/j.bandl.2004.06.103>.
- Basso, A., De Renzi, E., Faglioni, P., Scotti, G., & Spinnler, H. (1973). Neuropsychological evidence for the existence of cerebral areas critical to the performance of intelligence tasks. *Brain: A Journal of Neurology*, 96(4), 715–728. <https://doi.org/10.1093/brain/96.4.715>.
- Bek, J., Blades, M., Siegal, M., & Varley, R. (2010). Language and spatial reorientation: Evidence from severe aphasia. *Journal of Experimental Psychology. Learning, Memory, and Cognition*, 36(3), 646–658. <https://doi.org/10.1037/a0018281>.
- Bozeat, S., Lambon Ralph, M. A., Patterson, K., Garrard, P., & Hodges, J. R. (2000). Nonverbal semantic impairment in semantic dementia. *Neuropsychologia*, 38(9), 1207–1215. [https://doi.org/10.1016/S0028-3932\(00\)00034-8](https://doi.org/10.1016/S0028-3932(00)00034-8).
- Casals-Coll, M., Sánchez-Benavides, G., Quintana, M., Manero, R. M., Rognoni, T., Calvo, L., et al. (2013). Estudios normativos españoles en población adulta joven (proyecto NEURONORMA jóvenes): Normas para los test de fluencia verbal. *Neurología*, 28(1), 33–40. <https://doi.org/10.1016/j.nrl.2012.02.010>.
- Catani, M., & De Schotten, M. T. (2008). A diffusion tensor imaging tractography atlas for virtual in vivo dissections. *Cortex: A Journal Devoted to the Study of the Nervous System and Behavior*, 44(8), 1105–1132. <https://doi.org/10.1016/j.cortex.2008.05.004>.
- Catani, M., Jones, D. K., & ffytche, D. H. (2005). Perisylvian language networks of the human brain. *Annals of Neurology*, 57(1), 8–16. <https://doi.org/10.1002/ana.20319>.
- Chernoff, B. L., Teghipco, A., Garcea, F. E., Sims, M. H., Paul, D. A., Tivarus, M. E., et al. (2018). A role for the frontal aslant tract in speech planning: A neurosurgical case study. *Journal of Cognitive Neuroscience*, 30(5), 752–769. https://doi.org/10.1162/jocn_a_01244.
- De Renzi, E., & Faglioni, P. (1978). Normative data and screening power of a shortened Wechsler, D., psychological Corporation, 1997. WAIS-III: Wechsler adult intelligence scale. San Antonio, Tex, psychological Corp version of the token test. *Cortex: A Journal Devoted to the Study of the Nervous System and Behavior*, 14(1), 41–49. [https://doi.org/10.1016/S0010-9452\(78\)80006-9](https://doi.org/10.1016/S0010-9452(78)80006-9).
- Dell, G. S. (1985). Positive feedback in hierarchical connectionist models: Applications to language production. *Cognitive Science*, 9, 3–23. https://doi.org/10.1207/s15516709cog0901_2.
- Dick, A. S., Garic, D., Graziano, P., & Tremblay, P. (2019). The frontal aslant tract (FAT) and its role in speech, language and executive function. *Cortex: A Journal Devoted to the Study of the Nervous System and Behavior*, 111, 148–163. <https://doi.org/10.1016/j.cortex.2018.10.015>.
- Edwards, S., Ellams, J., & Thompson, J. (1976). Language and intelligence in dysphasia: Are they related? *International Journal of Language & Communication Disorders*, 11(2), 83–94. <https://doi.org/10.3109/13682827609011295>.
- Exner, S. (1881). *Untersuchungen über die lokalisation der Functionen in der Grosshirnrinde des Menschen*. Vienna, Austria: Wilhelm Braumüller.
- Fama, M. E., Hayward, W., Snider, S. F., Friedman, R. B., & Turkeltaub, P. E. (2017). Subjective experience of inner speech in aphasia: Preliminary behavioral relationships and neural correlates. *Brain and Language*, 164, 32–42. <https://doi.org/10.1016/j.bandl.2016.09.009>.
- Fama, M. E., Henderson, M. P., Snider, S. F., Hayward, W., Friedman, R. B., & Turkeltaub, P. E. (2019). Self-reported inner speech relates to phonological retrieval ability in people with aphasia. *Consciousness and Cognition*, 71, 18–29. <https://doi.org/10.1016/j.concog.2019.03.005>.
- Fama, M. E., Snider, S. F., Henderson, M. P., Hayward, W., Friedman, R. B., & Turkeltaub, P. E. (2019). The subjective experience of inner speech in aphasia is a meaningful reflection of lexical retrieval. *Journal of Speech, Language, and Hearing Research*, 62(1), 106–122. <https://doi.org/10.1044/2018.JSLHR-L-18-0222>.
- Fedorenko, E., & Varley, R. (2016). Language and thought are not the same thing: Evidence from neuroimaging and neurological patients. *Annals of the New York Academy of Sciences*, 1369(1), 132–153. <https://doi.org/10.1111/nyas.13046>.
- Fernyhough, C. (2004). Alien voices and inner dialogue: Towards a developmental account of auditory verbal hallucinations. *New Ideas in Psychology*, 22, 49–68. <https://doi.org/10.1016/J.NEWIDEAPSYCH.2004.09.001>.
- Fink, T., Hahne, A., Friederici, A. D., Gerber, J., Murbe, D., & Anwander, A. (2019). Language without speech: Segregating distinct circuits in the human brain. *Cerebral Cortex (New York, N.Y. : 1991)*. <https://doi.org/10.1093/cercor/bhz128>.
- Fodor, J. A. (1975). *The language of thought*. Harvard University Press.
- François, C., Ripollés, P., Bosch, L., García-Alix, A., Muchart, J., Sierpowska, J., et al. (2016). Language learning and brain reorganization in a 3-year-old child with left perinatal stroke

- revealed using structural and functional connectivity. *Cortex: A Journal Devoted to the Study of the Nervous System and Behavior*, 77, 95–118. <https://doi.org/10.1016/j.cortex.2016.01.010>.
- Gallagher, S. (2004). Neurocognitive models of schizophrenia: A neurophenomenological critique. *Psychopathology*, 37(1), 8–19. <https://doi.org/10.1159/000077014>.
- Geva, S., & Fernyhough, C. (2019). A penny for your thoughts: Children's inner speech and its neuro-development. *Frontiers in Psychology*, 10, 1708. <https://doi.org/10.3389/fpsyg.2019.01708>.
- Geva, S., Jones, P. S., Crinion, J. T., Price, C. J., Baron, J.-C., & Warburton, E. A. (2011). The neural correlates of inner speech defined by voxel-based lesion-symptom mapping. *Brain: A Journal of Neurology*, 134(10), 3071–3082. <https://doi.org/10.1093/brain/awr232>.
- Gleitman, L., & Papafragou, A. (2005). Language and thought. In K. J. Holyoak, & R. G. Morrison (Eds.), *The Cambridge handbook of thinking and reasoning* (pp. 633–661). New York, NY, US: Cambridge University Press.
- Goodglass, H., & Kaplan, E. (2001). *Boston naming test*. Lippincott Williams & Wilkins.
- Grandchamp, R., Rapin, L., Perrone-Bertolotti, M., Pichat, C., Haldin, C., Cousin, E., et al. (2019). The ConDialInt model: Condensation, dialogality, and intentionality dimensions of inner speech within a hierarchical predictive control framework. *Frontiers in Psychology*, 10. <https://doi.org/10.3389/fpsyg.2019.02019>.
- Halai, A. D., Woollams, A. M., & Lambon Ralph, M. A. (2017). Using principal component analysis to capture individual differences within a unified neuropsychological model of chronic post-stroke aphasia: Revealing the unique neural correlates of speech fluency, phonology and semantics. *Cortex: A Journal Devoted to the Study of the Nervous System and Behavior*, 86, 275–289. <https://doi.org/10.1016/j.cortex.2016.04.016>.
- Hamsher, K. (1991). Intelligence and aphasia. In M. Sarno (Ed.), *Acquired aphasia* (2nd ed.). San Diego: Academic Press.
- Havas, V., Gabarrós, A., Juncadella, M., Rifa-Ros, X., Plans, G., Acebes, J. J., et al. (2015). Electrical stimulation mapping of nouns and verbs in Broca's area. *Brain and Language*, 145–146, 53–63. <https://doi.org/10.1016/j.bandl.2015.04.005>.
- Hermer-Vazquez, L., Spelke, E. S., & Katsnelson, A. S. (1999). Sources of flexibility in human cognition: Dual-task studies of space and language. *Cognitive Psychology*, 39(1), 3–36. <https://doi.org/10.1006/cogp.1998.0713>.
- Howard, D., & Patterson, K. (1992). *The pyramids and palm trees test. A test of semantic access from words and pictures*. Thames Valley Test Company.
- Jones, S. R., & Fernyhough, C. (2007). Thought as action: Inner speech, self-monitoring, and auditory verbal hallucinations. *Consciousness and Cognition*, 16(2), 391–399. <https://doi.org/10.1016/j.concog.2005.12.003>.
- Katz, R. B., & Goodglass, H. (1990). Deep dysphasia: Analysis of a rare form of repetition disorder. *Brain and Language*, 39(1), 153–185. [https://doi.org/10.1016/0093-934x\(90\)90009-6](https://doi.org/10.1016/0093-934x(90)90009-6).
- Kemerdere, R., de Champfleury, N. M., Deverduin, J., Cochereau, J., Moritz-Gasser, S., Herbet, G., et al. (2016). Role of the left frontal aslant tract in stuttering: A brain stimulation and tractographic study. *Journal of Neurology*, 263(1), 157–167. <https://doi.org/10.1007/s00415-015-7949-3>.
- Kinoshita, M., de Champfleury, N. M., Deverduin, J., Moritz-Gasser, S., Herbet, G., & Duffau, H. (2015). Role of fronto-striatal tract and frontal aslant tract in movement and speech: An axonal mapping study. *Brain Structure & Function*, 220(6), 3399–3412. <https://doi.org/10.1007/s00429-014-0863-0>.
- Levelt, W. J. M. (1983). Monitoring and self-repair in speech. *Cognition*, 14, 41–104. [https://doi.org/10.1016/0010-0277\(83\)90026-4](https://doi.org/10.1016/0010-0277(83)90026-4).
- Levelt, W. J. M. (1989). *Speaking: From intention to articulation*. Cambridge, MA: MIT Press.
- Loevenbruck, H., Grandchamp, R., Rapin, L., Nalborczyk, L., Dohen, M., Perrier, P., et al. (2018). In P. Langland-Hassan, & A. Vicente (Eds.), "A cognitive neuroscience view of inner language: To predict and to hear, see, feel," in *inner speech: New voices* (pp. 131–167). Oxford: Oxford University Press.
- McCarthy-Jones, S., & Fernyhough, C. (2011). The varieties of inner speech: Links between quality of inner speech and psychopathological variables in a sample of young adults. *Consciousness and Cognition*, 20(4), 1586–1593. <https://doi.org/10.1016/j.concog.2011.08.005>.
- Möller, J., Jansma, B. M., Rodríguez-Fornells, A., & Münte, T. F. (2007). What the brain does before the tongue slips. *Cerebral Cortex*, 17, 1173–1178. <https://doi.org/10.1093/cercor/bhl028>.
- Motley, M. T., Baars, B. J., & Camden, C. T. (1983). Experimental verbal slip studies: A review and an editing model of language encoding. *Communications Monographs*, 50(2), 79–101. <https://doi.org/10.1080/0363775830939015>.
- Oldfield, R. C. (1971). The assessment and analysis of handedness: The Edinburgh inventory. *Neuropsychologia*, 9, 97–113. [https://doi.org/10.1016/0028-3932\(71\)90067-4](https://doi.org/10.1016/0028-3932(71)90067-4).
- Paik, N.-J., & Kim, W. (2014). Lesion localization of global aphasia without hemiparesis by overlapping of the brain magnetic resonance images. *Neural Regeneration Research*, 9(23), 2081. <https://doi.org/10.4103/1673-5374.147935>.
- Pai, A. R., Krishnan, G., Prashanth, S., & Rao, S. (2011). Global aphasia without hemiparesis: A case series. *Annals of Indian Academy of Neurology*, 14(3), 185–188. <https://doi.org/10.4103/0972-2327.85890>.
- Peña-Casanova, J. (2005). *Integrated neuropsychological exploration program barcelona test revised*. Barcelona: Masson.
- Peña-Casanova, J., Quinones-Ubeda, S., Gramunt-Fombuena, N., Aguilar, M., Casas, L., Molinuevo, J. L., et al. (2009). Spanish multicenter normative studies (NEURONORMA project): Norms for Boston naming test and token test. *Archives of Clinical Neuropsychology*, 24(4), 343–354. <https://doi.org/10.1093/arclin/acp039>.
- Postma, A. (2000). Detection of errors during speech production: A review of speech monitoring models. *Cognition*, 77, 97–131. [https://doi.org/10.1016/S0010-0277\(00\)00090-1](https://doi.org/10.1016/S0010-0277(00)00090-1).
- Rodríguez-Fornells, A., Krämer, U., Lorenzo-Seva, U., Festman, J., & Münte, T. F. (2012). Self-assessment of individual differences in language switching. *Frontiers in Psychology*, 2, 388. <https://doi.org/10.3389/fpsyg.2011.00388>.
- Roux, F.-E., Dufor, O., Giussani, C., Wamain, Y., Draper, L., Longcamp, M., et al. (2009). The graphemic/motor frontal area Exner's area revisited: Graphemic/motor frontal area. *Annals of Neurology*, 66(4), 537–545. <https://doi.org/10.1002/ana.21804>.
- Sapir, E. (1941). *Language, culture, and personality: Essays in memory of Edward Sapir*. Greenwood Pub Group.
- Sclavi, M. (2017). *The finch in my brain*. Hodder & Stoughton, An Hachette UK Company.
- Shindo, A., Satoh, M., Naito, Y., Asahi, M., Takashima, S., Sasaki, R., et al. (2013). Global aphasia without hemiparesis: The underlying mechanism examined by transcranial magnetic stimulation. *The Neurologist*, 19(1), 11–14. <https://doi.org/10.1097/NRL.0b013e31827c6b95>.
- Sierpowska, J., Fernández-Coello, A., Gómez-Andrés, A., Camins, A., Castañer, S., Juncadella, M., et al. (2018). Involvement of the middle frontal gyrus in language switching as revealed by electrical stimulation mapping and functional magnetic resonance imaging in bilingual brain tumor patients. *Cortex: A Journal Devoted to the Study of the Nervous System and Behavior*, 99, 78–92. <https://doi.org/10.1016/j.cortex.2017.10.017>.

- Sierpowska, A., Gabarros, A., Fernandez-Coello, Camins, A., Castañer, A., Juncadella, M., et al. (2015). Language morphological derivation overflow as a result of disruption of the left frontal aslant white matter tract. *Brain and Language*, 142, 54–64. <https://doi.org/10.1016/j.bandl.2015.01.005>.
- Sierpowska, J., Gabarrós, J., Fernandez-Coello, A., Camins, A., Castañer, S., Juncadella, M., et al. (2019). Implication of ventral white-matter pathways in semantic processing: Intraoperative and lesion-behavior mapping evidence. *NeuroImage: Clinical*, 22, 101704. <https://doi.org/10.1016/j.nicl.2019.101704>.
- Sierpowska, J., Gabarros, A., Fernandez-Coello, A., Camins, A., Castañer, S., Juncadella, M., et al. (2017). Words are not enough: Nonword repetition as an indicator of arcuate fasciculus integrity during brain tumor resection. *Journal of Neurosurgery*, 126(2), 435–445. <https://doi.org/10.3171/2016.2.JNS151592>.
- Sierpowska, J., Gabarros, A., Ripolles, P., Juncadella, M., Castañer, S., Camins, A., et al. (2013). Intraoperative electrical stimulation of language switching in two bilingual patients. *Neuropsychologia*, 51(13), 2882–2892. <https://doi.org/10.1016/j.neuropsychologia.2013.09.003>.
- Snodgrass, J. G., & Vanderwart, M. (1980). A standardized set of 260 pictures: Norms for name agreement, image agreement, familiarity, and visual complexity. *Journal of Experimental Psychology: Human Learning and Memory*, 6(2), 174–215. <https://doi.org/10.1037/0278-7393.6.2.174>.
- Sokolov, A. (2012). *Inner speech and thought*. Springer Science & Business Media.
- Vicente, A., & Martinez Manrique, F. (2011). Inner speech: Nature and functions. *Philosophy Compass*, 6(3), 209–219. <https://doi.org/10.1111/j.1747-9991.2010.00369.x>.
- Vygotsky, L. S. (1987). Thinking and speech. In R. W. Rieber, & A. S. Carton (Eds.), *The collected works of L.S. Vygotsky, Volume 1: Problems of general psychology* (39–285). New York: Plenum Press (Original work published in 1934).
- Wechsler, D. (1997). *WAIS-III*. San Antonio, TX: Psychological Corporation.
- Wechsler, D. (2004). *Adaptación al castellano de la escala de memoria de Wechsler-III*. Madrid: TEA Ediciones.
- Whitford, T. J., Jack, B. N., Pearson, D., Griffiths, O., Luque, D., Harris, A. W., et al. (2017). Neurophysiological evidence of efference copies to inner speech. *ELife*, 6. <https://doi.org/10.7554/eLife.28197>.
- Whorf, B. L. (1956). *Language, thought and reality*. Cambridge: MIT Press.
- Wittgenstein, L. (1922). *Tractatus logico-philosophicus (TLP)*. London: Kegan Paul.