

## Short report

### Intratumoral PEG-interleukin-2 therapy in patients with locoregionally recurrent head and neck squamous-cell carcinoma

V. Mattijssen,<sup>1</sup> P. H. De Mulder,<sup>1</sup> A. De Graeff,<sup>5</sup> P. S. Hupperets,<sup>6</sup> F. Joosten,<sup>2</sup> D. J. Ruiter,<sup>3</sup> H. Bier,<sup>7</sup> P. A. Palmer<sup>8</sup> & P. Van den Broek<sup>4</sup>

Departments of <sup>1</sup>Medical Oncology, <sup>2</sup>Radiology, <sup>3</sup>Pathology, and <sup>4</sup>Otorhinolaryngology, University Hospital, Nijmegen; Departments of Medical Oncology, University Hospitals <sup>5</sup>Utrecht, and <sup>6</sup>Maastricht, The Netherlands; <sup>7</sup>Department of Otorhinolaryngology, University Hospital, Düsseldorf, Germany; <sup>8</sup>EuroCetus B.V., Amsterdam, The Netherlands

#### Summary

**Background:** An enhanced efficacy of local as compared to systemic administration of interleukin-2 (IL-2) has been demonstrated in several experimental tumors. We previously reported that guinea pigs with palpable tumors and regional micrometastases could be cured by intratumoral injections of polyethylene glycol-modified IL-2 (PEG-IL-2). In the present study this treatment schedule was applied in a clinical situation.

**Patients and methods:** Nineteen patients with 11 local and 11 regional recurrences of head and neck squamous cell carcinoma (HNSCC) were treated with intratumoral injections of 200,000 U of PEG-IL-2 3 times weekly in courses of 4 weeks.

**Results:** Treatment was given on an out-patient basis, and was well tolerated. Temporary regional swelling and redness developed in 10 patients, and in 9 of them systemic eosino-

philia was documented. Median duration of treatment was 4 weeks (range 2-14 weeks). Seventeen patients were evaluable for response. One complete response (CR; 6%; duration 91 weeks), and 6 stable diseases (SDs; duration 8-57+ weeks) were recorded. The CR and the 3 best SDs (23, 40, 57+ weeks) occurred in patients with a single regional tumor recurrence of relatively small size. During treatment, all 4 developed locoregional edema and redness, and high levels of circulating eosinophils. Median survival was 23 weeks for all patients, and 45+ weeks for the patients with SD.

**Conclusion:** Intratumoral injection of PEG-IL-2 in patients with HNSCC is feasible. This treatment appears beneficial for highly selected patients. The objective response rate is insufficient to justify wide clinical application.

**Key words:** head and neck squamous-cell carcinoma, immunotherapy, PEG-interleukin-2

#### Introduction

The efficacy of locoregional injections with low doses of interleukin-2 (IL-2) has been described in several experimental tumors. Besides locoregional antitumor effects, this approach has been shown to induce specific systemic immunity, which resulted in rejection of tumor cells inoculated at distant sites [1-3]. The peritumoral administration route of IL-2 and the presence of lymphocytes at the tumor site appeared to be prerequisites for these effects. It was hypothesized that host immune cells at the tumor site were activated by exogenous IL-2 to produce cytokines and to recruit specific and nonspecific immune effector mechanisms [1]. We analyzed locoregional immunotherapy in the guinea pig line-10 tumor model [4]. In addition to IL-2, polyethylene glycol (PEG)-modified IL-2 was also used, enhancing solubility and plasma half-life [5]. It was found that guinea-pigs with palpable tumors on the flank and micrometastases in the regional lymph nodes could be cured by intratumoral, but not perilymphatic, injections of PEG-IL-2, whereas IL-2

showed temporary tumor-growth inhibition only [4].

Head and neck squamous cell carcinoma (HNSCC) appears to be a suitable disease in which to evaluate local IL-2 immunotherapy in man. This tumor is localized near the body surface, close to submucosal and nodular lymphatic tissue, and tends to recur locoregionally after primary therapy. Cortesina et al. [6, 7] obtained objective responses with perilymphatic IL-2 injections (i.e., around the tumor-draining lymph nodes) in locoregionally recurrent HNSCC (6/10 and 4/31 patients). We could not confirm this in patients with primary locoregionally far-advanced disease [8]. Partial responses were also described in HNSCC patients using combined perilymphatic and intratumoral IL-2 injections (2/36 patients) [9], intra-arterial IL-2 infusion (2/12 patients) [10], and combined locoregional IL-2 and LAK cell administration (3/14 patients) [11]. The aim of the present study was to evaluate the feasibility and the local antitumor effects of intratumoral PEG-IL-2 injections in HNSCC, in a schedule which had been found to be optimal in our animal study [4].

## Patients and methods

Nineteen patients (13 men, 6 women) with a median age of 69 years (range 46–83), gave informed consent and entered this study. Eligible patients had to have measurable, histologically- or cytologically-confirmed locoregional recurrence of HNSCC since previous surgery and/or radiotherapy at not more than two sites, for which no curative treatment was available. Tumor recurrences had to be accessible to injection, and could not exceed 8 cm at the largest diameter. Further eligibility criteria included: Karnofsky performance status >70%, expected survival >3 months, normal hematologic parameters, adequate hepatic, renal, and cardiac function, no other significant medical conditions requiring ongoing therapy, no organ allografts, no concurrent corticosteroid therapy, and no distant metastases. The study was carried out with ethical committee approval.

Recombinant human IL-2 modified by the covalent attachment of 2–3 PEG M<sub>n</sub> 7,000 molecules per IL-2 molecule (PEG-IL-2) was provided by EuroCetus, Amsterdam, The Netherlands. Specific activity was  $85.7 \times 10^5$  (Lotno. LCP-920) or  $40.0 \times 10^5$  (Lotno. LCP-039B) U/mg IL-2 protein. Intralesional injections with 200,000 U PEG-IL-2 in 0.5 ml normal saline, containing 0.1% human serum albumin, were given 3 times a week for 4 weeks. Patients with 2 tumor recurrences received a double dose. Response to treatment was evaluated after 4 weeks, and defined according to WHO criteria. Patients with progressive disease (PD) were removed from the study. In instances of stable disease (SD) treatment was continued for 8 weeks. Objective responders were scheduled to receive 12 weeks of treatment without interruption. Response duration and patient survival were determined from the start of PEG-IL-2 treatment.

## Results

In 19 patients 22 tumor recurrences were treated (Table 1). Prior treatment included radiotherapy (all 19), primary tumor resection (14 patients), neck lymph node dissection (unilateral in 6 and bilateral in 5), and

chemotherapy (4 patients). Median time between conclusion of previous treatment and diagnosis of the current tumor recurrence was 4 months. PEG-IL-2 was injected preferably in vital tumor borders, rather than in necrotic central parts. For treatment of lymph node metastases the injection site and depth were determined by ultrasound. Seventeen patients were evaluable for response. One complete response (CR; 6%) was obtained in a man with a subcutaneous metastasis in the neck. Shrinkage of the lesion was first observed after 3 weeks of PEG-IL-2 treatment. After 8 weeks a flat skin lesion remained, which could no longer be injected. Treatment was then stopped, and 4 weeks later the lesion had disappeared completely (Fig. 1). The CR persisted for 91 weeks. The subsequent tumor recurrence was not accessible to injection. In 6 patients SD was recorded (duration 8–57+ weeks). Patients with progressive tumor growth at evaluation after 4 weeks, or before completing the successive 4 weeks of treatment were recorded as PD. Two patients were not evaluable for response, one because of unmeasurable disease, and the other because of early death. The latter occurred in a 66-year-old man who unexpectedly died during his sleep about 36 hours after the 5th PEG-IL-2 administration for 2 skin metastases on the cheek. Autopsy was not permitted and the cause of death remained uncertain. A relationship with PEG-IL-2 treatment was considered unlikely. Chemotherapy, given to 5 patients (Nos. 3, 4, 14, 16, and 17) for progressive tumor growth following PEG-IL-2 therapy, did not result in objective responses. Median survival from the start of PEG-IL-2 treatment was 23 weeks for the total group, and 45+ weeks for the 6 patients who achieved SD.

Table 1. HNSCC locoregional recurrences and intratumoral PEG-IL-2 treatment.

Patient no.	Treated lesions		Total weeks of treatment	Response (duration, weeks)	Patient survival (weeks)	Locoregional side effects	Eosinophils max. levels <sup>c</sup> ( $\times 10^6/l$ )
	Site <sup>a</sup>	Size (cm <sup>2</sup> ) <sup>b</sup>					
1	subc.	7.2	8	CR (91)	102+	swelling, redness	1140
2	l.n. (2)	3.1; 3.2	2	Early progression	9	swelling, redness	962
3	l.n.	4.3	8	SD (40)	59	swelling, redness, itching	2436
4	subc.	10.8	4	PD	20	none	320
5	prim.	3.8	6	PD	23	swelling, redness	720
6	prim.	12.0	6	PD	24	enhanced tumor necrosis	231
7	prim.	1.5	8	SD (8)	39	swelling, redness	726
8	l.n. + prim.	5.5; 5.3	8	SD (8)	22	swelling, redness, mild pain	710
9	prim.	36.0	2	Early progression	14	none	97
10	prim.	42.0	4	PD	8	none	186
11	prim.	4.9	4	PD	8	none	162
12	l.n.	1.6	4	SD (57+)	57+	swelling, redness, itching	3515
13	prim.	not measurable	14 <sup>d</sup>	not measurable	31	swelling, redness	688
14	l.n.	20.0	8	SD (23)	52+	swelling, redness, itching	4653
15	prim.	6.3	4	PD	38+	none	70
16	l.n.	23.4	8	SD (12)	36+	mild pain	99
17	prim.	15.0	4	PD	11	none	152
18	skin (2)	3.6; 2.0	2	not evaluable	2	swelling, redness	n.m.
19	prim.	6.0	4	PD	6	mild pain	260

<sup>a</sup>subc.: subcutaneous; l.n.: lymph node; prim.: primary tumor site. <sup>b</sup>Product of largest bipерpendicular diameters. <sup>c</sup>Normal count <400/10<sup>6</sup>l. n.m.: not measured. <sup>d</sup>Therapy was continued for 14 weeks because of subjective improvement.

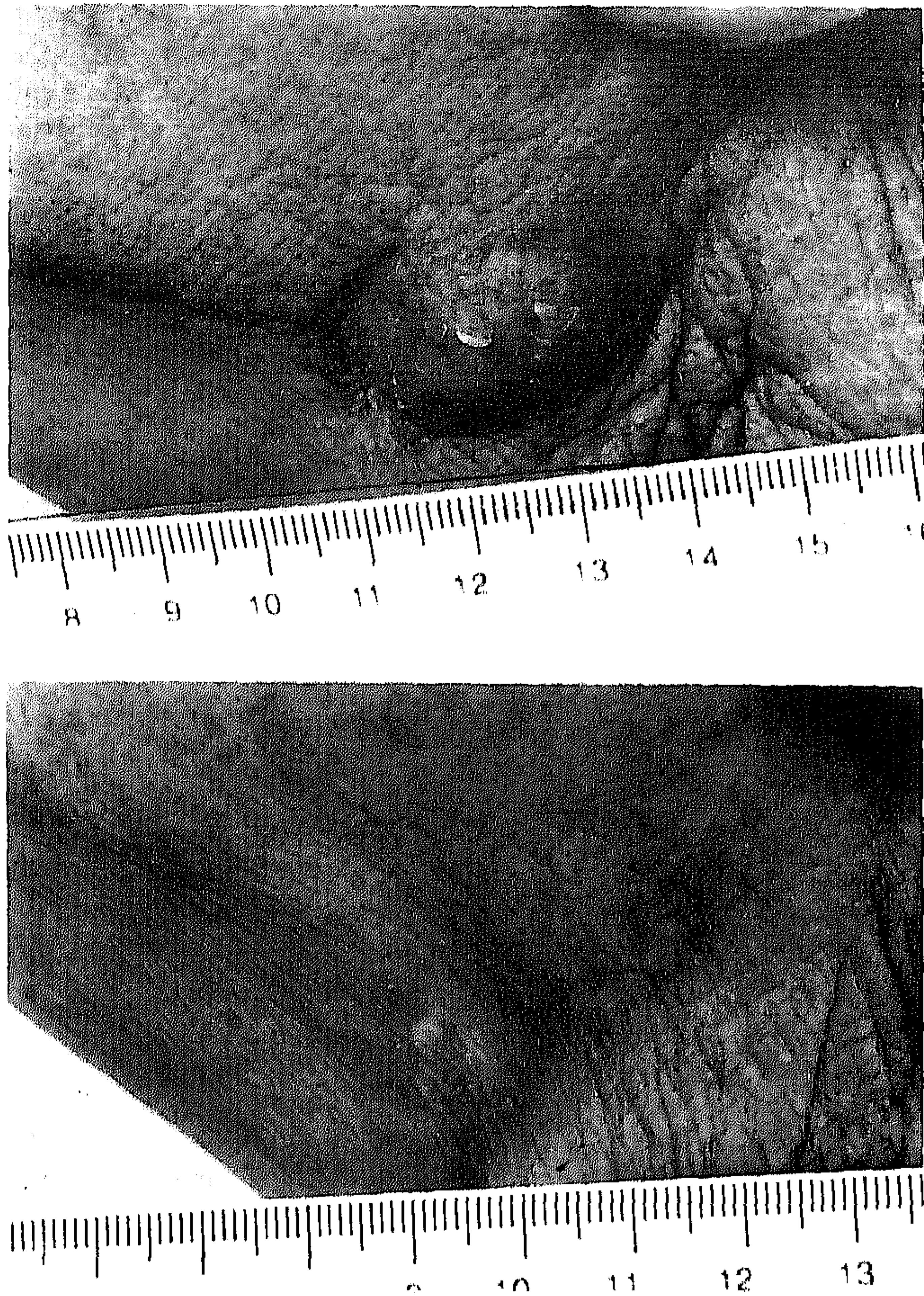


Fig. 1. Nodular subcutaneous tumor recurrence (30 × 24 mm, cytologically confirmed squamous cell carcinoma, with documented progressive growth) in the upper jugular region of the left neck, in a 69-year-old man who was previously treated with radiotherapy, laryngectomy, and bilateral neck lymph node dissection for poorly-differentiated squamous cell carcinoma of the larynx. a, before PEG-IL-2 treatment. b, complete response, 4 weeks after stopping treatment with 3 times weekly 200,000 U PEG-IL-2 injections for 8 weeks.

All patients were evaluable for toxicity. Treatment was well tolerated. No systemic toxicity was observed. Swelling and redness of the neck and/or face on the side of injection developed in 10 patients. The swelling consisted of thickening of the skin and subcutaneous edema, as was confirmed by ultrasound examination. This reaction generally started after 1 week of treatment, and decreased from 1–2 weeks after cessation of treatment. Hematological blood counts revealed temporary eosinophilia during treatment in 9 patients. Interestingly, these were the same patients who developed locoregional swelling and redness (Table 1).

## Discussion

Intratumoral injection of PEG-IL-2, 3 times weekly at intermediate doses, in patients with HNSCC appeared feasible. Treatment was given in the out-patient clinic, and toxicity was mild. The response rate obtained in

patients with locoregionally recurrent disease after previous surgical and/or radiation therapy was low (6%). Nevertheless, the long-lasting CR indicates that a highly effective antitumor mechanism can be induced in certain circumstances. A favorable response in patients with large or very fast-growing tumors appears unlikely. The patient with the CR and the 3 with SD of substantial duration all had a single regional tumor recurrence of relatively small size. During treatment these 4 patients developed high levels of circulating eosinophils and, along with 6 others, locoregional swelling and redness. Whether these observations are related to the tumor response remains speculative. In this study sufficient material could not be obtained for histopathological analysis of PEG-IL-2-induced local reactions. However, a local indurative and erythematous reaction after subcutaneous IL-2 or PEG-IL-2 injection in humans, resembling a delayed-type hypersensitivity reaction and consisting of mononuclear cell infiltration, has been previously described [12]. In the line-10 guinea-pig tumor, in which we previously evaluated intratumoral PEG-IL-2 therapy [4], an intense inflammatory reaction with eosinophils, T lymphocytes, macrophages and fibroblasts was observed at the site of regressing tumors (unpublished data). An association between eosinophilia and a favorable tumor response has been described in patients receiving subcutaneous IL-2 and IFN $\alpha$  therapy [13]. Tepper et al. provided evidence for eosinophil-mediated tumor-cell killing *in vivo* [14].

In the present study, a single, intermediate dose-level for PEG-IL-2 was chosen. This dose was based on our experimental results with intratumoral PEG-IL-2 in the fast-growing guinea-pig line-10 tumor. It is uncertain whether the present dose is optimal for HNSCC. In previous studies with locoregional IL-2 administration in HNSCC, there were no indications that high IL-2 doses yield better results [7, 9, 10]. In contrast, most objective clinical responses were obtained, especially with daily locoregional administration of relatively low doses (200–30,000 U) of IL-2 [6, 7, 10].

We conclude that a minority of patients with locoregionally recurrent HNSCC might benefit from intratumoral PEG-IL-2 injections. Therapy is well tolerated. The antitumor mechanism is unknown. Increased knowledge about the underlying mechanism would make possible identification of patients susceptible to this kind of locoregional immunotherapy. An alternative study design, with intratumoral PEG-IL-2 injections prior to tumor resection and regional lymph node dissection, appears appropriate. It could provide material for thorough histological and immunological analysis of PEG-IL-2-induced locoregional reactions. Moreover, this patient group might be more susceptible to immunotherapy because their regional lymphatic system has not been disturbed by previous surgery.

## Acknowledgements

Otorhinolaryngologists and maxillo-facial surgeons of the participating centers are gratefully acknowledged for their contributions to patient selection and treatment. This work was supported by Grant SNUKC 89-15 from the Dutch Cancer Society.

## References

1. Forni G, Giovarelli M, Santoni A. Lymphokine-activated tumor inhibition in vivo. The local administration of interleukin-2 triggers nonreactive lymphocytes from tumor-bearing mice to inhibit tumor growth. *J Immunol* 1985; 134: 1305-11.
2. Vaage J. Local and systemic effects during interleukin-2 therapy of mouse mammary tumors. *Cancer Res* 1987; 47: 4296-8.
3. Maas RA, Van Weering DH, Dullens HF et al. Intratumoral low-dose interleukin-2 induces rejection of distant solid tumour. *Cancer Immunol Immunother* 1991; 33: 389-94.
4. Mattijssen V, Balemans LT, Steerenberg PA et al. Polyethylene-glycol-modified interleukin-2 is superior to interleukin-2 in locoregional immunotherapy of established guinea-pig tumors. *Int J Cancer* 1992; 51: 812-7.
5. Katre NV, Knauf MJ, Laird WJ. Chemical modification of recombinant interleukin 2 by polyethylene glycol increases its potency in the murine Meth A sarcoma model. *Proc Natl Acad Sci USA* 1987; 84: 1487-91.
6. Cortesina G, De Stefani A, Giovarelli M et al. Treatment of recurrent squamous cell carcinoma of the head and neck with low doses of interleukin-2 injected perilymphatically. *Cancer* 1988; 62: 2482-5.
7. Cortesina G, De Stefani A, Galeazzi E et al. Temporary regression of recurrent squamous cell carcinoma of the head and neck is achieved with a low but not with a high dose of recombinant interleukin 2 injected perilymphatically. *Br J Cancer* 1994; 69: 572-6.
8. Mattijssen V, De Mulder PH, Schornagel JH et al. Clinical and immunopathological results of a phase II study on perilymphatically injected recombinant interleukin-2 in locally advanced, nonpretreated head and neck squamous cell carcinoma. *J Immunother* 1991; 19: 63-8.
9. Vlock DR, Snyderman CH, Johnson JT et al. Phase Ib trial of the effect of peritumoral and intranodal injections of interleukin-2 in patients with advanced squamous cell carcinoma of the head and neck: An Eastern Cooperative Oncology Group trial. *J Immunother* 1994; 15: 134-9.
10. Gore ME, Riches P, MacLennan K et al. Phase I study of intra-arterial interleukin-2 in squamous cell carcinoma of the head and neck. *Br J Cancer* 1992; 66: 405-7.
11. Squadrelli-Saraceno M, Rivoltini L, Cantù G et al. Local adoptive immunotherapy of advanced head and neck tumors with LAK cells and interleukin-2. *Tumori* 1990; 76: 566-71.
12. Tepler H, Kaplan G, Smith K et al. Efficacy of low doses of the polyethylene glycol derivate of interleukin-2 in modulating the immune response of patients with human immunodeficiency virus type 1 infection. *J Infect Dis* 1993; 167: 291-8.
13. Atzpodien J, Körfer A, Franks CR et al. Home therapy with recombinant interleukin-2 and interferon- $\alpha$ 2b in advanced human malignancies. *Lancet* 1990; 335-II: 1509-12.
14. Tepper RI, Coffman RL, Leder P. An eosinophil-dependent mechanism for the antitumor effect of interleukin-4. *Science* 1992; 257: 548-51.

Received 7 February 1994; accepted 28 June 1994.

### Correspondence to:

Vera Mattijssen, M.D.  
Department of Medicine  
University Hospital Nijmegen  
P.O. Box 9101, 6500 HB Nijmegen  
The Netherlands