

PDF hosted at the Radboud Repository of the Radboud University Nijmegen

The following full text is a publisher's version.

For additional information about this publication click this link.

<http://hdl.handle.net/2066/200617>

Please be advised that this information was generated on 2021-09-18 and may be subject to change.

RESEARCH ARTICLE


Effects of early adversity on the brain: Larger-volume anterior cingulate cortex in AIDS orphans

Peiyong Zuo¹, Yanan Wang², Jia Liu², Siyuan Hu², Guoxiang Zhao³, Lijie Huang⁴, Danhua Lin^{1*}

1 Institute of Developmental Psychology, Beijing Normal University, Beijing, China, **2** Beijing Key Laboratory of Applied Experimental Psychology, School of Psychology, Beijing Normal University, Beijing, China, **3** Department of Psychology, Henan University, Kaifeng, China, **4** State Key Laboratory of Cognitive Neuroscience and Learning & IDG/McGovern Institute for Brain Research, Beijing Normal University, Beijing, China

☞ These authors contributed equally to this work.

* danhualin@bnu.edu.cn



Abstract

Multiple studies have revealed that adolescent AIDS orphans have more psychosocial problems than healthy adolescents. However, little is known about whether and how the brain structures of adolescent AIDS orphans differ from those of healthy adolescents. Here, we used magnetic resonance imaging to compare adolescent AIDS orphans reared in institutions ($N = 20$) with a sex- and age-matched group of healthy adolescents reared in families ($N = 20$) in China using a voxel-based morphometry analysis. First, we found that both total gray- and white-matter volumes did not differ between groups. Second, after correcting for age, sex, and total gray-matter volume, the AIDS orphan group demonstrated smaller hippocampal volumes, larger anterior cingulate cortex (ACC) volumes, and no differences in the amygdala. Third, a whole-brain analysis identified higher gray-matter volume of the ACC in the AIDS orphan group than in the control group. The preliminary findings of this study highlight the need for future research to confirm the sensitivity of the hippocampus and ACC to early adversity.

OPEN ACCESS

Citation: Zuo P, Wang Y, Liu J, Hu S, Zhao G, Huang L, et al. (2019) Effects of early adversity on the brain: Larger-volume anterior cingulate cortex in AIDS orphans. PLoS ONE 14(1): e0210489. <https://doi.org/10.1371/journal.pone.0210489>

Editor: Jiang Qiu, Southwest University, CHINA

Received: May 22, 2018

Accepted: December 23, 2018

Published: January 14, 2019

Copyright: © 2019 Zuo et al. This is an open access article distributed under the terms of the [Creative Commons Attribution License](https://creativecommons.org/licenses/by/4.0/), which permits unrestricted use, distribution, and reproduction in any medium, provided the original author and source are credited.

Data Availability Statement: All relevant data are within the paper and its Supporting Information files.

Funding: This work was supported by the National Social Science Foundation of China (15ZDB138).

Competing interests: The authors have declared that no competing interests exist.

Introduction

An estimated 17.8 million AIDS orphans < 18 years old have lost either or both parents to AIDS [1], a population that was expected to increase to 25 million by 2015 [2]. AIDS orphans experience many severe early adversities such as maternal deprivation [3, 4], poverty [5, 6], stigma [7, 8], and multiple losses and erosion of family support [9]. As a result, adolescent AIDS orphans have more psychosocial and behavioral problems than do healthy adolescents [8–12]. For example, a study with a large sample size in China shows that AIDS orphans demonstrated poorer psychological adjustment than those from HIV-free families in the same rural community [10]. Once adopted by institutions, AIDS orphans are more vulnerable and

potentially at higher risk of lower degrees of life improvement and life satisfaction [13] and more psychopathologies [14] than are noninstitutionalized children.

In short, previous studies suggested that adolescent AIDS orphans, especially those reared in institutions, suffer more psychosocial and behavioral problems than healthy adolescents. However, very little is known about whether and how AIDS orphans differ from healthy adolescents at the neurobiological level. In particular, we aimed to identify the differences in neural structure between AIDS orphans and healthy children to determine how early adversity influences subsequent brain and behavioral development and develop effective intervention strategies to protect their health.

Effect of early adversity on neural structure

Several decades of neuroimaging studies have indicated that total gray- and white-matter volumes, the structures of the prefrontal cortex (PFC), hippocampus, and amygdala are highly sensitive to early stressful events, such as poverty [15], maternal deprivation [16], early exposure to institutionalization [17], and maltreatment [18]. Therefore, AIDS orphans are predicted to show differences in these areas when compared to healthy adolescents.

Previous studies showed that gray- and white-matter volumes can be affected by institutional rearing experiences [17, 19, 20]. For example, in English and Romanian Adoptees studies, Mehta et al. (2009) reported smaller gray- and white-matter volumes for 14 previously institutionalized adolescents (16 years old) relative to 11 never-institutionalized adoptees from the United Kingdom. Meanwhile, Sheridan et al. (2012) showed lower white-matter volumes among children who remained in institutional care than did children randomized to an improved rearing environment.

Multiple studies have reported that the PFC, which is responsible for temporal sequencing of goal-directed behaviors, is highly sensitive to early adversity [21, 22]. However, there are mixed findings from studies comparing the PFC volumes of children with early adversity to those of healthy children [23]. Some studies have reported that regions of the PFC in institutionalized adolescents showed lower cortical thickness [21] and volume [22] than did those of community control subjects. The two most recent studies on maltreatment-related post-traumatic stress disorder (PTSD) observed larger gray-matter volumes of the middle-inferior and ventral regions of the PFC in the clinical groups [24, 25].

Early adverse experiences are thought to influence the structure of the hippocampus and amygdala, two critical neural substrates that regulate stress responses, but the results are still mixed. For example, previous studies showed that poor children have smaller volumes of the hippocampus [26] and amygdala [27]. Meanwhile, maternal deprivation is correlated with smaller hippocampal volume [28, 29], and smaller hippocampal volumes were found in later-adopted children relative to non-adopted controls [22]. However, Mehta et al. (2009) failed to detect differences in hippocampal volumes in children with a history of institutional care. Moreover, institutionalized children reportedly showed higher amygdala volumes than did non-adopted adolescents [17, 30], but larger amygdala volumes were not detected by Hodel et al. (2015), whose study focused on post-institutionalized children.

In sum, previous studies showed that early adversity was associated with differences in the volumes of the white and gray matter, PFC, hippocampus, and amygdala [12]. However, the findings across studies regarding the specific regions affected that may be resulted by differences in sample composition are not entirely consistent [19]. Institutional rearing of AIDS orphans represents a severe form of early psychological and physical neglect and would serve as a model system for understanding how early experiences impact brain and behavioral development.

Current study

The aim of the present study was to determine whether and how the brain structures of AIDS orphans differ from those of healthy adolescents. First, we investigated whether institutionally reared AIDS orphans had smaller cortical gray- and white-matter volumes relative to healthy adolescents. Second, regions of interest (ROI) analyses were performed to examine whether and how the gray-matter volumes of the PFC, hippocampus, and amygdala differ between AIDS orphans and healthy adolescents. Third, a whole-brain analysis was performed to confirm the results of ROI analyses and determine which regions differed the most between the AIDS orphans and the controls.

Methods

Subjects

Twenty AIDS orphans (age, 15.75 ± 1.97 years; sex, 10 male, 10 female) were recruited from an orphanage located in Henan Province of China, an area with a high HIV/AIDS prevalence due to unsanitary commercial blood collections performed between the late 1980s and middle 1990s. They had lived in an orphanage a mean 5.08 ± 1.83 , and 90% of them had been transferred from another orphanage (especially AIDS orphans attending primary school) to their current orphanage (especially older AIDS orphans). Another 20 school-aged adolescents (mean age, 15.85 ± 2.35 ; sex, 12 male, 8 female) were recruited from Beijing as the control group. No significant group differences were identified on age ($t = 0.13$; $p = 0.90$) and gender ($\chi^2 = 0.40$; $p = 0.53$). Signed informed consent was obtained from the AIDS orphans and their legal guardians (their teachers in the orphanage) before the data collection. Meanwhile, written informed consent was obtained from all healthy adolescents and their parents. The magnetic resonance imaging (MRI) protocol and consent procedure were approved by the Institutional Review Board of Beijing Normal University.

MRI data acquisition

Participants were scanned in a Siemens 3T scanner (MAGENTOM Trio, a Tim system) with a 12-channel phased-array head coil at the BNU Imaging Center for Brain Research, Beijing, China. The whole-brain structural images were acquired using a 3D magnetization prepared rapid gradient echo (MP-RAGE) T1-weighted sequence (TR/TE/TI = 2530/3.39/1100 ms; flip angle = 7 degrees; field of view, 256×256 mm). One hundred and twenty-eight contiguous sagittal slices were acquired with 161-mm in-plane resolution and 1.33-mm slice thickness for whole-brain coverage.

Voxel-based morphometry analysis

Voxel-based morphometry (VBM) is a fully automatic technique which allows an objective analysis of anatomical differences between groups across the entire brain, and it has been widely used to quantify structural brain changes associated with neuropsychiatric pathologies such as psychiatric disorders [31] and depression [32, 33]. Hence, VBM was employed to quantify gray-matter volume in each voxel across the entire brain (Ashburner and Friston, 2000). Specifically, VBM was performed using SPM8 (Statistical Parametric Mapping 8; Wellcome Department of Imaging Neuroscience, University College, London, UK) and DARTEL (Wellcome Department of Imaging Neuroscience) running under MATLAB 2010 (The Mathworks, Sherborn, MA, USA). First, image quality was assessed by visual inspection, and no excessive scanner artifact was found. Second, the origin of the brain was manually set to the anterior commissure for each participant. Third, images were segmented into four distinct

tissue classes: gray matter, white matter, cerebrospinal fluid, and everything else (e.g., skull and scalp) using a unified segmentation approach [34]. Fourth, the segmented gray-matter images were rigidly aligned and resampled to $2 \times 2 \times 2$ mm. Fifth, the images were nonlinearly registered with DARTEL, which involves iteratively computing a study-specific template based on the tissue maps from all participants and then warping all participants' gray-matter images into the generated template to increasingly improve the alignment (Ashburner, 2007). Sixth, the gray-matter images were normalized to standard Montreal Neurological Institute space, and the gray-matter voxel values were modulated by multiplying the Jacobian determinants derived from the registration to preserve the volume of tissue from each structure [35]. The modulated gray-matter images were then smoothed with an 8-mm full width at half maximum isotropic Gaussian kernel. Finally, to exclude noisy voxels, the modulated images were masked using an absolute masking with a threshold of 0.2. The masked modulated gray-matter images were used in the further statistical analyses.

MRI data analysis

To fully investigate the neuroanatomical differences between the AIDS orphans and the control group, the current analysis started with an independent-sample *t*-test to compare the differences in the total white- and gray-matter volumes. Mean total gray- and white-matter volume were extracted for each participant using FreeROI (<http://freeroi.brainactivityatlas.org/>).

Second, ROI analyses were conducted to examine whether and how AIDS orphans differed from healthy adolescents in the PFC, hippocampus, and amygdala, which were hypothesized to be sensitive to early adversity based on previous studies (e.g., Mehta et al., 2009; Sheridan et al., 2012). All of the ROI masks were derived from Harvard-Oxford subcortical structural atlas available with FSL 4.1 (FMRIB, Oxford, UK; <http://www.fmrib.ox.ac.uk/fsl>) with the threshold set at 50%. Specifically, the PFC consisted of four subdivisions: middle frontal gyrus (MFG), inferior frontal gyrus (IFG), anterior cingulate cortex (ACC), and the orbital frontal cortex (OFC) [36]. The total amygdala and hippocampus volumes were obtained by adding right and left hemisphere. The independent-sample *t*-test was performed to identify differences in the gray-matter volumes of the PFC, amygdala, and hippocampus between AIDS orphans and healthy adolescents.

Third, to confirm the results of ROI analysis and determine which region differed the greatest between the AIDS orphans and controls, we further adopted a whole-brain VBM analysis. Total gray-matter volume, age, and sex were controlled for as confounding covariates. Through the analysis, we first identified clusters of contiguous voxels showing significant differences ($p < 0.005$, uncorrected) and then tested these clusters using cluster-based correction in the entire brain. In the whole-brain correction, the minimum cluster size above which the probability of type I error was < 0.05 was determined by the cluster program in FSL using the Gaussian Random Field theory. Local peak voxels were extracted using FreeROI.

Results

All analyses first reported the unadjusted comparison results of neural structure between AIDS orphans and the control group followed by the results adjusted for covariates such as age and sex. Analyses of the PFC, hippocampus, and amygdala were additionally adjusted for total gray-matter volume.

Total gray-matter volume

The independent-sample *t*-test identified no significant differences in the total gray-matter volume between the AIDS orphans and the control group ($t = -0.78$, $p = 0.439$). After the

addition of age and sex as confounding covariates, the two groups still showed no significant difference in total gray-matter volume ($t = -0.54, p = 0.591$).

Total white-matter volume

The total white-matter volume did not differ significantly between AIDS orphans and adolescents in the control group ($t = -0.49, p = 0.625$). After the adjustment for age and sex, no significant group difference was identified ($t = -0.23, p = 0.822$).

Prefrontal cortex

The PFC was subdivided into the MFG, IFG, ACC, and OFC according to previous studies [36]. The ROI analysis showed no group difference in the gray-matter volume of PFC ($t = 0.07, p = 0.947$), as well as of all the sub-regions (MFG: $t = -1.14, p = 0.261$; IFG pars opercularis: $t = -0.49, p = 0.629$; IFG pars triangularis: $t = -0.68, p = 0.500$; ACC: $t = 1.17, p = 0.250$; OFC: $t = 0.61, p = 0.544$) (Table 1). When controlled for age, sex, and total gray-matter volume, significant group differences were identified in the PFC ($t = 2.49, p = 0.017$) and ACC ($t = 3.21, p = 0.003$), while a marginal difference was found in OFC ($t = 2.01, p = 0.052$). These findings indicated that AIDS orphans have larger gray-matter volume in PFC as well as its sub-regions like the ACC and OFC than adolescents in the control group (Fig 1).

Hippocampus

The gray-matter volumes of the hippocampus (total hippocampus: $t = -2.06, p = 0.046$; left hippocampus: $t = -2.07, p = 0.047$; right hippocampus: $t = -2.00, p = 0.053$) differed between the AIDS orphans and the control group (Table 1). After the control for age, sex, and total gray-matter volume, AIDS orphans still demonstrated significantly smaller gray-matter volume in hippocampus (total hippocampus: $t = -2.16, p = 0.037$; left hippocampus: $t = -2.14, p = 0.039$; right hippocampus: $t = -2.01, p = 0.052$) than adolescents in the control group (Fig 2).

Amygdala

No significant group difference was found in the volume of the amygdala (total amygdala: $t = -1.38, p = 0.174$; left amygdala: $t = -1.67, p = 0.103$; right amygdala: $t = -1.11, p = 0.273$) (Table 1). After the control for age, sex, and total gray-matter volume, AIDS orphans and

Table 1. Mean values and standard deviation for region sizes for the PFC, hippocampus and amygdala.

Structures	AIDS orphan (N = 20)	Control (N = 20)	t	p
PFC				
Middle frontal gyrus	0.46±0.05	0.47±0.04	-1.14	0.261
Orbital frontal cortex	0.53±0.05	0.52±0.04	0.61	0.544
Inferior frontal gyrus (parsopercularis)	0.50±0.05	0.51±0.05	-0.49	0.629
Inferior frontalgyrus (parstriangularis)	0.39±0.05	0.40±0.04	-0.68	0.500
Anterior cingulate cortex	0.58±0.07	0.56±0.04	1.17	0.250
Hippocampus				
Left hippocampus	0.56±0.05	0.59±0.04	-2.06	0.047
Right hippocampus	0.54±0.04	0.57±0.04	-2.00	0.053
Amygdala				
Left amygdala	0.59±0.05	0.61±0.04	-1.67	0.103
Right amygdala	0.58±0.05	0.59±0.04	-1.11	0.273

<https://doi.org/10.1371/journal.pone.0210489.t001>

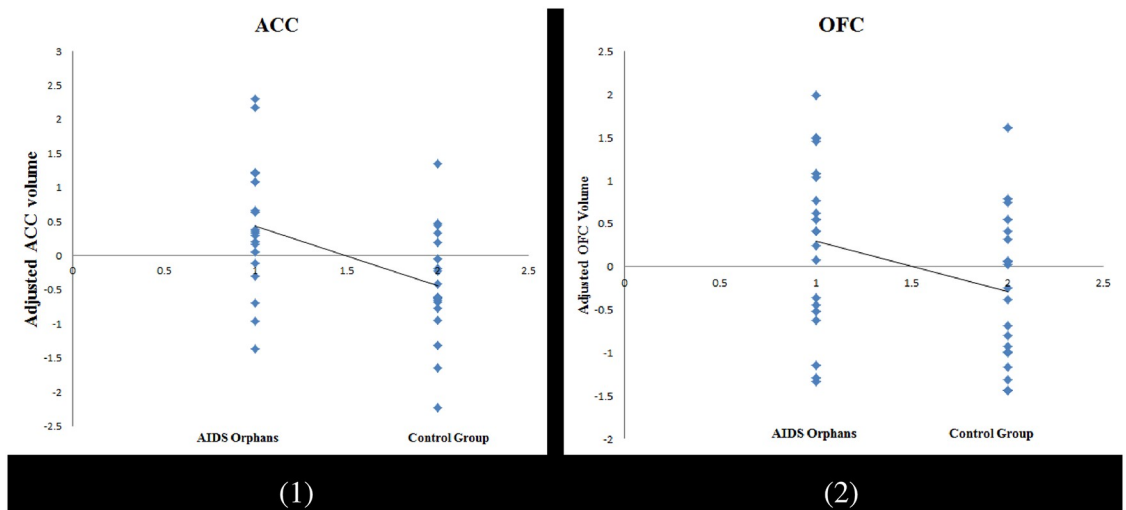


Fig 1. Gray matter volume in sub-regions of PFC, which demonstrating a significant difference between AIDS orphans and normal adolescents (controlled for age, gender, and whole brain gray matter volume, (1) = ACC; (2) = OFC).

<https://doi.org/10.1371/journal.pone.0210489.g001>

adolescents in the control group still showed no difference in gray-matter volume of the amygdala (amygdala: $t = -1.26, p = 0.217$; left amygdala: $t = -1.81, p = 0.080$; right amygdala: $t = -0.75, p = 0.461$).

Whole-brain VBM analysis

To confirm the ROI analysis results and determine which region differed the most between the AIDS orphans and the controls, a whole-brain VBM analysis was conducted. The results suggested that, when compared with adolescents in the control group, AIDS orphans reared in the orphanage exhibited significantly larger gray-matter volumes in the ACC (minimum coordinate: 2, -4, 44; cluster size: 1823; $p = 0.005$, cluster-based correction) (Table 2, Fig 3). This finding was consistent with the results of the ROI analysis conducted in ACC and further indicated that ACC was the largest different region between the AIDS orphans reared in an orphanage and the healthy adolescents.

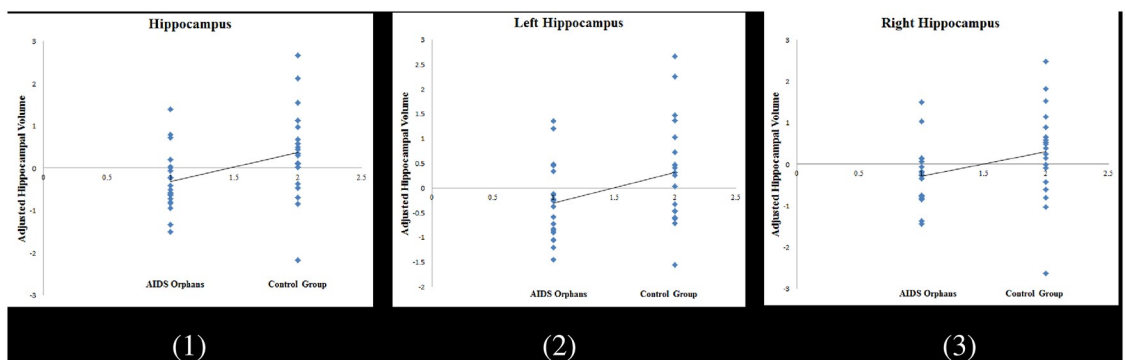


Fig 2. Gray matter volume in the hippocampus, which demonstrating a significant difference between AIDS orphans and normal adolescents (controlled for age, gender, and whole brain gray matter volume, (1) = Total hippocampus; (2) = Left hippocampus; (3) = Right hippocampus).

<https://doi.org/10.1371/journal.pone.0210489.g002>

Table 2. Identified region showing significant group difference and the corresponding anatomical area.

Region	Cluster size	Z-value	MNI coordinate		
			x	y	z
Anterior cingulate gyrus	1823	4.98	2	-4	44

<https://doi.org/10.1371/journal.pone.0210489.t002>

Discussion

In this first volumetric study of the brain in AIDS orphans reared in institutions, we found substantial support for the hypothesis that institutionalized AIDS orphans have structural brain alternations in a previously predicted ROI (PFC and hippocampus) based on previous studies [3, 17, 22]. Specifically, we found no group differences in the volumes of total gray and white matter between the AIDS orphans and the control group. Second, after the correction for age, sex, and total gray-matter volume, ROI analysis showed that AIDS orphans developed smaller hippocampal but larger ACC volumes than healthy adolescents, but no differences was observed in amygdala volumes. Third, the whole-brain analysis showed that the volume difference of the ACC was the largest between the AIDS orphans and the controls. Determining the differences in neural structures between AIDS orphans reared in institutions and those raised in families is an important step in increasing our understanding the mechanisms by which adverse experiences lead to behavioral and psychological deficits and ultimately for developing clinical interventions.

Despite the obvious paucity of structural imaging studies of AIDS orphans reared in institutions, our findings are largely consistent with those of previous studies of individuals suffering from early adversity like poverty, maternal deprivation, and maltreatment, especially with respect to significant reductions in hippocampal volumes (adjusted and unadjusted) [26, 29, 37]. The reason that AIDS orphans have smaller hippocampi may be that the hippocampus contains a high density of glucocorticoid receptors, so it appears particularly susceptible to the deleterious effect of chronic stress created by early adversity [28, 38–40] associated with the AIDS diagnosis and institutional rearing, such as stigma and poverty [7, 8, 11]. Our findings of AIDS orphans reared in institutions replicated previous studies that observed decreased gray-matter volume of the hippocampus in children exposed to other early adversities and suggested that different types of adversity, such as stigma, maternal deprivation, and poverty, might share a common neural pathway when exerting influence on adolescents' health.

Although our findings were inconsistent with those of previous MRI studies that showed reductions of PFC volumes in institutionalized children [41], we found that the largest increase

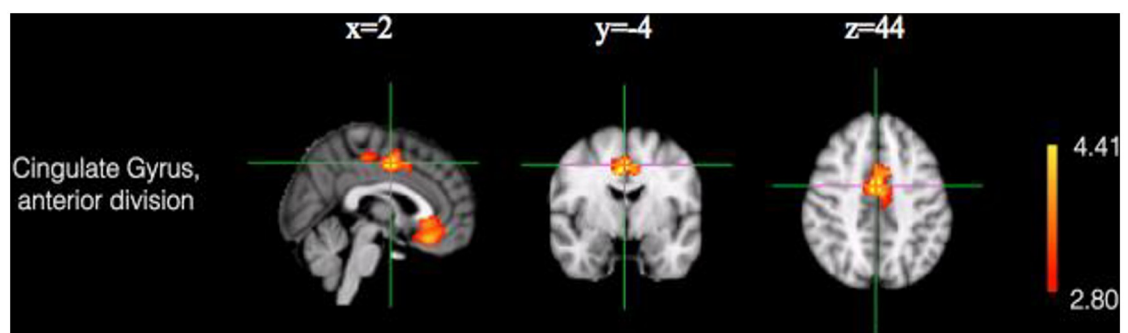


Fig 3. Region demonstrating a significant larger cluster for gray matter volume for AIDS orphans in comparison to the control group (adjusted for total gray matter volume, age and gender; cluster-based correction, $p = 0.005$).

<https://doi.org/10.1371/journal.pone.0210489.g003>

in volume occurs in the PFC (especially the ACC). For example, Hodel et al. (2015) showed that 12–14-year-old post-institutionalized children have significant reductions in PFC volume relative to the comparison group reared in families in the United States. In contrast, another study using VBM found that children (aged 7–14) with a history of interpersonal trauma have larger gray-matter volume of the PFC than do control subjects [25]. Why AIDS orphans developed larger ACC volumes than healthy adolescents is not yet clear, but one possibility is that larger ACC volumes might contribute to AIDS orphans' resilience in adversity. Resilience refers to one's capability to adapt flexibly, persistently, and resourcefully to stressful situations [42]. A recent study revealed that the ACC involves the cognitive regulation to change one's emotional response to stressful events [43–45] that might promote people's resilience to adversity. In particular, there is evidence that people who experience trauma but do not develop PTSD (more resilient people) show greater ACC activity [46], while PTSD patients with larger ACC volume achieve greater treatment gains during psychological therapy [47]. Furthermore, our findings showed that the gray-matter volumes in the dorsal and ventral ACC differed the greatest between AIDS orphans and healthy adolescents. Considering that neuroimaging studies divide the ACC into "cognitive/dorsal" and "affective/rostral" subdivisions [48], the current finding suggests that a larger ACC might contribute to promoting resilience through better cognitive and affective processing of information. To validate this assumption, future studies are needed to investigate whether a larger ACC might guarantee AIDS orphans enhanced resilience to ameliorate their psychological distress. Furthermore, the integration of resilience-based intervention and neuroscience would help uncover which factors played central roles (e.g., self-esteem, optimism, or social support) in the resilience-based interventions targeting adolescents affected by HIV/AIDS and the development of more targeted clinical interventions [12].

In contrast with two previous studies of institutionalized children [17, 49], we found no evidence of altered amygdala volume between AIDS orphans and healthy adolescents, which is consistent with the findings of Hodel et al. (2015). One possibility is that the amygdala is a small region of the brain and particularly difficult to segment using VBM [50]; further improvements in amygdala segmentation may contribute to determining the influences of early adversity on the amygdala structure [22]. Meanwhile, we found no differences in total gray- and white-matter in AIDS orphans relative to healthy adolescents, which was also inconsistent with previous studies (Mehta et al., 2009; Sheridan et al., 2012). One plausible explanation is that the heightened resilience associated with a larger ACC might the gray and white matter of AIDS orphans from the harm of early adversity.

In summary, this study is the first to demonstrate that AIDS orphans reared in institutions developed smaller hippocampal volumes and larger ACC volumes than did healthy adolescents. We acknowledge several limitations of the current study that make its replication in a larger sample set desirable. Considering that the subjects of the orphan and control group were enrolled from different cities in China and had different socioeconomic backgrounds, socioeconomic status is a potential confounder in the current study. To confirm the current findings, it is better to compare AIDS orphans with healthy adolescents from the same area (such as Henan province) in future studies. Meanwhile, because of the current small sample of subjects and our inability to gather the participants' histories of early stressful events, we cannot determine which adversity led to the neural differences between AIDS orphans and healthy adolescents. Therefore, a future strategy will explore whether specific brain changes in AIDS orphans are related to specific types of adversity. For example, whether the experience of being orphaned by AIDS or the institutional rearing led to differential brain alterations remained to be answered. Another limitation to the generalizability of our results is that our sample included only Chinese participants. Moreover, the sample

contained very few subjects. The generalizability of our findings is limited until we learn whether these results are robust across samples with different races and ages. Moreover, fundamental questions regarding the effects of mediators or moderators on brain volume differences in AIDS orphans need to be addressed in future studies. There is also a need to study the differential roles of the hippocampus and PFC in predicting behavioral differences between AIDS orphans and healthy adolescents.

Despite these shortcomings, the finding that AIDS orphanhood was related to a smaller hippocampus and a larger PFC has important research and clinical implications. First, structural changes in certain brain regions may be potential biomarkers for outlining the influence of AIDS orphanhood imposed on children, which reflects individuals' vulnerability to early traumatic experiences. Second, if an intervention could normalize the brain anatomical differences found in AIDS orphans, it may provide valuable clues about how an individual responds to the intervention as well as future research on intervention targeting this population. Based on the current findings, interventions focused on promoting AIDS orphans' resilience may be applicable to mitigate the impacts of early adversity on neurobehavioral development.

Supporting information

S1 File.
(DOC)

S2 File.
(SAV)

Author Contributions

Conceptualization: Yinan Wang, Danhua Lin.

Formal analysis: Yinan Wang.

Investigation: Peiying Zuo.

Resources: Jia Liu, Siyuan Hu, Guoxiang Zhao.

Software: Lijie Huang.

Writing – original draft: Peiying Zuo, Yinan Wang.

References

1. Carpenter LL, Shattuck TT, Tyrka AR, Geraciotti TD, Price LH. Effect of childhood physical abuse on cortisol stress response. *Psychopharmacology*. 2011; 214(1):367–75. <https://doi.org/10.1007/s00213-010-2007-4> PMID: 20838776
2. Yi S, Chhoun P, Brant S, Kita K, Tuot S. Improving Education Opportunity, Health, and Quality of Life of Orphans and Vulnerable Children: The Sustainable Action against HIV and AIDS in Communities (SAHACOM).
3. Chugani HT, Behen ME, Muzik O, Juhász C, Nagy F, Chugani DC. Local brain functional activity following early deprivation: a study of postinstitutionalized Romanian orphans. *Neuroimage*. 2001; 14(6):1290–301. <https://doi.org/10.1006/nimg.2001.0917> PMID: 11707085
4. Richter L. The impact of HIV/AIDS on the development of children. *A generation at risk*. 2004:9–31.
5. Cluver L, Orkin M. Cumulative risk and AIDS-orphanhood: Interactions of stigma, bullying and poverty on child mental health in South Africa. *Social Science & Medicine*. 2009; 69(8):1186–93.
6. Etkin A, Egner T, Kalisch R. Emotional processing in anterior cingulate and medial prefrontal cortex. *Trends in cognitive sciences*. 2011; 15(2):85–93. <https://doi.org/10.1016/j.tics.2010.11.004> PMID: 21167765

7. Chi P, Slatcher RB, Li X, Zhao J, Zhao G, Ren X, et al. Perceived Stigmatization, Resilience, and Diurnal Cortisol Rhythm Among Children of Parents Living With HIV. *Psychological science*. 2015;0956797615572904.
8. Cluver L, Gardner F, Operario D. Effects of stigma on the mental health of adolescents orphaned by AIDS. *Journal of Adolescent Health*. 2008; 42(4):410–7. <https://doi.org/10.1016/j.jadohealth.2007.09.022> PMID: 18346667
9. Li X, Naar-King S, Barnett D, Stanton B, Fang X, Thurston C. A developmental psychopathology framework of the psychosocial needs of children orphaned by HIV. *Journal of the Association of Nurses in AIDS Care*. 2008; 19(2):147–57. <https://doi.org/10.1016/j.jana.2007.08.004> PMID: 18328965
10. Fang X, Li X, Stanton B, Hong Y, Zhang L, Zhao G, et al. Parental HIV/AIDS and psychosocial adjustment among rural Chinese children. *Journal of pediatric psychology*. 2009;jsp006.
11. Chi P, Li X. Impact of parental HIV/AIDS on children's psychological well-being: a systematic review of global literature. *AIDS and Behavior*. 2013; 17(7):2554–74. <https://doi.org/10.1007/s10461-012-0290-2> PMID: 22972606
12. Wang Y, Chen L, Wang X, Bu Y, Liu X, Lin D. Report on the physiological mechanisms linking early adversity and children's development. In: Society CP, editor. *Report on advances in psychology (2016–2017)*. Beijing: Chinese Science and Technology Press; 2018. p. 191–209.
13. Zhao Q, Li X, Fang X, Stanton B, Zhao G, Zhao J, et al. Life improvement, life satisfaction, and care arrangement among AIDS orphans in rural Henan, China. *Journal of the Association of Nurses in AIDS Care*. 2009; 20(2):122–32. <https://doi.org/10.1016/j.jana.2008.09.009> PMID: 19286124
14. Kreppner JM, O'Connor TG, Rutter M, English, Team RAS. Can inattention/overactivity be an institutional deprivation syndrome? *Journal of abnormal child psychology*. 2001; 29(6):513–28. PMID: 11761285
15. Farah MJ, Shera DM, Savage JH, Betancourt L, Giannetta JM, Brodsky NL, et al. Childhood poverty: Specific associations with neurocognitive development. *Brain research*. 2006; 1110(1):166–74. <https://doi.org/10.1016/j.brainres.2006.06.072> PMID: 16879809
16. Brett ZH, Humphreys KL, Fleming AS, Kraemer GW, Drury SS. Using cross-species comparisons and a neurobiological framework to understand early social deprivation effects on behavioral development. *Development and psychopathology*. 2015; 27(02):347–67.
17. Mehta MA, Golembo NI, Nosarti C, Colvert E, Mota A, Williams SC, et al. Amygdala, hippocampal and corpus callosum size following severe early institutional deprivation: the English and Romanian Adoptees study pilot. *Journal of Child Psychology and Psychiatry*. 2009; 50(8):943–51. <https://doi.org/10.1111/j.1469-7610.2009.02084.x> PMID: 19457047
18. Glaser D. Child abuse and neglect and the brain—a review. *Journal of child psychology and psychiatry*. 2000; 41(01):97–116.
19. Sheridan MA, Fox NA, Zeanah CH, McLaughlin KA, Nelson CA. Variation in neural development as a result of exposure to institutionalization early in childhood. *Proceedings of the National Academy of Sciences*. 2012; 109(32):12927–32.
20. Rutter M, Sonuga-Barke EJ. X. Conclusions: overview of findings from the era study, inferences, and research implications. *Monographs of the Society for Research in Child Development*. 2010; 75(1):212–29. <https://doi.org/10.1111/j.1540-5834.2010.00557.x> PMID: 20500640
21. McLaughlin KA, Sheridan MA, Winter W, Fox NA, Zeanah CH, Nelson CA. Widespread reductions in cortical thickness following severe early-life deprivation: a neurodevelopmental pathway to attention-deficit/hyperactivity disorder. *Biological psychiatry*. 2014; 76(8):629–38. <https://doi.org/10.1016/j.biopsych.2013.08.016> PMID: 24090797
22. Hodel AS, Hunt RH, Cowell RA, Van Den Heuvel SE, Gunnar MR, Thomas KM. Duration of early adversity and structural brain development in post-institutionalized adolescents. *NeuroImage*. 2015; 105:112–9. <https://doi.org/10.1016/j.neuroimage.2014.10.020> PMID: 25451478
23. McCrory E, De Brito SA, Viding E. The link between child abuse and psychopathology: a review of neurobiological and genetic research. *Journal of the Royal Society of Medicine*. 2012; 105(4):151–6. <https://doi.org/10.1258/jrsm.2011.110222> PMID: 22532655
24. Richert KA, Carrion VG, Karchemskiy A, Reiss AL. Regional differences of the prefrontal cortex in pediatric PTSD: an MRI study. *Depression and anxiety*. 2006; 23(1):17–25. <https://doi.org/10.1002/da.20131> PMID: 16247760
25. Carrion VG, Weems CF, Watson C, Eliez S, Menon V, Reiss AL. Converging evidence for abnormalities of the prefrontal cortex and evaluation of midsagittal structures in pediatric posttraumatic stress disorder: an MRI study. *Psychiatry Research: Neuroimaging*. 2009; 172(3):226–34. <https://doi.org/10.1016/j.psychresns.2008.07.008> PMID: 19349151

26. Hanson JL, Chandra A, Wolfe BL, Pollak SD. Association between income and the hippocampus. *PloS one*. 2011; 6(5):e18712. <https://doi.org/10.1371/journal.pone.0018712> PMID: 21573231
27. Noble KG, Houston SM, Kan E, Sowell ER. Neural correlates of socioeconomic status in the developing human brain. *Developmental Science*. 2012; 15(4):516–27. <https://doi.org/10.1111/j.1467-7687.2012.01147.x> PMID: 22709401.
28. Avishai-Eliner S, Eghbal-Ahmadi M, Tabachnik E, Brunson KL, Baram TZ. Down-regulation of hypothalamic corticotropin-releasing hormone messenger ribonucleic acid (mRNA) precedes early-life experience-induced changes in hippocampal glucocorticoid receptor mRNA. *Endocrinology*. 2001; 142(1):89–97. <https://doi.org/10.1210/endo.142.1.7917> PMID: 11145570
29. Luby JL, Barch DM, Belden A, Gaffrey MS, Tillman R, Babb C, et al. Maternal support in early childhood predicts larger hippocampal volumes at school age. *Proceedings of the National Academy of Sciences*. 2012; 109(8):2854–9.
30. Tottenham N, Sheridan MA. A review of adversity, the amygdala and the hippocampus: a consideration of developmental timing. *Frontiers in human neuroscience*. 2009; 3.
31. Rametti G, Segarra N, Junqué C, Bargalló N, Caldú X, Ibarretxe N, et al. Left posterior hippocampal density reduction using VBM and stereological MRI procedures in schizophrenia. *Schizophrenia Research*. 2007; 96(1–3):62–71. <https://doi.org/10.1016/j.schres.2007.04.034> PMID: 17604968
32. Bell-McGinty S, Butters MA, Meltzer CC, Greer PJ, Becker JT. Brain morphometric abnormalities in geriatric depression: long-term neurobiological effects of illness duration. *American Journal of Psychiatry*. 2002; 159(8):1424–7. <https://doi.org/10.1176/appi.ajp.159.8.1424> PMID: 12153839
33. Bora E, Fornito A, Pantelis C, Yücel M. Gray matter abnormalities in major depressive disorder: a meta-analysis of voxel based morphometry studies. *Journal of affective disorders*. 2012; 138(1):9–18.
34. Ashburner J, Friston KJ. Unified segmentation. *Neuroimage*. 2005; 26(3):839–51. <https://doi.org/10.1016/j.neuroimage.2005.02.018> PMID: 15955494.
35. Good CD, Johnsrude IS, Ashburner J, Henson RN, Fristen K, Frackowiak RS, editors. A voxel-based morphometric study of ageing in 465 normal adult human brains. *Biomedical Imaging, 2002 5th IEEE EMBS International Summer School on*; 2002: IEEE.
36. Brett ZH, Sheridan M, Humphreys K, Smyke A, Gleason MM, Fox N, et al. A neurogenetics approach to defining differential susceptibility to institutional care. *International journal of behavioral development*. 2014:0165025414538557.
37. Anda RF, Felitti VJ, Bremner JD, Walker JD, Whitfield C, Perry BD, et al. The enduring effects of abuse and related adverse experiences in childhood. *European archives of psychiatry and clinical neuroscience*. 2006; 256(3):174–86. <https://doi.org/10.1007/s00406-005-0624-4> PMID: 16311898
38. Fenoglio KA, Brunson KL, Baram TZ. Hippocampal neuroplasticity induced by early-life stress: functional and molecular aspects. *Front Neuroendocrinol*. 2006; 27(2):180–92. <https://doi.org/10.1016/j.yfrne.2006.02.001> PMID: 16603235
39. Gianaros PJ, Jennings JR, Sheu LK, Greer PJ, Kuller LH, Matthews KA. Prospective reports of chronic life stress predict decreased grey matter volume in the hippocampus. *Neuroimage*. 2007; 35(2):795–803. <https://doi.org/10.1016/j.neuroimage.2006.10.045> PMID: 17275340
40. Plotsky PM, Meaney MJ. Early, postnatal experience alters hypothalamic corticotropin-releasing factor (CRF) mRNA, median eminence CRF content and stress-induced release in adult rats. *Molecular Brain Research*. 1993; 18(3):195–200. PMID: 8497182.
41. McCrory E, De Brito SA, Viding E. The impact of childhood maltreatment: a review of neurobiological and genetic factors. *Frontiers in Psychiatry*. 2011; 2.
42. Connor KM, Davidson JR. Development of a new resilience scale: The Connor-Davidson resilience scale (CD-RISC). *Depression and anxiety*. 2003; 18(2):76–82. <https://doi.org/10.1002/da.10113> PMID: 12964174
43. Ochsner KN, Gross JJ. The cognitive control of emotion. *Trends in cognitive sciences*. 2005; 9(5):242–9. <https://doi.org/10.1016/j.tics.2005.03.010> PMID: 15866151
44. Kong F, Zhen Z, Li J, Huang L, Wang X, Song Y, et al. Sex-related neuroanatomical basis of emotion regulation ability. *PloS one*. 2014; 9(5):e97071. <https://doi.org/10.1371/journal.pone.0097071> PMID: 24835267
45. Vijayakumar N, Whittle S, Yücel M, Dennison M, Simmons J, Allen NB. Thinning of the lateral prefrontal cortex during adolescence predicts emotion regulation in females. *Social cognitive and affective neuroscience*. 2014:nst183.
46. Hughes V. The roots of resilience. *Nature*. 2012; 490(7419):165–7. <https://doi.org/10.1038/490165a> PMID: 23060171

47. Bryant RA, Felmingham K, Whitford TJ, Kemp A, Hughes G, Peduto A, et al. Rostral anterior cingulate volume predicts treatment response to cognitive-behavioural therapy for posttraumatic stress disorder. *Journal of Psychiatry and Neuroscience*. 2008; 33(2):142. PMID: [18330460](#)
48. Bush G, Luu P, Posner MI. Cognitive and emotional influences in anterior cingulate cortex. *Trends in Cognitive Sciences*. 2000; 4(6):215–22. PMID: [10827444](#)
49. Tottenham N, Hare TA, Quinn BT, McCarry TW, Nurse M, Gilhooly T, et al. Prolonged institutional rearing is associated with atypically large amygdala volume and difficulties in emotion regulation. *Developmental science*. 2010; 13(1):46–61. <https://doi.org/10.1111/j.1467-7687.2009.00852.x> PMID: [20121862](#)
50. Morey RA, Petty CM, Xu Y, Hayes JP, Wagner HR, Lewis DV, et al. A comparison of automated segmentation and manual tracing for quantifying hippocampal and amygdala volumes. *Neuroimage*. 2009; 45(3):855–66. <https://doi.org/10.1016/j.neuroimage.2008.12.033> PMID: [19162198](#)