

Assessment of the efficacy of repeated instillations of mitomycin C mixed with a thermosensitive hydrogel in an orthotopic rat bladder cancer model

F. Johannes P. van Valenberg , Dalit Strauss-Ayali, Yael Agmon-Gerstein, Astar Friedman, Harm C. Arentsen, H. Ewout Schaafsma, J. Alfred Witjes and Egbert Oosterwijk

Abstract

Background: We investigated a thermoreversible hydrogel that is highly viscous at body temperature, while fluid-like at a low temperature, thus aiming for a slow and prolonged intravesical drug release. Our study purposed to assess antitumor efficacy of mitomycin C (MMC) mixed with hydrogel in an orthotopic rat bladder cancer model.

Methods: Bladders of female Fischer F344 rats were grafted with 1.5×10^6 AY-27 urothelial carcinoma cells. On day 5, tumor presence was assessed by cystoscopy and rats were divided into six groups (five treatment, one control, $n = 10$ /group). Intravesical treatments (0.5 mg or 1 mg MMC-H₂O or MMC-hydrogel, or 2 mg MMC-hydrogel) were administered on days 5, 8 and 11. Rats were sacrificed at day 14 and bladders were evaluated.

Results: Rats with tumor at cystoscopy (47/60) were evaluated for efficacy. At necropsy, all control animals (8/8) had tumors. No microscopic tumors were present in the 0.5 mg and 1 mg MMC-hydrogel groups compared with 2/8 and 1/8 rats in the 0.5 mg and 1 mg MMC-H₂O groups ($p = 0.47$ and $p = 1.00$, respectively).

Greater toxicity was seen in animals treated with MMC-hydrogel compared with MMC-H₂O, as demonstrated by lower body weights at necropsy ($p = 0.000$) and a tendency for more severe clinical signs in the 1 and 2 mg MMC-hydrogel groups. Rats that died prematurely received 1 mg (4/10) or 2 mg (9/10) of MMC-hydrogel.

Conclusions: Under the current model conditions it is unclear whether instillation of MMC-hydrogel is more effective than MMC-H₂O. Nonetheless, the observed difference in toxicity, acting as a surrogate marker for systemic MMC exposure in the MMC-hydrogel-treated rats, supports the prolonged drug release mechanism of the hydrogel.

Keywords: animal models, bladder cancer, mitomycin C, thermosensitive hydrogel, urinary bladder neoplasms

Received: 5 October 2017; revised manuscript accepted: 2 February 2018.

Introduction

The majority of bladder cancer patients (around 75%) initially present with nonmuscle-invasive bladder cancer (NMIBC). The standard treatment consists of a transurethral resection, followed by adjuvant intravesical chemo- or immunotherapy. The exact scheme depends on the patient's risk category of recurrence and progression.¹

The high recurrence and progression rates^{2,3} necessitate a high frequency of follow up and consequent treatments, imposing a significant financial and logistic burden to the patient and to the healthcare system. This underlines the need for improved treatment, either replacing transurethral resection or as a neoadjuvant or adjuvant treatment.

Ther Adv Urol

2018, Vol. 10(7) 213–221

DOI: 10.1177/
1756287218762064

© The Author(s), 2018.



Reprints and permissions:
[http://www.sagepub.co.uk/
journalsPermissions.nav](http://www.sagepub.co.uk/journalsPermissions.nav)

Correspondence to:

F. Johannes P. van Valenberg
Department of Urology,
Radboud University
Medical Center, Geert
Grooteplein 26–28 (2677),
PO Box 9101, 6500
HB Nijmegen, The
Netherlands
[hans.vanvalenberg@
radboudumc.nl](mailto:hans.vanvalenberg@radboudumc.nl)

Dalit Strauss-Ayali
Yael Agmon-Gerstein
Astar Friedman
UroGen Pharma Ltd.,
Ra'anana, Israel

Harm C. Arentsen
AZ Sint-Jan Hospital
Brugge-Oostende, Bruges,
Belgium

H. Ewout Schaafsma
Department of Pathology,
Radboud University
Medical Center, Nijmegen,
The Netherlands

J. Alfred Witjes
Egbert Oosterwijk
Department of Urology,
Radboud University
Medical Center, Nijmegen,
The Netherlands

A thermosensitive drug retention system was developed for the delivery of various therapeutic agents into body internal cavities. This system consists of a biocompatible sterile hydrogel which has high viscosity (gel state) at body temperature and low viscosity (liquid state) at a lower temperature. The liquid state enables the mixing of the hydrogel with a specific drug, such as mitomycin C (MMC), and facilitates delivery through a catheter into the bladder. The solid state enables an extended dwell time of the hydrogel mixed with the drug and hence a prolonged exposure of the bladder tissue to MMC with possibly a higher efficacy.

Typically, water-dissolved MMC is maintained intravesically for as long as the patient can refrain from urinating. The patient's urge of urination, which might be increased in response to irritation by MMC, limits the exposure time to the drug. Moreover, drug concentration is reduced due to continuous urine production. Prolonged exposure of the tumor to MMC might be more effective and previous studies have shown that increased dwell time of MMC can significantly increase MMC efficacy *in vitro* and *in vivo*.^{4,5}

In a limited number of preclinical studies with hydrogels, all with different physical characteristics,^{6–12} materials were combined with nanoparticles,^{6,12} epirubicin,⁷ doxorubicin¹⁰ and bacillus Calmette-Guérin (BCG).¹¹ These studies suggested prolonged exposure or enhanced drug penetration.^{6,7,11,12} The two studies evaluating a thermosensitive hydrogel different from our thermosensitive hydrogel, suggested higher antitumor efficacy based on prolonged drug exposure and increased drug concentrations^{6,7,11} or stronger immune response if combined with BCG¹¹ as compared with standard drug instillations. We therefore hypothesized that our thermosensitive MMC-hydrogel combination will enable longer exposure of the drug to the bladder wall and will consequently result in a deeper MMC penetration and a better oncologic outcome *versus* standard MMC instillations in water.

The aim of our study was to evaluate the efficacy of repeated instillations of MMC mixed with the thermosensitive hydrogel *versus* repeated instillations of MMC in water in an orthotopic AY-27 rat bladder cancer model.

Methods

To our knowledge, no studies on any hydrogel in bladder cancer patients have been published. Since no tumor models are available in pigs and a good preclinical rat model exists, we chose to use the previously described orthotopic AY-27 rat bladder cancer model.^{13–15}

Animals

Animal procedures were approved by the Institutional Animal Care and Use Committee (IACUC, Radboud University Medical Center, Nijmegen, The Netherlands) and in compliance with European regulations. In total, 60 female Fischer F344 rats (Charles River Laboratories B.V., Leiden, The Netherlands) weighing 132–164 g were housed in shared type 3 individually ventilated cages (Bleuline series, Techniplast, Milan, Italy) with paper bedding (SPPS, Frasné, France) and environmental enrichment (2–3 rats/cage), in a temperature controlled environment (19–22°C) with a 12-h light/dark cycle and free access to standard chow and water. After treatment allocation, animals were housed according to their treatment group to prevent cross-contamination of MMC. General wellbeing, weight and clinical signs for humane endpoints were monitored.

Tumor cell line

The AY-27 urothelial carcinoma cell line was established previously.¹³ The AY-27 cells were grown as a monolayer culture in RPMI-1640 medium with L-glutamine, supplemented with 10% fetal bovine serum, 100 U/ml penicillin G, and 100 µg/ml streptomycin at 37°C in a humidified 95% air/5% carbon dioxide atmosphere. Cells were passaged using trypsin/0.05% ethyl-enediaminetetraacetic acid (Life Technologies, Bleiswijk, The Netherlands).

Tumor cell implantation

The instillation procedure was performed as described previously.^{13,16} All procedures were performed under inhalation anesthesia. The rat bladder was catheterized with a 17-gauge intravenous cannula (BD Biosystems, Erembodegem-Aalst, Belgium) and drained. The bladder was preconditioned by instillation of 0.4 ml 0.1 M hydrochloride for 15 s followed by 0.4 ml 0.1 M potassium hydroxide for 15 s. The bladder was drained and

flushed three times with 0.8 ml 0.01 M phosphate-buffered saline. Freshly harvested AY-27 cells (1.5×10^6 cells in 0.5 ml medium, time between cell harvest and bladder inoculation <1 h) were directly instilled *via* the catheter and left indwelling for 60 min. In order to distribute the cells homogeneously over the stripped bladder wall, animals were rotated every 15 min. After 1 h the catheter was removed and rats were allowed to void spontaneously.

Tumor assessment

Previous studies have demonstrated tumor growth in approximately 80% of the animals 5 days after tumor cell implantation.^{14–16} To prevent uneven distribution of animals with differently sized tumors or without any tumor growth at all, macroscopic tumor growth was assessed by cystoscopy prior to the first treatment at day 5. A semi-flexible sialo-endoscope (Erlangen, Karl Storz, Tuttlingen, Germany) with a 1.1 mm diameter, 10 cm length, and miniature 0° telescope with working and irrigation channel was used. The bladder surface was inspected, and a video record and images were taken using TELE PACK VET X (Karl Storz, Tuttlingen, Germany). Animals were allocated evenly in between treatment groups according to their tumor burden.

Test agents

The thermosensitive hydrogel (TC-3 sterile hydrogel) and MMC in mannitol (Accord Healthcare, Durham, NC, USA) were supplied by UroGen Pharma Ltd. (Ra'anana, Israel). Dosages were calculated based on the rat bladder instillation volume and bladder surface compared with the human values, resulting in a respective ratio of 106.7 and 22.5. These ratios resulted in a respective 40 mg human dose-equivalent of 0.375–1.78 mg in rats. Based on the latter, the chosen low dose in the current study was 0.5 mg.

Prior to each instillation, solutions were prepared after liquidation in ice, and were stored protected from light at room temperature. For the MMC-H₂O groups, MMC in mannitol was dissolved as per the manufacturer's instruction in sterile water to result in a similar osmolality as the saline control group.

Experimental groups

The estimated response rate to MMC was 60–70%. We choose an $\alpha = 0.05$ and a power of

80%, resulting in a C value of 7.85. Thus, the number of animals to be tested was given by (for continuous variables of studies comparing two means): $n = 1 + 2C (s/d)^2$, where $s/d = 0.65$ (mean between 60–70% response rate).

This results in a number of animals needed per treatment group of $1 + 2 \times 7.85 \times (0.65)^2 = 7.6$ animals. Thus, eight tumor-positive animals per group were needed. To correct for the tumor take of 80% at 5 days after tumor cell implantation, a factor of 1.25 had to be applied to the amount of tumor-bearing animals to calculate the total amount of animals per group. Thus, 10 animals per group were included.

Rats were treated with a volume of 0.6 ml of test agent. Bladder instillations were given on days 5, 8 and 11 after cell inoculation, using an 18 or 22-gauge intravenous cannula (BD Biosystems, Erembodegem-Aalst, Belgium), which depended on the ease of catheterization. During 12 min, rats underwent 90° position changes every 4 min. Subsequently, the catheter was removed and the rats were allowed to void spontaneously. Water was withheld for 4 h post-instillation.

The time points were chosen based on our experience with the orthotopic bladder cancer rat model.^{15,16} It was previously shown that 3–5 days after tumor cell inoculation 80% of the rats will be tumor-bearing and tumors generally are nonmuscle invasive.¹⁵ After 5 days, tumors tend to grow into the detrusor muscle. Moreover, 5 days post tumor implantation the urothelium barrier will have had sufficient time to recover from the aggressive preconditioning with HCl for tumor cell implantation. Therefore, the first treatment was set on day 5. Additionally, the maximum acceptable humane endpoint time in this bladder cancer model is around 17 days.¹⁵ To prevent death due to aggressive tumor growth, 14 days after inoculation was chosen as the end-of-experiment time point for both ethical and methodological considerations. We chose to perform three instillations with equal intervals within this time frame of 5–14 days after tumor cell inoculation, resulting in 2-day intervals and additional instillations at days 8 and 11.

Treatment groups consisted of: (a) NaCl 0.9% as control, (b) 0.5 mg MMC-H₂O (0.833 mg/ml), (c) 1 mg MMC-H₂O (1.67 mg/ml), (d) 0.5 mg MMC-hydrogel (0.833 mg/ml), (e) 1 mg MMC-hydrogel (1.67 mg/ml), and (f) 2 mg MMC-hydrogel (3.34 mg/ml). The latter group was added since lower

MMC availability could have been a possible scenario for the hydrogel groups and thus it was expected that in such case a higher concentration of MMC in hydrogel would be needed to reach the equivalent mucosal concentration and efficacy as compared with MMC administered in H₂O. A control group with hydrogel only was not included, since previous *in vivo* models have shown good biocompatibility of hydrogel in pigs: no toxicity was observed after hydrogel only in two previous *in vivo* safety studies in the porcine upper urinary tract.^{8,9} These studies report no mortality, clinical adverse events, nor meaningful changes in hematology with either MMC-hydrogel, hydrogel alone,^{8,9} or saline.⁹ The levels of leucocytes, platelets and the hematocrit after hydrogel alone were similar to the sterile water group⁹ or low dose MMC-hydrogel groups.⁸ All animals from the different groups gained weight at approximately similar rates over the 3 or 6-week dosing schedule.^{8,9} In view of the available evidence and in line with the 3R principles no hydrogel-alone group was included, thus saving animals.^{8,9}

To prevent dehydration, animals received wet food when indicated. In reaction to unanticipated signs of dehydration, rats from groups e and f were given 2 ml of NaCl 0.9% subcutaneously twice daily from their second treatment and onwards to prevent and treat dehydration. No such signs were observed in the MMC-H₂O groups.

Blood samples from a subset of rats [$n = 5$ (groups c–e); $n = 4$ (groups a–b); $n = 3$ (group F)] were collected to assess myelosuppression as a possible sign of systemic MMC toxicity after clinical toxicity was observed in some of the first rats.

Necropsy

At day 14, surviving rats were sacrificed by carbon dioxide inhalation and necropsy was performed. Bladders were harvested for histopathologic examination, as were any other macroscopically abnormal tissues. Animals that died prior to scheduled necropsy were identically evaluated. Bladder tissue was weighed, fixed and embedded in paraffin. A total of three sections of 4–5 μm were cut and stained with Haematoxylin-Eosin. Pathologic outcome assessment was blinded. A total of two observers (HES, specialized urologist, and FJPvV) evaluated tumor presence, including the number of tumors, tumor size, stage, and grade. The bladder wall thickness was measured at ≥ 1 mm distance of any present tumor. Inflammation

and presence of epithelial atypia were quantified and graded as: no reaction, mild, moderate or severe reaction. Additionally, presence of hyperplasia, denudation, fibrosis, necrosis, edema, or hemorrhage was assessed.

Statistics

Fisher's exact test was used to compare the treatment effect on tumor presence (i.e. for comparing proportions). Independent student's *t* test was used to compare means if a single comparison was made. Comparison of multiple means was performed by one-way analysis of variance (ANOVA) with post-hoc analysis (Tukey HSD or Tamhane, depending on assumption of homogeneity of variances).

All analyses were performed using SPSS software, version 20, with a two-sided $p < 0.05$ considered statistically significant.

Results

Tumor take

At 5 days after cell seeding, cystoscopy revealed tumors in 78% (47/60) of rats (Figure 1). After distribution between the different treatment groups, all groups contained 8/10 rats with cystoscopy-identified tumors, except for the 0.5 mg MMC-hydrogel group which contained 7/10 tumor-bearing rats. A large diversity of lesions was observed on cystoscopy, ranging from 1 or 2 small lesions to more than five small lesions (< 0.5 mm) or even big lesions (> 2.5 mm) per animal. No stone formation or inflammation was identified in any of the rats.

Efficacy

Rats with cystoscopy-identified tumor presence ($n = 47$) were used for the efficacy analysis.

Tumor frequency, stage and grade are shown in Table 1. All cystoscopy tumor-positive animals from the untreated control group had confirmed tumor presence at necropsy (8/8). A total of three tumors were detected in the MMC-H₂O treated groups (b: 2/8; c: 1/8), while no tumors were detected in the identical dose MMC-hydrogel treatment groups (d: 0/7; e: 0/8). Comparison of the number of tumor-positive animals between the same MMC dosage in water *versus* MMC-hydrogel did not reveal a significant difference (p

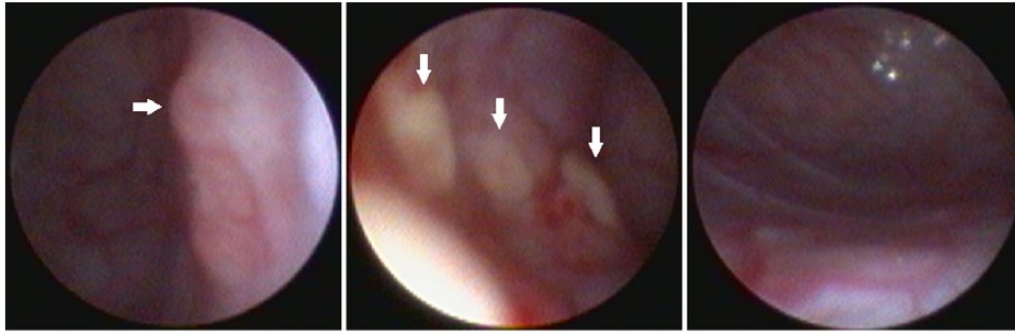


Figure 1. Tumor take as judged on cystoscopy.

Overall, three images are depicted with a solitary tumor (left image, arrow), multiple tumors (center image, arrows), and no tumor on cystoscopy (right image).

Table 1. Number of rats with tumors found on microscopic evaluation.

Group	MMC dosage (mg)	Vehicle	No. of rats with tumor (n/group size)	T stage [†]
a	0	NaCl 0.9%	8/8	T2 (4/8), T3a (4/8)
b	0.5	H ₂ O	2/8	T2 (2/2)
c	1.0	H ₂ O	1/8	T1 (1/1)
d	0.5	Hydrogel	0/7*	NA
e	1.0	Hydrogel	0/8**; ‡	NA
f	2.0	Hydrogel	2/8 ¶	T1 (1/8), T2 (1/8)

MMC, mitomycin C; NA, not applicable.
 *Fisher exact test for comparison of the 0.5 mg MMC dose in H₂O and hydrogel groups: $p = 0.467$.
 **Fisher exact test for comparison of the 1 mg MMC dose in H₂O and hydrogel groups: $p = 1.000$.
 †All tumors found on microscopy ($n = 13$) were grade 3 (high grade) transitional cell carcinomas.
 ‡Three rats were killed before the predetermined endpoint as they reached a predefined humane endpoint: day 12 ($n = 1$) and day 13 ($n = 2$). In addition, one rat was found dead at day 13.
 ¶Five rats were killed before the predetermined endpoint as they reached a predefined humane endpoint: day 12 ($n = 1$) and day 13 ($n = 4$). In addition, at day 10 one rat was found dead after completing 2/3 treatments only, and three rats were found dead at day 13.

= 0.47 for 0.5 mg MMC, $p = 1.00$ for 1 mg MMC). In two rats treated with 2 mg MMC-hydrogel, tumors were found (2/8). Of these animals, one did not receive the third treatment since it was euthanized on day 10 due to severe clinical signs, whereas the other was similarly euthanized at day 13. No metastasis was observed during gross examination at the day of necropsy.

Histopathology

The mean bladder weight of rats treated with MMC-H₂O (combined groups b + c) was significantly lower compared with the bladder weight of rats treated with MMC-hydrogel in the same concentrations (combined groups d + e) (mean 0.221 g versus 0.266 g, $p = 0.01$). No significant

differences were seen between the treatment groups regarding the presence of epithelial atypia, hyperplasia, denudation, inflammation, fibrosis or necrosis. Epithelial atypia was considered as being reactive atypia to MMC exposure, not as carcinoma *in situ*. None of the rats in the control group ($n = 10$) had epithelial atypia. A gradual increase in bladder wall thickness was seen with increasing MMC dose, independent of the vehicle used. None of the bladders showed signs of perforation. Hemorrhage was seen in 23 rats and was abundant in group f (9/10).

Animal wellbeing

Animal weights decreased significantly during treatments [Figure 2(a)], with MMC treatment

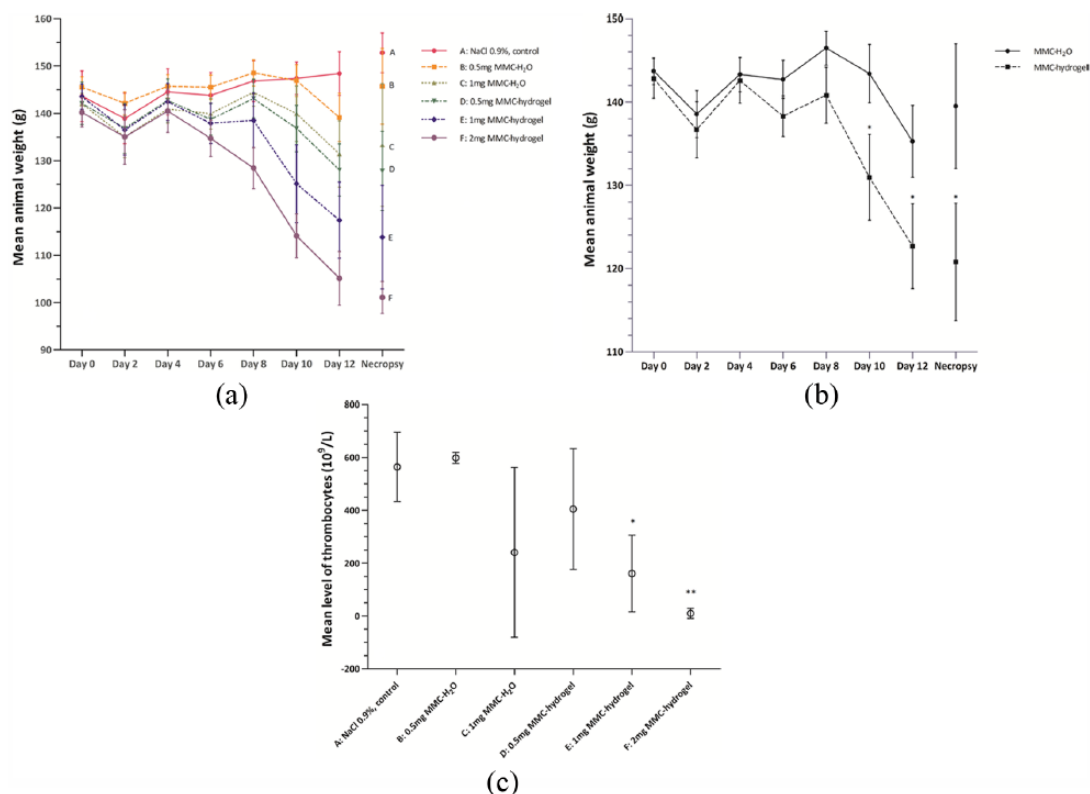


Figure 2. Toxicity in the different treatment groups.

All error bars represent 95% confidence intervals. (a) mean animal weight per treatment group, (b) mean animal weight of MMC-H₂O (groups b + c) versus MMC-hydrogel (groups d + e) treated rats (*, $p < 0.05$), (c) dot plot of the mean level of thrombocytes per group (*, $p = 0.001$; **, $p = 0.000$ compared with control). The number of animals evaluated in figure (c): groups a, b; $n = 4$, groups c–e; $n = 5$, group f; $n = 3$. MMC, mitomycin C.

leading to a dose-dependent significant lower body weight [mean body weight at necropsy 153 g (group a) versus 124 g (groups b–f), $p = 0.000$]. When MMC-hydrogel was administered (groups d + e), animal weight decreased significantly compared with MMC-H₂O (groups b + c) [Figure 2(b); mean weight at necropsy 140 g versus 121 g, $p = 0.000$].

A total of eight rats were killed prematurely because they reached the predefined humane endpoints (i.e. weight loss of $>20\%$ of weight at start, or clinical signs of failure to thrive); five rats were found dead (Table 1). At necropsy, non-hematologic changes were observed in seven rats and included a dilated ureter or kidney ($n = 3$), pelvic inflammation ($n = 2$), microscopic interstitial hemorrhage ($n = 2$), and intestinal necrosis ($n = 3$, all found dead without known time of death). These effects were equally seen in the MMC-H₂O and MMC-hydrogel treated groups. Thus, they were most likely model-related and might have been due to the frequent invasive

therapeutic procedures, transient obstruction or reflux of the instilled fluid into the upper urinary tract, or due to the MMC instillation itself. Although pelvic inflammation and intestinal necrosis might be signs of bladder perforation, no signs of perforation were found on pathologic assessment of the bladders.

A reluctance to consume food and water was noticed in all rats receiving MMC-hydrogel from day 11 onwards. Clinical signs seemed to be more severe at higher MMC doses or when MMC-hydrogel was used and were typical for MMC-induced effects. No adverse events were observed in the saline control group.

The mean number of erythrocytes, leucocytes and amount of hemoglobin was not significantly different between treatment groups (one-way ANOVA $p > 0.05$ in all), although a trend for lower levels in the hydrogel group was observed. However, mean thrombocyte count differed significantly between control and the higher dose

MMC-hydrogel treated rats (for respectively group e and f: mean $564 \times 10^9/l$ versus $161 \times 10^9/l$, $p = 0.001$; and $564 \times 10^9/l$ versus $9.3 \times 10^9/l$, $p = 0.000$;) [Figure 2(c)]. Consequently, systemic MMC-induced myelosuppression was assumed.

Discussion

We hypothesized that extended release of MMC from a thermosensitive hydrogel would lead to higher cure rates in this orthotopic bladder cancer rat model. Treatment was highly effective in all the animals treated with MMC, both with and without hydrogel, regardless of the MMC dose used. No significant difference in efficacy was found following treatment of MMC-hydrogel versus MMC-H₂O. The reason for the high efficacy regardless of the vehicle used may be the high administered MMC concentrations. However, we did observe more systemic toxicity in the animals treated with MMC-hydrogel compared with MMC-H₂O, especially at the higher MMC dosages. MMC-hydrogel treatment resulted in significantly lower thrombocyte levels in the 1 mg and 2 mg MMC-hydrogel groups compared with the saline control group, accompanied by a significantly lower body weight at necropsy. Body weight was also significantly lower when MMC-hydrogel was compared with MMC-H₂O. All rats that died prior to necropsy belonged to the 1 mg and 2 mg MMC-hydrogel groups. The enhanced toxicity in animals treated with MMC-hydrogel is possibly caused by the longer intravesical drug residence time, leading to extended MMC exposure locally and systemically. Due to the slow dissolution of the MMC-containing hydrogel, the bladder mucosa is exposed to MMC for as long as the gel is not fully dissolved and removed from the bladder through micturition (an estimated period of 1–3 h in rats, data not shown). We hypothesize that the prolonged exposure of the mucosa to MMC resulted in significantly higher levels of systemic MMC in rats and eventually in myelosuppression causing the clinical signs, weight loss and preliminary death, acting as a surrogate biomarker for MMC exposure. Thus, despite our failure to show higher efficacy, our results suggest that encapsulation of MMC in this hydrogel results in increased MMC tissue exposure.

Remarkably, prolonged exposure to similar or considerably higher concentrations of MMC-hydrogel of the renal pelvis in other animals (up to 8 mg/ml in pigs)^{8,9} or bladder mucosa in

NMIBC patients (conference abstract¹⁷), did not result in enhanced systemic toxicity. Moreover, plasma MMC levels were low and several orders of magnitude below levels known to be associated with systemic toxicity.¹⁸ This suggests that MMC-related toxicity may be species specific. Indeed, Vandepitte and colleagues reported that rats are more sensitive to MMC.¹⁹ In the same orthotopic rat bladder tumor model as used in our study, rats were treated with either a single instillation of 1 mM MMC (0.334 mg/ml) or 10 mM MMC (3.34 mg/ml) for 2 h one day after tumor cell implantation. From the five rats treated with 10 mM MMC, a concentration identical to our highest MMC dose group, none survived more than 7 days, most likely due to a systemic toxic effect of the MMC.¹⁹ Although a single instillation was given, MMC remained longer intravesically, and the interval between mucosa preconditioning with HCl and treatment was much shorter compared with our treatment schedule. As the barrier function of the urothelium is impaired after preconditioning, this could have contributed to the observed systemic MMC toxicity in their experiment. We have allowed the urothelium to recover for 5 days, and administered three treatments with the highest dose (3.34 mg/ml MMC) which might have been a too intense dosing schedule for the already thin rat bladder wall. In line with the presumed prolonged MMC exposure, the increased bladder wall contact time might explain the increased bladder weight secondary to any local irritation, inflammation, edema, fibrosis, or potential immune-stimulatory effects of the MMC-hydrogel.

No direct data such as plasma and tissue concentrations of MMC are available to support our suggestion that the higher toxicity observed in the MMC-hydrogel group is a consequence of prolonged exposure to MMC. This enhanced toxicity was unanticipated. As such, no blood or tissue samples for assessment of MMC concentrations were collected since our primary goal was to evaluate efficacy. However, indirect evidence is highly suggestive: all observed toxicity and clinical symptoms were typical for MMC-induced effects. The thrombocyte levels decreased, animals experienced severe weight loss, and animals died prematurely in the MMC-hydrogel groups. This toxicity appeared to be dose-dependent within the different vehicles, which was in accordance with previous porcine models.^{8,9} Any procedural influence on the toxicity (e.g. catheterization, instillation) is unlikely in view of the saline

control group and by previous studies using the same methodology.^{14–16,19} Perforation or excessive inflammatory response was excluded by extensive pathologic assessment of the bladders. Thus, the remaining factor for explaining the observed premature deaths, weight loss, and toxicity in the MMC-hydrogel groups is an increased bladder wall contact time with MMC leading to a too high systemic exposure of MMC with our chosen concentration of MMC.

The conditions in this model seem suboptimal to investigate whether this new treatment of urothelial carcinoma was superior. This may have been caused by: (1) use of a too high dose of MMC resulting in only few tumors present at necropsy in both the MMC-hydrogel and, specifically, MMC-H₂O groups to demonstrate a potential difference in efficacy, (2) a too high treatment frequency and too small intervals between treatments that prevented sufficient recovery of animals following each treatment (typically, an induction course in humans consists of six treatments weekly), or (3) a too low animal weight at study onset, associated with a small bladder size, and possibly with a relatively too high instillation volume of the hydrogel which might have led to volumetric obstruction. In previous *in vivo* safety studies, no toxicity was observed after hydrogel instillation in the porcine upper urinary tract.^{8,9} Based on these observations and in line with the 3R principle, a hydrogel-alone group was not included in the present study. Nevertheless, the collective evidence suggests that direct and indirect effects on the bladder wall are likely a consequence of MMC and not of the hydrogel.

In conclusion, a prolonged exposure of the tumor to the drug-containing hydrogel is suggested by the observed enhanced toxicity, acting as a surrogate marker for MMC exposure. Treatment with the tested doses of intravesical MMC using either vehicle was highly effective, although the MMC-hydrogel was toxic to rats at the levels administered. Whether MMC-hydrogel is more efficacious than MMC-H₂O could not be determined due to too high MMC dosing and low tumor frequencies following either treatment. We hypothesize that in light of a prolonged exposure, the hydrogel might maintain or ideally even improve treatment efficacy in rats compared with aqueous MMC when lower doses of drug are used. This might create opportunities in the treatment of bladder or, especially, upper urinary tract urothelial carcinomas,

where instillations are suboptimal due to the swift washout of the instilled fluid. However, confirmation of improved or similar efficacy together with similar or decreased toxicity of lower dosed MMC-hydrogel is needed.

Acknowledgements

We would like to thank Bianca Lemmers-van de Weem and Kitty Lemmens-Hermans for their support during the experiment implementation, and Mirjam de Weijert for her biotechnical support.


Funding

This study was supported by UroGen Pharma Ltd., Israel.

Conflict of interest statement

F. J. P. van Valenberg, H. C. Arentsen, H. E. Schaafsma, J. A. Witjes, and E. Oosterwijk have no financial disclosures or conflicts of interest to declare other than the financial support of this study. D. Strauss-Ayali, Y. Agmon-Gerstein, and A. Friedman are employees of UroGen Pharma Ltd.

ORCID iD


F. Johannes P. van Valenberg  <https://orcid.org/0000-0003-1663-1192>

References

1. Babjuk M, Böhle A, Burger M, *et al.* EAU guidelines on non-muscle-invasive urothelial carcinoma of the bladder: update 2016. *Eur Urol* 2017; 71: 447–461.
2. Fernandez-Gomez J, Madero R, Solsona E, *et al.* The EORTC tables overestimate the risk of recurrence and progression in patients with non-muscle-invasive bladder cancer treated with bacillus Calmette-Guérin: external validation of the EORTC risk tables. *Eur Urol* 2011; 60: 423–430.
3. Cambier S, Sylvester RJ, Collette L, *et al.* EORTC nomograms and risk groups for predicting recurrence, progression, and disease-specific and overall survival in non-muscle-invasive stage Ta-T1 urothelial bladder cancer patients treated with 1–3 years of maintenance bacillus Calmette-Guérin. *Eur Urol* 2016; 69: 60–69.
4. Schmittgen TD, Wientjes MG, Badalament RA, *et al.* Pharmacodynamics of mitomycin C in cultured human bladder tumors. *Cancer Res* 1991; 51: 3849–3856.

5. De Bruijn EA, Sleetboom HP, van Helsdingen PJ, *et al.* Pharmacodynamics and pharmacokinetics of intravesical mitomycin C upon different dwelling times. *Int J Cancer* 1992; 51: 359–364.
6. GuhaSarkar S, More P and Banerjee R. Urothelium-adherent, ion-triggered liposome-in-gel system as a platform for intravesical drug delivery. *J Control Release* 2017; 245: 147–156.
7. Liu CW, Wu YT, Lin KJ, *et al.* A Hydrogel-Based Epirubicin Delivery System for Intravesical Chemotherapy. *Molecules* 2016; 21: pii: E712.
8. Donin NM, Duarte S, Lenis AT, *et al.* Sustained-release formulation of mitomycin C to the upper urinary tract using a thermosensitive polymer: a preclinical study. *Urology* 2017; 99: 270–277.
9. Donin NM, Strauss-Ayali D, Agmon-Gerstein Y, *et al.* Serial retrograde instillations of sustained release formulation of mitomycin C to the upper urinary tract of the Yorkshire swine using a thermosensitive polymer: safety and feasibility. *Urol Oncol* 2017; 35: 272–278.
10. Lin T, Zhang Y, Wu J, *et al.* A floating hydrogel system capable of generating CO₂ bubbles to diminish urinary obstruction after intravesical instillation. *Pharm Res* 2014; 31: 2655–2663.
11. Zhang D, Sun P, Li P, *et al.* A magnetic chitosan hydrogel for sustained and prolonged delivery of Bacillus Calmette-Guerin in the treatment of bladder cancer. *Biomaterials* 2013; 34: 10258–10266.
12. Men K, Liu W, Li L, *et al.* Delivering instilled hydrophobic drug to the bladder by a cationic nanoparticle and thermo-sensitive hydrogel composite system. *Nanoscale* 2012; 4: 6425–6433.
13. Xiao Z, McCallum TJ, Brown KM, *et al.* Characterization of a novel transplantable orthotopic rat bladder transitional cell tumour model. *Br J Cancer* 1999; 81: 638–646.
14. Arentsen HC, Hendricksen K, Oosterwijk E, *et al.* Experimental rat bladder urothelial cell carcinoma models. *World J Urol* 2009; 27: 313–317.
15. Hendricksen K, Molkenboer-Kuennen J, Oosterwijk E, *et al.* Evaluation of an orthotopic rat bladder urothelial cell carcinoma model by cystoscopy. *BJU Int* 2008; 101: 889–893.
16. Arentsen HC, Hendricksen K, Hulsbergen-van de, Kaa CA, *et al.* The orthotopic Fischer/AY-27 rat bladder urothelial cell carcinoma model to test the efficacy of different apaziquone formulations. *Urol Oncol* 2012; 30: 64–68.
17. Friedman B, Dekel Y, Tubaro A, *et al.* The chemoablative effect of VesiGel® instillation in patients with NMIBC – preliminary results. *J Urol* 2016; 95: e289–e290.
18. Crooke ST, Henderson M, Samson M, *et al.* Phase I study of oral mitomycin C. *Cancer Treat Rep* 1976; 60: 1633–1636.
19. Vandepitte J, Maes J, Van Cleynenbreugel B, *et al.* An improved orthotopic rat bladder tumor model using Dil-loaded fluorescent AY-27 cells. *Cancer Biol Therapy* 2010; 9: 986–993.

Visit SAGE journals online
[journals.sagepub.com/
home/tau](http://journals.sagepub.com/home/tau)

 SAGE journals