

## Case Report

## Chronic Localized Back Pain Due to Posterior Cutaneous Nerve Entrapment Syndrome (POCNES): A New Diagnosis

Oliver B. Boelens, MD<sup>1</sup>, Robert C. Maatman, BSc<sup>2</sup>, Marc R. Scheltinga, MD<sup>2</sup>,  
Kees van Laarhoven, MD, PhD<sup>3</sup>, and Rudi M. Roumen MD, PhD<sup>2</sup>

From: <sup>1</sup>Dept of Surgery, Maasziekenhuis Pantein, Boxmeer, The Netherlands; <sup>2</sup>SolviMáx Center of Excellence for Abdominal Wall and Groin Pain and Dept. of Surgery, Máxima Medical Center, Eindhoven/Veldhoven, The Netherlands; <sup>3</sup>Dept. of Surgery, Radboud University Medical Centre, Nijmegen, The Netherlands

Address Correspondence:  
Oliver Boelens, MD, PhD  
Maasziekenhuis Pantein  
Doktor Kopstraat 1  
5835 DV Beugen, Netherlands  
E-mail: o.boelens@gmail.com

Disclaimer: There was no external funding in the preparation of this manuscript.

Conflict of interest: Each author certifies that he or she, or a member of his or her immediate family, has no commercial association (i.e., consultancies, stock ownership, equity interest, patent/licensing arrangements, etc.) that might pose a conflict of interest in connection with the submitted manuscript.

Manuscript received: 01-26-2016

Revised manuscript received:

04-21-2016

Accepted for publication:

04-29-2016

Free full manuscript:  
[www.painphysicianjournal.com](http://www.painphysicianjournal.com)

Most patients with chronic back pain suffer from degenerative thoracolumbovertebral disease. However, the following case illustrates that a localized peripheral nerve entrapment must be considered in the differential diagnosis of chronic back pain.

We report the case of a 26-year-old woman with continuous excruciating pain in the lower back area. Previous treatment for nephroptosis was to no avail. On physical examination the pain was present in a 2 x 2 cm area overlying the twelfth rib some 4 cm lateral to the spinal process. Somatosensory testing using swab and alcohol gauze demonstrated the presence of skin hypo- and dysesthesia over the painful area. Local pressure on this painful spot elicited an extreme pain response that did not irradiate towards the periphery. These findings were highly suggestive of a posterior version of the anterior cutaneous nerve entrapment syndrome (ACNES), a condition leading to a severe localized neuropathic pain in anterior portions of the abdominal wall.

She demonstrated a beneficial albeit temporary response after lidocaine infiltration as dictated by an established diagnostic and treatment protocol for ACNES. She subsequently underwent a local neurectomy of the involved superficial branch of the intercostal nerve. This limited operation had a favorable outcome resulting in a pain-free return to normal activities up to this very day (follow-up of 24 months).

We propose to name this novel syndrome "posterior cutaneous nerve entrapment syndrome" (POCNES). Each patient with chronic localized back pain should undergo simple somatosensory testing to detect the presence of overlying skin hypo- and dysesthesia possibly reflecting an entrapped posterior cutaneous nerve.

**Key words:** Chronic pain, back pain, posterior cutaneous nerve entrapment, peripheral nerve entrapment, surgical treatment for pain, anterior cutaneous nerve entrapment

**Pain Physician 2017; 20:E455-E458**

**M**ost patients with chronic back pain suffer from degenerative thoracolumbovertebral disease. However, the following case illustrates that a localized peripheral nerve entrapment must be considered in the differential diagnosis of chronic back pain.

A 26-year-old woman presented with a continuous excruciating right sided back pain. She was not able to stand for even a short period of time and was heavily impaired in her work as a fashion designer. Lying down attenuated the symptoms. Her medical history revealed a right-sided nephroptosis for this back

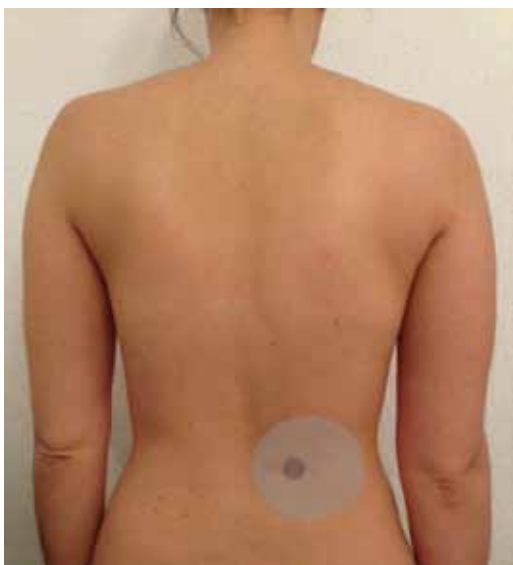

Fig. 1. Back of the patient 6 months after surgery, showing the neurectomy scar over the previous area of allodynia (shaded in a lighter gray). Centrally, the point of maximum pain is marked (shaded in dark gray).

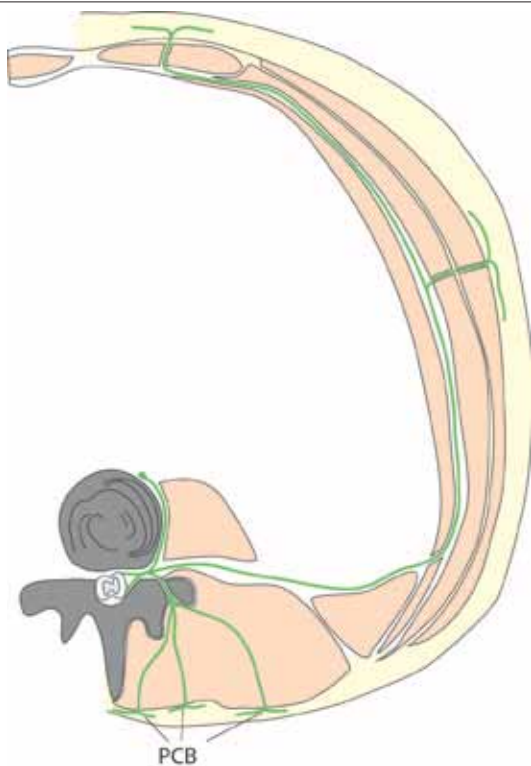


Fig. 2. Schematic representation of the anatomy of the intercostal nerve.

PCB = posterior cutaneous branches

pain that was treated twice by a laparoscopic nephropexia but to no avail. After consulting with several pain specialists, she was referred to Maasziekenhuis Pantein as part of an abdominal wall pain study group, since a non-urological, neuropathic origin of the pain was suspected.

On physical examination, the pain was present in a 2 x 2 cm area overlying the twelfth rib some 4 cm lateral to the spinal process (Fig. 1). This area was not in proximity to any surgical scar or previous laparoscopic trocar sites. Somatosensory testing using swab and alcohol gauze demonstrated the presence of skin hypo- and dysesthesia over the painful area. Local pressure on this 2 x 2 cm spot elicited an extreme pain response that did not irradiate towards the periphery. Signs and symptoms strongly suggested a cutaneous nerve entrapment syndrome such as in anterior cutaneous nerve entrapment syndrome (ACNES) (1). The trigger point was infiltrated subfascially by a freehand technique using 2 mL of 1% lidocaine. This resulted in an immediate, albeit temporary relief. Therefore, a superficial entrapment was deemed highly likely. As 2 additional infiltrations using a mix of lidocaine and methylprednisolone were not successful on the long-term, specifics of a surgical procedure were discussed. Following written consent, the point of maximal pain was surgically explored via a small transverse incision. The posterior end branch of the twelfth intercostal nerve penetrating the fascia of paravertebral muscles was identified followed by resection (Figs. 2, 3). At the 6 weeks follow-up she was pain free. After 24 months, only minimal discomfort was reported without interference of daily activities.

To our knowledge, this report is the first in the literature to identify a patient with a –to this date unknown– diagnosis of posterior cutaneous nerve entrapment syndrome (POCNES). The diagnosis is well explained on the basis of its anatomical features, whereas the diagnostic tests are straightforward. Treatment modalities including injections and surgery confirm the diagnosis with a successful short-term and long-term result as also observed in a related diagnosis of ACNES (2).

High level evidence literature for ACNES is sparse (3). Anterior branches of an intercostal nerve are somehow trapped in abdominal muscles causing severe pain. A recent randomized trial including a sham operation unambiguously confirmed the validity of a theoretical-anatomical model of a painfully entrapped intercostal nerve (4). Once ACNES is properly diagnosed, treatment is simple and successful (2). Over 80% of patients experience an immediate pain relief following trigger point

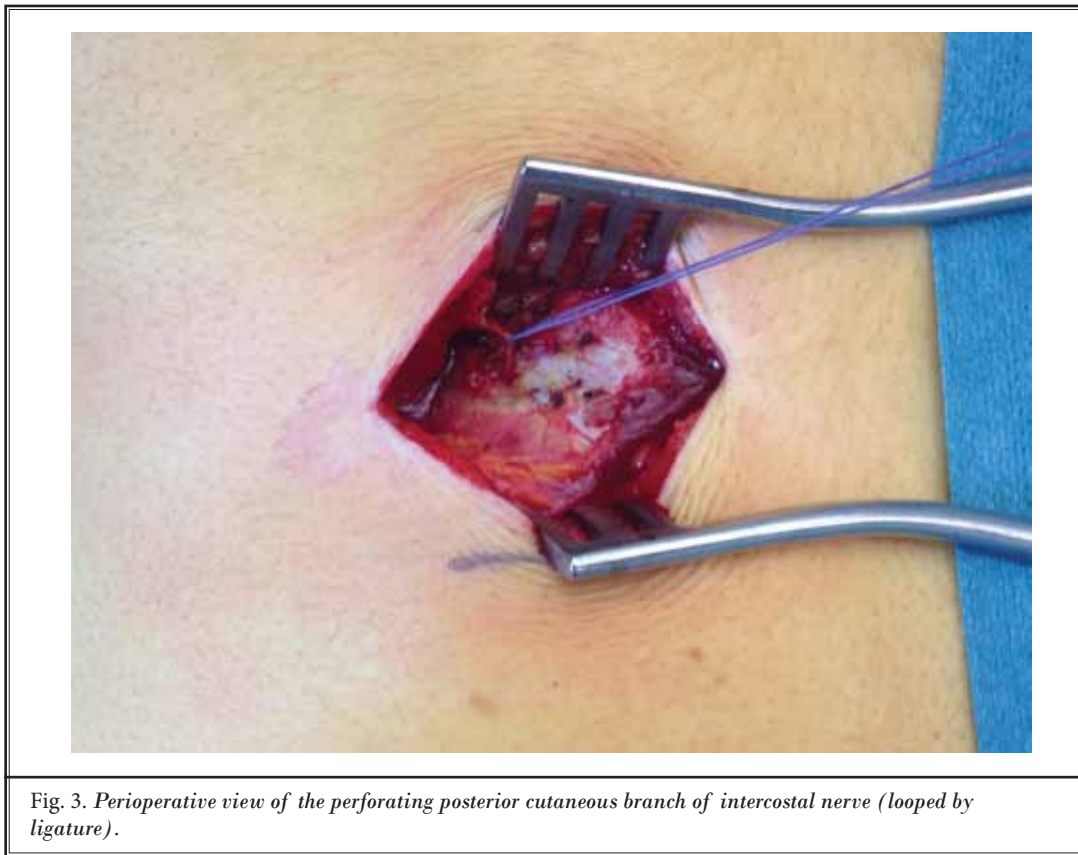


Fig. 3. Perioperative view of the perforating posterior cutaneous branch of intercostal nerve (looped by ligature).

injections using a local anaesthetic agent (with or without corticosteroids), whereas 32% also report long-term pain relief. Subsequent surgical treatment in refractory patients results in a 70% long-term positive result in neurectomized patients (2,4).

With these data in mind and reflecting on anatomy, it must be appreciated that an intercostal nerve also has lateral and posterior branches. In the literature just one case reported a chronic flank pain patient undergoing a neurectomy of entrapped lateral branches of the intercostal nerve (5). In a systematic literature search however, neither similar case reports or series suggesting a posterior cutaneous nerve entrapment syndrome nor a theoretical-anatomical description of this phenom-

enon were found. Considering the sparse literature on ACNES and a long doctor's delay, POCNES is likely overlooked as well. Therefore, an estimate of the true incidence of this diagnosis is not available.

In conclusion, the term posterior cutaneous nerve entrapment syndrome (POCNES) is proposed for this novel syndrome. General practitioners, neurologists, (orthopaedic) surgeons, as well as pain specialists should consider POCNES in the differential diagnosis in each patient with chronic localized back pain in the presence of overlying skin hypo- or dysesthesia on simple somatosensory testing using a swab and an alcohol gauze. This set of findings may reflect an entrapped posterior cutaneous nerve.

## REFERENCES

1. Srinivasan R, Greenbaum DS. Chronic abdominal wall pain: A frequently overlooked problem. Practical approach to diagnosis and management. *Am J Gastroenterol* 2002; 97:824-830.
2. Boelens OB, Scheltinga MR, Houterman S, Roumen RM. Management of anterior cutaneous nerve entrapment syndrome in a cohort of 139 patients. *Ann Surg* 2011; 254:1054-1058.
3. Abdominal wall tenderness test: Could Carnett cut costs? *Lancet* 1991; 337:1134.
4. Boelens OB, van Assen T, Houterman S, Scheltinga MR, Roumen RM. A double-blind, randomized, controlled trial on surgery for chronic abdominal pain due to anterior cutaneous nerve entrapment syndrome. *Ann Surg* 2013; 257:845-849.
5. Sharf M, Shvartzman P, Farkash E, Horvitz J. Thoracic lateral cutaneous nerve entrapment syndrome without previous lower abdominal surgery. *J Fam Pract* 1990; 30:211-212, 214.