



Letter to the editor

Combination of docetaxel, trastuzumab and pertuzumab or treatment with trastuzumab-emtansine for metastatic salivary duct carcinoma



Wim van Boxtel^a, Eline Boon^a, Willem L.J. Weijs^b, Frank J.A. van den Hoogen^c, Uta E. Flucke^d, Carla M.L. van Herpen^{a,*}

^a Department of Medical Oncology, Radboud University Medical Center, Geert Grooteplein Zuid 8, 6525 AG Nijmegen, The Netherlands

^b Department of Oral and Maxillofacial Surgery, Radboud University Medical Center, Geert Grooteplein Zuid 8, 6525 AG Nijmegen, The Netherlands

^c Department of Otorhinolaryngology/Head and Neck Surgery, Radboud University Medical Center, Geert Grooteplein Zuid 8, 6525 AG Nijmegen, The Netherlands

^d Department of Pathology, Radboud University Medical Center, Geert Grooteplein Zuid 8, 6525 AG Nijmegen, The Netherlands

ARTICLE INFO

Article history:

Received 14 April 2017

Received in revised form 22 June 2017

Accepted 23 June 2017

Available online 30 June 2017

Keywords:

Salivary duct carcinoma

Salivary gland neoplasms

Head and Neck Neoplasms

Neoplasm metastasis

Receptor, ErbB-2

Docetaxel

Trastuzumab

Pertuzumab

Ado-trastuzumab emtansine

Dear editor,

With great interest we read the review of Alfieri et al. [1] concerning systemic therapies in metastatic salivary gland carcinomas. In addition to this, we hereby present our experience with novel HER2-targeted therapies in metastatic salivary duct carcinoma (SDC) patients.

SDC is a rare and aggressive subtype of salivary gland cancer, with a median overall survival (OS) of 3–4 years after primary diagnosis [2–4]. As stated in the above mentioned review, responses to chemotherapy are poor and knowledge about new drugs is based on small studies. Next to this, many studies “lumped” patients with a spectrum of salivary gland cancers, failing to fully appreciate the impact of the heterogeneity in salivary gland cancer [5].

In SDC, HER2 is overexpressed in 21–44% [4,6,7] of the cases, and could serve as a therapeutical target [8]. In Table 1 we show the available evidence on HER2-targeted therapies for metastatic

SDC. The most important study is a phase II clinical trial in 45 patients treated with docetaxel and trastuzumab for advanced HER2-positive SDC, in which preliminary results show an overall response rate of 69% and a median progression free survival (PFS) of 11.3 months [9].

In breast cancer, patients receiving docetaxel and trastuzumab for HER2-positive metastatic breast cancer have a median PFS of 12.4 months and median OS of 40.8 months. Adding pertuzumab to this regimen extends the median PFS and OS to 18.7 and 56.5 months, respectively [10]. Because of similarities in histology and HER2 status, we hypothesized that adding pertuzumab may also increase PFS in SDC. In this letter to the editor we describe two patients treated with the combination of docetaxel, trastuzumab and pertuzumab in our clinic. Additionally, we demonstrate in one patient that after disease progression another line of HER2-targeted therapy with trastuzumab-emtansine can be beneficial.

* Corresponding author at: Geert Grooteplein Zuid 8, P.O. Box 9101, 6525 GA Nijmegen, The Netherlands.

E-mail addresses: wim.vanboxtel@radboudumc.nl (W. van Boxtel), eline.boon@radboudumc.nl (E. Boon), willem.weijs@radboudumc.nl (W.L.J. Weijs), frank-KNO.vandendoogen@radboudumc.nl (F.J.A. van den Hoogen), Uta.flucke@radboudumc.nl (U.E. Flucke), Carla.vanHerpen@radboudumc.nl (C.M.L. van Herpen).

Table 1Literature review on HER2-targeted therapies in metastatic salivary duct carcinoma.^a

Author	Study	Number of patients	Therapy	Clinical benefit	Median PFS
Agulnik et al. [12]	Phase II trial	4	Lapatinib	No CR or PR	Unknown
Limaye et al. [13]	Case series	5	Trastuzumab, paclitaxel and carboplatin	1 × CR 2 × PR 2 × PD	18 months
Perissinotti et al. [14]	Case series	11	3 patients: Trastuzumab only 8 patients: Trastuzumab and chemotherapy ^b	3 × SD 2 × PR 3 × SD 5 × PD	Unknown
Falchook et al., [15]	Phase I trial	3	Trastuzumab, lapatinib and bevacizumab	1 × non-evaluable 1 × PR 1 × SD 1 × PD	3 months
De Block et al. [16]	Case series	3	Trastuzumab and chemotherapy ^b	3 × CR	11 months
Takahashi et al. [9]	Phase II trial	45	Trastuzumab and docetaxel	31 × CR/PR → Response rate 69%	11.3 months

CR: complete remission, PR: partial response, SD: stable disease, PD: progressive disease, PFS: progression free survival.

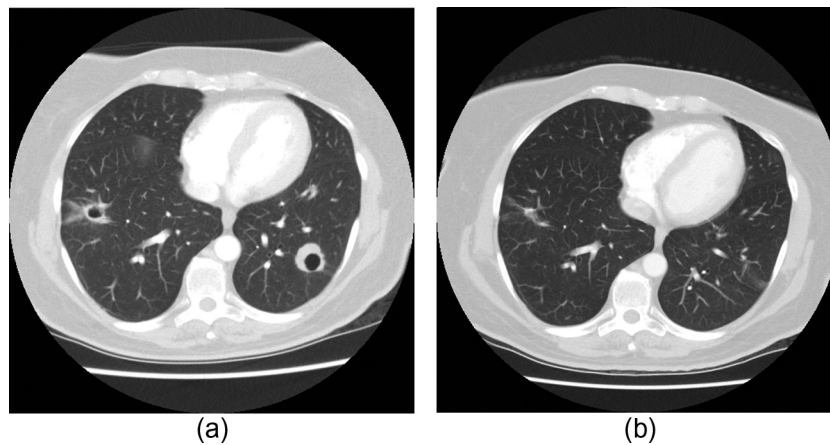
^a Case-reports were excluded.^b Different combinations of chemotherapy were used.

Fig. 1. (a) Chest CT with a section width of 5 mm, pulmonary window, after intravenous contrast administration of the second patient before starting trastuzumab-emtansine. Pulmonary metastasis with cavitation in the left lower lobe of 29 mm in the largest axial direction and a more opacified metastasis in the right lower lobe measuring 34 mm in the largest axial direction. (b) Chest CT with a section width of 5 mm, pulmonary window, after intravenous contrast administration of the second patient after 4 months of treatment with trastuzumab-emtansine. Pulmonary metastasis in the left lower lobe measuring 16 mm. The pulmonary metastasis in the right lower lobe is immeasurable.

Both patients were treated with the combination of docetaxel, trastuzumab and pertuzumab. Docetaxel was dosed 75 mg/m² intravenously (IV) every 3 weeks. The HER2-targeting monoclonal antibodies trastuzumab and pertuzumab were dosed 600 mg subcutaneously and 420 mg IV every 3 weeks, respectively. For pertuzumab, patients received a loading dose of 840 mg in the first cycle. After 6 cycles docetaxel was stopped and trastuzumab and pertuzumab were continued until PD. After PD, one patient was treated with trastuzumab-emtansine. This is an antibody-drug conjugate consisting of trastuzumab linked to the microtubule inhibitor emtansine. It was dosed 3.6 mg/kg IV every 3 weeks.

Case 1. A 63-year-old man was diagnosed with a pT3N2bM0 androgen receptor (AR) positive SDC of the right parotid gland and primary treatment consisted of a parotidectomy with a modified neck dissection of level I–V, followed by adjuvant radiation therapy (66 Gy in fractions of 2 Gy). Only 8 months later, patient was diagnosed with metastases in liver, lungs and mediastinal lymph nodes for which palliative androgen deprivation therapy (ADT) was started. After 6 months, the patient had PD and ADT was stopped. Because HER2 was strongly positive (immunohistochemistry (IHC) 3+ and fluorescence in situ hybridization (FISH) positive), we started with the combination of docetaxel,

trastuzumab and pertuzumab. After 2 cycles the patient had a partial response (PR). Currently, he has an ongoing PR 17 months after start of treatment, and received 25 cycles. Side effects consisted of a flare-up of radiotherapy toxicity induced by the systemic treatment and a pre-auricular and retropharyngeal abscess after 2 cycles. After 10 cycles the patient developed erysipelas of the right side of his face. At this moment he has a very good quality of life with no adverse events and a WHO performance score of 0.

Case 2. A 48-year-old woman was diagnosed with a pT3N1M0 SDC ex pleomorphic adenoma. Primary treatment consisted of a right parotidectomy with homolateral neck dissection, followed by adjuvant radiation therapy. Fifteen months after the initial diagnosis multiple pulmonary metastases were detected. Because of strong HER2 overexpression and amplification (IHC 3+ and FISH positive) and only weak AR expression, palliative treatment with the combination of docetaxel, trastuzumab and pertuzumab was initiated. The evaluation CT-scan showed SD with a decrease in the sum of target lesions by 22%. After the sixth cycle she developed erysipelas of the right side of her face. Eight months after start of treatment, progression of pulmonary metastases was detected. Trastuzumab and pertuzumab were stopped and ADT

was started, but the first evaluation after 3 months showed an increase of the pulmonary lesions and a new brain metastasis. Therefore, ADT was stopped and she received stereotactic radiation therapy on the brain metastasis. The primary tumor was analyzed with the 'Radboud Cancer Hotspot gene panel', but no druggable mutations were found. Leaving HER2 as the only druggable target, we decided to start with trastuzumab-emtansine once every 3 weeks. After 6 cycles of trastuzumab-emtansine she had a PR with a decrease in the sum of target lesions of 70% (Fig. 1). Currently, after 12 cycles she has an ongoing PR.

Discussion

We presented two patients with metastatic SDC, which were treated with the combination of docetaxel, trastuzumab and pertuzumab. On this regimen, one patient has an ongoing PR after 17 months of treatment and one patient had PD after 8 months. In the last patient, we show that a subsequent line of HER2-targeted therapy can be beneficial, as this patient has a sustained PR after 8 months of treatment with trastuzumab-emtansine.

Remarkably, both patients developed erysipelas at the site of the resected primary tumor. Erysipelas is a known side effect of trastuzumab [11] but not for pertuzumab. Whether dual HER2 blockade increases the risk of this side effect, especially in a previously operated and irradiated area, is not known.

In conclusion, we showed that dual HER2 blockade and multiple lines of HER2-targeted therapies can be beneficial to patients with metastatic HER2-positive SDC. More research is needed to establish the advantage of the combination of docetaxel, trastuzumab and pertuzumab over docetaxel and trastuzumab alone. The efficacy of trastuzumab-emtansine in SDC has to be assessed, however we showed efficacy in one patient after PD with dual HER2 blockade.

Funding

This research did not receive any specific grant from funding agencies in the public, commercial, or not-for-profit sectors.

Conflict of interest

None declared.

Acknowledgement

We would like to thank M. Brink, radiologist, for providing the radiology images.

References

- [1] Alfieri S, Granata R, Bergamini C, et al. Systemic therapy in metastatic salivary gland carcinomas: a pathology-driven paradigm? *Oral Oncol* 2017;66:58–63.
- [2] Jaehne M, Roeser K, Jaekel T, Schepers JD, Albert N, Loning T. Clinical and immunohistologic typing of salivary duct carcinoma: a report of 50 cases. *Cancer* 2005;103:2526–33.
- [3] Gilbert MR, Sharma A, Schmitt NC, et al. A 20-year review of 75 cases of salivary duct Carcinoma. *JAMA Otolaryngol. Head Neck Surg.* 2016;142:489–95.
- [4] Boon E, Bel E, van Boxtel W, et al. Salivary duct carcinoma an analysis of clinical outcome, AR and HER-2 expression and prognostic factors of 177 patients from the Netherlands. Unpublished results.
- [5] Dunn LA, Ho AL, Laurie SA, Pfister DG. Unmet needs for patients with salivary gland cancer. *Oral Oncol.* 2016;60:142–5.
- [6] Clauditz TS, Reiff M, Gravert L, et al. Human epidermal growth factor receptor 2 (HER2) in salivary gland carcinomas. *Pathology* 2011;43:459–64.
- [7] Locati LD, Perrone F, Losa M, et al. Treatment relevant target immunophenotyping of 139 salivary gland carcinomas (SGCs). *Oral Oncol* 2009;45:986–90.
- [8] Haddad R, Colevas AD, Krane JF, et al. Herceptin in patients with advanced or metastatic salivary gland carcinomas. A phase II study. *Oral Oncol.* 2003;39:724–7.
- [9] Takahashi H, Masubuchi T, Fushimi C, et al. Trastuzumab and docetaxel for HER2-positive unresectable salivary gland carcinoma: Updated results of a phase II trial. In: 2016 International Conference on Head and Neck Cancer. Abstract S207. Presented July 18, 2016.
- [10] Swain SM, Baselga J, Kim SB, et al. Pertuzumab, trastuzumab, and docetaxel in HER2-positive metastatic breast cancer. *New Engl. J. Med.* 2015;372:724–34.
- [11] EMA. Herceptin: EPAR – Product Information; 2016. <http://www.ema.europa.eu/docs/en_GB/document_library/EPAR_-_Product_Information/human/000278/WC500074922.pdf>. (accessed 6 April, 2017).
- [12] Agulnik M, Cohen EW, Cohen RB, et al. Phase II study of lapatinib in recurrent or metastatic epidermal growth factor receptor and/or erbB2 expressing adenoid cystic carcinoma and non adenoid cystic carcinoma malignant tumors of the salivary glands. *J. Clin. Oncol. Off. J. Am. Soc. Clin. Oncol.* 2007;25:3978–84.
- [13] Limaye SA, Posner MR, Krane JF, et al. Trastuzumab for the treatment of salivary duct carcinoma. *Oncologist* 2013;18:294–300.
- [14] Perissinotti AJ, Lee Pierce M, Pace MB, El-Naggar A, Kies MS, Kupferman M. The role of trastuzumab in the management of salivary ductal carcinomas. *Anticancer Res* 2013;33:2587–91.
- [15] Falchook GS, Moulder S, Naing A, et al. A phase I trial of combination trastuzumab, lapatinib, and bevacizumab in patients with advanced cancer. *Invest New Drugs* 2015;33:177–86.
- [16] De Block K, Vander Poorten V, Dormaar T, et al. Metastatic HER-2-positive salivary gland carcinoma treated with trastuzumab and a taxane: a series of six patients. *Acta Clin Belg* 2016;71:383–8.