

PDF hosted at the Radboud Repository of the Radboud University Nijmegen

The following full text is a publisher's version.

For additional information about this publication click this link.

<http://hdl.handle.net/2066/177201>

Please be advised that this information was generated on 2021-10-19 and may be subject to change.

Structural Brain Abnormalities of Attention-Deficit/Hyperactivity Disorder With Oppositional Defiant Disorder

Siri D.S. Noordermeer, Marjolein Luman, Corina U. Greven, Kim Veroude, Stephen V. Faraone, Catharina A. Hartman, Pieter J. Hoekstra, Barbara Franke, Jan K. Buitelaar, Dirk J. Heslenfeld, and Jaap Oosterlaan

ABSTRACT

BACKGROUND: Attention-deficit/hyperactivity disorder (ADHD) is associated with structural abnormalities in total gray matter, basal ganglia, and cerebellum. Findings of structural abnormalities in frontal and temporal lobes, amygdala, and insula are less consistent. Remarkably, the impact of comorbid oppositional defiant disorder (ODD) (comorbidity rates up to 60%) on these neuroanatomical differences is scarcely studied, while ODD (in combination with conduct disorder) has been associated with structural abnormalities of the frontal lobe, amygdala, and insula. The aim of this study was to investigate the effect of comorbid ODD on cerebral volume and cortical thickness in ADHD. **METHODS:** Three groups, 16 ± 3.5 years of age (mean \pm SD; range 7–29 years), were studied on volumetric and cortical thickness characteristics using structural magnetic resonance imaging (surface-based morphometry): ADHD+ODD ($n = 67$), ADHD-only ($n = 243$), and control subjects ($n = 233$). Analyses included the moderators age, gender, IQ, and scan site.

RESULTS: ADHD+ODD and ADHD-only showed volumetric reductions in total gray matter and (mainly) frontal brain areas. Stepwise volumetric reductions (ADHD+ODD < ADHD-only < control subjects) were found for mainly frontal regions, and ADHD+ODD was uniquely associated with reductions in several structures (e.g., the precuneus). In general, findings remained significant after accounting for ADHD symptom severity. There were no group differences in cortical thickness. Exploratory voxelwise analyses showed no group differences.

CONCLUSIONS: ADHD+ODD and ADHD-only were associated with volumetric reductions in brain areas crucial for attention, (working) memory, and decision-making. Volumetric reductions of frontal lobes were largest in the ADHD+ODD group, possibly underlying observed larger impairments in neurocognitive functions. Previously reported striatal abnormalities in ADHD may be caused by comorbid conduct disorder rather than ODD.

Keywords: ADHD, Comorbidity, Cortical thickness, ODD, SBM, Structural MRI

<http://dx.doi.org/10.1016/j.biopsych.2017.07.008>

Attention-deficit/hyperactivity disorder (ADHD) is one of the most common childhood psychiatric disorders and is defined by developmentally inappropriate levels of inattention, and/or hyperactivity/impulsivity (1). Neuroanatomical findings most consistently reported for ADHD are reduced total gray matter volume and reduced volume of the basal ganglia and the cerebellum. For the latter, cortical thickness abnormalities are also associated with ADHD. In addition, volumetric reductions and reduced cortical thickness of the frontal and temporal lobes have been reported, although less consistently [for reviews, see (2,3)]. Finally, some studies reported volumetric abnormalities in the amygdala and insula to be related to ADHD, but the findings are inconsistent, especially for the amygdala (4–9).

A potential explanation for the inconsistent neuroanatomical findings may be the presence of comorbid disorders in the studied ADHD samples, such as oppositional defiant disorder (ODD). ODD is present in up to 60% of clinically referred children

with ADHD (10–12) and is defined by a persistent pattern of irritable and angry mood, vindictiveness, and developmentally inappropriate, negativistic, defiant, and disobedient behavior toward authority figures (1). Compared with individuals with only ADHD or ODD, individuals with ADHD+ODD show an earlier age of onset for both ADHD and ODD symptoms, exhibit more physical aggression and delinquency, show more functional impairments, such as poorer working memory, inhibition, temporal processing, and emotion recognition, and have a considerably worse prognosis (11,13,14).

Surprisingly, most studies on neuroanatomical correlates of ADHD did not investigate or report on the presence of comorbidities, such as ODD, resulting in relatively few studies investigating ADHD-only samples. The few studies in ADHD-only samples were less likely to find volumetric abnormalities in the frontal cortex than studies that included comorbid individuals [for an overview, see (15)]. They also showed that

SEE COMMENTARY ON PAGE e67

accounting for the presence of comorbid ODD significantly influenced findings, with either larger abnormalities in individuals with ADHD+ODD (16) or more abnormalities associated with ADHD after controlling for comorbid ODD (17). In addition, studies assessing ADHD-only groups showed no volumetric abnormalities in the amygdala (4,6,7), and abnormalities in the insula were accounted for by comorbid ODD (8). For cortical thickness, an influential study showed a delay in cortical development for individuals with ADHD, but of that sample 35% of the individuals had a comorbid diagnosis of ODD (3,18). Thus, previous findings may not purely reflect neuroanatomical characteristics of ADHD but may be confounded by comorbid ODD.

An alternative explanation for the inconsistent neuroanatomical findings for ADHD could be the age of included participants. According to the maturational delay hypothesis (18), individuals with ADHD show a maturational lag in brain development compared with typically developing control (TDC) subjects. According to this theory, the maturational lag is most prominent in prefrontal regions and has been reported to correspond with a 3-year delay, with TDC subjects attaining their peak cortical thickness at 7.5 years of age and individuals with ADHD at 10.5 years of age (18). In addition, it has been reported that structural abnormalities in the basal ganglia normalize with age (2,19). However, in contrast with the maturational delay hypothesis, structural abnormalities in the anterior cingulate cortex seem to persist into adulthood (2,20). Hence, studying the impact of comorbid ODD and age is pivotal to understanding the heterogeneity in findings.

So far, no studies on neuroanatomical correlates exclusively focused on individuals with ODD-only or on ADHD+ODD. Rather, studies included mixed samples of children with ADHD with and without comorbid ODD, or included children with both (comorbid) ODD and conduct disorder (CD) (a related disorder for which ODD is often a precursor) (21). The studies that focused on volumetric characteristics of individuals with ODD/CD with and without comorbid ADHD consistently reported reduced volumes of the amygdala, insula, and frontal lobe [for a review, see (21)]. Furthermore, it has been reported that CD is associated with volumetric abnormalities in frontal areas, while this association seemed relatively weak for ADHD-only (15). In terms of cortical thickness, one study investigated an ODD/CD sample and reported a decreased overall mean cortical thickness and thinning of the cingulate, prefrontal, and insular cortices (22).

To summarize, while neuroanatomical abnormalities in ADHD-only appear to be most strongly related to the frontal regions, ADHD+ODD appears associated with abnormalities in the frontal regions, amygdala, and insula. The overlap in affected brain areas may explain inconsistencies in reported abnormalities for frontal areas in ADHD, because these may be driven (partly) by the presence of comorbid ODD or by a combined effect of both disorders. So far, the literature does not answer the question on whether previously reported abnormalities in ADHD reflect neuroanatomical characteristics of ADHD or rather of comorbid ODD. Therefore, a comparison between individuals with ADHD+ODD and individuals with ADHD-only would be highly informative in terms of specificity of findings for ADHD. This may also clarify whether previously reported structural abnormalities in the amygdala and insula were driven by comorbid ODD.

The current study aimed to disentangle brain abnormalities associated with ADHD versus ADHD+ODD by comparing these diagnostic groups to TDC subjects across a broad age range from childhood to late adolescence. We studied the impact of age in order to test whether individuals with ADHD showed a maturational delay in neuroanatomical development. To meet these aims, neuroanatomical volumes and cortical thickness were compared between a large sample of individuals with ADHD without ODD (ADHD-only), individuals with ADHD and ODD (ADHD+ODD), and TDC subjects. We hypothesized that 1) abnormalities in the basal ganglia and cerebellum would be strongly associated with ADHD and therefore present in both diagnostic groups and that 2) abnormalities in the amygdala and the insula would be driven by ODD rather than by ADHD and hence would be predominantly present in the ADHD+ODD group rather than the ADHD-only group. Furthermore, we speculated that 3) abnormalities in the frontal lobes would be more pronounced in the ADHD+ODD group than in the ADHD-only group but would be present in both, given that previous studies have implicated the frontal lobe in both ADHD and ODD.

METHODS AND MATERIALS

Participants

Participants were selected from the NeuroIMAGE cohort [for a full description, see the Supplement and (23)]. Inclusion criteria for the current study were as follows: European Caucasian descent, IQ ≥ 80 (as estimated with the vocabulary and block design subtests of an age-appropriate Wechsler Intelligence Scale for Children or Wechsler Adult Intelligence Scale), and no diagnosis of autism/Asperger's/anxiety disorder/depression/epilepsy/general learning difficulties/brain disorders/known genetic disorders (e.g., fragile X syndrome or Down syndrome). Control subjects were not allowed to have a previous or current diagnosis of ADHD, ODD, or any other psychiatric disorder. A total of 1069 participants contributed data to NeuroIMAGE: 751 participants from ADHD families (participants in the ADHD-only or ADHD+ODD group and their biological siblings) and 318 participants from control families [participants in the TDC group and their biological siblings (23)]. For the current study, only individuals with a current ADHD diagnosis, with comorbid ODD ($n = 67$) and without comorbid ODD ($n = 243$), and TDC subjects ($n = 233$) were included. Not all participants in the NeuroIMAGE study underwent a magnetic resonance imaging (MRI) scanning session because of contraindications for MRI.

Diagnostic Assessment

A full description of the diagnostic assessment has been provided in previous work [Supplement and (24)]. In short, participants were diagnosed with ADHD or ODD according to DSM-IV criteria. Individuals in the ADHD+ODD group qualified for a diagnosis of both ADHD and ODD, while individuals in the ADHD-only group only qualified for a diagnosis of ADHD. A diagnostic algorithm was applied to create a combined symptom count from the questionnaires and interview.

MRI Acquisition and Analysis

MRI data were acquired on a 1.5T Siemens Sonata (Siemens, Erlangen, Germany) scanner (used at the Amsterdam scanning site) and on a Siemens Avanto scanner (used at the Nijmegen scanning site). Both sites used a standard identical 8-channel phased array coil and closely matched scan parameters (Supplement).

Cortical reconstruction and volumetric segmentation were performed with FreeSurfer software version 5.3 with default settings (<http://surfer.nmr.mgh.harvard.edu/>) (see the Supplement for the investigated areas and quality assurance procedures). FreeSurfer is an image processing pipeline including a volume-based route to subcortical segmentation (25), and a surface-based route to create a three-dimensional reconstruction and parcellation of the cortical sheet (26,27). From FreeSurfer parcellations and segmentations (27) we calculated total gray matter, total cortical matter, and cortical and subcortical volumes, as well as bilateral volumes for each brain region. In addition, FreeSurfer was used to calculate cortical thickness measures. Regions were based on the Desikan-Killiany atlas (27), and an overview of investigated areas can be found in the Supplement.

Procedure

The current study was part of a comprehensive assessment protocol encompassing phenotypic, neurocognitive, and MRI assessments (23) (details in the Supplement). Informed consent was signed by all participants (for participants <12 years of age, only parents signed informed consent; for participants 12–18 years of age, both the participants and their parents signed; for participants >18 years of age, only the participants signed). The study was approved by the local ethics committees.

Statistical Analyses

Groups were compared on demographic characteristics using analysis of variance or χ^2 tests. All analyses that tested group differences in neuroanatomical characteristics were performed using the mixed models procedure in SPSS software (version 21.0; IBM Corp., Armonk, NY). Mixed model analyses were performed with a random intercept, with an exchangeable structure for family, to account for the hierarchical structure due to family relations (siblings with ADHD in the diagnostics group or siblings without ADHD in the control group) in the data. Group differences were examined as a fixed effect. To correct for multiple testing, false discovery rate (FDR)-corrected results were reported (maximum acceptable FDR of 5%), based on the sequential Benjamini-Hochberg FDR correction algorithm (28). When an overall significant main effect of group was found, post hoc pairwise group comparisons (least significant difference) were assessed.

Linear interaction effects between group and possible moderator variables (age [linear/nonlinear], gender, IQ, medication use, and scan site) were assessed. When a significant interaction effect was present, the main effect of the moderator and interaction effect between group and moderator were added to the model. In that case, interactions were plotted to clarify the direction of the interaction. When the interaction term was not significant, but only a main effect was found, the variable was included in the model as a covariate.

RESULTS

A total of 542 participants took part in this study: 67 participants with ADHD+ODD, 243 participants with ADHD-only, and 233 TDC subjects. The mean age was 16 years (SD 3.5 years [range 7–29 years]), and individuals from the three groups were similarly spread out across the age range. Table 1 shows additional group characteristics. The diagnostic groups did not differ from the TDC group in age ($p > .225$, both diagnostic groups) but did differ in IQ ($p < .001$, both diagnostic groups; higher IQ in the control group) and gender ($p < .001$ for ADHD-only, $p = .026$ for ADHD+ODD; more females in the control group). Furthermore, the diagnostic groups showed higher levels of total ADHD, hyperactive and inattentive symptoms, and ODD symptoms compared with the control group ($p < .001$ for both diagnostic groups; fewer symptoms in the control group). The ADHD+ODD and ADHD-only groups did not differ from each other in IQ ($p = .532$) or gender ($p = .803$). However, compared with the ADHD-only group, the ADHD+ODD group showed a higher level of ODD symptoms ($p < .001$) as well as a higher level of total ($p < .001$), hyperactive ($p = .021$), and inattentive ($p < .001$) ADHD symptoms. Given these differences in ADHD symptom count between diagnostic groups, sensitivity analyses were performed for those regions for which group differences were observed between the diagnostic groups. For these analyses, total ADHD symptom count was entered as covariate.

We found no significant interactions between group and gender, IQ, medication use, or scan site. However, age (linear only), gender, IQ, and scan site added significantly to the model for the majority of the structures. Therefore, these variables were included as covariates in all models. For the volumetric analyses, total intracranial volume was added as an additional covariate. Results for the main group comparisons are shown in Supplemental Table S1 (volume) and Supplemental Table S2 (cortical thickness), including the post hoc comparisons after FDR correction. Table 2 shows the results of the sensitivity analyses (accounting for ADHD symptom severity) for the diagnostic groups that survived FDR correction.

Group Effects

Total Cortical, Gray Matter, and Subcortical Gray Matter Volume. For total cortical volume ($p_{\text{FDR-corrected}} = .001$) and total gray matter volume ($p_{\text{FDR-corrected}} = .001$), both diagnostic groups showed reduced volumes compared with the control group but did not differ from each other ($p = .103$ and $p = .126$, respectively). There were no group differences for total subcortical gray matter volume.

Cortical Volumes. There were several main group effects (Figures 1–3 and Supplemental Table S1). Post hoc analysis showed areas for which one or both of the diagnostic groups differed from controls and areas for which the diagnostic groups also differed from each other. Structures that showed volumetric reductions in both diagnostic groups compared with the control group included the lateral orbitofrontal (left $p_{\text{FDR-corrected}} < .001$; right $p_{\text{FDR-corrected}} < .001$), isthmus (left $p_{\text{FDR-corrected}} = .006$; right $p_{\text{FDR-corrected}} < .001$), inferior parietal gyrus (left $p_{\text{FDR-corrected}} < .001$; right $p_{\text{FDR-corrected}} = .015$), caudal middle

Table 1. Group Characteristics

Measure	ADHD+ODD (n = 67)	ADHD-Only (n = 243)	TDC (n = 233)	Group Comparisons
Age, Years (Range)	16.3 ± 3.2 (8–22)	17.0 ± 3.5 (7–25)	16.6 ± 3.6 (7–29)	NS
IQ	98.0 ± 11.2	96.9 ± 16.1	105.9 ± 13.9	ADHD+ODD < TDC, ^a ADHD-only < TDC, ^a ADHD+ODD = ADHD-only
Male Gender, %	66	68	55	ADHD+ODD > TDC, ^b ADHD-only > TDC, ^a ADHD+ODD = ADHD-only
Scan Site (Amsterdam), %	42	42	64	ADHD+ODD < TDC, ^c ADHD-only < TDC, ^a ADHD+ODD = ADHD-only
Medication Use, ^d mg	58,373 ± 49,668	61,848 ± 57,795	–	NS
ADHD Total Symptoms ^e	14.3 ± 2.5	12.9 ± 3.0	1.3 ± 2.4	ADHD+ODD > ADHD-only, ^a ADHD+ODD > TDC, ^a ADHD-only > TDC ^a
Hyperactive Symptoms ^e	6.6 ± 2.1	5.8 ± 2.4	0.5 ± 1.2	ADHD+ODD > ADHD-only, ^b ADHD+ODD > TDC, ^a ADHD-only > TDC ^a
Inattentive Symptoms ^e	7.8 ± 1.2	7.1 ± 1.8	0.8 ± 1.6	ADHD+ODD > ADHD-only, ^a ADHD+ODD > TDC, ^a ADHD-only > TDC ^a
ODD Symptoms ^e	5.1 ± 1.2	1.0 ± 1.8	0.0 ± 0.5	ADHD+ODD > ADHD-only, ^a ADHD+ODD > TDC, ^a ADHD-only > TDC ^a

Values presented as percent or mean ± SD (range).

ADHD, attention-deficit/hyperactivity disorder; NS, not significant; ODD, oppositional defiant disorder; TDC, typically developing control subject.

^a*p* < .001.

^b*p* < .05.

^c*p* < .01.

^dCumulative stimulation medication intake, calculated by multiplying treatment duration and mean daily dose, corrected for age (53).

^eAs measured using the combination of Kiddie Schedule for Affective Disorders and Schizophrenia for School-Age Children–Present and Lifetime version and Conners Scale total, inattentive, and hyperactive/impulsive symptoms.

frontal (left *p*_{FDR-corrected} = .002; right *p*_{FDR-corrected} = .002), right parahippocampal gyrus (*p*_{FDR-corrected} < .001), right medial orbitofrontal gyrus (*p*_{FDR-corrected} < .001), right superior frontal gyrus (*p*_{FDR-corrected} = .002), left precentral gyrus (*p*_{FDR-corrected} = .004), right rostral middle frontal gyrus (*p*_{FDR-corrected} = .005), and left lateral occipital gyrus (*p*_{FDR-corrected} = .005).

Several of the structures showed a stepwise significant reduction in volume, with the largest volumetric reduction in the ADHD+ODD group, followed by the ADHD-only group,

compared with the control group. These structures were the lateral orbitofrontal, right medial orbitofrontal, right superior frontal, right caudal middle frontal, and left inferior parietal gyrus (Figure 1). Finally, there were five areas showing a disorder-specific volumetric reduction compared with controls (Figure 2). For the left rostral middle frontal (*p*_{FDR-corrected} = .002), left medial orbitofrontal (*p*_{FDR-corrected} = .004), right precuneus (*p*_{FDR-corrected} = .005), and left pars triangularis (*p*_{FDR-corrected} = .007), the ADHD+ODD group showed a

Table 2. Results of Diagnostic Group Comparisons Accounting for ADHD Symptom Severity—Volume

Structure	Lateralization	ADHD+ODD (n = 67)	ADHD-Only (n = 243)	Main Effect of Group	Post Hoc Group Comparisons
Linear Volumetric Reduction, mL					
Lateral orbitofrontal	Left	8.69 ± 1.43	8.95 ± 1.09	<i>F</i> _{1,301} = 5.24 ^a	ADHD-only > ADHD+ODD
	Right	8.45 ± 1.51	8.72 ± 1.06	<i>F</i> _{1,300} = 5.53 ^a	ADHD-only > ADHD+ODD
Medial orbitofrontal	Right	5.72 ± 0.87	5.89 ± 0.69	<i>F</i> _{1,297} = 6.63 ^a	ADHD-only > ADHD+ODD
Caudal middle frontal	Right	6.93 ± 1.57	7.22 ± 1.28	<i>F</i> _{1,295} = 3.38	NS
Inferior parietal gyrus	Left	13.83 ± 2.51	14.32 ± 2.04	<i>F</i> _{1,299} = 6.19 ^a	ADHD-only > ADHD+ODD
Superior frontal gyrus	Right	25.58 ± 3.63	26.08 ± 3.11	<i>F</i> _{1,295} = 4.38 ^a	ADHD-only > ADHD+ODD
Disorder Specificity, mL					
Rostral middle frontal	Left	18.89 ± 3.14	19.32 ± 2.80	<i>F</i> _{1,294} = 7.69 ^b	ADHD-only > ADHD+ODD
Medial orbitofrontal	Left	5.58 ± 0.93	5.83 ± 0.76	<i>F</i> _{1,301} = 7.04 ^b	ADHD-only > ADHD+ODD
Precuneus	Right	10.99 ± 1.56	11.23 ± 1.44	<i>F</i> _{1,286} = 4.57 ^a	ADHD-only > ADHD+ODD
Pars triangularis	Left	3.99 ± 0.61	4.20 ± 0.70	<i>F</i> _{1,300} = 6.46 ^a	ADHD-only > ADHD+ODD
Middle temporal gyrus	Left	12.32 ± 1.97	12.68 ± 1.84	<i>F</i> _{1,301} = 4.09 ^a	ADHD-only > ADHD+ODD

Values presented as mean ± SD.

ADHD, attention-deficit/hyperactivity disorder; ODD, oppositional defiant disorder.

^a*p* < .05.

^b*p* < .01.

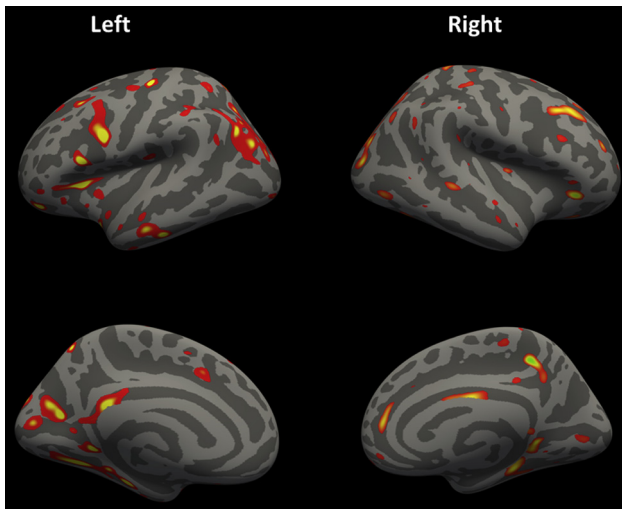


Figure 1. Overall volumetric group differences between the three groups, based on whole brain voxelwise analyses. Lateral (top) and sagittal (bottom) view of the left (left) and right (right) hemispheres. Colored areas indicate clusters exhibiting overall group differences in cortical volume for all three groups (control subjects, attention-deficit/hyperactivity disorder only, and attention-deficit/hyperactivity disorder plus oppositional defiant disorder). Results are uncorrected for multiple comparisons ($p < .0001$). Yellow indicates the center of gravity for the clusters. Dark gray indicates sulci; light gray indicates gyri.

reduced volume compared with both the control group and the ADHD-only group (that did not differ from each other; $p = .311$, $p = .566$, $p = .087$, and $p = .332$, respectively). For the left middle temporal gyrus ($p_{\text{FDR-corrected}} = .010$), the

ADHD+ODD group showed a reduced volume compared with the control group, but not compared with the ADHD-only group ($p = .050$). The control and ADHD-only groups did not differ ($p = .104$).

Results of post hoc exploratory whole-brain voxelwise group comparisons showed no clusters surviving FDR-corrected voxelwise multiple comparisons. Uncorrected ($p < .0001$) voxelwise results largely overlapped with the findings using a region of interest approach (Figure 1 and Supplemental Figures S1–S3).

Subcortical Volumes. There were no main group effects for any of the subcortical structures.

Cortical Thickness. There were no main group effects for cortical thickness of any of the structures (Supplemental Table S2).

Effects of Group by Age. We found no significant linear or quadratic interactions between group and age for any of the volumes or for cortical thickness surviving FDR correction. Thus, the interactions were not included in the models.

Sensitivity Analysis Diagnostic Groups

For all 11 structures that showed differences between the diagnostic groups (Table 2), the analyses were rerun for the diagnostic groups while accounting for total number of ADHD symptoms. For five of the six structures, the finding of stepwise greater volumetric reductions in the ADHD+ODD group compared with the ADHD-only group remained significant (right medial orbitofrontal $p_{\text{FDR-corrected}} = .011$, left inferior

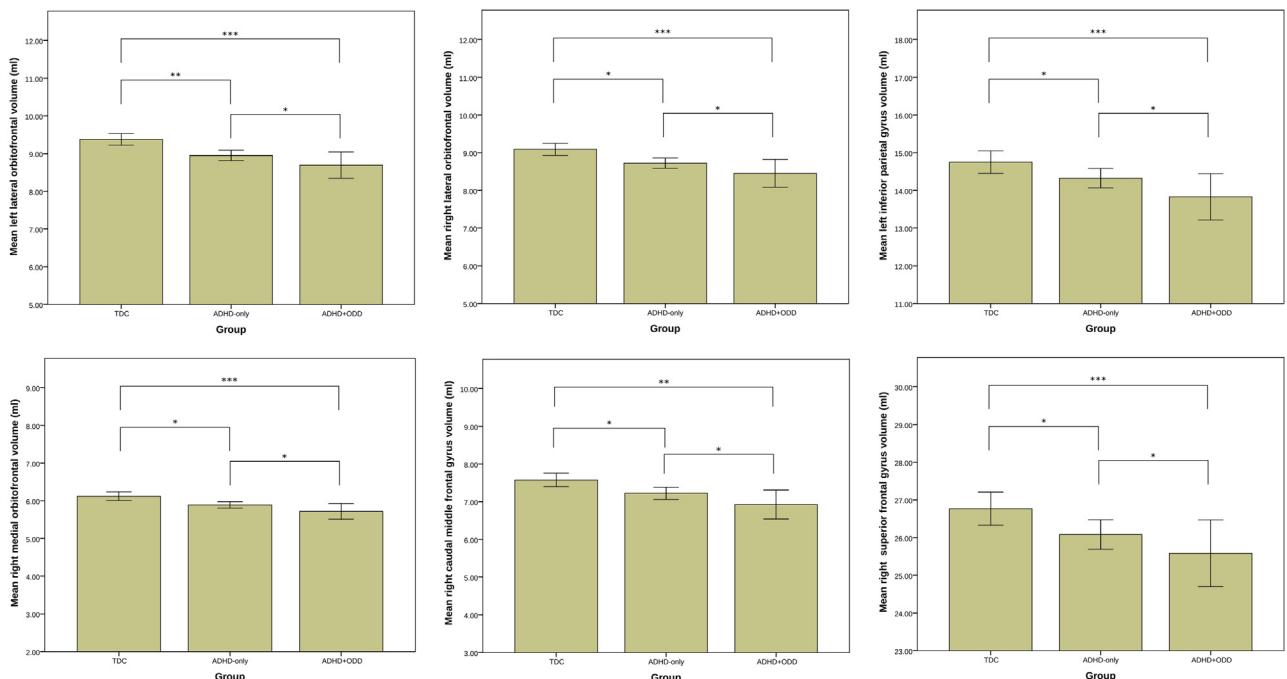


Figure 2. Stepwise volumetric reductions. Volumes are provided in milliliters (mL), and the error bars represent 95% confidence intervals. ADHD, attention-deficit/hyperactivity disorder; ODD, oppositional defiant disorder; TDC, typically developing control subjects. * $p < .05$, ** $p < .01$, *** $p < .001$.

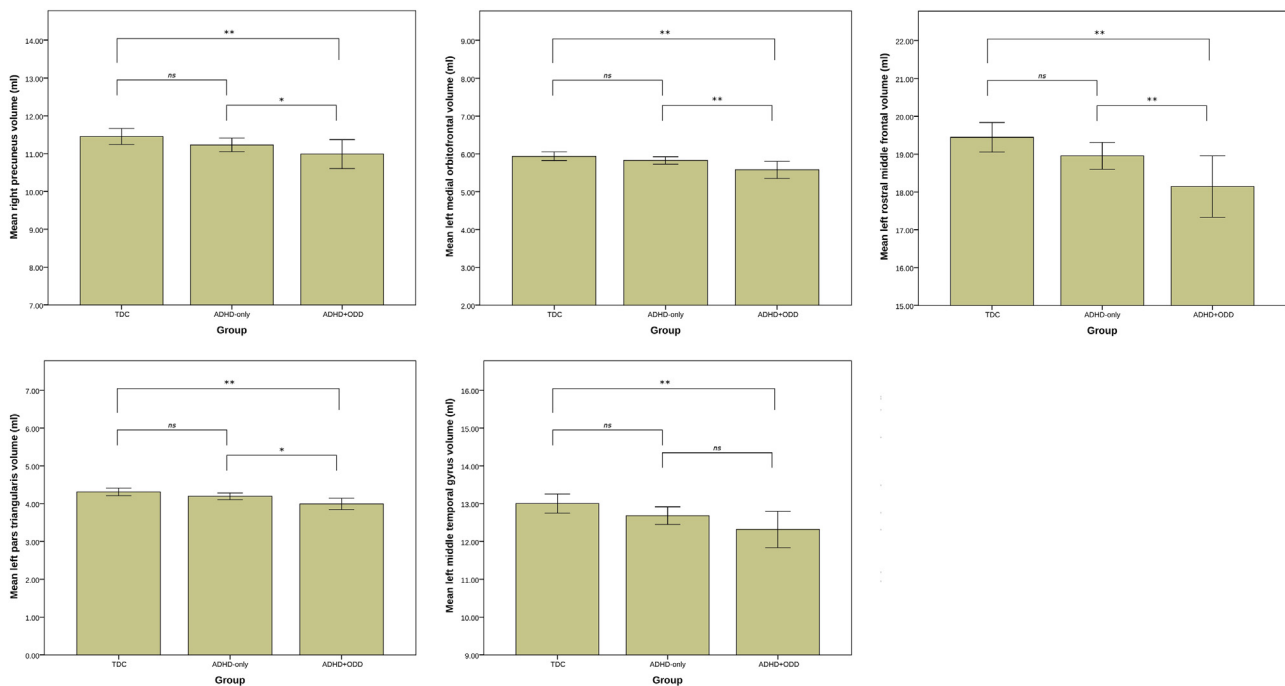


Figure 3. Disorder-specific volumetric reductions. Volumes are provided in milliliters (mL), and the error bars represent 95% confidence intervals. ADHD, attention-deficit/hyperactivity disorder; ns, not significant; ODD, oppositional defiant disorder; TDC, typically developing control subjects. * $p < .05$, ** $p < .01$, *** $p < .001$.

parietal gyrus $p_{\text{FDR-corrected}} = .013$, right lateral orbitofrontal $p_{\text{FDR-corrected}} = .019$, left lateral orbitofrontal $p_{\text{FDR-corrected}} = .023$, and right superior frontal $p_{\text{FDR-corrected}} = .037$). Finally, for all four structures, the ADHD+ODD-specific reduction remained significant (left rostral middle frontal $p_{\text{FDR-corrected}} = .006$, left medial orbitofrontal $p_{\text{FDR-corrected}} = .008$, left pars triangularis $p_{\text{FDR-corrected}} = .012$, and right precuneus $p_{\text{FDR-corrected}} = .033$). The disorder-specific reduction in the left middle temporal gyrus for the ADHD+ODD compared with the control group, became also significant between the ADHD+ODD and ADHD-only group ($p = .044$).

DISCUSSION

We found several structures that showed volumetric abnormalities in the ADHD+ODD and/or ADHD-only group compared with TDC subjects. Frontal regions showed the hypothesized linear decrease in volume (ADHD+ODD < ADHD-only < controls). Unlike others (29), we found no lateralization for the volumetric abnormalities. After accounting for ADHD symptom severity, most of the linear volumetric reductions and all disorder-specific volumetric reductions for the ADHD+ODD group persisted. We found no cortical thickness abnormalities. Finally, there were no interactions between group and age for our outcome measures.

Our results show that abnormalities in frontal regions are most strongly pronounced in the ADHD+ODD group compared with the ADHD-only group, in line with our hypothesis. For the left pars triangularis, left medial orbitofrontal, and left rostral middle frontal gyri, ADHD+ODD

group-specific volumetric abnormalities were present. In addition, for the lateral orbitofrontal, right medial orbitofrontal, right caudal middle frontal, and right superior frontal gyrus, a linear volumetric decrease was present, with the largest reductions in the ADHD+ODD group, followed by the ADHD-only group. Most group differences remained present after controlling for ADHD symptom severity, suggesting that these larger abnormalities are driven by both ADHD and ODD and result in a “double burden.” This finding is in line with neurocognitive findings of impairments in inhibitory control, attention, decision making, and working memory, all functions that are heavily dependent on integrity of the (superior) frontal cortex, for both individuals with ADHD and individuals with ODD, and the observation that these neurocognitive impairments are worse in the comorbid group (3,10,30). Consistent with these findings, we found a similar linear decrease in volume of the left inferior parietal gyrus over the groups that also remained present when controlling for ADHD severity. Thus, in line with the literature showing a neurocognitive double burden for individuals with ADHD+ODD, this group also shows greater reductions in neuroanatomical volumes than individuals with ADHD-only.

The results also showed structural abnormalities in brain regions for which we had no specific hypotheses. Similar volumetric reductions in both diagnostic groups were present for global measures of total gray matter and total cortical volume. In addition, areas with similar volumetric reductions included the isthmus of the cingulate gyrus, right parahippocampal gyrus, right inferior parietal gyrus, left lateral occipital gyrus, and the left precentral gyrus. These findings

are in line with previous studies showing widespread structural abnormalities in ADHD with and without comorbid ODD (2,3,20). These areas, among others, are associated with neurocognitive impairments frequently observed in individuals with ADHD and ODD, such as social learning, spatial working memory, reward processing, and motor functioning (3,10,30–32).

Disorder-specific abnormalities for the ADHD+ODD group were observed in the right precuneus, one of the structures that are associated with self-reflection processing, awareness, and feelings of guilt (33,34), and the left middle temporal gyrus, one of the structures that are associated with empathic processing (33). Abnormalities of the precuneus have been related to ODD/CD in a recent meta-analysis (21) and are in line with both observed neurocognitive impairments associated with ODD and with theoretical models on ODD that suggest that impairments in social skills, such as the failure to exhibit socially relevant behaviors and lack of guilt, are key features of the disorder (34–36). The left middle temporal gyrus, among other structures, is involved in empathic processing and has been linked to antisocial personality disorder and psychopathy, disorders that are related to ODD and show similar behavioral problems in terms of a lack of adequate empathic responses (10,37).

There was no evidence that volumetric abnormalities in the basal ganglia or cerebellum were specific for ADHD, which was not as hypothesized, because these were not present. Likewise, we found no evidence for cortical thickness abnormalities in either of the diagnostic groups, in contrast with previous studies (18). The absence of these abnormalities may be related to the mean age of our sample (16 years), which is relatively old compared with other studies (38). Especially for cortical thickness, the abnormalities seem to normalize with age (39,40). For the basal ganglia specifically, our sample with ADHD may have outgrown their deficits, as suggested in an extensive review that reported that adults with ADHD no longer show those abnormalities (2,41).

Our second hypothesis—that abnormalities in the amygdala and the insula would be driven by ODD rather than by ADHD—was not confirmed. One possible explanation is that previously reported abnormalities in amygdala and insula in ADHD+ODD groups are driven by the presence of comorbid CD, a comorbid condition that was absent in our sample. This suggestion is supported by the fact that in previous studies that showed an association between abnormalities in the amygdala and the insula and ODD/CD, only mixed samples of individuals with ODD and/or CD, rather than individuals with ODD-only, were assessed (15,42). Thus, since ODD has frequently been reported as a milder form of CD and possibly acts as a precursor for CD, it may be possible that these striatal structures may not be affected in ODD (43).

We found no support for the maturational delay hypothesis in terms of volume or cortical thickness. Although our sample was on average relatively old compared to earlier studies on brain development in ADHD, the age range was large enough to be able to detect possible developmental differences. Since the maturational delay seems most prominent in late childhood (7–13 years of age) and our sample ranged up to 29 years, a small effect of age may have been missed. Therefore, we

reanalyzed our data in an age-restricted subsample (7–13 years of age), with similar results (data not shown). It must be acknowledged that the cross-sectional design of our study limits the interpretability of the developmental results, and a longitudinal design would be required to specifically test the maturational delay hypothesis. Nevertheless, our findings are based on a large, well-defined sample following strict inclusion criteria and are in line with a recent longitudinal study including a large sample of children with ADHD (44). This suggests that maybe the maturational delay hypothesis holds true for a specific subset of individuals with ADHD, but not all.

Our study has some important strengths, such as the large sample and well-defined groups, but there are also some limitations. First, it would have been valuable to also have an ODD-only group to investigate whether the stronger abnormalities in the comorbid group are indeed related to ODD or rather to an interaction between ADHD and ODD. Second, even though we statistically controlled for effects of age, gender, and IQ, this is not the same as investigating matched groups. It is therefore possible that we missed small effects of subtle neuroanatomical abnormalities. Third, most previous studies in ADHD used voxel-based morphometry approaches, while the current study used a surface-based morphometry approach. This was preferred because surface-based morphometry has been shown to be most robust across different scanners (45). Although surface-based morphometry and voxel-based morphometry are different approaches, results in terms of cortical volume from both approaches are highly correlated (46). Furthermore, our voxelwise results were nonsignificant. Although the approaches differ substantially, both have their merits and they may be seen as complementary (47). In addition, our findings did largely overlap with the uncorrected voxelwise results, indicating that abnormalities were distributed rather than focal. Fourth, the prevalence of comorbid ODD in our sample is relatively low (22%) compared to other studies, but is in line with the idea that comorbid problems in ADHD emerge early in childhood and remit during adolescence (48), and is a consequence of the strict inclusion criteria applied (e.g., no mood/anxiety disorders, no CD). However, ODD severity was still comparable with other studies (mean 5.2 [range 4–8] symptoms).

Taken together, our study showed that both individuals with ADHD-only and ADHD+ODD show volumetric reductions in total gray matter and in brain areas crucial for attention, (working) memory, and decision making, but do not show abnormalities in similar brain areas in cortical thickness. Given the absence of cortical thickness abnormalities, the observed volumetric reductions are most likely driven by reduced surface area development of the involved structures (49). Post hoc analyses confirmed reduced surface area for the diagnostic groups for the majority (79%) of structures for which volumetric reductions were observed (Supplemental Figure S3). This is in line with a study that showed regional variation in the contribution of thickness and surface area to volumetric differences (50). For the other areas, it may be that small abnormalities in cortical thickness and surface area together resulted in the observed volumetric reductions, but this remains speculative. In addition, the volumetric reductions in the frontal lobes were largest in the ADHD+ODD group, possibly underlying the larger impairments in neurocognitive

functions commonly observed in this comorbid group (24,51,52). Thus, individuals with ADHD+ODD seem to face a double burden and show an accumulation of the deficits associated with each of the separate disorders. Moreover, there were disorder-specific abnormalities for the ADHD+ODD group not only in the frontal regions, but also in the precuneus and the middle temporal gyrus, in line with neurocognitive findings of impairments in social skills in individuals with (comorbid) ODD.

ACKNOWLEDGMENTS AND DISCLOSURES

This work was supported by National Institutes of Health Grant Nos. R01MH62873 and R13MH059126 and National Institute of Mental Health Grant No. R01MH094469 (to SVF), Netherlands Organization for Scientific Research Large Investment Grant No. 1750102007010 and Netherlands Organization for Scientific Research Brain and Cognition Grant No. 056-24-011 (to JKB), European Union Seventh Framework Programs AGGRESSO-TYPE (Grant No. 602805 to BF) and MATRICS (Grant No. 603016 to PJH and CAH), and by grants from Radboud University Medical Center (to JKB), University Medical Center Groningen and Accare (to PJH and CAH), and Vrije Universiteit Amsterdam (to JO). BF is supported by a Vici grant from the Netherlands Organization for Scientific Research (016-310-669).

JKB has been in the past 3 years a consultant to, member of the advisory board, and/or speaker for Eli Lilly, Janssen Cilag BV, Lundbeck, Medice, Roche, Servier, and Shire. He is not an employee of any of these companies, and not a stock shareholder of any of these companies. He has no other financial or material support, including expert testimony, patents, and royalties. BF received an educational speaking fee from Merz. PJH has been in the past 3 years a consultant to or member of the advisory board for Shire. JO has received unrestricted investigator initiated research grants from Shire Pharmaceuticals. SVF received income, travel expenses, and/or research support from and/or has been on an advisory board for Akili Interactive Labs, Alcobra, CogCubed, Impax, Ironshore, NeuroLifeSciences, Neurovance, Pfizer, Shire, and VAYA Pharma and has received research support from the K.G. Jebsen Centre for Research on Neuropsychiatric Disorders, University of Bergen, Bergen, Norway. With his institution, he has US patent US20130217707 A1 for the use of sodium-hydrogen exchange inhibitors in the treatment of attention-deficit/hyperactivity disorder. In previous years, he received consulting fees or was on advisory boards or participated in continuing medical education programs sponsored by Alcobra, Eli Lilly, Janssen, McNeil, Novartis, Otsuka, Pfizer, and Shire. Dr. Faraone receives royalties from books published by Guilford Press (*Straight Talk about Your Child's Mental Health*), Oxford University Press (*Schizophrenia: The Facts*), and Elsevier (*ADHD: Non-Pharmacologic Treatments*). All other authors report no biomedical financial interests or potential conflicts of interest.

ARTICLE INFORMATION

From the Section of Clinical Neuropsychology (SDSN, ML, DJH, JO), Vrije Universiteit Amsterdam, Amsterdam; Departments of Cognitive Neuroscience (CUG, KV, JKB) and Human Genetics and Psychiatry (BF), Donders Institute for Brain, Cognition and Behaviour, and the Karakter Child and Adolescent Psychiatry University Center (CUG, JKB), Nijmegen; and the Department of Psychiatry (CAH, PJH), University Medical Center Groningen, University of Groningen, Groningen, The Netherlands; Medical Research Council Social, Genetic and Developmental Psychiatry Centre, Institute of Psychiatry, Psychology and Neuroscience (CUG), King's College London, London, United Kingdom; Departments of Psychiatry and Neuroscience and Physiology (SVF), State University of New York Upstate Medical University, Syracuse, New York; K.G. Jebsen Center (SVF), Bergen, Norway.

Address correspondence to Siri D.S. Noordermeer, M.Sc., Vrije Universiteit Amsterdam, Clinical Neuropsychology, Van der Boechorststraat 1, Amsterdam 1081 BT, The Netherlands; E-mail: s.d.s.noordermeer@vu.nl

Received May 20, 2016; revised and accepted Jul 6, 2017.

Supplementary material cited in this article is available online at <http://dx.doi.org/10.1016/j.biopsych.2017.07.008>.

REFERENCES

- American Psychiatric Association (2013): Diagnostic and Statistical Manual of Mental Disorders (DSM-5). Arlington, VA: American Psychiatric Association.
- Rubia K, Alegria A, Brinson H (2014): Imaging the ADHD brain: Disorder-specificity, medication effects and clinical translation. *Expert Rev Neurother* 14:519–538.
- Faraone SV, Asherson P, Banaschewski T, Biederman J, Buitelaar JK, Ramos-Quiroga JA, et al. (2015): Attention-deficit/hyperactivity disorder. *Nat Rev Dis Primers* 1:15020.
- Villemonteix T, De Brito SA, Kavec M, Baleriaux D, Metens T, Slama H, et al. (2015): Grey matter volumes in treatment naive vs. chronically treated children with attention deficit/hyperactivity disorder: A combined approach. *Eur Neuropsychopharmacol* 25:1118–1127.
- Frodl T, Stauber J, Schaaff N, Koutsouleris N, Scheuerecker J, Ewers M, et al. (2010): Amygdala reduction in patients with ADHD compared with major depression and healthy volunteers. *Acta Psychiatr Scand* 121:111–118.
- Perlov E, Philipson A, Tebartz van Elst L, Ebert D, Henning J, Maier S, et al. (2008): Hippocampus and amygdala morphology in adults with attention-deficit hyperactivity disorder. *J Psychiatry Neurosci* 33: 509–515.
- Plessen KJ, Bansal R, Zhu H, Whiteman R, Amat J, Quackenbush GA, et al. (2006): Hippocampus and amygdala morphology in attention-deficit/hyperactivity disorder. *Arch Gen Psychiatry* 63:795–807.
- Lopez-Larson MP, King JB, Terry J, McGlade EC, Yurgelun-Todd D (2012): Reduced insular volume in attention deficit hyperactivity disorder. *Psychiatry Res* 204:32–39.
- Maier S, Perlov E, Graf E, Dieter E, Sobanski E, Rump M, et al. (2015): Discrete global but no focal gray matter reductions in unmedicated adult patients with attention-deficit/hyperactivity disorder. *Biol Psychiatry* 80:905–915.
- Burke JD, Loeber R, Birmaher B (2002): Oppositional defiant disorder and conduct disorder: A review of the past 10 years, part II. *J Am Acad Child Adolesc Psychiatry* 41:1275–1293.
- Loeber R, Burke JD, Lahey BB, Winters A, Zera M (2000): Oppositional defiant and conduct disorder: a review of the past 10 years, part I. *J Am Acad Child Adolesc Psychiatry* 39:1468–1484.
- Connor DF, Doerfler LA (2008): ADHD with comorbid oppositional defiant disorder or conduct disorder: Discrete or nondistinct disruptive behavior disorders? *J Atten Disord* 12:126–134.
- Anderson NE, Kiehl KA (2012): The psychopath magnetized: insights from brain imaging. *Trends Cogn Sci* 16:52–60.
- Biederman J, Petty CR, Monuteaux MC, Mick E, Parcell T, Westerberg D, et al. (2008): The longitudinal course of comorbid oppositional defiant disorder in girls with attention-deficit/hyperactivity disorder: Findings from a controlled 5-year prospective longitudinal follow-up study. *J Dev Behav Pediatr* 29:501–507.
- Stevens MC, Haney-Caron E (2012): Comparison of brain volume abnormalities between ADHD and conduct disorder in adolescence. *J Psychiatry Neurosci* 37:389–398.
- McAlonan GM, Cheung V, Cheung C, Chua SE, Murphy DG, Suckling J, et al. (2007): Mapping brain structure in attention deficit-hyperactivity disorder: A voxel-based MRI study of regional grey and white matter volume. *Psychiatry Res* 154:171–180.
- Sasayama D, Hayashida A, Yamasue H, Harada Y, Kaneko T, Kasai K, et al. (2010): Neuroanatomical correlates of attention-deficit-hyperactivity disorder accounting for comorbid oppositional defiant disorder and conduct disorder. *Psychiatry Clin Neurosci* 64:394–402.
- Shaw P, Eckstrand K, Sharp W, Blumenthal J, Lerch JP, Greenstein D, et al. (2007): Attention-deficit/hyperactivity disorder is characterized by a delay in cortical maturation. *Proc Natl Acad Sci U S A* 104: 19649–19654.
- Villemonteix T, De Brito SA, Slama H, Kavec M, Baleriaux D, Metens T, et al. (2015): Grey matter volume differences associated with gender in children with attention-deficit/hyperactivity disorder: A voxel-based morphometry study. *Dev Cogn Neurosci* 14:32–37.
- Nakao T, Radua J, Rubia K, Mataix-Cols D (2011): Gray matter volume abnormalities in ADHD: Voxel-based meta-analysis exploring the

- effects of age and stimulant medication. *Am J Psychiatry* 168: 1154–1163.
21. Noordermeer SD, Luman M, Oosterlaan J (2016): A systematic review and meta-analysis of neuroimaging in oppositional defiant disorder (ODD) and conduct disorder (CD) taking attention-deficit hyperactivity disorder (ADHD) into account. *Neuropsychol Rev* 26:44–72.
 22. Fahim C, He Y, Yoon U, Chen J, Evans A, Perusse D (2011): Neuroanatomy of childhood disruptive behavior disorders. *Aggress Behav* 37:326–337.
 23. von Rhein D, Mennes M, van Ewijk H, Groenman AP, Zwiers MP, Oosterlaan J, *et al.* (2015): The NeuroIMAGE study: A prospective phenotypic, cognitive, genetic and MRI study in children with attention-deficit/hyperactivity disorder. Design and descriptives. *Eur Child Adolesc Psychiatry* 24:265–281.
 24. Noordermeer SD, Luman M, Buitelaar JK, Hartman CA, Hoekstra PJ, Franke B, *et al.* (2015): Neurocognitive deficits in attention-deficit/hyperactivity disorder with and without comorbid oppositional defiant disorder [published online ahead of print Oct 20]. *J Atten Disord*.
 25. Fischl B, Salat DH, van der Kouwe AJ, Makris N, Segonne F, Quinn BT, *et al.* (2004): Sequence-independent segmentation of magnetic resonance images. *Neuroimage* 23(suppl 1):S69–S84.
 26. Dale AM, Fischl B, Sereno MI (1999): Cortical surface-based analysis. I. Segmentation and surface reconstruction. *Neuroimage* 9:179–194.
 27. Desikan RS, Segonne F, Fischl B, Quinn BT, Dickerson BC, Blacker D, *et al.* (2006): An automated labeling system for subdividing the human cerebral cortex on MRI scans into gyral based regions of interest. *Neuroimage* 31:968–980.
 28. Benjamini Y, Hochberg Y (1995): Controlling the false discovery rate: A practical and powerful approach to multiple testing. *J R Stat Soc Series B Methodol* 57:289–300.
 29. Mohamed SM, Borger NA, Geuze RH, van der Meere JJ (2015): Brain lateralization and self-reported symptoms of ADHD in a population sample of adults: A dimensional approach. *Front Psychol* 6:1418.
 30. Vaidya CJ (2012): Neurodevelopmental abnormalities in ADHD. *Curr Topics Behav Neurosci* 9:49–66.
 31. Aminoff EM, Kveraga K, Bar M (2013): The role of the parahippocampal cortex in cognition. *Trends Cogn Sci* 17:379–390.
 32. Bush G, Luu P, Posner MI (2000): Cognitive and emotional influences in anterior cingulate cortex. *Trends Cogn Sci* 4:215–222.
 33. Farrow TF, Zheng Y, Wilkinson ID, Spence SA, Deakin JF, Tarrier N, *et al.* (2001): Investigating the functional anatomy of empathy and forgiveness. *Neuroreport* 12:2433–2438.
 34. Matthys W, Vanderschuren LJ, Schutter DJ, Lochman JE (2012): Impaired neurocognitive functions affect social learning processes in oppositional defiant disorder and conduct disorder: Implications for interventions. *Clin Child Fam Psychol Rev* 15:234–246.
 35. Zhang S, Li CS (2012): Functional connectivity mapping of the human precuneus by resting state fMRI. *Neuroimage* 59:3548–3562.
 36. Bastin C, Harrison BJ, Davey CG, Moll J, Whittle S (2016): Feelings of shame, embarrassment and guilt and their neural correlates: A systematic review. *Neurosci Biobehav Rev* 26:455–471.
 37. Gregory S, fytche D, Simmons A, Kumari V, Howard M, Hodgins S, *et al.* (2012): The antisocial brain: Psychopathy matters. *Arch Gen Psychiatry* 69:962–972.
 38. Greven CU, Bralten J, Mennes M, O'Dwyer L, van Hulzen KJ, Rommelse N, *et al.* (2015): Developmentally stable whole-brain volume reductions and developmentally sensitive caudate and putamen volume alterations in those with attention-deficit/hyperactivity disorder and their unaffected siblings. *JAMA Psychiatry* 72:490–499.
 39. Shaw P, Lerch J, Greenstein D, Sharp W, Clasen L, Evans A, *et al.* (2006): Longitudinal mapping of cortical thickness and clinical outcome in children and adolescents with attention-deficit/hyperactivity disorder. *Arch Gen Psychiatry* 63:540–549.
 40. Shaw P, Sharp WS, Morrison M, Eckstrand K, Greenstein DK, Clasen LS, *et al.* (2009): Psychostimulant treatment and the developing cortex in attention deficit hyperactivity disorder. *Am J Psychiatry* 166:58–63.
 41. Hoogman M, Bralten J, Hibar DP, Mennes M, Zwiers MP, Schweren LS, *et al.* (2017): Subcortical brain volume differences in participants with attention deficit hyperactivity disorder in children and adults: A cross-sectional mega-analysis. *Lancet Psychiatry* 4:310–319.
 42. Fairchild G, Passamonti L, Hurford G, Hagan CC, von dem Hagen EA, van Goozen SH, *et al.* (2011): Brain structure abnormalities in early-onset and adolescent-onset conduct disorder. *Am J Psychiatry* 168:624–633.
 43. Loeber R, Burke J, Pardini DA (2009): Perspectives on oppositional defiant disorder, conduct disorder, and psychopathic features. *J Child Psychol Psychiatry* 50:133–142.
 44. Ambrosino S, de Zeeuw P, Wierenga LM, van Dijk S, Durston S (2017): What can cortical development in attention-deficit/hyperactivity disorder teach us about the early developmental mechanisms involved? *Cerebral Cortex* 27:4624–4634.
 45. Clarkson MJ, Cardoso MJ, Ridgway GR, Modat M, Leung KK, Rohrer JD, *et al.* (2011): A comparison of voxel and surface based cortical thickness estimation methods. *Neuroimage* 57:856–865.
 46. Fergusson DM, Swain-Campbell NR, Horwood LJ (2002): Deviant peer affiliations, crime and substance use: A fixed effects regression analysis. *J Abnormal Child Psychol* 30:419–430.
 47. Giuliani NR, Calhoun VD, Pearlson GD, Francis A, Buchanan RW (2005): Voxel-based morphometry versus region of interest: A comparison of two methods for analyzing gray matter differences in schizophrenia. *Schizophr Res* 74:135–147.
 48. van Lieshout M, Luman M, Twisk JW, van Ewijk H, Groenman AP, Thissen AJ, *et al.* (2016): A 6-year follow-up of a large European cohort of children with attention-deficit/hyperactivity disorder-combined subtype: Outcomes in late adolescence and young adulthood. *Eur Child Adolesc Psychiatry* 25:1007–1017.
 49. Raznahan A, Shaw P, Lalonde F, Stockman M, Wallace GL, Greenstein D, *et al.* (2011): How does your cortex grow? *J Neurosci* 13:7174–7177.
 50. Silk TJ, Beare R, Malpas C, Adamson C, Vilgis V, Vance A, *et al.* (2016): Cortical morphometry in attention deficit/hyperactivity disorder: Contribution of thickness and surface area to volume. *Cortex* 82:1–10.
 51. Qian Y, Shuai L, Cao Q, Chan RC, Wang Y (2010): Do executive function deficits differentiate between children with attention deficit hyperactivity disorder (ADHD) and ADHD comorbid with oppositional defiant disorder? A cross-cultural study using performance-based tests and the behavior rating inventory of executive function. *Clin Neuropsychol* 24:793–810.
 52. Youngwirth SD, Harvey EA, Gates EC, Hashim RL, Friedman-Weieneth JL (2007): Neuropsychological abilities of preschool-aged children who display hyperactivity and/or oppositional-defiant behavior problems. *Child Neuropsychol* 13:422–443.
 53. Schweren LJ, Hartman CA, Heslenfeld DJ, van der Meer D, Franke B, Oosterlaan J, *et al.* (2015): Thinner medial temporal cortex in adolescents with attention-deficit/hyperactivity disorder and the effects of stimulants. *J Am Acad Child Adolesc Psychiatry* 54:660–667.