

Anti-Xa activity in patients with hepatocellular carcinoma

To the Editor,

Patients with chronic liver disease are characterized by various disturbances in the haemostatic balance [1]. In hepatocellular carcinoma (HCC), several abnormalities of glycosaminoglycans (GAGs) compared to normal liver tissue have been reported [2]. In particular, endogenous circulating heparan sulfates detected by anti-Xa assay were reported in a patient with HCC [3]. In our recent study, assessing anti-Xa activity during acute variceal bleeding in cirrhotic patients, we found detectable anti-Xa levels in HCC patients [4]. This study was designed to evaluate the role of endogenous heparinoids in HCC patients.

Our study comprised three groups of subjects: healthy individuals (n=10), HCC patients (n=25) and patients with other malignancies: cholangiocarcinoma (n=5) and pancreatic cancer (n=8). Patients were observed over a median follow up period of 27 (9-33) months. The effect of endogenous GAGs was measured using a Xa inhibition clotting assay.

The baseline characteristics of the study population are shown in Table I. All patients with HCC had undetectable anti-Xa. In the group with the other malignancies, three patients had detectable anti-Xa (n=3, 23.1%). In the control

group, one patient had detectable anti-Xa (n=1, 10%). Correlations regarding the anti-Xa status and age of the patients, gender, presence of cancer, type of cancer, presence of cirrhosis and malignancy stage were performed. All of them were non-significant. Between the anti-Xa status in the HCC group and in the group with other malignancies and the group with pancreatic cancer there was no difference, but we found a significant difference between the HCC and the cholangiocarcinoma patients (0 and 2 patients, respectively, had detectable anti-Xa) (p=0.025).

A significant difference in survival was determined by Kaplan Meier analysis among the different patient groups (p=0.012). The median survival time was 30, 29 and 25 months for the HCC, the pancreatic cancer and the cholangiocarcinoma group, respectively. In the model for survival analysis which included the type of malignancy, age of the patients, malignancy stage, anti-Xa status, presence of cirrhosis and development of thrombotic complications during follow-up, the only factor which was identified as a prognostic factor for survival was the type of cancer. In particular, there was a statistically significant difference between patients with HCC and patients with cholangiocarcinoma: HR = 5.26, 95%CI 1.473-18.806 (p=0.011).

The results of this study show that there are no detectable endogenous heparinoids in HCC patients. There is no clear

Table I. Baseline characteristics of the study groups

	Group 1 (n=25)	Group 2 (n=13)	Group 3 (n=10)	p value
Age, years (range)	69 (42-93)	71 (59-84)	40 (24-47)	0.001*
Sex male/female (%)	22/3 (88/ 12)	11/ 2 (84.6/ 15.4)	3/ 7 (30/ 70)	0.001
Cirrhosis, n (%)	19 (76)	0 (0)	0 (0)	na
CP score (range)	8 (5-23)	na	na	na
CP stage A/B/C (%)	12/ 11/ 1 (48/ 44/ 4)	na	na	na
MELD (range)	6 (5-14)	na	na	na
BCLC stage A/B/C/D (%)	5/ 9/ 4/ 1 (20/ 36/ 16/ 4)	na	na	na
TNM stage I/II/III/IV (%)	na	0/ 1/ 3/ 9 (0/ 7.7/ 23.1/ 69.2)	na	na
Detectable anti-Xa, n (%)	0 (0)	3 (23.2)	1 (10)	0.006

CP: Child Pugh; na: non available; *p=0.3 between group 1 and 2

explanation for the different results in this versus our previous study. However, there is a significant difference between the median values of MELD in the HCC group in this study compared to the previous one (median MELD: 6 vs10, respectively). In addition, the sample size (HCC patients) in the first study was small. Lastly, the anti-Xa detection method in the two studies was different.

In conclusion, we have shown that there is no anti-Xa activity in patients with HCC. There is a need for a further investigation of the use of GAGs as prognostic factors in other malignancies, as this issue remains controversial.

Christos Triantos¹, Andreas Emmanuil², Ioanna Aggeletopoulou¹, Chrysostomos Tsolias¹, Xristina Grigoropoulou¹, Eleni Jelastopulu³, Nikolaos Koukias¹, Stelios Assimakopoulos⁴, Charalambos Gogos⁴, Chrisoula Labropoulou-Karatzas⁴, Konstantinos Thomopoulos¹

1) Department of Gastroenterology, University Hospital of Patras,
2) Department of Hematology, University Hospital of Patras,
3) Department of Public Health, Medical School, University of Patras,
4) Department of Internal Medicine, University Hospital of Patras, Patras, Greece

Correspondence: Christos Triantos, chtriantos@hotmail.com

Conflicts of interest: No conflicts to declare.

DOI: <http://dx.doi.org/10.15403/jgld.2014.1121.261.axa>

REFERENCES

1. Blasi A. Coagulopathy in liver disease: Lack of an assessment tool. *World J Gastroenterol* 2015;21:10062-10071. doi: [10.3748/wjg.v21.i35.10062](https://doi.org/10.3748/wjg.v21.i35.10062)
2. Kojima J, Nakamura N, Kanatani M, Omori K. The glycosaminoglycans in human hepatic cancer. *Cancer Res* 1975;35:542-547.
3. Wages DS, Staprans I, Hambleton J, Bass NM, Corash L. Structural characterization and functional effects of a circulating heparan sulfate in a patient with hepatocellular carcinoma. *Am J Hematol* 1998;58:285-292. doi: [10.1002/\(SICI\)1096-8652\(199808\)58:4<285::AID-AJH6>3.0.CO;2-M](https://doi.org/10.1002/(SICI)1096-8652(199808)58:4<285::AID-AJH6>3.0.CO;2-M)
4. Triantos C, Louvros E, Kalafateli M, et al. Endogenous heparinoids detected by anti-Xa activity are present in blood during acute variceal bleeding in cirrhosis. A prospective study. *J Gastrointest Liver Dis* 2014;23:187-194. doi: [10.15403/jgld.2014.1121.232.cht1](https://doi.org/10.15403/jgld.2014.1121.232.cht1)

Celiac disease: past, present and future – boundless explorations of a disease of modern times

To the Editor,

We read with great interest the recent paper by van Gils et al. [1], describing gender and age differences in celiac disease (CD) at the time of its diagnosis in The Netherlands. The results of a well-conducted retrospective database study among members of the Dutch Celiac Society are presented, showing an overall ratio of women to men of 2.4:1 and the absence of age specificity of CD diagnosis (0-88 years of age), with more than one third of population diagnosed in early childhood. In adults, median age differed between males and females, with 52 and 44 years, respectively [1]. The authors rightly postulate that

this may be probably accounted for by hormonal differences between genders, genetic inheritance, and proper medical care from which women benefit more than men [1]. Though we agree with most of the authors' comments, we have, however, a query on the methods used for CD diagnosis. In the study performed, diagnosis relies purely on the histological analysis of biopsy specimens without any mention of serological or even genetic testing. Traditionally, small-bowel biopsy has played a central role since the late 50s [2], but the confirmation of CD is currently based on a combination of findings including medical history, serology, physical examination and genetic testing. Diagnosing CD based on histology samples alone may be risky, allowing an overestimation of disease prevalence. At present, a special role is attributed to HLA typing due to its negative predictive value of almost 100% [3].

The geo-epidemiology of CD varies greatly, but several reports have shown that CD is increasing in frequency in developing areas [4]. The widespread dissemination of CD is not surprising, yet there is still a lack of knowledge regarding CD epidemiology in some countries, such as Romania. Is CD infrequent in our country, or just underdiagnosed? In order to find an answer to these questions, our group conducted a retrospective study between 2003 and 2013 at a tertiary referral centre in Iasi, Romania [5]. When reviewing the yearly distribution of patients, an increase in prevalence of CD was noted, predominantly among young adult female patients (median age 33 years). Extra-intestinal manifestations were documented in 32.8% of the patients, proving the versatile nature of this autoimmune enteropathy; hence, the need to screen "outside the box" [5]. Unpublished data regarding the genetic profile of a prospectively enrolled Romanian CD cohort shows a 53% predominance of the HLA-DQ2 heterodimer, either in homozygous or heterozygous state, 3% DQ2.5/DQ8 heterozygous genotype, and 7.5% DQ8 genotype in heterozygous state, with a DQA1*05 allele frequency of 75% and 77.8% for DQB1*02. According to the Allele Frequency Net Database, in The Netherlands the prevalence of DQB1*02 in the general population is estimated to be 23.7%, and 20% for DQA1*05. In the Romanian population, it is estimated that the frequency of DQB2*02 reaches 31.2%, with no current data regarding DQA1*05 prevalence [6]. Further studies are required to accurately determine the genetic profile of these communities.

Future efforts should address the need for a national CD patient database in order to access reliable and consistent information to respond to the specific needs of the Romanian society and provide knowledge as well as even prevention tools. New epidemiological studies aimed at assessing worldwide distribution of CD, the role of environmental factors and relevant parameters such as CD predisposing genotypes will play a key role in increasing detection rate for this clinical chameleon.

Roxana Maxim, Anca Trifan, Alina Plesa

Gr. T. Popa University of Medicine and Pharmacy, and Institute of Gastroenterology and Hepatology, St. Spiridon Emergency Hospital, Iasi, Romania

Correspondence: Anca Trifan, ancatrifan@yahoo.com

Conflicts of interest: No conflicts to declare.

DOI: <http://dx.doi.org/10.15403/jgld.2014.1121.261.cel>

REFERENCES

1. van Gils T, Rootsart B, Bouma G, Mulder CJ. Celiac Disease in The Netherlands: Demographic Data of Members of the Dutch Celiac Society. *J Gastrointest Liver Dis* 2016;25:441-445. doi:[10.15403/jgld.2014.1121.254.gil](https://doi.org/10.15403/jgld.2014.1121.254.gil)
2. Shiner M. Small intestinal biopsy: diagnostic and research value. *Proc R Soc Med* 1959;52:10-14.
3. Husby S, Koletzko S, Korponay-Szabo IR, et al. European Society for Pediatric Gastroenterology, Hepatology, and Nutrition guidelines for the diagnosis of coeliac disease. *J Pediatr Gastroenterol Nutr* 2012;54:136-160. doi:[10.1097/MPG.0b013e31821a23d0](https://doi.org/10.1097/MPG.0b013e31821a23d0)
4. Mustalahti K, Catassi C, Reunanen A, et al. The prevalence of celiac disease in Europe: results of a centralized, international mass screening project. *Ann Med* 2010;42:587-595. doi:[10.3109/07853890.2010.505931](https://doi.org/10.3109/07853890.2010.505931)
5. Maxim R, Plesa A, Ciortescu I, Girleanu I, Stoica O, Trifan AV. Celiac disease: 10-year experience in a Romanian tertiary center. *Rev Med Chir Soc Med Nat Iasi* 2014;118:986-991.
6. Gonzalez-Galarza FE, Christmas S, Middleton D, Jones AR. Allele frequency net: a database and online repository for immune gene frequencies in worldwide populations. *Nucleic Acids Res* 2011;39:D913-D919. doi:[10.1093/nar/gkq1128](https://doi.org/10.1093/nar/gkq1128)

Reply

We thank Trifan and colleagues for their comments on our article "Celiac disease in The Netherlands: demographic data of members of the Dutch Celiac Society" that was published in *JGLD* in December 2016 [1]. They queried the methods used for celiac disease (CD) diagnosis in our study, suggesting that diagnosis was based only on biopsy results. We agree that adult CD diagnosis has to be based on a combination of serological tests, duodenal histology and, when recommended, complemented by HLA typing. Since CD is a clinical chameleon, the absence of significant symptoms does not exclude the diagnosis of CD.

As stated in the Methods [1], only the date of biopsy and diagnosis were recorded in the database. Obviously, this does not exclude the appliance of other diagnostic parameters in the diagnostic work up in these patients. In fact, it is reasonable to assume that most, if not all, patients in The Netherlands are diagnosed according to the current diagnostic criteria including both biopsy and serology when diagnosed in adulthood.

It is very unlikely that the few patients who were diagnosed based on histology only will affect outcome. Such patients could possibly suffer from other non-CD causes of villous atrophy [2, 3].

There is a need for national CD patient registries in different countries for epidemiological purposes, but more importantly, for gaining a better understanding of the natural history, prognosis and complications of this common disease.

Tom van Gils¹, Bianca Rootsart², Gerd Bouma¹, Chris J.J. Mulder¹

1) Dept Gastroenterology and Hepatology, VU University Medical Center, Amsterdam; 2) Dutch Celiac Society, Naarden, The Netherlands

Correspondence: Tom van Gils, t.vangils@vumc.nl

Conflicts of interest: No conflicts to declare.

DOI: <http://dx.doi.org/10.15403/jgld.2014.1121.261.gil>

REFERENCES

1. van Gils T, Rootsart B, Bouma G, Mulder CJ. Celiac Disease in The Netherlands: Demographic Data of Members of the Dutch Celiac Society. *J Gastrointest Liver Dis* 2016;25:441-445. doi:[10.15403/jgld.2014.1121.254.gil](https://doi.org/10.15403/jgld.2014.1121.254.gil)
2. Aziz I, Peerally MF, Barnes JH, et al. The clinical and phenotypical assessment of seronegative villous atrophy; a prospective UK centre experience evaluating 200 adult cases over a 15-year period (2000-2015). *Gut* 2016. doi:[10.1136/gutjnl-2016-312271](https://doi.org/10.1136/gutjnl-2016-312271)
3. van Gils T, van de Donk T, Bouma G, van Delft F, Neefjes-Borst EA, Mulder CJ. The first cases of collagenous sprue successfully treated with thioguanine. *BMJ Open Gastroenterol* 2016;3:e000099. doi:[10.1136/bmjgast-2016-000099](https://doi.org/10.1136/bmjgast-2016-000099)

Fatal acute liver failure during Ritonavir-boosted Paritaprevir, Ombitasvir and Dasabuvir plus Ribavirin therapy

To the Editor,

We read with great interest the case report published in your journal by Masetti et al. [1] describing a patient with acute liver failure during Ritonavir-boosted Paritaprevir, Ombitasvir and Dasabuvir plus Ribavirin therapy in a 84-year-old Caucasian man with chronic compensated hepatitis C virus (HCV) genotype 1b cirrhosis. This patient developed hepatic failure after 13 days of treatment, without any identifiable precipitating factor. In his past medical history the patient had had a partial portal vein thrombosis (PVT) completely resolved after Fondaparinux treatment.

We had a similar case, a 65-year-old Caucasian female, with compensated HCV genotype 1b cirrhosis, treated with the same drug association, who developed acute severe hepatic failure three days after the treatment initiation. Our patient had had ischemic transitory liver imagistic lesions, initially revealed on computer-tomography (CT). The ischemic lesions had resolved spontaneously, without liver perfusion defects on a later magnetic resonance imaging (MRI) study. She did not take other medication.

At presentation our patient had high levels of bilirubinemia (total bilirubin 18 mg/dl, conjugated bilirubin 12 mg/dl), mild encephalopathy, no ascites and acute PVT. The prothrombin time was slightly prolonged (22 seconds). Mild cholestasis and hepatocytolysis were identified. No precipitating factor or infections were identified. The viral load was 434 UI/ml. The evolution was not favorable, with progressive liver failure

(higher levels of bilirubin, ascites in the context of low albumin levels, severe encephalopathy) till death (after 19 hospitalization days). The liver transplantation was declined, considering the PVT. An etiology for PVT, e.g. thrombophilia, was not documented in our case.

A possible causative link between the direct-acting-antivirals (DAAs), the development of PVT and the onset of acute severe liver insufficiency was debated. To date, the published literature data does not confirm this hypothesis. The effect of DAAs on coagulation in HCV-related liver cirrhosis was studied by Tripodi et al. [2] in a group of 28 cirrhotic patients. Their results brought arguments for improvement of the individual pro- and anticoagulants under the DAAs treatment [2]. The authors hypothesized that the DAAs do not substantially modify the balance of pro- and anticoagulants, but make it more stable at the end of the treatment [2].

Portal vein thrombosis can occur in liver cirrhosis; its incidence increases with the increasing severity of liver disease, and is less than 1% in well-compensated cirrhosis [3]. Literature data provides insufficient arguments for the worsening of liver function in the presence of PVT [3, 4].

In our case, similar to the case presented by Masetti et al. [1], an idiosyncratic pattern of drug-related acute liver failure is more likely, considering the early onset of clinical manifestation (after three days).

Based on 26 worldwide published cases of hepatic decompensation and liver failure in advanced cirrhotic patients treated with Viekira Pak (3D) and Technivie (Ombitasvir-Paritaprevir-Ritonavir plus RBV) [5], the FDA made a safety announcement regarding this category of patients. Patients with compensated liver cirrhosis and history of PVT should be reported and closely monitored.

Claudia Buzaș, Marcel Tanțău, Lidia Ciobanu

3rd Medical Clinic, Prof. Dr. Octavian Fodor Institute of Gastroenterology and Hepatology, Cluj-Napoca, Romania

Correspondence: Lidia Ciobanu, ciobanulidia@yahoo.com

Conflicts of interest: No conflicts to declare.

DOI: <http://dx.doi.org/10.15403/jgld.2014.1121.261.vir>

REFERENCES

- Masetti M, Magalotti D, Martino E, Andreone P, Scuteri A, Zoli M. A Case of Acute Liver Failure during Ritonavir-Boosted Paritaprevir, Ombitasvir and Dasabuvir Therapy in a Patient with HCV Genotype 1b Cirrhosis. *J Gastrointest Liver Dis* 2016;25:559-561. doi: [10.15403/jgld.2014.1121.254.tti](https://doi.org/10.15403/jgld.2014.1121.254.tti)
- Tripodi A, D'Ambrosio R, Padovan L, et al. Evaluation of coagulation during treatment with directly acting antivirals in patients with hepatitis C virus related cirrhosis. *Liver Int* 2017 Jan 27. doi: [10.1111/liv.13374](https://doi.org/10.1111/liv.13374)
- Harding DJ, Perera MT, Chen F, Olliff S, Tripathi D. Portal vein thrombosis in cirrhosis: Controversies and latest developments. *World J Gastroenterol* 2015;21:6769-6784. doi: [10.3748/wjg.v21.i22.6769](https://doi.org/10.3748/wjg.v21.i22.6769)
- Luca A, Caruso S, Milazzo M, et al. Natural course of extrahepatic nonmalignant partial portal vein thrombosis in patients with cirrhosis. *Radiology* 2012;265:124-132. doi: [10.1148/radiol.12112236](https://doi.org/10.1148/radiol.12112236)

- FDA Drug Safety Communication: FDA warns of serious liver injury with hepatitis C treatments Viekira Pak and Technivie. 10/22/2015. Available at: <https://www.fda.gov/Drugs/DrugSafety/ucm468634.htm>

Potential pitfalls of Viekira Pak™ therapy in patients with HCV genotype 1b cirrhosis

To the Editor,

The paper by Masetti et al. [1] reported a case of acute liver failure during Ritonavir-boosted Paritaprevir, Ombitasvir and Dasabuvir therapy in a patient with HCV genotype 1b cirrhosis. The FDA recommends the Viekira Pak™ regimen in patients with compensated liver cirrhosis [2]. However, the elevations of serum bilirubin, as well as alanine aminotransferase levels reported in clinical trials [3] warrant close monitoring during therapy.

A 60-year-old HCV genotype 1b infected female patient, diagnosed with compensated cirrhosis (Child Pugh A 6 and MELD 13), treatment-naïve, was admitted to our Unit on 19/11/2015 for initiating direct antiviral agents (DAAs) regimen. Esophageal varices grade II/III were detected without signs of bleeding, and the abdominal ultrasound showed no ascites. Baseline serum bilirubin was 2.1 mg/dL and international normalized ratio 1.4. The patient denied any history of alcohol abuse.

Fibromax indicated a F4 fibrosis. The alpha-fetoprotein was in normal ranges (5.5 IU/mL). The HCV-RNA level was 1,130,609 IU/mL. On 10/02/2016 the 3D plus RBV treatment was initiated. The first assessment after the initiation of therapy was performed at week 4, when patient's complaints were asthenia and fatigue; physical examination revealed jaundice, without other signs of hepatic decompensation.

Within 6 weeks of DAA therapy, the patient was admitted with dizziness, drowsiness, confused speech, disorientation, bleeding gums, jaundice and flapping tremor. Elevated levels of total bilirubin (up to 6.79 mg/dL), international normalized ratio levels (INR max 1.81) and low albumin levels (3.04 g/dL) were detected (Fig. 1); testing for viral acute hepatitis was negative and abdominal ultrasound revealed ascites in the Douglas pouch.

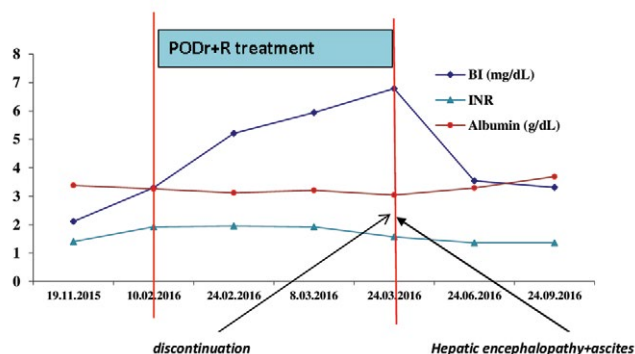


Fig. 1. Changes in laboratories in relation to antiviral therapy. Shortly after the initiation of hepatitis C treatment, the laboratory levels deteriorated indicating a decline in hepatic synthetic function. After treatment discontinuation, values slowly returned to baseline. PODr+R: Paritaprevir, Ombitasvir, Dasabuvir, Ritonavir and Ribavirin. BI: total bilirubin. INR: International normalized ratio.

Given the malaise of the patient, due to the Interferon-free treatment (the patient denied use of any other drugs in the last 6 months), discontinuation was decided. The patient was discharged after two weeks on therapy with diuretics and hepatoprotective drugs, with progressive remission of ascites and without clinical signs of encephalopathy. At three and six months after discontinuation of the antiviral therapy HCV RNA was assessed and viremia was undetectable.

The case reported by Masetti et al. demonstrates the possibility of severe liver failure due to the 3D therapy, characterized by grade 4 hyperbilirubinemia and coagulation disorders, with only mild elevation of liver enzymes, which is consistent with an idiosyncratic pattern of drug related acute liver failure [1]. Our case is characterized by two unexpected features: the occurrence of liver decompensation under an Interferon-free regimen in a patient with Child Pugh A cirrhosis and the sustained viral response (SVR) achieved already after 6 weeks of treatment.

Our report highlights the importance of close monitoring for liver decompensation. Hyperbilirubinemia represents a frequent finding during therapy. Aminotransferase levels do not tend to increase in parallel with bilirubin in DAA-related liver injury [4]. This pattern could delay the early recognition of severe liver injury, which requires therapy discontinuation.

Crina Fofiu, Daniela Dobru, Alina Boeriu

Department of Gastroenterology, University of Medicine and Pharmacy Tirgu Mures, Tirgu Mures, Romania

Correspondence: Daniela Dobru, danidobru@gmail.com

Conflicts of interest: No conflicts to declare.

DOI: <http://dx.doi.org/10.15403/jgld.2014.1121.261.pak>

REFERENCES

1. Masetti M, Magalotti D, Martino E, Andreone P, Scuteri A, Zoli M. A Case of Acute Liver Failure during Ritonavir-Boosted Paritaprevir, Ombitasvir and Dasabuvir Therapy in a Patient with HCV Genotype 1b Cirrhosis. *J Gastrointest Liver Dis* 2016;25:559-561. doi:[10.15403/jgld.2014.1121.254.tti](https://doi.org/10.15403/jgld.2014.1121.254.tti)
2. FDA Drug Safety Communication: FDA warns of serious liver injury risk with hepatitis C treatments Viekira Pak and Technivie. 10/22/2015. Available at: <https://www.fda.gov/Drugs/DrugSafety/ucm468634.htm>
3. Hussar DA, Kavelak HL. Ledipasvir/sofosbuvir; ombitasvir/paritaprevir/ritonavir/ dasabuvir sodium monohydrate; and peramivir. *J Am Pharm Assoc* (2003) 2015;55:216- 223. doi:[10.1331/JAPhA.2015.15512](https://doi.org/10.1331/JAPhA.2015.15512)
4. Barritt AS 4th, Lee J, Hayashi PH. Detective work in drug-induced liver injury: sometimes it is all about interviewing the right witness. *Clin Gastroenterol Hepatol* 2010;8:635-637. doi:[10.1016/j.cgh.2010.03.020](https://doi.org/10.1016/j.cgh.2010.03.020)

Assessing mucosal healing in IBD in daily practice

To the Editor,

We read with interest the article by Römken et al. regarding the treatment targets in IBD, as used in clinical

practice in Nijmegen, The Netherlands [1]. According to the authors, the main goal in treating IBD for most of the Dutch gastroenterologists is reaching deep remission, most of them choosing to intensify treatment in order to obtain it. Mucosal healing (MH) is correlated with better outcome (longer remission, reduction of hospitalizations, complications and surgical resections) [2], being considered as a treatment target for 66% of the participants in the study [1]. For defining MH in UC, Mayo score 0-1 was used by 52% of the participants, whereas 66% considered MH in CD when “macroscopic normal mucosa” was described [1].

We consider that a “macroscopic normal mucosa” is rarely obtained, especially in a formerly severe CD. In these cases, pseudopolyps or mucosal scars, as residuals of former inflammation, appearing on a non-ulcerated mucosa, can be interpreted as MH.

In most of the CD trials (ACCENT 1, MUSIC, SONIC, EXTEND), MH is clearly defined as the complete absence of ulcers and inflammatory lesions (SES-CD 0, CDEIS 0) [3-7]. Unfortunately, in clinical practice, an unequivocal definition of MH is lacking; all of the scoring systems published have certain limitations. Among the available ones, which are known to have a high interobserver variability, SES-CD is the one with an excellent inter-observer reliability [8].

Reading the study by Romkens et al. raised the question whether pseudopolyps or mucosal scars in an otherwise normal colonic mucosa may also be termed MH, enlarging the spectrum of “macroscopic normal mucosa” in CD.

In our case-series, we retrospectively analyzed a group of 66 patients with CD, based on the following selection criteria: ileocolonic (L3) or colonic extension (L2), inflammatory pattern, biological and endoscopic remission on two consecutive evaluations, separated by at least 1 year (biological remission considered if CRP<10 mg/l, and/or fecal calprotectin <100). Patients with isolated disease or with a history of surgery for IBD were excluded. We found no significant differences regarding the gender or the extension of the disease in the selected group: 48.48% vs 51.51% (F:M, L2:L3). Most of the patients maintained the remission with anti-TNF drugs as a monotherapy (63.63%) or as a combination therapy with AZA (24.24%).

When MH was first considered, a „normal aspect of the macroscopic mucosa” was described in 37.87% of patients. The majority of patients (68.18%) lacked the complete normalization of the mucosa, but they were still labeled as endoscopic remission, if the remaining lesions were pseudopolyps (50%) or mucosal scars (18.18%), and no ulcerations were visible.

Given the fact that all these patients maintained the endoscopic remission after a median time of 2.72 years (range 1- 8), we believe that an “abnormal” mucosa due to the presence of pseudopolyps or mucosal scars should not preclude a diagnosis of MH, and no therapeutic effort should be made in order to make these lesions withdraw.

In conclusion, a correct distinction between “active” and “inactive” IBD is of great importance in clinical practice. In CD, a “macroscopic normal mucosa” is a restrictive way to define MH, excluding a significant number of cases and leading to unnecessary therapeutic changes. Of note, in CD, activity

assessment would also require imaging modalities (MaRIA, Lemann scores), and “bowel wall healing” rather than MH should be desirable.

Cristian Gheorghe, Anca Dimitriu, Liana Gheorghe

Fundeni Clinical Institute, Center for Digestive Diseases and Liver Transplantation, Bucharest, Romania

Correspondence: Cristian Gheorghe, drgheorghe@xnet.ro

Conflicts of interest: No conflicts to declare.

DOI: <http://dx.doi.org/10.15403/jgld.2014.1121.261.ibd>

REFERENCES

1. Römkens TE, Gijbbers K, Kievit W, Hoentjen F, Drenth JP. Treatment Targets in Inflammatory Bowel Disease: Current Status in Daily Practice. *J Gastrointest Liver Dis* 2016;25:465-471. doi:[10.15403/jgld.2014.1121.254.ken](https://doi.org/10.15403/jgld.2014.1121.254.ken)
2. Mazzuoli S, Guglielmi FW, Antonelli E, Salemme M, Bassotti G, Villanacci V. Definition and evaluation of mucosal healing in clinical practice. *Dig Liver Dis* 2013;45:969-977. doi:[10.1016/j.dld.2013.06.010](https://doi.org/10.1016/j.dld.2013.06.010)
3. Rutgeerts P, Diamond RH, Bala M, et al. Scheduled maintenance treatment with infliximab is superior to episodic treatment for the healing of mucosal ulceration associated with Crohn's disease. *Gastrointest Endosc* 2006;63:433-442. doi:[10.1016/j.gie.2005.08.011](https://doi.org/10.1016/j.gie.2005.08.011)
4. Colombel JF, Sandborn WJ, Reinisch W, et al. Infliximab, azathioprine, or combination therapy for Crohn's disease. *N Engl J Med* 2010;362:1383-1395. doi:[10.1056/NEJMoa0904492](https://doi.org/10.1056/NEJMoa0904492)
5. D'Haens G, Baert F, van Assche G, et al. Early combined immunosuppression or conventional management in patients with newly diagnosed Crohn's disease: an open randomised trial. *Lancet* 2008;371:660-667. doi:[10.1016/S0140-6736\(08\)60304-9](https://doi.org/10.1016/S0140-6736(08)60304-9)
6. D'Haens GR. Top-down therapy for IBD: rationale and requisite evidence. *Nat Rev Gastroenterol Hepatol* 2010;7:86-92. doi:[10.1038/nrgastro.2009.222](https://doi.org/10.1038/nrgastro.2009.222)
7. Schreiber S. Certolizumab pegol for the treatment of Crohn's disease. *Therap Adv Gastroenterol* 2011;4:375-389. doi:[10.1177/1756283X11413315](https://doi.org/10.1177/1756283X11413315)
8. Schoepfer AM, Beglinger C, Straumann A, et al. Fecal calprotectin correlates more closely with the Simple Endoscopic Score for Crohn's disease (SES-CD) than CRP, blood leukocytes, and the CDAI. *Am J Gastroenterol* 2010;105:162-169. doi:[10.1038/ajg.2009.545](https://doi.org/10.1038/ajg.2009.545)

Reply,

We thank Gheorghe and colleagues for their interest in our work and for their thoughtful comments. We appreciate their willingness to share the original data from their cohort of 66 Crohn's disease (CD) patients. The authors highlight the complexity of endoscopic scoring of apparently normal looking mucosa and show that the proportion of patients with 'endoscopic remission' depends on the used definition. The issue at stake is not only to formulate a lucid definition of mucosal healing (MH) in inflammatory bowel disease (IBD), but also to coin a clear definition of 'macroscopic normal mucosa'. The aim of our nationwide survey was to map treatment targets in daily clinical IBD practice, not to propose new scoring systems for IBD.

We found that more than half of the participants use the Mayo score (0 or ≤ 1) to define MH in ulcerative colitis (UC), with 40% of the participants indicating 'macroscopic normal mucosa' as MH in UC, and 66% in CD. In CD only one-fifth used validated scoring systems as CDEIS and SES-CD, probably because of their time-consuming and complex character [1]. We agree with the comments of Dr. Gheorghe and colleagues, as mentioned in our discussion, that 'macroscopic normal mucosa' in CD must be interpreted in accordance with the IOIBD consensus [2] as 'absence of ulceration'.

Clear definitions are indispensable to categorise IBD treatment targets.

Tessa E.H. Römkens

Radboud University Nijmegen Medical Centre, Department of Gastroenterology and Hepatology, 6500 HB Nijmegen, The Netherlands

Correspondence: Tessa E.H. Römkens, tessa.romkens@radboudumc.nl

Conflicts of interest: No conflicts to declare.

DOI: <http://dx.doi.org/10.15403/jgld.2014.1121.261.teh>

REFERENCES

1. Römkens TE, Gijbbers K, Kievit W, Hoentjen F, Drenth JP. Treatment Targets in Inflammatory Bowel Disease: Current Status in Daily Practice. *J Gastrointest Liver Dis* 2016;25:465-471. doi:[10.15403/jgld.2014.1121.254.ken](https://doi.org/10.15403/jgld.2014.1121.254.ken)
2. Peyrin-Biroulet L, Sandborn W, Sands BE, et al. Selecting Therapeutic Targets in Inflammatory Bowel Disease (STRIDE): Determining Therapeutic Goals for Treat-to-Target. *Am J Gastroenterol* 2015;110:1324-1338. doi:[10.1038/ajg.2015.233](https://doi.org/10.1038/ajg.2015.233)