

Carbonic Anhydrase Inhibitors for the Treatment of Cystic Macular Lesions in Children With X-Linked Juvenile Retinoschisis

Sanne K. Verbakel,¹ Johannes P. H. van de Ven,¹ Linda M. P. Le Blanc,¹ Joannes M. M. Groenewoud,² Eiko K. de Jong,¹ B. Jeroen Klevering,¹ and Carel B. Hoyng¹

¹Department of Ophthalmology, Donders Institute for Brain, Cognition and Behaviour, Radboud University Medical Center, Nijmegen, The Netherlands

²Department for Health Evidence, Radboud University Medical Center, Nijmegen, The Netherlands

Correspondence: Carel B. Hoyng, Department of Ophthalmology, Radboud University Medical Center, P.O. Box 9101, 6500 HB, Nijmegen, The Netherlands; Carel.Hoyng@radboudumc.nl

Submitted: June 7, 2016
Accepted: August 21, 2016

Citation: Verbakel SK, van de Ven JPH, Le Blanc LMP, et al. Carbonic anhydrase inhibitors for the treatment of cystic macular lesions in children with X-linked juvenile retinoschisis. *Invest Ophthalmol Vis Sci*. 2016;57:5143-5147. DOI:10.1167/ iovs.16-20078

PURPOSE. Little is known regarding the therapeutic effect of carbonic anhydrase inhibitors (CAIs) in the management of cystic macular lesions in children with X-linked juvenile retinoschisis (XLRs) despite the fact that this disease often manifests during childhood. Therefore, our goal was to determine the efficacy of CAIs in the treatment of cystic macular lesions in children with XLRs.

METHODS. We used CAIs to treat cystic macular lesions in 18 eyes of nine children with XLRs. We evaluated the therapeutic effect of CAI treatment with the best-corrected visual acuity and foveal zone thickness (FZT) with spectral-domain optical coherence tomography. A reduction of at least 22.4% in FZT was defined as objective evidence of response.

RESULTS. Five of nine (55.6%) XLRs patients showed a significant reduction of FZT in both eyes over a median treatment interval of 6.8 months (range, 1-23). In four of five (80.0%) patients, this reduction was already apparent after 1 month of treatment. An improvement of visual acuity was observed in five eyes (27.8%) of three patients (33.3%). Six patients (66.6%) reported minor side effects.

CONCLUSIONS. Treatment with CAIs decreased FZT in more than half of the children with XLRs. This effect was observed within 1 month in the majority of patients. Carbonic anhydrase inhibitor treatment restores retinal anatomy and may contribute to creating optimal circumstances for gene therapy.

Keywords: carbonic anhydrase inhibitor, x-linked juvenile retinoschisis, cystoid macular edema, foveal zone thickness, acetazolamide

X-linked juvenile retinoschisis (XLRs) is the leading cause of hereditary juvenile macular degeneration in males, with an estimated prevalence ranging from 1 in 5000 to 1 in 25,000.¹ The onset of XLRs has been attributed to pathogenic mutations in the retinoschisin gene (*RST*) on the X chromosome, which encodes a cell adhesion protein responsible for the architectural integrity of the retina.² Cystic macular lesions are the hallmark features in the early stage of XLRs.³ The pathogenesis of these cystic macular lesions is not entirely understood, but they should not be confused with cystoid macular edema as the normal appearance of the macula on fluorescein angiography in patients with XLRs suggests that vascular leakage plays a minor role, if any, in the pathogenesis of these cystic lesions.

Both oral and topical carbonic anhydrase inhibitors (CAIs) have been used successfully in the management of cystic lesions in macular dystrophies, including XLRs.⁴ The clinical effect of CAIs is thought to be through their action on the membrane-bound carbonic anhydrase receptors present in the retinal pigment epithelium (RPE).⁵ Moreover, other carbonic anhydrase receptors in different cells of the neural retina may also play a role.⁶ Carbonic anhydrase inhibitors act both on retinal and RPE cell function by acidifying the subretinal space, decreasing the standing potential as well as raising retinal adhesiveness, probably by increasing RPE fluid transport.^{5,7}

The vast majority of previous studies investigated the effects of CAI treatment in managing XLRs-associated cystic macular lesions in adults.^{4,8-13} Few studies reported the effect of topical CAIs in the management of cystic macular lesions in children.¹³⁻¹⁶ To the best of our knowledge, only eight cases of the effect of oral acetazolamide on cystic macular lesions in children with XLRs have been reported in the literature.¹⁶⁻¹⁸ This is surprising since restoration of retinal function, albeit temporarily, is more likely to occur in younger patients as compared to adults, where structural alterations may prevent visual improvement despite anatomical recovery.¹² The aim of this study was therefore to determine the efficacy of CAI treatment in children with XLRs-associated cystic macular lesions.

METHODS

Patients

This retrospective cohort study adhered to the tenets of the Declaration of Helsinki, and informed consent was obtained from all participants. We included nine XLRs patients (18 eyes) with a mean age of 12.3 years (range, 6.4-16.6), who were



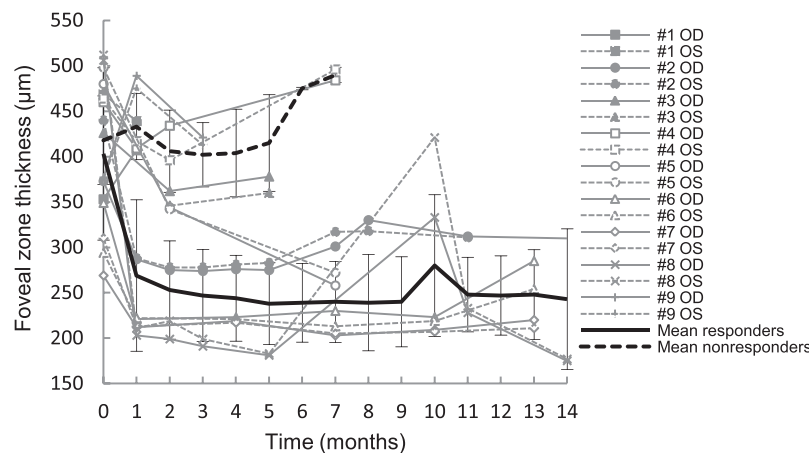


FIGURE 1. Change in FZT over time. The *solid black line* indicates the mean FZT of the five XLRS patients with a significant reduction of FZT, and the *dotted black line* indicates the mean FZT of the patients without a significant reduction. *Vertical lines* are the standard deviation of the mean responder and mean nonresponder lines.

treated with oral CAIs for cystic macular lesions between March 2014 and March 2016 at the Institute of Ophthalmology of the Radboud University Medical Center, Nijmegen (The Netherlands). A 10th patient was excluded from the study because he chose to discontinue treatment because of paresthesias in the second week of treatment, as were patients over 18 years of age and patients who did not take CAIs for at least 4 weeks.

The diagnosis of XLRS was molecularly confirmed in four out of nine patients. In the remaining five patients, no molecular analysis was performed and the diagnosis of XLRS was based on the combination of information regarding family history, a decrease in visual acuity, a spoke-wheel pattern in the macula on high-magnification ophthalmoscopy, and bilateral foveoschisis on spectral-domain optical coherence tomography (SD-OCT).

All nine patients were treated with oral acetazolamide with a dose ranging from 125 mg two times a day to 250 mg three times a day. In addition, six patients also used topical CAIs such as brinzolamide (four patients) or dorzolamide (two patients) (Table). Carbonic anhydrase inhibitor doses were mainly dependent on the patients' age, although adjustments were made based on side effects and the effect on cystic macular lesions seen on SD-OCT. The minimum effective CAI dose was pursued.

Ophthalmic Data Collection

Information regarding best-corrected Snellen visual acuity and retinal thickness measured on SD-OCT was collected from baseline to the most recent visit during CAI treatment. For statistical analysis, the best-corrected Snellen visual acuity was converted into logarithm of the minimal angle of resolution (logMAR) values. A change of 0.14 logMAR, corresponding with a change of seven or more letters on the Early Treatment Diabetic Retinopathy Study (ETDRS) chart, was considered significant.^{11,12}

Cross-sectional images were obtained using SD-OCT (Spectralis HRA+OCT; Heidelberg Engineering, Heidelberg, Germany). The foveal zone thickness (FZT) was calculated using Heidelberg Eye Explorer software (version 1.8.6.0; Heidelberg Engineering) in the central 1000- μ m diameter circle (C1) of the ETDRS grid.

The intervisit variability of SD-OCT measurements was calculated using a previously described method based on the FZT change in both eyes of four XLRS patients (no. 1, no. 6, no.

7, and no. 10, who was excluded from the rest of the study). Baseline FZT was compared with the first preceding FZT up to 6 months prior to starting treatment, with a mean interval of 3.3 months (range, 2–6).^{12,19}

The average difference was 10.1% and the average + 2 SD was 22.4%. Hence, in this study, a reduction of more than 22.4% in FZT was considered a significant response due to CAI treatment.

During treatment, patients were advised to regularly eat potassium-rich food to prevent possible hypokalemia caused by the CAIs. Potassium levels were checked by the attending ophthalmologist or general practitioner.

Statistical Analysis

Prognostic factors for the response to CAIs were analyzed with a multivariable logistic regression analysis. Two-sided *P* values of less than 0.05 were considered statistically significant. Data were analyzed using SPSS Software (version 22.0; SPSS, Inc., Chicago, IL).

RESULTS

Five of nine (55.6%) XLRS patients showed a significant reduction of FZT in both eyes over a median treatment interval of 6.8 months (range, 1–23) (Table; Figs. 1, 2, 3). In four of five (80.0%) patients, this significant reduction was already present after 1 month of treatment. In the remaining patient (no. 5), no information about FZT after 1 month of treatment was available, but he already showed a FZT reduction of 10% and 6% after 12 days of treatment. The FZT reduction persisted over a median treatment interval of 10.1 months (range, 7–16) in eight eyes of the five patients. In two eyes, the right eye of patient no. 2 and the left eye of patient no. 8, a rebound effect occurred where the macular cysts returned to at least baseline levels. This happened after dose reduction of oral acetazolamide from 125 mg three times a day to daily 250 mg with sustained release in patient no. 2. In patient no. 8, the rebound effect occurred after cessation of additional topical brinzolamide eight times a day. After restarting brinzolamide six times a day, FZT again decreased significantly. Overall mean FZT decreased from 409.1 μ m at baseline to 332.8 μ m at the most recent visit during treatment (*P* = 0.024). In the five patients with a significant reduction, mean FZT decreased from 403.1 μ m at baseline to 261.9 μ m at the most recent visit during

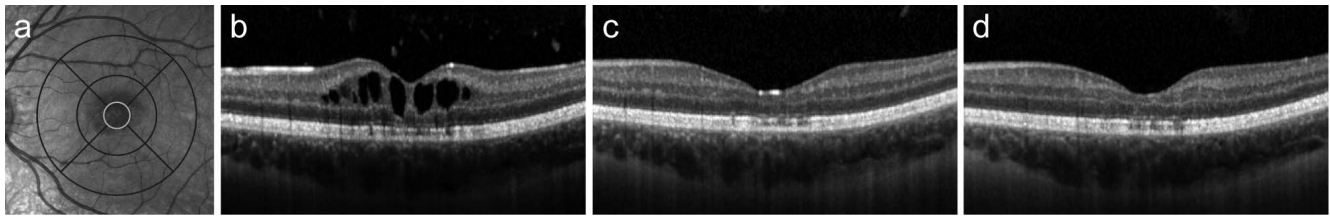


FIGURE 2. Infrared and horizontal SD-OCT images (30°) from the left eye of patient no. 7 showing the response to oral acetazolamide. Near-infrared image with a projection of the ETDRS grid (a). The highlighted innermost circle of the grid was used to measure FZT. Spectral-domain optical coherence tomography image at baseline (b), after 1 month of treatment (c) and after 13 months of treatment (d).

treatment ($P = 0.006$). Age at baseline ($P = 0.111$) or mean FZT at baseline ($P = 0.531$) did not predict the response to CAIs.

Visual acuity improved significantly (≥ 0.14 logMAR) from baseline value in at least one eye in three out of nine (33.3%) XLRS patients. Two patients (22.2%) showed a significant improvement of visual acuity in both eyes (Table; Fig. 4). Overall, mean visual acuity at baseline (0.39 ± 0.15 logMAR) and mean visual acuity at the most recent visit (0.32 ± 0.19 logMAR) were not statistically different ($P = 0.078$). Only one patient showed both a visual improvement and a significant reduction in FZT at the most recent visit during CAI treatment. Improvement of visual acuity was therefore not correlated with a reduction in FZT as well as not correlated with patient age.

Six patients (66.6%) experienced minor side effects during treatment, such as digital and/or perioral paresthesia (55.6%) and fatigue (22.2%) (Table). In patient no. 9, the paresthesias disappeared after switching from oral acetazolamide 250 mg two times a day to oral acetazolamide with sustained release 250 mg daily.

DISCUSSION

We investigated the therapeutic effect of CAIs in the management of cystic macular lesions in children with XLRS. Five of nine patients showed a significant reduction of FZT in

both eyes that was observed within 1 month in the majority of patients. Judged by the treatment effect in our patients, the response to CAIs can be assessed after only 1 month in most patients. This treatment response was quicker than the effect described in XLRS patients by Apushkin and Fishman, though they used only topical CAIs with notable lower doses.¹² The difference in treatment response might consequently be explained by the dose differences between both studies as dose dependency was previously described in patients with XLRS or other retinal dystrophies who were treated with CAIs.^{11,20,21} This is supported by the return of macular cysts after reduction of the CAI dose in patients no. 2 and no. 8 that may be, at least in part, dose dependent and not solely a rebound effect.

In this study we defined FZT changes of more than 22.4% as statistically significant. This percentage is slightly higher compared to the 17.1% used in other studies.¹⁰⁻¹² This difference may be explained by the higher variation in thickness in younger patients on which our calculation was based. Not all patients could be included in the intervisit percent difference calculations because of the lack of SD-OCT scans made within 6 months prior to the baseline measurement. By using 22.4% as the cutoff point, we might have underestimated the CAI effect compared to other studies.

No prognostic factors for response to CAIs were found in this study. Age at baseline and greater initial FZT did not affect treatment response, although such influences were previously described in patients with retinitis pigmentosa (RP).²²

Improvement of visual acuity in at least one eye occurred in three patients (33.3%). In accordance with previous studies, improvement of visual acuity was not correlated with age nor with reduction of central retinal thickness on OCT.^{10,19,23} To our knowledge, the natural course of visual acuity in children with XLRS has not been described previously. To be comparable with studies performed in adults, we used 0.14 logMAR as cutoff point for improvement in visual acuity, keeping in mind that the results may be over- or underestimated.^{11,12}

No patient discontinued CAI treatment due to the side effects. However, one patient was excluded from the study because he discontinued treatment due to paresthesias in the second week of treatment. The disappearance of the side effects in patient no. 9 can be caused by the switch to oral acetazolamide with sustained release, but at the same time patients' total daily CAI dose was reduced. Consequently, we cannot conclude that sustained release treatment shows fewer side effects. Limitations of our study include its retrospective nature, the inherent small cohort size of rare diseases, and the variation in dosage of CAIs, partly by the selective use of topical CAIs. Because of these limitations and the different follow-up intervals, conclusions should be interpreted cautiously.

Despite the side effects and the little improvement in visual acuity, there may also be a long-term benefit in restoring normal retinal anatomy. In patients with XLRS, treatment of the

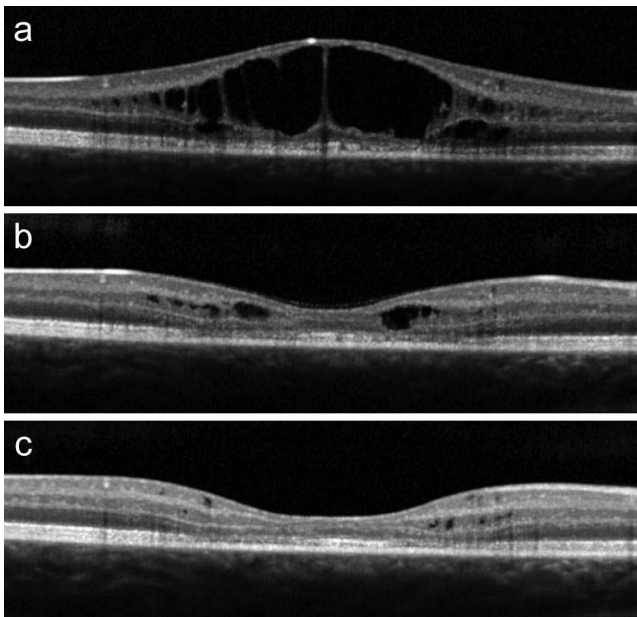


FIGURE 3. Horizontal SD-OCT images (30°) from the right eye of patient no. 8 showing the response to oral acetazolamide. Spectral-domain optical coherence tomography image at baseline (a), after 1 month of treatment (b) and after 14 months of treatment (c).

TABLE. Clinical Characteristics of XLRS Patients at Baseline and During Acetazolamide Treatment

Patient	Age, y*	Sex	Family	Duration, mo†	VA, logMAR		FZT, μm (% Change)		OS	OS	Acetazolamide Dose	Topical Therapy (Times/d)	Side Effects
					OD	OS	OD	OS					
No. 1	6	Male	1	Baseline	0.60	0.45	353	469	0.45	469	125 mg b.i.d.	-	Absent
No. 2	11	Male	1	Baseline	0.70	0.68	407 (+15)	439 (-6)	0.68	439 (-6)	125 mg b.i.d.¶	-	-
					0.38	0.45	373	440	0.45	440	250 mg b.i.d.	-	Paresthesia
No. 3	6	Male	1	Baseline	0.35	0.33	287 (-23)	288 (-35)	0.33	288 (-35)	125 mg b.i.d.	-	-
					0.15	0.15	275 (-26)	283 (-36)	0.15	283 (-36)	250 mg SR‡ b.i.d.	Dorzolamide (8)	-
					0.13	0.08	376 (+1)	391 (-11)	0.08	391 (-11)	250 mg SR‡ daily	Dorzolamide (8)	-
No. 4	15	Male	1	Baseline	0.18	0.25	426	Poor quality	0.25	Poor quality	125 mg b.i.d.	-	Absent
					0.18	0.35	362 (-15)	346	0.35	346	125 mg b.i.d.	-	-
					0.08	0.13	378 (-11)	360	0.13	360	250 mg SR‡ daily¶	-	-
					0.28	0.38	460	464	0.38	464	250 mg b.i.d.	-	Paresthesia
No. 5	13	Male	1	Baseline	0.38	0.53	409 (-11)	417 (-10)	0.53	417 (-10)	250 mg b.i.d. + 125 mg daily	Dorzolamide (6)	-
					0.28	0.45	484 (+5)	496 (+7)	0.45	496 (+7)	125 mg t.i.d.	-	Absent
No. 6	12	Male	2	Baseline	0.10	0.28	480	498	0.28	498	250 mg b.i.d. + 125 mg daily	-	-
					0.15	0.15	344 (-28)	342 (-30)	0.15	342 (-30)	250 mg b.i.d. + 125 mg daily	-	-
					0.08	0.15	258 (-46)	272 (-45)	0.15	272 (-45)	250 mg b.i.d. + 125 mg daily	-	-
No. 7	15	Male	2	Baseline	0.40	0.45	349	294	0.45	294	125 mg t.i.d.	-	Paresthesia
					0.40	0.38	214 (-39)	209 (-29)	0.38	209 (-29)	125 mg daily	Brinzolamide (6)	-
					0.35	0.35	230 (-34)	213 (-28)	0.35	213 (-28)	250 mg daily + 125 mg daily	Brinzolamide (2)	-
					0.40	0.38	285 (-18)	254 (-14)	0.38	254 (-14)	250 mg b.i.d.	-	Fatigue
No. 8	16	Male	1	Baseline	0.38	0.33	269	310	0.33	310	125 mg t.i.d.	-	-
					0.33	0.30	201 (-25)	205 (-34)	0.30	205 (-34)	125 mg daily	Brinzolamide (6)	-
					0.30	0.30	203 (-25)	205 (-34)	0.30	205 (-34)	250 mg daily + 125 mg daily	Brinzolamide (2)	-
					0.43	0.43	220 (-18)	211 (-32)	0.43	211 (-32)	250 mg daily + 125 mg daily	-	-
					0.65	0.35	506	512	0.35	512	250 mg t.i.d.	Brinzolamide (8)	Paresthesia
No. 9	13	Male	1	Baseline	0.34	0.28	203 (-60)	211 (-59)	0.28	211 (-59)	250 mg t.i.d.	Brinzolamide (8)	-
					0.35	0.35	181 (-64)	183 (-64)	0.35	183 (-64)	125 mg b.i.d. + 250 mg daily	Brinzolamide (8)	-
					0.40	0.35	175 (-65)	177 (-65)	0.35	177 (-65)	250 mg b.i.d.	Brinzolamide (6)	-
					0.63	0.55	377	375	0.55	375	250 mg b.i.d.	-	Paresthesia
					0.53	0.40	489 (+30)	475 (+27)	0.40	475 (+27)	250 mg SR‡ daily	-	-
					0.38	0.30	421 (+12)	413 (+10)	0.30	413 (+10)	250 mg SR‡ daily	Brinzolamide (6)	-

(-), Decrease in FZT; (+), increase in FZT; b.i.d., two times a day; t.i.d., three times a day. Visual acuity printed in bold indicates a significant improvement of at least 0.14 logMAR. Foveal zone thickness values printed in bold indicate a significant reduction, which was defined as a reduction in FZT of 22.4%.

* Age at start of acetazolamide treatment.

† Total duration of treatment (in months) calculated from the baseline.

‡ Acetazolamide with sustained release.

§ Side effects disappeared over time.

|| Side effects disappeared after switching to oral acetazolamide with sustained release.

¶ Therapy discontinued due to lack of effect.

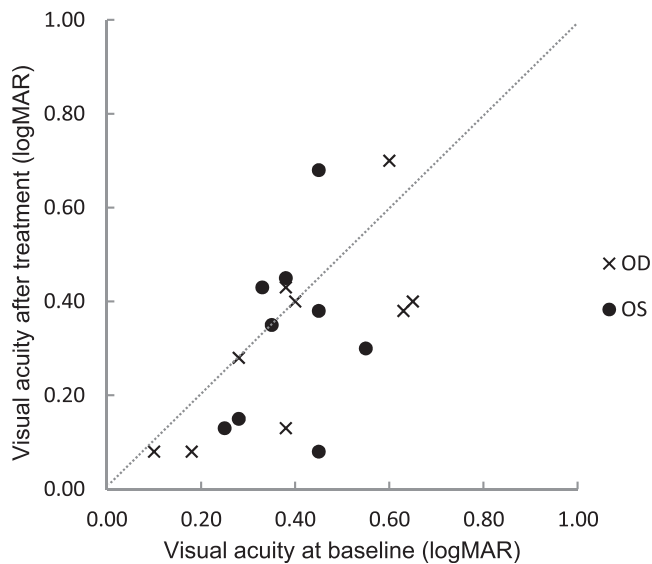


FIGURE 4. Changes in visual acuity from baseline to the most recent visit during acetazolamide treatment.

cystoid macular lesions may decrease the occurrence of later-onset atrophic lesions and the associated visual loss.²⁴

With upcoming treatments such as gene therapy, CAIs may play a role in preserving and restoring retinal anatomy to create optimal circumstances. Retinal pretreatment with CAIs shortly before subretinal injection with transgene vectors may reduce the risk of traumatic damage to the central retina caused by the subretinal injection. The long-term benefits of CAI treatment, especially in relation to the side effects, will have to be studied further.

In conclusion, reduction of central retinal thickness occurred in more than half of the children treated with CAIs, but only three patients experienced visual improvement over a median treatment interval of 6.8 months. Evaluation of treatment effect is possible after only 1 month in the majority of patients. Restoration of macular architecture with CAI treatment may delay functional retinal loss and could be important in the creation of more optimal circumstances for gene therapy.

Acknowledgments

This work was presented as a poster at the Association for Research in Vision and Ophthalmology 2016 conference in Seattle, Washington.

Disclosure: **S.K. Verbakel**, None; **J.P.H. van de Ven**, None; **L.M.P. Le Blanc**, None; **J.M.M. Groenewoud**, None; **E.K. de Jong**, None; **B.J. Klevering**, None; **C.B. Hoyng**, None

References

- Mooy CM, Van Den Born LI, Baarsma S, et al. Hereditary X-linked juvenile retinoschisis: a review of the role of Müller cells. *Arch Ophthalmol*. 2002;120:979-984.
- Tantri A, Vrabec TR, Cu-Unjieng A, Frost A, Annesley WH Jr, Donoso LA. X-linked retinoschisis: a clinical and molecular genetic review. *Surv Ophthalmol*. 2004;49:214-230.
- Molday RS, Kellner U, Weber BH. X-linked juvenile retinoschisis: clinical diagnosis genetic analysis, and molecular mechanisms. *Prog Retin Eye Res*. 2012;31:195-212.

- Salvatore S, Fishman GA, Genead MA. Treatment of cystic macular lesions in hereditary retinal dystrophies. *Surv Ophthalmol*. 2013;58:560-584.
- Wolfensberger TJ, Dmitriev AV, Govardovskii VI. Inhibition of membrane-bound carbonic anhydrase decreases subretinal pH and volume. *Doc Ophthalmol*. 1999;97:261-271.
- Wistrand PJ, Schenholm M, Lonnerholm G. Carbonic anhydrase isoenzymes CA I and CA II in the human eye. *Invest Ophthalmol Vis Sci*. 1986;27:419-428.
- Wolfensberger TJ. The role of carbonic anhydrase inhibitors in the management of macular edema. *Doc Ophthalmol*. 1999;97:387-397.
- Zhang L, Reyes R, Lee W, et al. Rapid resolution of retinoschisis with acetazolamide. *Doc Ophthalmol*. 2015;131:63-70.
- Ali S, Seth R. X-linked juvenile retinoschisis in females and response to carbonic anhydrase inhibitors: case report and review of the literature. *Semin Ophthalmol*. 2013;28:50-54.
- Thobani A, Fishman GA. The use of carbonic anhydrase inhibitors in the retreatment of cystic macular lesions in retinitis pigmentosa and X-linked retinoschisis. *Retina*. 2011;31:312-315.
- Genead MA, Fishman GA, Walia S. Efficacy of sustained topical dorzolamide therapy for cystic macular lesions in patients with X-linked retinoschisis. *Arch Ophthalmol*. 2010;128:190-197.
- Apushkin MA, Fishman GA. Use of dorzolamide for patients with X-linked retinoschisis. *Retina*. 2006;26:741-745.
- Khandhadia S, Trump D, Menon G, Lotery AJ. X-linked retinoschisis maculopathy treated with topical dorzolamide, and relationship to genotype. *Eye (Lond)*. 2011;25:922-928.
- Bastos AL, Freitas Bde P, Villas Boas O, Ramiro AC. Use of topical dorzolamide for patients with X-linked juvenile retinoschisis: case report. *Arq Bras Oftalmol*. 2008;71:286-290.
- Yang FP, Willyasti K, Leo SW. Topical brinzolamide for foveal schisis in juvenile retinoschisis. *J AAPOS*. 2013;17:225-227.
- Rocha Cabrera P, Pareja Rios AC, Cordoves Dorta L, Mantolan Sarmiento C, Serrano Garcia MA. A combination of topical and systemic carbonic anhydrase in the treatment of chromosome X-linked retinoschisis. *Arch Soc Esp Ophthalmol*. 2014;89:320-323.
- Gurbaxani A, Wei M, Succar T, McCluskey PJ, Jamieson RV, Grigg JR. Acetazolamide in retinoschisis: a prospective study. *Ophthalmology*. 2014;121:802-803.e803.
- Ghajarnia M, Gorin MB. Acetazolamide in the treatment of X-linked retinoschisis maculopathy. *Arch Ophthalmol*. 2007;125:571-573.
- Grover S, Apushkin MA, Fishman GA. Topical dorzolamide for the treatment of cystoid macular edema in patients with retinitis pigmentosa. *Am J Ophthalmol*. 2006;141:850-858.
- Fishman GA, Gilbert LD, Fiscella RG, Kimura AE, Jampol LM. Acetazolamide for treatment of chronic macular edema in retinitis pigmentosa. *Arch Ophthalmol*. 1989;107:1445-1452.
- Boon CJ, van den Born LI, Visser L, et al. Autosomal recessive bestrophinopathy: differential diagnosis and treatment options. *Ophthalmology*. 2013;120:809-820.
- Liew G, Moore AT, Webster AR, Michaelides M. Efficacy and prognostic factors of response to carbonic anhydrase inhibitors in management of cystoid macular edema in retinitis pigmentosa. *Invest Ophthalmol Vis Sci*. 2015;56:1531-1536.
- Ikeda Y, Hisatomi T, Yoshida N, et al. The clinical efficacy of a topical dorzolamide in the management of cystoid macular edema in patients with retinitis pigmentosa. *Graefes Arch Clin Exp Ophthalmol*. 2012;250:809-814.
- Walia S, Fishman GA, Molday RS, et al. Relation of response to treatment with dorzolamide in X-linked retinoschisis to the mechanism of functional loss in retinoschisis. *Am J Ophthalmol*. 2009;147:111-115.e1.