

## PDF hosted at the Radboud Repository of the Radboud University Nijmegen

The following full text is a publisher's version.

For additional information about this publication click this link.

<http://hdl.handle.net/2066/155559>

Please be advised that this information was generated on 2021-10-22 and may be subject to change.

## Three-dimensional displacement of the hip joint after triple pelvic osteotomy: A postmortem radiostereometric study

Marinus de Kleuver, Rik Huiskes, John M G Kauer & Rene P H Veth

To cite this article: Marinus de Kleuver, Rik Huiskes, John M G Kauer & Rene P H Veth (1998) Three-dimensional displacement of the hip joint after triple pelvic osteotomy: A postmortem radiostereometric study, Acta Orthopaedica Scandinavica, 69:6, 585-589, DOI: [10.3109/17453679808999260](https://doi.org/10.3109/17453679808999260)

To link to this article: <http://dx.doi.org/10.3109/17453679808999260>



© 1998 Informa UK Ltd All rights reserved: reproduction in whole or part not permitted



Published online: 08 Jul 2009.



Submit your article to this journal [↗](#)



Article views: 59



View related articles [↗](#)



Citing articles: 5 View citing articles [↗](#)

# Three-dimensional displacement of the hip joint after triple pelvic osteotomy

## A postmortem radiostereometric study

Marinus de Kleuver<sup>1</sup>, Rik Huiskes<sup>2</sup>, John M G Kauer<sup>3</sup> and René P H Veth<sup>4</sup>

Triple pelvic osteotomy reorients the acetabulum relative to the pelvis in order to improve acetabular coverage of the femoral head in cases of acetabular dysplasia. We undertook a radiostereometric analysis (RSA) on 6 osteotomized cadaver hips to determine the actual three-dimensional reorientation obtained.

The centers of the femoral head were all translated posteriorly between 11 and 41 mm, and distally up to 13 mm. 4 were lateralized up to 8 mm, and 2 were medialized up to 5 mm. All acetabuli rotated anteriorly about the lateral to medial axis (X-axis), and 4 rotated outwards around the distal to proximal axis (Y-axis). The correlations between measure-

ments performed on conventional anteroposterior radiographs and the RSA measurements were poor: variations in the lateral-medial direction ranged from -16 to +6 mm, and in the distal-proximal direction between -10 and +12 mm.

The changes in orientations measured will significantly affect the load across the hip joint, since the dimensions of the pelvis change and the moment arms of the muscles, their lengths and lines of action are changed as well. We conclude that, with the procedures presently performed, the loads across the hip joint are bound to change, and that the reorientation can hardly be checked with conventional radiographs.

<sup>1</sup>Department of Orthopaedic Surgery, St. Maartenskliniek, Hengstdal 3, NL-6522 JV Nijmegen, The Netherlands. Tel +31 24-3659289. Fax -3659317; <sup>2</sup>Orthopaedic Research Laboratory, Institute of Orthopaedics, <sup>3</sup>Department of Anatomy and Embryology, <sup>4</sup>Institute of Orthopaedics, University of Nijmegen, The Netherlands  
Submitted 98-02-28. Accepted 98-08-11

Acetabular dysplasia, characterized by insufficient acetabular coverage of the femoral head, can be treated in adolescents and young adults by triple pelvic osteotomy (Steel 1977, Tönnis et al. 1981). The acetabulum is cut free from the pelvis, and tilted to improve acetabular coverage of the femoral head. However, current data have not shown a clear relationship between the degree of acetabular coverage and the long-term clinical outcome (de Kleuver et al. 1997). The acetabular reorientation obtained has hitherto been determined on conventional anteroposterior radiographs (Colton 1972, Nakamura et al. 1992, Hsin et al. 1996). However, these measurements are influenced by the position of the patient and the tilt of the pelvis when the radiographs are taken. Most importantly, anteroposterior radiographs give a two-dimensional representation of a three-dimensional reality.

We assessed the reorientation of the acetabulum in osteotomized cadaver hips by radiostereometric analysis (RSA) and compared the findings with measurements obtained from conventional anteroposterior radiographs.

## Material and methods

A routine triple pelvic osteotomy (Tönnis et al. 1981) was performed on 6 fresh cadaver hips by experienced surgeons who have performed more than 500 of these operations since 1980. We employed standard RSA techniques (Kärrholm 1989, Selvik 1989). Two rigid bodies were considered: the sacrum (with the iliac wing) and the acetabulum.

During the surgical exposure, 10–15 1.5 mm markers were placed anteriorly and posteriorly in the acetabulum and approximately 10 more markers were placed in the iliac wing and the ischium. Through a small additional posterior incision, 4 markers were placed in the sacrum. Routine calibration was performed (Selvik 1989) and stereoradiographs of the hip were made. The osteotomy and acetabular reorientation were also performed. The intention was to rotate the acetabulum anteriorly by 20 degrees and laterally by 20 degrees. These are the amounts of rotation typically performed in patients with acetabular dysplasia, although the correction is normally determined individually, depending on the

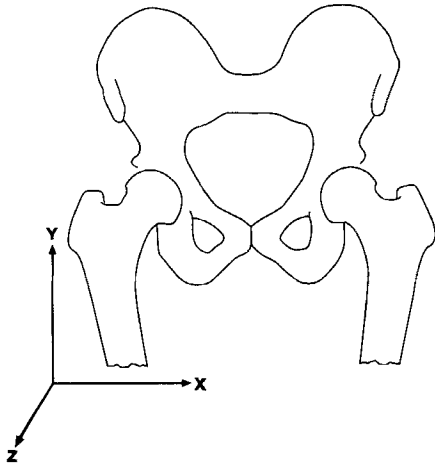


Figure 1. The coordinate system.

severity of the dysplasia. As in routine surgery, the anterior rotation was estimated by drilling two K-wires parallel to the sagittal plane before correction, one into the acetabulum and one into the iliac wing. The amount of anterior rotation about the lateral to medial X-axis of the acetabulum was estimated by assessment of the angle in the sagittal plane between the two K-wires after the correction. Similarly, another set of two K-wires was inserted in the acetabulum and iliac wing, parallel to the frontal plane, to estimate the lateral rotation about the posterior to anterior Z-axis of the acetabulum. After surgery, stereoradiography was performed again, followed by a second calibration. The data were digitized, using an ARISTO digitizer (Huiskes et al. 1985) and analyzed using the X-RAY and KINEMA software (Selvik 1989). In all calculations, the origin of the coordinate system was taken as the center of the sacrum. The center of the acetabular fragment was taken to be the center of the femoral head. As no marker could be placed at the center of the femoral head, this point was determined on the two preoperative stereoradiographs, using spherical templates. The coordinates of this point were calculated and related to markers in the acetabular fragment. This is not so precise as the RSA method per se, but for the accuracy required in this study it was judged sufficient. The change in position of the center of the femoral head due to the reorientation was then calculated relative to the sacrum, using a right-handed coordinate system (Figure 1). The X, Y and Z translations of the center of the femoral head and the Eulerian rotation angles of the acetabulum were determined. In order to visualize the results typically obtained, they were

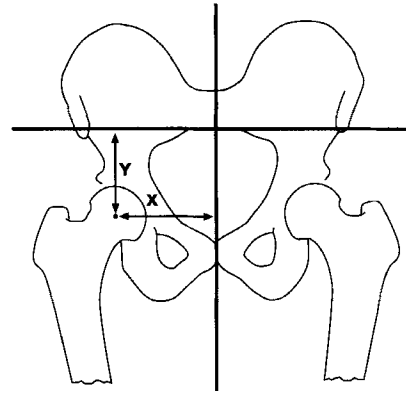


Figure 2. Measurement of translation of the center of the femoral head in the medial to lateral X-axis and the proximal to distal Y-axis on antero-posterior radiographs. The vertical reference line is the longitudinal axis of the body through the pubic symphysis, the horizontal reference line passes through the inferior margins of the SI joints.

recreated in a plastic pelvis model from the RSA data and then photographed.

Pre- and postoperatively, anteroposterior radiographs (35 × 43 cm) of the whole pelvis were taken by a qualified radiographic technician. The cadaver was placed on the cassette, the beam was centered cranial to the pubic symphysis and the focus-film distance was 120 cm, as in standard radiographic practice. The hips were extended with the patellae pointed forward. Measurement of the displacements of the femoral head were performed on these radiographs (Figure 2). Spherical templates were placed over the radiograph to determine the center of the femoral head. Medial-lateral displacement along the X-axis was measured along a line from the pubic symphysis, perpendicular to the longitudinal axis of the body (Legal 1987). Distal-proximal displacement along the Y-axis was measured along a line perpendicular to a line connecting the inferior margins of the left and right sacro-iliac joints (the inter-teardrop line could not be used, since the teardrop is displaced by the operation).

**Accuracy:** A previous study from our institution, using the same RSA set-up, showed an estimated error of less than 50 µm, and with repeated reconstructions of knee RSA measurements, the SD was less than 0.1 mm (Blankevoort et al. 1988). In the present experiments, the stability of the markers in each rigid body was tested, and a mean error of 0.342 mm was found.

## Results

The centers of the 6 femoral heads were all translated

**Table 1.** Translation of the center of the femoral head and rotation of the acetabulum relative to the sacrum in 6 hips after triple osteotomy of the pelvis. All measurements are given as for a right hip. The rotations are sequential about the X-, Y- and Z-axes, for axes see Figure 1

Hip	Translation, mm			Rotation, degrees		
	X	Y	Z	Fi	Psi	Theta
1	5	-13	-25	20	2	7
2	-8	-4	-41	20	-6	0
3	-4	-5	-11	15	-4	-4
4	-6	-7	-18	10	-7	3
5	-1	-4	-26	16	-6	8
6	4	-11	-17	10	12	4
Average	-1.7	-7.3	-24	16	-3	4

*Translation*

X lateral to medial translation, Y distal to proximal translation, Z posterior to anterior translation

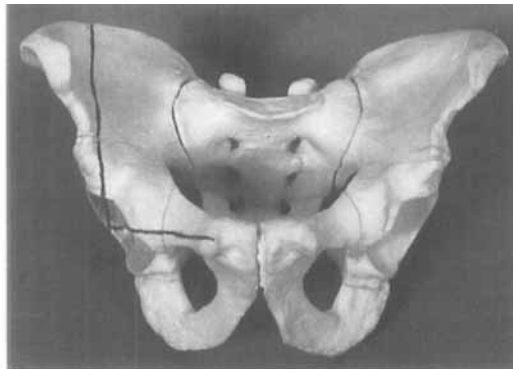
*Rotation*

Fi anterior rotation about the X-axis, Psi medial rotation about the Y-axis (increased anteversion), Theta lateral rotation about the Z-axis.

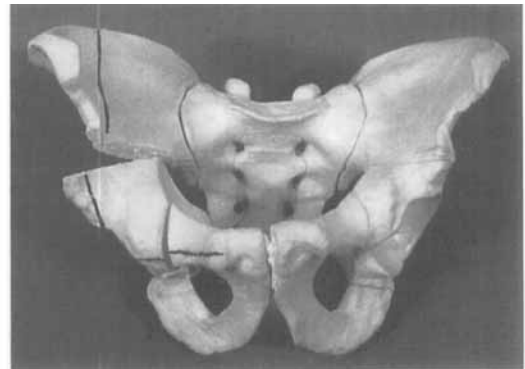
posteriorly between 11 and 41 mm; all were translated distally up to 13 mm and 4 were lateralized up to 8 mm (Table 1, Figure 3). All acetabuli were rotated 10–20 degrees anteriorly about the X-axis and 4 were rotated outwards about the Y-axis, thereby reducing anteversion. Although the center of the femoral head was displaced posteriorly, this was not apparent when seen from the anterior aspect during surgery, since the acetabulum comes forward while it rotates anteriorly about the X-axis (Figure 3).

The correlations between the measurements performed on conventional anteroposterior radiographs and the RSA results were poor (Table 2). Conventional radiographs and RSA gave the same direction of translation along the X-axis (towards medial or towards lateral) only 3 of 6 times, and the discrepancy in the translations measured ranged between -16 and +6 mm. The direction of translations along the Y-axis agreed 5 of 6 times (towards proximal or towards distal), but the discrepancy in the translations measured

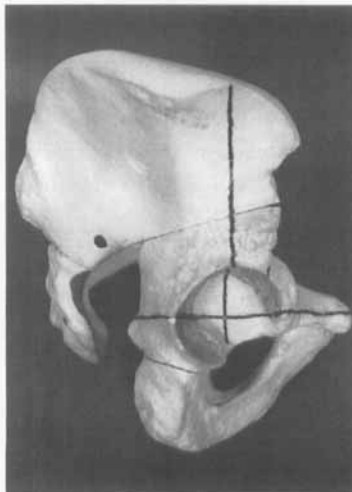
**Figure 3.** Illustration of the average displacement of the acetabulum on a plastic model of the pelvis. The vertical and horizontal planes are marked by the black lines. Note the evident posterior displacement of the center of the hip joint.



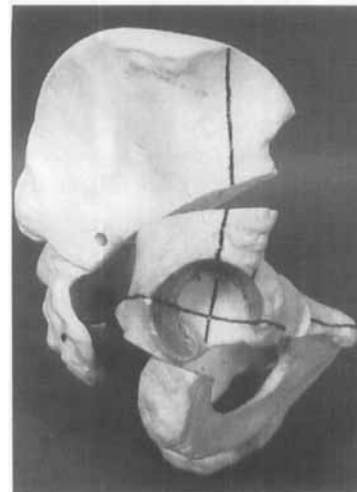Preoperative



Postoperative



Preoperative



Postoperative

Table 2. Two-dimensional translation of the center of the femoral head as measured on conventional anteroposterior radiographs and as measured with RSA for six hips after triple pelvic osteotomy

Hip no.	Translation, mm			
	X radiography	X RSA	Y radiography	Y RSA
1	-1	5	-4	-13
2	8	-8	6	-4
3	-4	-4	-17	-5
4	2	-6	-9	-7
5	-2	-1	-1	-4
6	4	4	-7	-11

X translation along the X-axis (lateral to medial) as measured on anteroposterior radiographs and RSA, Y translation along the Y-axis (distal to proximal) as measured on anteroposterior radiographs and RSA.

ranged between -10 and +12 mm. The small number of specimens and the wide ranges of the values preclude further statistical analysis.

## Discussion

In cases of acetabular dysplasia, pelvic osteotomies such as a triple osteotomy or a periacetabular osteotomy (Ganz et al. 1988) aim to improve deficient acetabular coverage of the femoral head by shifting the nonweight bearing acetabular cartilage from medial and posterior towards the superior and anterior areas, which have reduced coverage. In this manner, the weight bearing area in axial loading increases, supposedly reducing the pressure in the joint. However, there is no clear relationship between the parameters of acetabular coverage measured and the long-term clinical outcome (de Kleuver et al. 1997), so that factors other than just acetabular coverage might be of importance.

A better understanding of the effects of a pelvic osteotomy on the mechanics of the hip joint may be helpful in explaining by which mechanism pelvic osteotomies that reorient the acetabulum are effective. We found that when the acetabulum is reoriented by a triple osteotomy, the center of the hip joint (the center of the femoral head) is markedly translated distally and posteriorly and sometimes medially or laterally. The acetabulum does not rotate about the center of the hip joint. The translation suggests that the reorientation is dictated, more than was previously believed, by the soft tissues attached to the acetabulum (hip capsule, periosteum and muscles) and perhaps even more by the orientation of the osteotomy planes. The

displacements were larger than we had expected, particularly the translation posteriorly, which has not been reported before. Such translations must have a substantial effect on the load transfer across the hip joint. First, because the moment-generating requirements of the muscles change since the dimensions of the pelvis change. Secondly, the change in position of the femoral head may lead to an equivalent displacement of the entire leg, and probably results in some rotation of the femur. This will change the orientation of the femoral head in the acetabulum, which also causes a change in anterior or posterior coverage of the femoral head. Thirdly, because the lengths and lines of action of the muscles change, the moment arms and forces produced by the muscles are altered. Nemeth and Ohlsen (1985) found that the normal moment arm for the gluteus maximus was 8 cm, for the hamstrings 6 cm and for the adductor magnus 1.5 cm. The translations measured in this study, in the order of centimeters, would cause substantial changes in these moment arms. Delp and Maloney (1993) have calculated that a 2 cm posterior displacement of the hip center, which is close to the average displacement that we have measured, would lead to a decrease in extension moment by one third and an increase in flexion moment by one fifth. Similarly, the 8 mm distal displacement that we have measured would lead to a 15% increase in abduction moment, a 5% increase in adduction moment and a 5% increase in flexion moment.

Our findings cannot easily be extrapolated to other pelvic osteotomies. The soft tissues attached to the acetabulum and the orientation of the osteotomy planes influence the reorientation. In a periacetabular osteotomy (Ganz et al. 1988), the posterior column from ilium to ischium remains intact. Because posterior translation is not possible in this case, in contrast to a triple osteotomy, the center of the hip joint will probably be forced to translate anteriorly since the acetabulum is rotated anteriorly. How this affects the load across the hip joint is unclear.

Hsin et al. (1996) have analyzed the mechanics of the hip following triple osteotomy on the basis of the work of Pauwels and Legal (Legal 1987) using anteroposterior radiographs of a patient population. They found an increased weight bearing area of the acetabulum, but the relative load, based on the moment arm calculations, remained the same. These calculations took into account only the medial-lateral displacement of the center of rotation of the hip joint (the center of the femoral head) as measured on anteroposterior radiographs, and not the superior-inferior or the anterior-posterior displacements. Our experiments show that these translations can be large.

Another method of estimating reorientation was employed by Rab (1978), when he made a mathematical analysis of a single innominate osteotomy (Salter 1961). This was based on an assumed axis of rotation of the acetabulum between the pubic symphysis and the sciatic notch. The acetabulum was found to translate 1 cm distally, 1.2 cm medially, and 1.5 cm posteriorly. The acetabulum rotated in extension and adduction. This is a simple and elegant analysis and the inferior and posterior translations were of the same order of magnitude as found in this study. However, the major difference is that in adults a triple osteotomy gives much more freedom of motion of the acetabulum than a single innominate osteotomy, and therefore there is no predictable axis of rotation for a mathematical model.

The rotations of the acetabulum we found are more difficult to relate to normal clinical experience than the translations. The rotations are sequential about the body's (acetabulum) fixed axes X, Y and Z and are performed in that order. They therefore cannot be considered individually. For example, rotation about the Z-axis is not the same as a change in the center edge angle, as measured on anteroposterior radiographs, and rotation about the Y-axis is not the same as changes in anteversion of the acetabulum. For this reason, the K-wire method used intraoperatively to estimate rotational corrections is inherently inaccurate. Furthermore, the K-wires can never point exactly towards the center of the hip joint, which further increases the error of this method.

The data for translations in the X- and Y-axes were quite different as determined by RSA and as measured from anteroposterior radiographs. We feel that the difference is due to the fact that the anteroposterior radiograph is a two-dimensional representation of a three-dimensional reality. The distances are measured between points and lines that do not lie in the same frontal plane, thus introducing an error. Changes in position in the anteroposterior direction (such as occur in the current experiments) will enhance these errors. Additional sources of inaccuracy of the measurements performed on the anteroposterior radiographs might be changes in the magnification and changes in the pelvic tilt and pelvic obliquity of the patient between the pre- and postoperative radiographs (despite the standardized radiographic technique). In daily practice, these errors are common since intraoperative radiographs and lying down and standing postoperative radiographs are all taken differently. This inaccuracy of conventional radiographs raises questions about the accuracy of studies on translations of the

hip joint during pelvic osteotomies based on such radiographs (Nakamura et al. 1992, Hsin 1996).

Despite the fact that we attempted to reorient all acetabuli equally, the interspecimen variability of the data was substantial. This may be partly due to the age and stiffness of cadaver hips, which makes the operation, and especially the reorientation, more difficult to perform and check than in healthy young patients. However, it also casts some doubt on the reproducibility of the operation as it is performed in daily practice.

- Blankevoort L, Huiskes R, de Lange A. The envelope of passive knee joint motion. *J Biomech* 1988; 21: 705-20.
- Colton C L. Chiari osteotomy for acetabular dysplasia in young subjects. *J Bone Joint Surg (Br)* 1972; 54: 578-89.
- Delp S L, Maloney W. Effects of hip center location on the moment-generating capacity of the muscles. *J Biomech* 1993; 26: 485-99.
- Hsin J, Saluja R, Eilert R E, Wiedel J D. Evaluation of the biomechanics of the hip following a triple osteotomy of the innominate bone. *J Bone Joint Surg (Am)* 1996; 78: 855-62.
- de Kleuver M, Kooijman M A P, Pavlov P W, Veth R P H. Triple osteotomy of the pelvis for acetabular dysplasia. Results at 8 to 15 years. *J Bone Joint Surg (Br)* 1997; 79: 225-9.
- Ganz R, Klaue K, Vinh T S, Mast J W. A new peri-acetabular osteotomy for the treatment of hip dysplasias. *Clin Orthop* 1988; 232: 26-36.
- Huiskes R, Kremers J, de Lange A, Woltring H J, Selvik G, van Rens Th J G. Analytical stereophotogrammetric determination of three-dimensional knee-joint geometry. *J Biomech* 1985; 18: 559-70.
- Kärrholm J. Roentgen stereophotogrammetry. Review of orthopedic applications. *Acta Orthop Scand* 1989; 60: 491-503.
- Legal H. Introduction to biomechanics of the hip. In: *Congenital dysplasia and dislocation of the hip in children and adults*. Springer Verlag, Berlin/Heidelberg 1987: 26-57.
- Nakamura T, Yamaura M, Nakamitsu S, Suzuki K. The displacement of the femoral head by rotational acetabular osteotomy. A radiographic study of 97 subluxated hips. *Acta Orthop Scand* 1992; 63: 33-6.
- Nemeth G, Ohlsen H. In vivo moment arm lengths for hip extensor muscles at different angles of hip flexion. *J Biomech* 1985; 18: 129-40.
- Rab G T. Biomechanical aspects of Salter osteotomy. *Clin Orthop* 1978; 132: 82-7.
- Salter R B. Innominate osteotomy in the treatment of congenital dislocation and subluxation of the hip. *J Bone Joint Surg (Br)* 1961; 43: 518-39.
- Selvik G. Roentgen stereophotogrammetry. A method for the study of the kinematics of the skeletal system. *Acta Orthop Scand (Suppl 232)* 1989: 60.
- Steel H H. Triple osteotomy of the innominate bone. *Clin Orthop* 1977; 122: 116-27.
- Tönns D, Behrens K, Tscharani F. Eine neue Technik der Dreifachosteotomie zur Schwenkung dysplastischer Hüftpfannen bei Jugendlichen und Erwachsenen. *Z Orthop* 1981; 119: 253-65.