

## PDF hosted at the Radboud Repository of the Radboud University Nijmegen

The following full text is a publisher's version.

For additional information about this publication click this link.

<http://hdl.handle.net/2066/155540>

Please be advised that this information was generated on 2021-10-23 and may be subject to change.

## Acetabular coverage of the femoral head after triple pelvic osteotomy: No relation to outcome in 51 hips followed for 8–15 years

Marinus de Kleuver, Paul J C Kapitein, Marinus A P Kooijman, Jacques van Limbeek, Paul W Pavlov & Rene P H Veth

To cite this article: Marinus de Kleuver, Paul J C Kapitein, Marinus A P Kooijman, Jacques van Limbeek, Paul W Pavlov & Rene P H Veth (1999) Acetabular coverage of the femoral head after triple pelvic osteotomy: No relation to outcome in 51 hips followed for 8–15 years, Acta Orthopaedica Scandinavica, 70:6, 583-588, DOI: [10.3109/17453679908997846](https://doi.org/10.3109/17453679908997846)

To link to this article: <http://dx.doi.org/10.3109/17453679908997846>



© 1999 Informa UK Ltd All rights reserved:  
reproduction in whole or part not permitted



Published online: 08 Jul 2009.



Submit your article to this journal [↗](#)



Article views: 155



View related articles [↗](#)



Citing articles: 17 View citing articles [↗](#)

# Acetabular coverage of the femoral head after triple pelvic osteotomy

No relation to outcome in 51 hips followed for 8–15 years

Marinus de Kleuver<sup>1</sup>, Paul J C Kapitein<sup>1</sup>, Marinus A P Kooijman<sup>1</sup>, Jacques van Limbeek<sup>1</sup>, Paul W Pavlov<sup>1</sup> and Rene P H Veth<sup>2</sup>

In developmental dysplasia of the hip in adolescents and young adults, pelvic osteotomies aim to improve acetabular coverage of the femoral head by reorienting the acetabulum. We determined whether acetabular coverage is related to long-term clinical results after triple osteotomy of the pelvis. We used a previously published computer program (Konishi and Mieno 1993) which calculates three-dimensional coverage of the femoral head from plain anteroposterior radiographs. We studied the pelvic radiographs of 51 hips in 43 patients and the results were correlated with studies on clinical outcome (de Kleuver et al. 1997). Total acetabular coverage improved from a mean of 56% to 70%. We did not find a relationship

between total acetabular coverage and long-term outcome, nor could we determine an optimal coverage. Reduced coverage of the posterolateral quadrant of the femoral head was related to a reduced score for walking ability ( $p = 0.03$ ), and therefore care should be taken not to overcorrect the acetabulum forwards when attempting to improve the deficient anterior coverage. We challenge the concept that total acetabular coverage is a prerequisite for a good long-term outcome after triple pelvic osteotomy, and hypothesize that other factors such as the change in load across the hip are probably more important in determining the outcome.

Departments of Orthopaedic Surgery, <sup>1</sup>St. Maartenskliek, Hengstdal 3, NL-6522 JV Nijmegen, The Netherlands. Tel +31 24 365-9289. Fax -9317; <sup>2</sup>St. Radboud University Hospital, Nijmegen, The Netherlands  
Submitted 98-11-13. Accepted 99-06-29

Dysplasia of the hip in adolescents and young adults is characterized by malposition of the proximal femur and a shallow obliquely-oriented acetabulum. This abnormal relationship is thought to lead to an increased load over a small acetabular weight-bearing area. To reduce pain and prevent secondary arthrosis, many surgical techniques are used, such as the triple osteotomy (Tönnis et al. 1981), periacetabular osteotomy (Ganz et al. 1988) and spherical osteotomy (Wagner 1973). All aim to improve acetabular coverage. However, we have recently shown that a triple osteotomy substantially displaces the center of the hip joint, particularly in the posterior direction (de Kleuver et al. 1998). This has major implications for the load across the joint, and may contribute to the clinical effect of the operation. It also casts doubt on the assumption that a pelvic osteotomy is merely a matter of improvement in acetabular coverage of the femoral head. This was the reason

why the current study was undertaken, in which we evaluated pre- and postoperative acetabular coverage of the femoral head and its relationship to the long-term clinical outcome after triple osteotomy of the pelvis. We calculated the three-dimensional acetabular coverage from plain anteroposterior radiographs with the computer program developed by Konishi and Mieno (1993), and related these to studies on the clinical outcome in 43 patients (51 hips) with an 8–15 year follow-up (de Kleuver et al. 1997).

## Patients and methods

From 1980 to 1987, 51 triple osteotomies were performed in 43 patients. The indication for surgery was a symptomatic dysplastic hip. Prerequisites were a hip joint with almost full range of motion, and congruency on radiographic evalua-

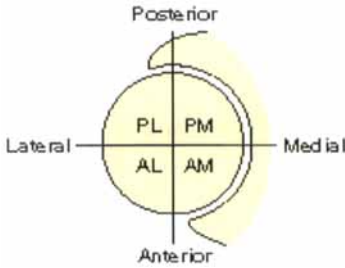


Figure 1. Coverage of the femoral head. The femoral head as seen from above is shown with the four quadrants. AM anteromedial quadrant, AL anterolateral quadrant, PL posterolateral quadrant, PM posteromedial quadrant.

tion (which usually requires a spherical femoral head). 2 patients (3 hips) could not be traced for follow-up and 1 hip could not be assessed using the computer program because only a plain radiograph of the hip instead of the complete pelvis was available. This left 47 hips for the study, with a mean follow-up of 10 years (8–15 years). All patients gave informed consent, and after the completion of the study they received a letter reporting the general results.

Three-dimensional coverage of the femoral head was calculated from plain anteroposterior radiographs with a computer program developed by Konishi and Mieno (Konishi and Mieno 1993). It has been validated against direct measurements and CT measurements. For spherical femoral heads, it was shown to be of similar accuracy as CT measurements. The program involves digitizing the contours of the hip joint and certain pelvic landmarks (the contours of the femoral head, acetabular roof, anterior and posterior edges of the acetabulum, obturator foramen, and the inferior margin of the teardrops). These data were used as input for the computer program. The acetabulum and the femoral head are assumed to be spherical. The edges of the acetabulum are digitized, and are

postulated to lie on the spherical surface of the acetabulum. To determine the acetabular coverage, the boundaries of the superior hemisphere of the acetabulum on a cephalo-caudal projection are determined. These are projected onto the superior hemispherical surface of the femoral head. Acetabular coverage as a percentage of the total superior hemispherical surface of the femoral head is then calculated, and so is the coverage of the four quadrants (anteromedial, anterolateral, posterolateral, posteromedial) (Figure 1). In addition, conventional 2-dimensional radiographic parameters were calculated: center-edge angle (Wiberg 1939), Sharp angle (Sharp 1961), the acetabular index of depth to width (AI) (Heyman and Herndon 1950) and the acetabulum-head index (AHI) (Heyman and Herndon 1950) (Figure 2). The calculations were corrected for pelvic tilt. Because all calculated parameters are percentages and angles (and not distances), the magnification factor of the radiographs is not a confounding variable.

Clinical evaluation used a routine questionnaire which included the D'Aubigné and Postel scoring system (D'Aubigné and Postel 1954) that grades each of the three categories—i.e., pain, walking ability and range of motion of the hip from 1 to 6. Clinical evaluation also included a visual analogue scale of pain, patients' use of pain medication and the ability to play sports. The severity of degenerative arthritis was graded on the plain radiographs from 0 to 4, using Tönnis' method (Tönnis 1987).

The statistical analysis of the relationship between acetabular coverage and clinical outcome was performed using the Statistical Program for the Social Sciences (SPSS, version 6.1). Dichotomously and ordinaly scaled variables were analyzed with chi-square tests. Interval and ratio-scaled variables were analyzed with t-tests and the

Figure 2. The 4 radiographic criteria calculated.

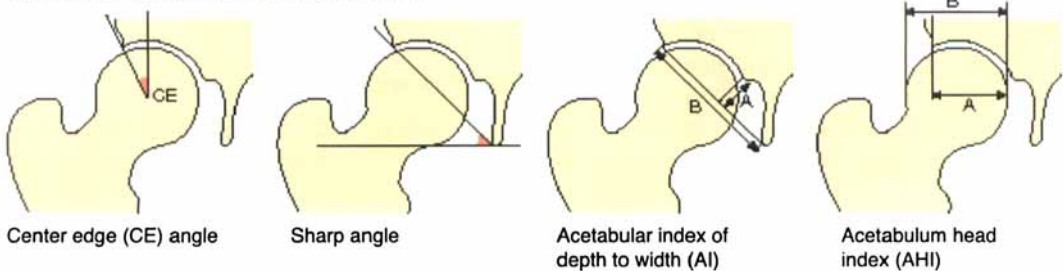


Table 1. Mean acetabular coverage of the femoral head in 47 hips before and 10 years after triple osteotomy (percentage standard deviation)

	Preoperative		Postoperative	
Total area	55	12	70	12
Anterior half	50	13	63	16
Posterior half	61	13	75	13
Anteromedial quadrant	86	14	92	10
Anterolateral quadrant	14	15	36	24
Posterolateral quadrant	25	20	51	25
Posteromedial quadrant	96	7.0	99	1.6

All differences between pre- and postoperative measures of coverage were significant at  $p < 0.01$

univariate and multivariate analyses of the variance. Correlation analyses were performed using the Pearson correlation coefficient. A logistic regression analysis was performed to determine the influence of confounding variables, such as patients' weight, length, age and sex on the clinical outcomes. The alpha level was set at 0.05.

## Results

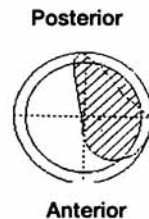
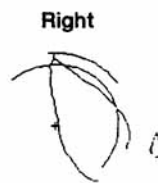
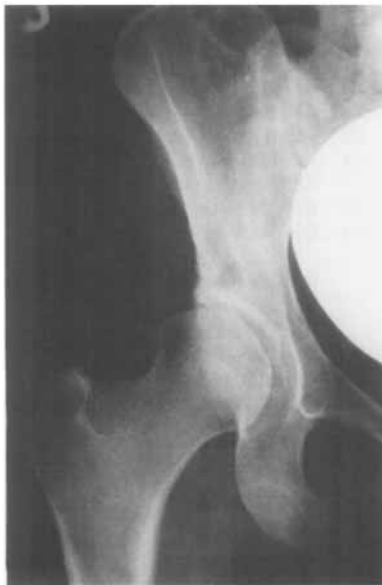Total acetabular coverage improved in all hips (Table 1, Figures 3 and 4). There was a statistical-

Table 2. Mean radiographic findings in 47 hips before and 10 years after triple osteotomy (degrees and percentage standard deviation)

	Preoperative		Postoperative	
CE angle, degrees	8.6	11	24	12
Sharp angle, degrees	44	8.0	32	8.7
Acetabular index (AI), %	24	5.9	26	6.4
Acetabulum head index (AHI), %	57	10	71	10

ly significant increase in acetabular coverage of all four quadrants. The mean CE angle, Sharp angle and acetabulum-head index (AHI) improved to normal values (Table 2). The acetabular index of depth to width of the acetabulum (AI) remained unchanged.

No relationship was found between postoperative total acetabular coverage and the clinical score (including the D'Aubigné and Postel subscores for pain, walking ability, range of motion), the visual analogue pain score, the ability to play sports or the use of pain medication. Similarly, total acetabular coverage and coverage per quadrant did not differ significantly between the hips that scored poorly (score  $< 12$  of 18, or a total hip arthroplasty) and the other hips.



2.7 CE angle (°)  
 39 Sharp angle (°)  
 17 AI (%)  
 53 AHI (%)  
 25 Head radius (mm)  
 30 Acetabular radius (mm)  
 102 ACP angle (degree)  
 47 Center X-coordinate (mm)  
 14 Center Y-coordinate (mm)

Between teardrops = 152 mm

Area of head covered (%)  
 50 Total area  
 42 Anterior 1/2  
 59 Posterior 1/2  
 82 Ant. med. 1/4  
 1.8 Ant. lat. 1/4  
 17 Post. lat. 1/4  
 100 Post. med. 1/4  
 71 Ant./post. ratio

Tilt angle = 0°

Figure 3. The right hip in a 30-year-old woman. The clinical score was fair.

However, correlation analysis revealed that reduced postoperative coverage of the posterolateral quadrant was associated with a lower postoperative walking score ( $r = 0.32$ ,  $p = 0.03$ ). Similarly, mean postoperative coverage of the posterolateral quadrant was less in the cases with a poor result (score  $< 12$  of 18) than in the other hips (39.8% coverage versus 52.6% coverage). However, this difference did not reach statistical significance with the numbers available ( $p = 0.2$ ).

Progression of osteoarthritis by one grade had occurred in 10 hips (21%) over 10 years, 7 from grade 0 to grade 1, and 3 from grade 1 to grade 2. The 3 hips that went on to grade 2 osteoarthritis were all converted to a total hip arthroplasty (5, 6 and 7 years postoperatively). In patients with progression of osteoarthritis, the total postoperative coverage and coverage per quadrant did not differ significantly from those who showed no progression of osteoarthritis. 4 of these 10 had less than 65% total coverage and 6 of 10 had more than 80% coverage. None had coverage in the normal range between 65% and 80% (Klaue et al. 1988).

27 of 38 hips with no preoperative osteoarthritis scored good or excellent at follow-up compared to 2 of 10 with preoperative grade 1 osteoarthritis. However, joints with preoperative osteoarthritis did not have a poorer coverage preoperatively nor

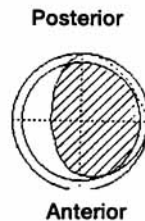
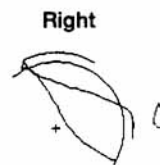
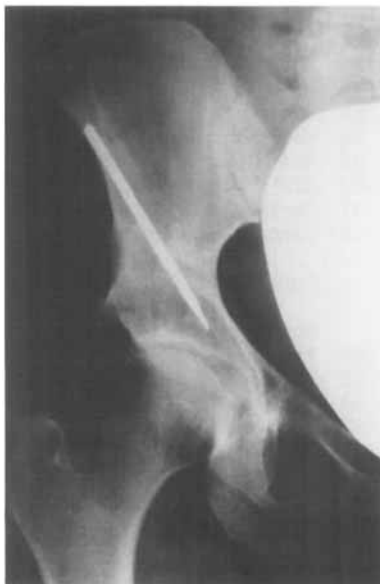a poorer coverage postoperatively than those with no osteoarthritis.

The strongest relationship was found between postoperative and preoperative total acetabular coverage (correlation coeff. = 0.7,  $p < 0.001$ ).

Using a logistic regression analysis, increased weight was found to be significantly associated with the probability of a poor result ( $B = -0.14$ , standard error = 0.06,  $p = 0.04$ ). No other preoperative variables were related to clinical outcome.

## Discussion

Dysplasia of the hip in adolescents and young adults is characterized by an abnormal relationship between the proximal femur and the acetabulum. The proximal femoral valgus anteversion leads to increased load being transferred across the hip joint (Bombelli 1993). The shallow acetabulum results in a reduced weight bearing area to carry this increased load, and the obliquity of the acetabulum leads to increased shear forces (Bombelli 1993). Together this causes high stresses in the joint. Pelvic osteotomies are thought to be effective because they increase the weight bearing area in axial loading by bringing cartilage from medial and posterior areas up into the superior



28	CE angle (°)
22	Sharp angle (°)
21	AI (%)
73	AHI (%)
27	Head radius (mm)
31	Acetabular radius (mm)
86	ACP angle (degree)
48	Center X-coordinate (mm)
0.4	Center Y-coordinate (mm)

Between teardrops = 152 mm

	Area of head covered (%)
73	Total area
69	Anterior 1/2
76	Posterior 1/2
97	Ant. med. 1/4
42	Ant. lat. 1/4
52	Post. lat. 1/4
100	Post. med. 1/4
91	Ant./post. ratio

Tilt angle = 0°

Figure 4. 10 years postoperatively. The clinical score was excellent.

area (Millis et al. 1995). However, no long-term studies are available which show that increased coverage of the femoral head is related to better clinical results. Furthermore, the available data (Tönnis et al. 1994, Hsin et al. 1996) are based on assessments of this coverage from conventional anteroposterior radiographs by measurements such as of the center edge (Wiberg 1939) and Sharp angles (Sharp 1961). They are 2-dimensional measurements of a 3-dimensional object. For a more accurate assessment of the acetabular coverage, CT scans are especially valuable (Klaue et al. 1988), but long-term follow-up studies were not routinely available preoperatively, and at follow-up they cause ethical concerns because of the relatively large doses of ionizing radiation required (Wedge 1997). Using a previously published and validated computer program (Konishi and Mieno 1993), we analyzed the three-dimensional pre- and postoperative acetabular coverage in a series of patients with long-term clinical follow-up. The acetabular coverage was markedly improved. However, these data do not support the hypothesis that increased acetabular coverage of the femoral head is related to better long-term clinical outcome. 6 different clinical items were scored, but obviously these are partly subjective measurements. However, there was also no relationship between the acetabular coverage and the reasonably objective radiographic progression of osteoarthritis or the placement of a total hip arthroplasty. We could not define an optimal coverage, but among the 10 patients with progress of osteoarthritis, none have acetabular coverage in the normal range (between 65% and 80%) (Klaue et al. 1988).

There was a strong correlation between pre- and postoperative coverage, implying that preoperative coverage strongly influenced postoperative coverage. This must be due to the fact that these operations reorient the acetabulum, but they cannot enlarge it. This is also why the measured depth of the acetabulum (AI) remained unaltered. A very deficient acetabulum with a small total area of cartilage can be reoriented to improve coverage, but cannot provide normal coverage. Similarly, improving the coverage of the often deficient anterolateral quadrant may lead to uncovering of the posterolateral quadrant. We found that decreased

posterolateral coverage was significantly associated with a reduced walking capacity ( $p = 0.03$ ), and tended towards association with poor results ( $p = 0.18$ ). This implies that care must be taken not to create uncoverage of the posterolateral quadrant when reorienting the acetabulum. This will inevitably happen when performing a Salter innominate osteotomy (Salter 1984) in adults, as in that case the acetabulum is tilted forward about an axis between the sciatic notch and the pubic symphysis. It also means that preoperatively a CT scan should be made to assess the posterior coverage, which can be measured with the posterior acetabular sector angle (PASA) (Anda et al. 1991) to determine whether this is sufficient to allow for anterior reorientation.

If total acetabular coverage is not associated with clinical outcome, other factors must have an influence. The pain in the hip may be due to an osseous or nonosseous lesion of the acetabular rim (Klaue et al. 1991). Acetabular reorientation reduces the obliquity of the acetabulum and shear forces in the joint. Thereby the labrum and the acetabular rim are unloaded and symptoms might be alleviated.

Alternatively, if it is not the total coverage and the weight bearing area that is the most important factor in determining the clinical outcome, then the load across the hip might be. This would explain why we found a weak but significant influence of body weight on the incidence of poor results. In performing a triple osteotomy, the load across the hip joint might be reduced by changing the three-dimensional position of the center of the hip joint. A recent cadaver study (de Kleuver et al. 1998), using röntgen stereophotogrammetry (RSA), has shown that the center of the hip joint may be significantly displaced, especially in the posterior direction. This may lead to a change in load across the hip joint, thereby contributing to the efficacy of the operation.

We realize that the computer program we have used has certain weaknesses (Klaue 1995), but it has been validated against CT measurements and direct cadaver measurements (Konishi and Mieno 1993), and was shown to have similar accuracy as CT scans. It assumes that the femoral head is spherical, but this is not quite accurate. However, these operations were performed on patients with

congruent and almost spherical femoral heads. Furthermore, most current biomechanical analyses are based on the same assumption (Legal 1987). A more important limitation is that the fossa acetabuli is not taken into consideration. Although it may have some weight bearing capacity through the soft tissues in it, it must be considered less able to transfer loads than the articular cartilage of the acetabulum. Despite these limitations, since long-term follow-up series have no preoperative CT scans of the patients, we feel that up till now this is the only way to correlate long-term clinical results to pre- and postoperative three-dimensional acetabular coverage of the femoral head.

With the current clinical evaluation and calculation of three-dimensional acetabular coverage of the femoral head, we have not confirmed the expected relationship between acetabular coverage of the femoral head and clinical outcome. Therefore we challenge the concept that total acetabular coverage is a prerequisite for a good long-term result after triple pelvic osteotomy. We conclude that other variables, such as reduction of the load and shear forces, may be important in influencing the outcome of triple osteotomy of the pelvis. When reorienting the acetabulum, it is essential not to uncover the posterolateral quadrant of the femoral head, since this seems to be related to poorer results. For this reason, preoperative analysis of posterior coverage by means of CT scans is recommended.

We thank N. Konishi, MD, and T. Mieno, MD, for providing us with their computer program, and Rik Huiskes, PhD, for his valuable advice during the preparation of the manuscript.

- Anda S, Terjesen T, Kvistad K A. CT measurement of the acetabulum in adult dysplastic hips. *Skeletal Radiol* 1991; 20: 267-71.
- Bombelli R. Structure and function in normal and abnormal hips. 3rd edition. Springer Verlag, Berlin, 1993: 32-7.
- D'Aubigné R M, Postel M. Functional results of hip arthroplasty with acrylic cement. *J Bone Joint Surg (Am)* 1954; 36: 451-75.
- de Kleuver M, Kooijman M A P, Pavlov P W, Veth R P H. Triple osteotomy of the pelvis for acetabular dysplasia. Results at 8 to 15 years. *J Bone Joint Surg (Br)* 1997; 79: 225-9.
- de Kleuver M, Huiskes R, Kauer J M G, Veth R P H. Three-dimensional displacement of the hip joint after triple pelvic osteotomy. A postmortem radiostereometric study. *Acta Orthop Scand* 1998; 69: 585-9.
- Ganz R, Klaue K, Vinh T S, Mast J W. A new periacetabular osteotomy for the treatment of hip dysplasias. Technique and preliminary results. *Clin Orthop* 1988; 232: 26-36.
- Heyman C H, Herndon C H. Legg-Perthes disease. A method for the measurement of the roentgenographic result. *J Bone Joint Surg (Am)* 1950; 32: 767-78.
- Hsin J, Saluja R, Eilert R E, Wiedel J D. Evaluation of the biomechanics of the hip following a triple osteotomy of the innominate bone. *J Bone Joint Surg (Am)* 1996; 78: 855-62.
- Klaue K. Correspondence. *J Bone Joint Surg (Am)* 1995; 77: 153.
- Klaue K, Wallin A, Ganz R. CT evaluation of coverage and congruency of the hip prior to osteotomy. *Clin Orthop* 1988; 232: 15-25.
- Klaue K, Durmish C W, Ganz R. The acetabular rim syndrome. A clinical presentation of dysplasia of the hip. *J Bone Joint Surg (Br)* 1991; 73: 423-9.
- Konishi N, Mieno T. Determination of acetabular coverage of the femoral head with use of a single anteroposterior radiograph, a new computerized technique. *J Bone Joint Surg (Am)* 1993; 75: 1318-33.
- Legal H. Introduction to biomechanics of the hip. In: Congenital dysplasia and dislocation of the hip in children and adults. Springer Verlag, Berlin/Heidelberg 1987: 26-57.
- Millis M B, Murphy S B, Poss R. Osteotomies about the hip for the prevention and treatment of osteoarthritis. Instructional course lecture. *J Bone Joint Surg (Am)* 1995; 77: 626-46.
- Salter R B. Innominate osteotomy in the management of residual congenital subluxations of the hip in young adults. *Clin Orthop* 1984; 182: 53-68.
- Sharp I K. Acetabular dysplasia. The acetabular angle. *J Bone Joint Surg (Br)* 1961; 43: 268-72.
- Tönnis D. Congenital dysplasia and dislocation of the hip in children and adults. Springer Verlag, Berlin/Heidelberg 1987: 167.
- Tönnis D, Behrens K, Tscharan F. Eine neue Technik der Dreifachosteotomie zur Schwenkung dysplastischer Hüftpfannen bei Jugendlichen und Erwachsenen. *Z Orthop* 1981; 119: 253-65.
- Tönnis D, Arning A, Bloch M, Heinecke A, Kalschschmidt K. Triple pelvic osteotomy. *J Pediatr Orthop B* 1994; 3: 54-67.
- Wagner H. Erfahrungen mit der Pfannenosteotomie bei der dysplastischen Hüftgelenkpfanne. *Orthopäde* 1973; 2: 253-9.
- Wedge J H. Hip joint acetabular dysplasia. Editorial. *J Paediatr Orthop* 1997; 17: 141-2.
- Wiberg G. Studies on dysplastic acetabula and congenital subluxation of the hip joint, with special reference to the complication of osteo-arthritis. *Acta Chir Scand (Suppl 58)* 1939: 83.