

## PDF hosted at the Radboud Repository of the Radboud University Nijmegen

The following full text is a publisher's version.

For additional information about this publication click this link.

<http://hdl.handle.net/2066/14769>

Please be advised that this information was generated on 2021-10-25 and may be subject to change.

F. C. Henny, Ch. J. J. Mulder, A. S. Lampe, J. W. M. van der Meer

## Branhamella catarrhalis Septicaemia in a Granulocytopenic Patient

**Summary:** A patient with acute leukaemia developed a maxillary sinusitis and septicaemia with *Branhamella catarrhalis* during the period of bone marrow hypoplasia. One blood culture also grew *Staphylococcus aureus*. In the same period, the patient developed tender red skin lesions and disseminated intra-vascular coagulation. The patient recovered when therapy with high dosages of amoxicillin was instituted. At the same time, however, the bone marrow recovered.

**Zusammenfassung:** *Branhamella catarrhalis*-Septikämie bei einem granulozytopenischen Patienten. Bei einem Patienten mit akuter Leukämie trat während der Phase der Knochenmarksdepression eine Sinusitis maxillaris und Septikämie durch *Branhamella catarrhalis* auf. In einer Blutkultur wuchs auch *Staphylococcus aureus*. In der gleichen Phase entwickelten sich bei dem Patienten weiche gerötete Hautläsionen und eine disseminierte intravasale Gerinnung. Unter hohen Dosen Amoxicillin erholte sich der Patient, gleichzeitig regenerierte auch das Knochenmark.

### Introduction

*Branhamella catarrhalis* (former name: *Neisseria catarrhalis*) is a gram-negative diplococcus which occurs as a commensal in the upper respiratory tract. The organism may cause acute, often mild and self-limiting infections such as otitis media, maxillary sinusitis and lower respiratory tract infections (1, 2). Recently, however, *B. catarrhalis* has been reported as the etiologic agent of serious infections, especially in the immuno and myelo-suppressed host (3-9). The present paper reports a case of septicaemia in a leukaemic patient.

### Case Report

A 24-year-old woman was admitted because of acute myeloblastic leukaemia (AML) in relapse. The AML had been diagnosed six months before, and administration of daunorubicine, vincristine and cytosine arabinoside had been followed by a remission. On examination there were no abnormalities. Laboratory investigations: Hb: 8.9 mmol/l; WBC:  $37 \times 10^9/l$  with  $4.2 \times 10^9/l$  granulocytes and 85% blast cells; platelet count:  $7.0 \times 10^9/l$ . Further laboratory studies were normal. Chest and sinus radiographs were normal. Under protective isolation and oral antibiotic prophylaxis consisting of neomycin, polymyxin B, amphotericin B and nalidixic acid (SAM regimen) (10), intermediate dose cytosine arabinoside and daunorubicine (11) was started. During the period of pancytopenia she developed a temperature of 39° C. Physical examination revealed only a nasopharyngitis and

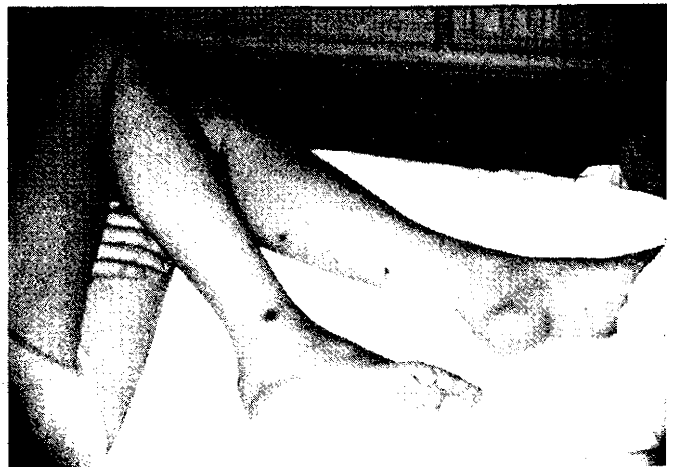


Figure 1: Tender red subcutaneous nodules on the legs.

bacteriological investigations showed no abnormalities. The temperature returned to normal without systemic antibiotics.

A week later, still pancytopenic, she had a chill after a transfusion and developed diarrhoea. She appeared ill with a temperature of 39° C. The chest X-ray was normal, but sinus X-ray films disclosed an air fluid level in the right maxillary sinus. Blood cultures were taken and because septicaemia was suspected, treatment with intravenous tobramycin and cefamandole (4x1 g) was started. During the next four days her temperature remained around 39° C and repeated examinations showed no abnormalities.

On the fifth day tender red subcutaneous nodules (Figure 1) were found on the arms and legs. Cultures from the maxillary sinus could not be taken because of disseminated intravascular coagulation (DIC) and profound thrombocytopenia. On the same day three blood cultures were reported to be positive for *B. catarrhalis*, sensitive to amoxicillin and to cefamandole, intermediate to tobramycin and resistant to sulfamethoxazole and trimethoprim (disk diffusion technique). One of the blood cultures also yielded *Staphylococcus aureus*, as did one stool specimen. Antibiotic treatment was changed to amoxicillin (6 x 2 g) and cloxacillin (6x1 g) intravenously. Within the next five days the bone marrow recovered, the skin lesions cleared and the temperature returned to normal. At this time an aspirate from the maxillary sinus showed many leucocytes, but no bacteria in the Gram stain; cultures remained sterile. Amoxicillin and cloxacillin were continued for twelve days. The patient experienced another remission and was discharged in good condition.

Received: 19 January 1984/Accepted: 28 March 1984

F. C. Henny, M. D., Department of Nephrology, University Hospital Leiden, NL-Leiden;

Ch. J. J. Mulder, M. D., J. W. M. van der Meer, M. D., Department of Infectious Diseases, University Hospital Leiden, NL-Leiden;

A. S. Lampe, M. D., Department of Medical Microbiology, University Hospital Leiden, NL-Leiden.

## Discussion

This report documents the pathogenicity of *B. catarrhalis* in a compromised host. Previously, this agent was recognised as the cause of otitis media (1), maxillary sinusitis (2), pneumonia (3, 7), meningitis with septicaemia (4, 6) and endocarditis (8, 9). Our patient had subcutaneous nodules giving the impression of a disseminated infection. Since the lesions were not punctured for culture, we cannot prove that they represented metastatic lesions with *B. catarrhalis*. The skin lesions did not resemble the skin lesions of meningococcal septicaemia which have also been reported in *B. catarrhalis* meningitis (6). As a gram-negative microorganism, *B. catarrhalis* produces endotoxin and this might explain the DIC. Although the *B. catarrhalis* strain was sensitive *in vitro* to cefamandole, our patient did not respond until a high dose of amoxicillin was given.

At the same time, however, the bone marrow recovered. Since organisms like *B. catarrhalis* are not eradicated with the oral non-absorbable antibiotics used (10), infections with such microorganisms can occur.

Prophylaxis with co-trimoxazole (12) most probably would not have prevented this infection either, since the microorganism was co-trimoxazole-resistant. Our case report underlines the experience in previous reports that *B. catarrhalis* is an opportunistic pathogen that may cause serious systemic infections in the compromised host.

## Acknowledgements

We are grateful to Prof. Dr. R. van Furth and Dr. J. M. Dunbar for their critical review of the manuscript and to Mrs. A. H. Picket for her secretarial help.

## Literature

1. Coffey, J. D.: Otitis media in the practice of pediatrics. *Pediatrics* 38 (1966) 25-32.
2. Brorson, J. E., Axelsson, A., Holm, S. E.: Studies on *Branhamella catarrhalis* (*Neisseria catarrhalis*) with special reference to maxillary sinusitis. *Scand. J. Infect. Dis.* 8 (1976) 151-155.
3. McNeely, D. J., Kitchens, C. S., Kluge, R. M.: Fatal *Neisseria* (*Branhamella*) *catarrhalis* pneumonia in an immunodeficient host. *Am. Rev. Respir. Dis.* 14 (1976) 399-402.
4. Pfister, L. E., Gallagher, M. V., Potterfield, T. G., van Brown, D. W.: *Neisseria catarrhalis* bacteremia with meningitis. *JAMA* 193 (1965) 399-401.
5. Doern, G. V., Miller, M. J., Winn, R. E.: *Branhamella* (*Neisseria*) *catarrhalis* systemic disease in humans. *Arch. Intern. Med.* 141 (1981) 1690-1692.
6. Feigin, R. D., San Joaquin, V., Middelkamp, J. N.: Purpura fulminans associated with *Neisseria catarrhalis* septicaemia and meningitis. *Pediatrics* 44 (1969) 120-123.
7. Srinivasan, G., Raff, M. J., Templeton, W. C., Givens, S. J., Grave, R. C., Melo, J. C.: *Branhamella catarrhalis* pneumonia. *Am. Rev. Respir. Dis.* 123 (1981) 553-555.
8. Pollock, A. A., Holzman, R. S.: *Neisseria catarrhalis* endocarditis. *Ann. Intern. Med.* 85 (1976) 206-207.
9. Douer, D., Danziger, Y., Pinkhas, J.: *Neisseria catarrhalis* endocarditis. *Ann. Intern. Med.* 86 (1977) 116-119.
10. Guiot, H. F. L., van den Broek, P. J., van der Meer, J. W. M., van Furth, R.: Selective antimicrobial modulation of the intestinal flora of patients with acute non-lymphocytic leukaemia: A double-blind, placebo-controlled study. *J. Infect. Dis.* 147 (1983) 615-623.
11. Willemze, R., Fibbe, W. E., Zwaan, F. E.: Experience with intermediate and high dose cytosine arabinoside in refractory acute leukaemia. *Onkologie* 6 (1983) 200-204.
12. Dekker, A. W., Rozenberg-Arska, M., Sixma, J. J., Verhoef, J.: Prevention of infection by trimethoprim-sulfamethoxazole plus amphotericin B in patients with acute non-lymphocytic leukaemia. *Ann. Intern. Med.* 95 (1981) 555-559.