

Retinoids Strongly and Selectively Correlate With Keratin 13 and Not Keratin 19 Expression in Cutaneous Warts of Renal Transplant Recipients

Willeke A. M. Blokx, MD; Jurgen V. Smit, MD; Elke M. G. J. de Jong, MD, PhD; Monique M. G. M. Link; Peter C. M. van de Kerkhof, MD, PhD; Dirk J. Ruiter, MD, PhD

Objective: To compare the expression of keratin (K) 13 and K19 in cutaneous warts of renal transplant recipients (RTRs) and immunocompetent individuals (ICIs).

Design: Retrospective, nonrandomized immunohistochemical study.

Patients and Methods: Specimens from cutaneous warts of RTRs and ICIs were retrieved from the archives of the Department of Pathology, University Medical Center St Radboud, Nijmegen, the Netherlands. Twenty-one warts from RTRs and 21 from ICIs were examined. Nine RTRs (10 specimens) received either systemic acitretin or topical all-*trans* retinoic acid, and their effect on both keratins was assessed.

Main Outcome Measures: Frequency and expression patterns of K13 and K19 in warts of RTRs vs ICIs and the effect of retinoids.

Results: A significantly higher percentage of warts of RTRs expressed K13 compared with warts of ICIs (86% vs 14%, 18 vs 3 cases, respectively; $P < .001$). In warts of RTRs, retinoid treatment correlated significantly with a particularly strong, segmental K13 expression pattern, which we termed *zebroid*. Without use of retinoids, K13 was mostly restricted to suprabasal single cells. Keratin 19 was absent in all warts of both patient groups.

Conclusions: Retinoids strongly correlate with K13 in a characteristic zebroid pattern in warts of RTRs, making K13 a sensitive marker for retinoid bioactivity in skin (lesions) of RTRs. In non-retinoid-treated RTRs, K13 is also frequently found in warts but without the dramatic zebroid pattern noted in retinoid-treated warts.

Arch Dermatol. 2002;138:61-65

EPITHELIAL KERATINS comprise a heterogeneous group of acidic (type I) and neutral-to-basic (type II) proteins. As a general rule, they are coexpressed in specific pairings, each pair consisting of a type I and a type II keratin (K). For instance, in normal adult skin, keratin pairs K5/K14 and K1/K10 predominate in the basal layer and the suprabasal compartment, respectively.¹

The type I keratins K13 and K19 are usually expressed separately in adult epithelia. Combined expression occurs only in fetal skin. Both keratins are thought to be absent in normal skin of adults except at certain body sites, such as the penile foreskin, which still contains K13. Furthermore, K13 is abundantly present in adults in internal stratified epithelia and is associated (with terminal differentiation) with suprabasal expression.¹⁻⁴ Expression of K19 in adults is found in simple epithelia, such as most glandular epithelia.

In the past few years, several murine and in vitro studies have demonstrated that vitamin A and its derivatives (retinoids) are important regulators of epidermal differentiation and affect keratin gene expression. In cultured keratinocytes, the induction of an embryonic type of differentiation by retinoids with reinduction of K13 and K19 expression has been well documented.^{5,6} In vivo topical application of retinoids on photo-aged human skin also showed induction of K13.⁷

Although retinoids are used as chemopreventive agents for inhibiting skin cancer in renal transplant recipients (RTRs),^{8,9} to the best of our knowledge there are no studies regarding the effects of retinoids on keratin expression in the skin or skin lesions of these patients.

Renal transplant recipients develop multiple warts and skin neoplasms. Immunosuppressive treatment, sun exposure, and viral infection with human papillomavirus are all implicated in the etiology of cutane-

From the Departments of Pathology (Drs Blokx and Ruiter and Ms Link) and Dermatology (Drs Smit, de Jong, and van de Kerkhof), University Medical Center St Radboud, Nijmegen, the Netherlands.

MATERIALS AND METHODS

TISSUE SAMPLES

For this retrospective immunohistochemical study, we retrieved formalin-fixed and paraffin-embedded skin specimens from warts of RTRs (21 specimens from 18 patients; average age, 50.8 years; mean duration of immunosuppression, 16.4 years) and healthy ICIs (21 specimens from 19 patients; average age, 33.3 years) from archival material at the Department of Pathology, University Medical Center St Radboud, Nijmegen, the Netherlands.

RETINOID TREATMENT

Nine RTRs (10 specimens) received retinoids. In 3 patients (4 specimens), topical all-trans retinoic acid (concentration, 0.025%-0.05%) was used, and 6 patients received systemic acitretin (dose at time of biopsy, 10-35 mg). Patients taking systemic acitretin participated in a clinical trial, unrelated to the present study, studying the effects of systemic retinoids on cutaneous carcinogenesis in RTRs. Inclusion criteria for this trial were either the presence of at least 1 squamous cell carcinoma (SCC) in the patient's history or the presence of 10 or more actinic keratoses, with at least 1 confirmed histologically. Initially, most patients taking acitretin started with 30 to 35 mg/d, a dosage that prevented SCCs in RTRs in an earlier study.⁸ However, in a relatively large number of patients, doses of acitretin had to be lowered because of mucocutaneous adverse effects (peeling of palms and soles and/or cheilitis). Retinoid- and non-retinoid-treated patients showed no obvious differences with respect to duration, dosage, and type of immunosuppression, all factors implied in the etiology of skin cancers in immunosuppressed patients (data not shown).

HISTOPATHOLOGIC EXAMINATION

Histologic examination of all studied lesions was revised according to World Health Organization definitions of verrucae.¹⁶ The verrucae consisted predominantly of common warts or verrucae vulgares, with a smaller group of

verrucae plana, especially in ICIs, usually on the hands and feet. Condyloma acuminata and anogenital warts were not included.

IMMUNOHISTOCHEMICAL ANALYSIS

Immunohistochemical analysis was performed on all specimens by using standard avidin-biotin-peroxidase complex system with either diaminobenzidine and/or 3-amino-9-ethylcarbazole as the chromogens. In brief, 4- μ m-thick paraffin sections were deparaffinized, hydrated, and washed in buffered phosphate.

For K13 staining, sections were cooked in buffered citrate (10mM, pH 6.0) in a microwave oven 2 times for 5 minutes each (600 W). After a cooling down period of (at least) 20 minutes and preincubation with 20% normal horse serum for 15 minutes, the sections were incubated with undiluted primary antibody overnight at 4°C. We used 2 mouse monoclonal primary antibodies, 1C7 (immunoglobulin G2a) and 2D7 (immunoglobulin G2b), both recognizing K13.¹⁷ As a positive control, normal esophageal tissue was used. After incubation with primary antibodies, sections were incubated for 30 minutes with biotinylated horse antimouse (1:200 dilution) (Vector Laboratories, Burlingame, Calif), followed by incubation for 45 minutes with avidin-biotin complex (1:50 dilution) (Vector Laboratories). For development with 3-amino-9-ethylcarbazole, avidin-biotin complex concentrations were doubled.

For K19 immunohistochemical analysis, (mouse) monoclonal antibody RCK 108 (Biogenex, San Ramon, Calif) was used. Besides different pretreatment (0.1% pronase for 10 minutes), the same procedure as used for K13 was followed. Eccrine ducts and sweat glands served as positive internal controls. Sections were counterstained with Mayer hematoxylin for 2 minutes.

Immunoreactivity was scored as negative, slightly positive in a suprabasal single-cell pattern (<10% lesional keratinocytes positive), or strongly positive in a suprabasal segmental columns pattern (zebroid pattern). Scoring was performed without knowledge of patient history and use of retinoid therapy.

The Pearson χ^2 test was used for all statistical analyses, and significance was set at $P < .05$.

ous tumorigenesis in RTRs.¹⁰⁻¹⁴ The frequent simultaneous occurrence of warts and skin cancers in RTRs led us to the assumption that the verrucae or warts in RTRs might be more prone to become malignant than equivalent lesions in healthy immunocompetent individuals (ICIs). The existence of high- and low-risk papillomas was previously shown in mice models of cutaneous carcinogenesis.¹⁵ Interestingly, these high-risk papillomas expressed K13, which was absent in low-risk papillomas.

The present study shows that RTR-associated warts in contrast to warts in normal ICIs indeed show pronounced K13 expression. This suggests that altered keratin expression may reflect an important molecular event inherent in the malignant degeneration of warts in RTRs. Furthermore, this K13 expression in warts of RTRs strongly correlates with retinoid therapy, but, in contrast to findings in animal studies and in cultured human keratinocytes,⁵ we could not demonstrate an effect

of retinoids on K19 expression in these patients. Retinoid-related K13 expression in epithelial skin lesions of RTRs displays a highly characteristic pattern, which we termed *zebroid*, making K13 a useful marker for evaluating the effect of retinoid treatment in these patients.

RESULTS

GENERAL ASPECTS OF IMMUNOSTAINING FOR K13 AND K19

In all cases, immunostaining for K13 was restricted to the cytoplasm. Slight variations in staining intensity were observed in lesional skin comparing antibodies 1C7 and 2D7 with overall stronger staining with the 2D7 antibody. Principally, however, the staining pattern of lesional skin with both antibodies was identical. Normal

Table 1. K13-Positive and K13-Negative Warts in RTRs and ICIs*

	Warts, No. (%)	
	RTRs (n = 21)	ICIs (n = 21)
K13 positive	18 (86)	3 (14)
K13 negative	3 (14)	18 (86)

*K13 indicates keratin 13; RTRs, renal transplant recipients; and ICIs, immunocompetent individuals.

esophagus was used as a positive control and showed strong diffuse suprabasal staining.

Keratin 19 immunostaining was also localized in the cytoplasm. Eccrine ducts and sweat glands, serving as internal controls, showed marked positivity.

EXPRESSION OF K13 AND K19 IN WARTS OF RTRs VS ICIs AND EFFECTS OF RETINOID TREATMENT

There was a significant difference in K13 expression between warts of RTRs and warts of ICIs ($P < .001$). A high percentage of warts of RTRs (86%, 18 cases) showed K13 expression, whereas in benign warts of ICIs almost all lesions were negative except for 3 (14%) of 21 with suprabasal single-cell positivity (**Table 1** and **Figure 1**). This statistical difference in K13 positivity remained when we excluded retinoid-treated patients: 82% K13 positivity in non-retinoid-treated RTRs vs 14% in controls ($P < .001$). Besides number of positive specimens, the proportion of positive lesional cells also differed and was more pronounced in warts of RTRs: the 3 positive warts of ICIs showed only suprabasal single-cell positivity (**Figure 2**); in RTRs, half of the 18 positive warts also showed this suprabasal single-cell positivity, whereas the other half showed strong positive staining in a remarkable pattern of segmental positive suprabasal full epithelium thickness columns (zebroid pattern) (**Figure 1B, D** and **Figure 2**). This particular pattern was not linked to eccrine ducts or hair follicle structures; the latter actually seemed to be spared. This zebroid pattern correlated with retinoid treatment (topical and systemic) when comparing retinoid-treated RTRs (warts and in situ SCCs) with non-retinoid-treated RTRs (**Table 2**) ($P < .001$). Only 1 patient without (anamnestically traceable) retinoid treatment exhibited the same K13 expression pattern.

Most warts were superficially excised, with no perilesional skin available. In 1 retinoid-treated RTR, the perilesional skin showed K13 positivity comparable with the previously described zebroid pattern. All warts in both groups were negative for K19, with use of retinoids having no demonstrable effect on K19 expression (**Figure 1C-D**).

COMMENT

Data from numerous animal and in vitro studies^{5,6,18-20} with cultured human keratinocytes indicate that retinoids affect epidermal proliferation and differentiation.

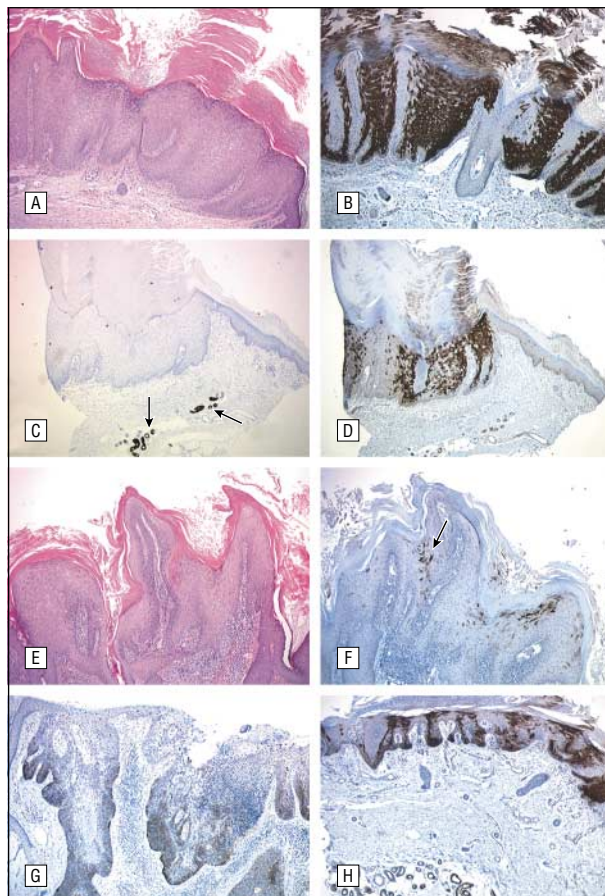


Figure 1. A, Hematoxylin-eosin staining of a wart from a retinoid-treated renal transplant recipient (RTR) (original magnification $\times 40$). B, Immunohistochemical analysis of a wart from a retinoid-treated RTR for keratin (K) 13 (monoclonal antibody 2D7, with diaminobenzidine as the chromogen) showing the particularly strong 3+ positive zebroid pattern of alternating suprabasal columns of K13-positive and K13-negative keratinocytes. This zebroid pattern was significantly correlated to retinoid treatment in RTRs (original magnification $\times 40$). C and D, Wart of a retinoid-treated RTR showing uncoupled regulation of K13 and K19 expression by retinoids, with strong zebroid pattern K13 positivity (D), whereas K19 expression is absent (C). The arrows (C) point to K19-positive sweat glands, which serve as an internal control (original magnification $\times 40$). E, Hematoxylin-eosin staining of a wart from an immunocompetent individual (ICI) (original magnification $\times 40$). F, Immunohistochemical analysis of a wart from an ICI for K13 (2D7, diaminobenzidine) showing suprabasal single-cell positivity (arrow). This pattern of K13 expression was also typical of warts from non-retinoid-treated RTRs (original magnification $\times 40$). G, In situ squamous cell carcinoma (ISCC) of an RTR showing K13 (2D7) expression partially centered around hair follicle structures (original magnification $\times 40$). This staining pattern differs considerably from the retinoid therapy-related zebroid K13 pattern. H, Perilesional skin specimen from an ISCC of an RTR receiving retinoid treatment. Immunohistochemical analysis of K13 (2D7) shows the same zebroid pattern as in lesional skin of most warts of retinoid-treated RTRs (original magnification $\times 25$).

Retinoids proved to repress differentiation-specific keratins (K1/K10) and strikingly reinduced expression of K13 and K19, 2 keratins that are only coexpressed in fetal skin and are not usually present in the epidermis of adults.^{2,4} In contrast to these findings of coupled K13 and K19 induction by retinoids, Agarwal et al²¹ were the first to report uncoupled regulation of K13 and K19 expression in a human SCC cell line.

Our in vivo data with immunohistochemical evaluation of K13 and K19 expression in warts of RTRs vs ICIs show that retinoids used as chemoprotective agents in

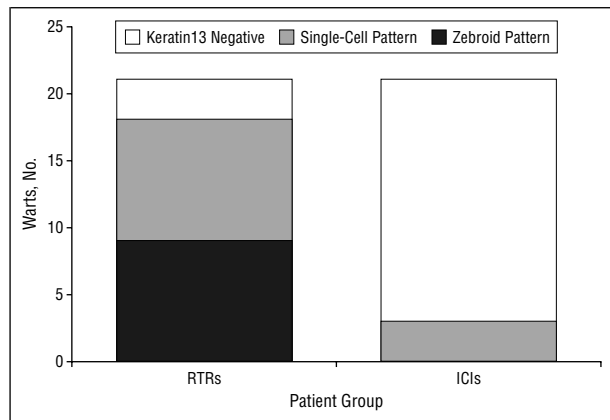


Figure 2. Keratin 13 expression patterns in warts of renal transplant recipients (RTRs) vs immunocompetent individuals (ICIs).

RTRs for preventing skin cancer also strongly relate only to K13, and not K19, expression. Our finding of retinoid therapy–related uncoupled K13 and K19 expression in these patients could be 3-fold. First, the retinoid concentration in our patients could be sufficient to enhance K13 expression but not K19 expression. Earlier findings⁶ in human epidermal cultures showed stronger induction of K13 than K19 by retinoids with an already marked increase of K13 in response to low levels of retinoids, whereas for K19 induction a higher retinoid concentration was necessary. Although the dosage of systemic retinoids taken by many of our patients had to be lowered during treatment because of severe mucocutaneous adverse effects, no induction of K19 was found in patients still receiving the higher dosages of acitretin. Second, the response of keratinocytes to retinoids in vitro might not be representative of the response in vivo, and retinoids in humans in vivo might not induce an embryonic type of differentiation and might only selectively induce K13 expression. In the only previous in vivo study⁷ on the effects of retinoids in photo-aged skin only K13, and not K19, expression was studied. Finally, this differentiation toward esophageal-type epithelium in contrast to so-called embryonic-type differentiation found in animals and in vitro could be specific for skin and skin lesions in RTRs: earlier studies¹⁹ already showed that effects of retinoids differed in normal compared with diseased keratinocytes.

Retinoid treatment significantly correlated with a specific pattern of K13 expression in skin lesions of RTRs. This pattern, which we termed zebroid because of alternating suprabasal columns of K13-positive and K13-negative keratinocytes, is suggestive of a genetic mosaicism, reflecting clonal expansion of genetically altered stem cells. In warts and slightly dysplastic skin of RTRs, segments of epidermis may contain keratinocytes with a genetic abnormality, making them more susceptible to inductive actions of retinoids. Future studies might unravel the underlying genes that are involved in this process and whether, for instance, (transforming types of) human papillomavirus might play a role.²²

Interpretation of the biological impact of K13 expression in retinoid- and non-retinoid-treated warts of RTRs could be 2-fold. The first interpretation relates the

Table 2. Strong Keratin 13 (K13) Positivity (Zebroid Pattern) and Nonzebraid K13 Positivity vs Retinoid Therapy in Renal Transplant Recipients

	Warts, No. (%)	
	Retinoid Treated (n = 10)	Non-Retinoid Treated (n = 11)
K13 zebroid pattern	9 (90)	1 (9)
K13 nonzebraid pattern	1 (10)	10 (91)

presence of K13 in skin to differentiation, in parallel to internal squamous epithelia, in which K13 is restricted to the suprabasal epithelial compartment and is associated with differentiation. Retinoids, by inducing K13 expression or directing keratinocytes toward (esophageal) differentiation, might be chemopreventive by “freezing” cells in this differentiated state and preventing them from (further) dedifferentiating. Results of previous studies^{6,23,24} of retinoid effects on epidermal keratinocytes have shown that in response to retinoid treatment, higher molecular weight keratins, typically encountered in squamous epithelia, disappear, and synthesis of 2 new low molecular-weight keratins, a 40- and a 52-kd keratin, corresponding to K19 and K13, respectively, is enhanced. In the absence of vitamin A, the opposite occurs, with an enhanced terminal epidermal type of differentiation.²⁵ Retinoid-induced esophageal-type differentiation could provide an explanation for the cosmetic improvement of lesional skin in these RTRs, who often had multiple hyperkeratoses before treatment: esophageal epithelium is, in contrast to the keratinizing epidermis, a nonkeratinizing squamous epithelium. By inducing nonkeratinizing differentiation, retinoids could lower the number of hyperkeratotic skin lesions. As an adverse effect, in normal skin the diminished cutaneous keratinization caused by retinoids leads to desquamation of palms and soles, which usually show the most prominent keratinization. On the lips, the outer cutaneous side becomes more vulnerable because of differentiation toward wet epithelium, leading to cheilitis, another known adverse effect of acitretin treatment also present in our patients.^{8,9,26}

The second interpretation relates the presence of K13 to a more dedifferentiated and potentially malignant phenotype. Regarding cutaneous carcinogenesis, malignant transformation is heralded by a switch from production of high-molecular-weight keratins usually present in adult skin (K1/K10) to low-molecular-weight keratins also characteristic of fetal skin and simple epithelia (eg, K8/K18 and K19).¹ Presence of K13, a low-molecular-weight embryonic keratin, would fit within this concept. It is tempting to attribute relevance to the high frequency of K13 in warts of RTRs and to speculate that it may be related to the higher susceptibility of warts in these patients to become malignant. This would be analogous to mouse models on skin carcinogenesis in which aberrant K13 expression is a consistent finding in chemically and v-Ha-ras–induced papillomas and SCCs.^{15,27,28} In in situ SCCs of RTRs and ICIs we found frequent K13 expression in 75% and 45% of lesions, respectively (20 in situ SCCs

tested within each group, data not shown), which is in concert with this second hypothesis. The pattern of K13 expression in in situ SCCs of both groups was different from the retinoid therapy-related K13 expression (zebroid pattern, compare Figure 1B, G). Only 4 RTRs with in situ SCCs used retinoids, and in these patients the retinoid therapy-related zebroid K13 pattern was most pronounced or only present in perilesional, slightly dysplastic skin (Figure 1H).

When this latter interpretation would be applicable to retinoid-related K13 expression, use of retinoids might actually be dangerous for these patients. This is contradicted by studies of the long-term safety of retinoid therapy, since no increased incidence of skin cancer is reported.²⁹ Studies of skin cancer chemoprophylaxis with retinoids in RTRs actually showed reduction in the skin cancer incidence.⁸

In conclusion, this retrospective in vivo study of embryonic keratin expression in warts of RTRs shows that retinoids strongly relate to K13 but not K19 expression. By keeping keratinocytes in this esophageal-type differentiation, retinoids might act chemopreventively. Retinoids correlate with a highly distinctive and strong K13 expression, which we termed zebroid, making K13 a useful marker for evaluating retinoid treatment in these patients. The alternating zebroid K13 pattern is suggestive of an underlying genetic mosaicism. Even in the absence of retinoids, a significantly higher percentage of K13 positivity is found in warts of RTRs compared with warts of ICIs. Future prospective, randomized, and well-controlled studies need to establish the relevance of this finding and whether K13, in analogue to mouse models of skin carcinogenesis, might become a predictive marker for malignant progression.

Accepted for publication May 15, 2001.

We thank Peter C. M. de Wilde, MD, PhD, for statistical assistance and Goos N. van Muijen, MD, PhD, for providing monoclonal antibodies 1C7 and 2D7 and for critically reading the manuscript.

Corresponding author and reprints: Willeke A. M. Blokk, MD, Department of Pathology, University Medical Center St Radboud, PO Box 9101, 6500 HB Nijmegen, the Netherlands (e-mail: w.blokk@pathol.azn.nl).

REFERENCES

- Smack DP, Korge BP, James WD. Keratin and keratinization. *J Am Acad Dermatol*. 1994;30:85-102.
- Moll R, Moll I, Wiest W. Changes in the pattern of cytokeratin polypeptides in epidermis and hair follicles during skin development in human fetuses. *Differentiation*. 1982;23:170-178.
- Kuruc N, Leube RE, Moll I, Bader BL, Franke WW. Synthesis of cytokeratin 13, a component characteristic of internal stratified epithelia, is not induced in human epidermal tumors. *Differentiation*. 1989;42:111-123.
- Van Muijen GN, Warnaar SO, Ponc M. Differentiation-related changes of cytokeratin expression in cultured keratinocytes and in fetal, newborn, and adult epidermis. *Exp Cell Res*. 1987;171:331-345.
- Korge B, Stadler R, Mischke D. Effect of retinoids on hyperproliferation-associated keratins K6 and K16 in cultured human keratinocytes: a quantitative analysis. *J Invest Dermatol*. 1990;95:450-455.
- Kopan R, Traska G, Fuchs E. Retinoids as important regulators of terminal differentiation: examining keratin expression in individual epidermal cells at various stages of keratinization. *J Cell Biol*. 1987;105:427-440.
- Rosenthal DS, Roop DR, Huff CA, et al. Changes in photo-aged human skin following topical application of all-trans retinoic acid. *J Invest Dermatol*. 1990;95:510-515.
- Bavinck JN, Tieben LM, Van der Woude FJ, et al. Prevention of skin cancer and reduction of keratotic skin lesions during acitretin therapy in renal transplant recipients: a double-blind, placebo-controlled study. *J Clin Oncol*. 1995;13:1933-1938.
- Yuan ZF, Davis A, Macdonald K, Bailey RR. Use of acitretin for the skin complications in renal transplant recipients. *N Z Med J*. 1995;108:255-256.
- Penn I. Neoplastic complications of transplantation. *Semin Respir Infect*. 1993;8:233-239.
- Barr BB, Benton EC, McLaren K, et al. Human papilloma virus infection and skin cancer in renal allograft recipients. *Lancet*. 1989;1:124-129.
- Boyle J, MacKie RM, Briggs JD, Junor BJ, Aitchison TC. Cancer, warts, and sunshine in renal transplant patients: a case-control study. *Lancet*. 1984;1:702-705.
- Seckin D, Gulec TO, Demirag A, Bilgin N. Renal transplantation and skin diseases. *Transplant Proc*. 1998;30:802-804.
- Webb MC, Compton F, Andrews PA, Koffman CG. Skin tumour posttransplantation: a retrospective analysis of 28 years' experience at a single centre. *Transplant Proc*. 1997;29:828-830.
- Yuspa SH. The pathogenesis of squamous cell cancer: lessons learned from studies of skin carcinogenesis. *J Dermatol Sci*. 1998;17:1-7.
- Heenan PJ, Elder DE, Sobin LH. *International Histological Classification of Tumours*. Vol 12. 2nd ed. Berlin, Germany: Springer-Verlag; 1996.
- van Muijen GN, Rüter DJ, Franke WW, et al. Cell type heterogeneity of cytokeratin expression in complex epithelia and carcinomas as demonstrated by monoclonal antibodies specific for cytokeratins nos. 4 and 13. *Exp Cell Res*. 1986;162:97-113.
- Eichner R, Kahn M, Capetola RJ, Gendimenico GJ, Mezick JA. Effects of topical retinoids on cytoskeletal proteins: implications for retinoid effects on epidermal differentiation. *J Invest Dermatol*. 1992;98:154-161.
- van Rossum MM, Mommers JM, van de Kerkhof PC, van Erp PE. Coexpression of keratins 13 and 16 in human keratinocytes indicates association between hyperproliferation-associated and retinoid-induced differentiation. *Arch Dermatol Res*. 2000;292:16-20.
- Griffiths CE, Elder JT, Bernard BA, et al. Comparison of CD271 (adapalene) and all-trans retinoic acid in human skin: dissociation of epidermal effects and CRABP-II mRNA expression [see Comments]. *J Invest Dermatol*. 1993;101:325-328.
- Agarwal C, Rorke EA, Boyce M, et al. Retinoid-dependent transcriptional suppression of cytokeratin gene expression in human epidermal squamous cell carcinoma cells. *Differentiation*. 1993;52:185-191.
- Pirisi L, Batova A, Jenkins GR, Hodam JR, Creek KE. Increased sensitivity of human keratinocytes immortalized by human papillomavirus type 16 DNA to growth control by retinoids. *Cancer Res*. 1992;52:187-193.
- Elias PM. Retinoid effects on the epidermis. *Dermatologica*. 1987;175(suppl 1):28-36.
- Stadler R, Muller R, Detmar M, Orfanos CE. Retinoids and keratinocyte differentiation in vitro. *Dermatologica*. 1987;175:45-55.
- Vahlquist A, Torma H. Retinoids and keratinization: current concepts. *Int J Dermatol*. 1988;27:81-95.
- Gupta AK, Goldfarb MT, Ellis CN, Voorhees JJ. Side-effect profile of acitretin therapy in psoriasis. *J Am Acad Dermatol*. 1989;20:1088-1093.
- Sutter C, Strickland JE, Welty DJ, Yuspa SH, Winter H, Schweizer J. v-Ha-ras-induced mouse skin papillomas exhibit aberrant expression of keratin K13 as do their 7,12-dimethylbenz[a]anthracene/12-O-tetradecanoylphorbol-13-acetate-induced analogues. *Mol Carcinog*. 1991;4:467-476.
- Nischt R, Roop DR, Mehrel T, et al. Aberrant expression during two-stage mouse skin carcinogenesis of a type I 47-kDa keratin, K13, normally associated with terminal differentiation of internal stratified epithelia. *Mol Carcinog*. 1988;1:96-108.
- Vahlquist A. Long-term safety of retinoid therapy. *J Am Acad Dermatol*. 1992;27:S29-S33.