

PDF hosted at the Radboud Repository of the Radboud University Nijmegen

The following full text is a publisher's version.

For additional information about this publication click this link.

<http://hdl.handle.net/2066/140867>

Please be advised that this information was generated on 2019-06-18 and may be subject to change.

WILMS TUMOR WITH TERATOMATOUS CYSTS IN A HORSESHOE KIDNEY: A DIAGNOSTIC PITFALL

HENK G. VAN DER POEL,* WOUTER F. J. FEITZ, JOS BÖKKERINK, FRANS V. D. STAAK AND
JOS D. M. DE VRIES

From the Departments of Urology, Pediatric Oncology and Pediatric Surgery, University Hospital, Nijmegen, The Netherlands

KEY WORDS: kidney, Wilms' tumor, teratoma, abnormalities

In 0.3 to 4% of patients with a Wilms tumor the tumor arises in a horseshoe kidney.¹ Patients with horseshoe kidneys have a 1.5 to 8-fold increased risk for Wilms tumor. The diagnosis in these cases can be difficult² and it is often incorrect preoperatively.¹ We report a case of Wilms tumor with teratomatous cysts in the isthmus of a horseshoe kidney.

CASE REPORT

A 6-month-old female infant, born at term after assisted conception, presented because the parents noticed an abdominal mass. The patient weighed 6,830 gm. Physical examination demonstrated a 7 to 8 cm. mobile painless mass in the upper and left abdomen but no other abnormalities. Serum blood urea nitrogen and creatinine were normal, hemoglobin was 7.1 mmol/l. (normal 7.5 to 10) and urinary sediment had 5 to 10 leukocytes per high power field. Ultrasound of the abdomen revealed a large 9 × 5 cm. cystic process just above the umbilical region that contained debris and appeared to have a thickened wall (fig. 1). Moreover, on both sides there was slight dilatation of the renal pelvis with normal appearing parenchyma. No signs of a horseshoe kidney were seen. A mesenteric cyst was suspected.

Laparotomy was performed and a large cystic process was found. Due to suspicion of decompensated hydronephrosis in a horseshoe kidney, a pigtail drain was placed. Postoperatively computerized tomography (CT) showed a partial solid 7 × 6 cm. tumor in the isthmus of a horseshoe kidney and 1 ureter on each side (fig. 2). Wilms tumor was suspected. Considering patient age, open surgery was performed to obtain a biopsy from the cystic and more solid part of the tumor and, thus, confirm the diagnosis.

Histological examination revealed a Wilms tumor with intermediate grade histology and cysts containing teratomatous components with mucous epithelium. A drain was placed into the cystic part of the tumor to drain mucus (5 to 15 cc/24 hours). Chemotherapy with 10 µg/kg. actinomycin, 1 mg/m.² vincristine and 30 mg/m.² epirubicin was complicated by veno-occlusive disease. Thus, actinomycin was replaced with carboplatin and etoposide. CT 3 months after the start of chemotherapy showed almost no decrease in tumor size.

Laparotomy was performed again. Residual tumor in the isthmus and the drain fistula were resected. The caliceal system was closed on both sides and the renal parenchyma was approximated, leaving well vascularized parenchyma on both sides in the divided kidneys, which were fixed to the abdominal wall. The lower pole of the left kidney was sacrificed but there was no sign of urinary leakage.

Histopathological evaluation of the tumor showed differentiated intermediate grade histology with primitive glomeruli and tubuli, and less than 10% vital blastema. Most of the resected tumor comprised cystic structures with colonic and urothelial epithelium as teratomatous components. Two ad-

Accepted for publication October 11, 1996.

* Requests for reprints: Department of Urology, University Hospital, P. O. Box 9101, 6500 HB Nijmegen, The Netherlands.

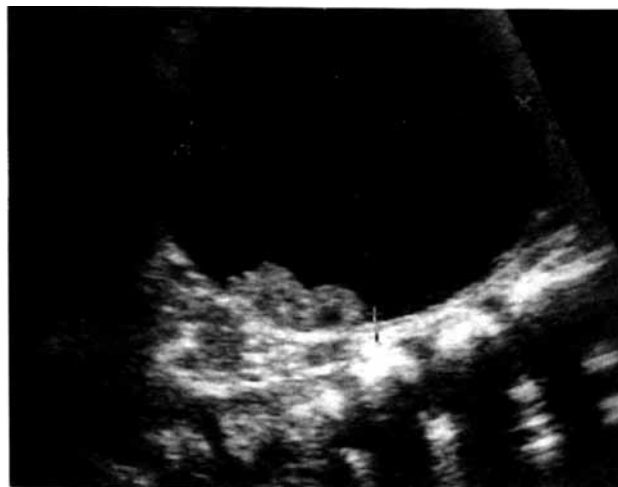

FIG. 1. Preoperatively ultrasound shows cystic abdominal lesion mistakenly diagnosed as mesenteric cyst.

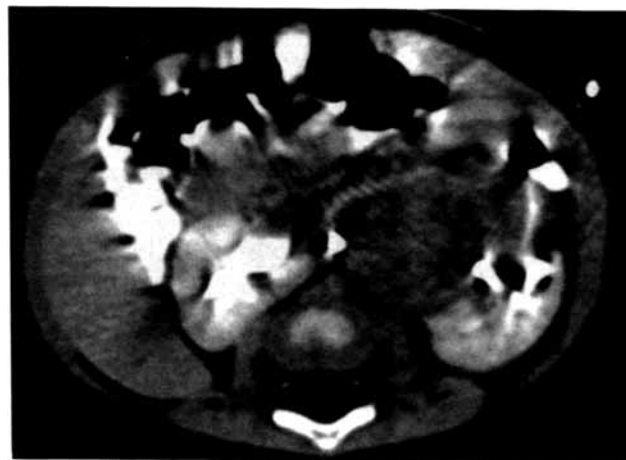


FIG. 2. Postoperatively CT reveals tumor in isthmus of horseshoe kidney and drain in cystic part of tumor.

ditional courses of chemotherapy were given and the patient is currently doing well 11 months after the initial diagnosis.

DISCUSSION

In approximately half of the patients with a Wilms tumor in a horseshoe kidney the correct diagnosis is reportedly missed preoperatively.¹ In our case cystic Wilms tumor was mistakenly judged to be a mesenteric cyst on preoperative ultrasonography. Even intraoperatively the large cystic process was not recognizable as a Wilms tumor and it was drained due to suspicion of pyelonephrosis.

The differential diagnosis of a cystic lesion in the retroperitoneal region in and around the kidney is extensive. Ugarte et al reported on 24 patients less than 1 year old with Wilms tumors, including 3 (12%) with partial cystic morphology.³ Cystic Wilms tumor should be differentiated from cystic nephroma and cystic, partially differentiated nephroblastoma, since the latter 2 lesions are rarely aggressive. On the other hand, several other renal diseases in childhood may involve cystic growth and require different treatments, such as clear cell sarcoma, mesoblastic nephroma, renal cell carcinoma and dysplastic kidney.

Since initial surgery was performed transperitoneally, intra-abdominal tumor cell spillage was assumed. Consequently after the primary operation the tumor was stage III. Thus, an additional biopsy procedure would not change tumor stage and anthracyclines should be used in the chemotherapy regimen. Fernandez et al previously described the rare event of teratomatous components in a Wilms tumor.⁴ These tumors were reported to respond poorly to chemotherapeutic regimens, as in our case.

Location in the horseshoe kidney and cystic growth hampered the correct diagnosis. Although it is known that patients with a horseshoe kidney are at risk for Wilms tumor, the correct preoperative diagnosis is often difficult.¹ Especially when the tumor is located at the isthmus of the kidney,

pelvic deformation is often lacking and the isthmus may not be recognized as such due to abundant tumor.² In our case the medial position of the cystic process with normal appearing renal parenchyma and pelvis on both sides impeded a correct ultrasonographic diagnosis. Preoperative CT would have been more suitable for detecting the horseshoe kidney and solid lesion. In conclusion, our case demonstrates that preoperative CT should be performed when there is an abdominal cystic lesion, particularly when ultrasound does not provide clear information on the kidneys and adjacent organs.

REFERENCES

1. Mesrobian, H.-G. J., Kelalis, P. P., Hrabovsky, E., Othersen, H. B., Jr., deLorimier, A. and Nesmith, B.: Wilms tumor in horseshoe kidneys: a report from the National Wilms Tumor Study. *J. Urol.*, **133**: 1002, 1985.
2. Gay, B. B., Jr., Dawes, R. K., Atkinson, G. O., Jr. and Ball, T. I.: Wilms tumor in horseshoe kidney: radiologic diagnosis. *Radiology*, **146**: 693, 1993.
3. Ugarte, N., Gonzalez-Crussi, F. and Hsueh, W.: Wilms' tumor: its morphology in patients under one year of age. *Cancer*, **48**: 346, 1981.
4. Fernandez, E. T., Parham, D. M., Ribeiro, R. C., Douglass, E. C., Kumar, A. P. and Wilimas, J.: Teratoid Wilms' tumor: the St Jude experience. *J. Ped. Surg.*, **23**: 1131, 1988.