

## Decreased Staining of Heparan Sulfate in Non-lesional Skin of a Subgroup of Patients with Systemic Lupus Erythematosus

M. M. B. SEYGER<sup>1</sup>, M. C. J. VAN BRUGGEN<sup>2</sup>, H. K. HARDEMAN<sup>1</sup>, F. H. J. VAN DEN HOOGEN<sup>3</sup>,  
J. H. M. BERDEN<sup>2</sup>, J. VAN DEN BORN<sup>2</sup> and E. M. G. J. DE JONG<sup>1</sup>

<sup>1</sup>Department of Dermatology and Department of Medicine, Divisions of <sup>2</sup>Nephrology and <sup>3</sup>Rheumatology, University Hospital Nijmegen, Nijmegen, The Netherlands

**Heparan sulfate proteoglycans (HSPGs) are components of the basement membrane of various tissues. They are composed of a core protein and of the negatively charged glycosaminoglycan side chain heparan sulfate, which is covalently bound to the core protein. We previously found that in both human and murine lupus nephritis, heparan sulfate staining in the basement membrane of the glomerulus is almost completely absent, and that there was an inverse correlation between heparan sulfate staining and glomerular immunoglobulin deposits.**

As immunoglobulin deposits are also present in the skin of systemic lupus erythematosus patients, we investigated the heparan sulfate staining pattern in the basement membrane of the dermal–epidermal junction. Furthermore, we studied whether there was a correlation between heparan sulfate staining and deposition of immunoglobulin in the basement membrane of this junction, and between heparan sulfate staining and the presence of anti-DNA antibodies in the serum.

Biopsies of non-lesional skin of 21 systemic lupus erythematosus patients (15 anti-DNA positive and 6 anti-DNA negative patients at the time of biopsy) were stained for the HSPG-core protein (mAb JM-72), highly sulfated stretches within heparan sulfate (JM-13), the low sulfated regions of heparan sulfate (mAb JM-403) and for immunoglobulin depositions.

Abnormal and discontinuous staining of the low sulfated parts of heparan sulfate using mAb JM-403 in the basement membrane was found in skin biopsies of 4 out of 15 systemic lupus erythematosus patients with anti-DNA antibodies. In contrast, all specimens of anti-DNA negative patients showed normal continuous staining. Staining with JM-13 and JM-72 showed normal linear staining in both groups. The decreased heparan sulfate staining was correlated significantly with the presence of immunoglobulin deposits in the basement membrane. The subgroup could not be identified by its clinical picture. Our results suggest similar but not identical pathways in systemic lupus erythematosus nephritis and skin of systemic lupus erythematosus patients. *Key words: anti-DNA antibodies; basement membrane; dermal epidermal junction; immunoglobulin; lupus nephritis.*

(Accepted March 16, 1998.)

Acta Derm Venereol (Stockh) 1998; 78: 326–330.

M. M. B. Seyger, Department of Dermatology, University Hospital Nijmegen, P.O. Box 9101, NL-6500 HB Nijmegen, The Netherlands.

Systemic lupus erythematosus (SLE) is an autoimmune disease that may effect any organ. Frequent clinical findings are glomer-

ulonephritis, vasculitis and skin lesions (1). The disease is characterized by the occurrence of antibodies directed at a variety of auto-antigens. Of these auto-antibodies, anti-nuclear antibodies predominate, and anti-dsDNA antibodies are regarded as particularly important mediators in the pathogenesis of the tissue lesions, especially glomerulonephritis. In lupus nephritis, anti-DNA titres correlate with disease activity and anti-DNA antibodies can be eluted from glomeruli (2).

Anti-DNA antibodies, which are complexed to nucleosomal antigens (DNA/histone), are able to bind to heparan sulfate (HS) in the glomerular basement membrane (GBM) (3, 4). HS is the negatively-charged glycosaminoglycan side chain of HS proteoglycan, present in the basement membrane (BM) of the kidneys (GBM), blood vessels and skin.

In both human (5) and murine (6) lupus nephritis, HS staining in the GBM is almost completely absent. This decrease in staining correlates with the presence of immunoglobulin deposits in the GBM. Together with the finding that the amount of HS was unchanged, this suggested that HS is masked by nucleosome complexed anti-nuclear (anti-DNA) antibodies (6). Indeed, in kidney biopsies of SLE patients with nephritis, an inverse correlation was found between HS staining and histone deposition (7). In addition to the involvement of anti-DNA antibodies in the development of lupus nephritis, they are also thought to be important for the evolution of skin lesions in SLE patients (1).

In this study, we first analysed the HS staining in the BM of the dermal–epidermal junction of non-lesional, light-protected skin in SLE patients. Because immunofluorescence of non-lesional skin in SLE patients shows the same deposits of immunoglobulins (8) as in lesional skin, and because lesional skin of SLE patients shows great clinical and histological variability, we chose to investigate specimens from non-lesional skin. As light-exposed areas can show false positive deposits (9), biopsies were taken from non-lesional, light-protected areas. Three monoclonal antibodies were used and directed against different parts of the HS proteoglycan molecule. Secondly, we investigated whether there was a correlation between HS staining and deposition of immunoglobulin in the BM of the dermal–epidermal junction. To further investigate the influence of immunoglobulin deposits on the BM zone, the epidermal and dermal layers adjacent to the BM were studied. Therefore, the basal layer of the epidermis was stained using the monoclonal antibody (mAb) MIB-1, a marker for proliferation. The high papillary dermis was studied by staining the dermal glycoprotein tenascin, expression of which is known to be increased in slight disturbances of the BM zone (10). Furthermore, we analysed whether there was a correlation between HS staining and the presence of anti-DNA antibodies in the circulation.

Table I. Clinical characteristics of SLE patients

Patient n	Sex/Age	Duration of disease (years)	Anti-ds DNA (kU/l) <sup>a</sup>	Urinary protein (g/24 h) <sup>a</sup>	Discontinuous HS staining	ARA criteria <sup>b</sup>										
						1	2	3	4	5	6	7	8	9	10	11
1	F/29	6	139	–						+		+			+	+
3	F/69	21	56	–	+				+		+	+		+	+	+
4	M/40	8	91	–					+		+				+	+
5	F/25	9	20	0.4	+				+	+	+			+	+	+
6	F/34	7	77	–	+						+			+	+	+
7	F/71	18	31	1.1					+		+			+	+	+
9	M/50	16	59	–					+				+		+	+
12	F/50	12	64	–							+				+	+
13	F/43	31	20	–					+	+	+			+	+	+
14	F/23	5	37	–						+	+			+	+	+
15	F/40	10	78	–	+				+		+	+			+	+
17	F/15	0.5	225	–					+		+				+	+
19	F/27	13	331	0.3					+				+	+	+	+
20	F/47	10	454	–						+			+		+	+
21	F/33	7	250	–					+	+	+	+		+	+	+
2	F/32	8	0	–					+		+				+	+
8	M/44	8	0	2.3					+		+	+			+	+
10	M/67	8	0	1					+	+	+				+	+
11	F/31	2	0	–					+	+	+			+		+
16	F/48	28	0	–					+	+				+	+	+
18	F/22	6	0	1					+				+	+	+	+

<sup>a</sup> At time of biopsy.

<sup>b</sup> Numbers 1–11 correspond to numbers given in ARA classification criteria: 1 = Malar rash, 2 = Discoid rash, 3 = Photosensitivity, 4 = Oral ulcers, 5 = Arthritis, 6 = Serositis, 7 = Renal disorder, 8 = Neurologic disorder, 9 = Haematologic disorder, 10 = Immunologic disorder, 11 = Antinuclear antibody. HS = heparan sulfate.

## MATERIALS AND METHODS

### Patients and biopsies

Twenty-one patients with SLE participated in this study. Anti-DNA antibodies were detected in the serum of all patients at least once during their disease. They all fulfilled the American Rheumatism Association revised 1982 criteria for SLE (11) and gave their informed consent. After local anaesthesia, a 4-mm punch biopsy was taken from the non-lesional skin of the abdomen, which, in all cases, was not exposed to sunlight. Normal skin was taken as control.

The biopsies were washed in phosphate-buffered saline (PBS) (NPBI, Emmer-Compascuum, The Netherlands), embedded in Tissue Tek OCT compound (Miles Scientific, Naperville, USA), snap frozen in liquid nitrogen and stored at  $-80^{\circ}\text{C}$ . They were sectioned at 6 mm and fixed for 10 min in acetone/ether (60/40 vol.%) for MIB-1, or in acetone ( $0^{\circ}\text{C}$ ) for staining with the other antibodies, and again stored at  $-80^{\circ}\text{C}$  until use. At the time of biopsy, blood was taken to determine the amount of anti-dsDNA antibodies in the serum. Anti-dsDNA levels were determined by  $^{125}\text{I}$  Farr assay (anti-dsDNA kit IM77, Amersham International).

### Antibodies

For immunohistochemical staining of HS proteoglycan, three mouse monoclonal antibodies were used: mAb JM-403 (12–14), mAb JM-13 (15) and mAb JM-72 (14). The antibody JM-403 is directed against unmodified/low sulfated domains of the HS side chains, JM-13 against the sulfated domains of the HS side chains and JM-72 against the core protein of BM-associated HS proteoglycan core protein. For the staining of immunoglobulin deposits at the dermal–epidermal junction, FITC-labelled rabbit anti-human immunoglobulin was used (DAKO, Copenhagen, Denmark). For immunohistochemical staining of tenascin, the monoclonal antibody T2H5 was used (10) (kindly provided by Dr. A. A. Verstraten, The Netherlands Cancer Institute, Amsterdam, The Netherlands). The monoclonal antibody MIB-1, which detects

the nuclear antigen Ki-67 present in the late G<sub>1</sub>, S and G<sub>2</sub> + M phases of the cell cycle, was used as a marker for proliferation (Immunotech, Marseilles, France).

### Immunohistochemical staining

For staining with the antibodies JM-403 (1:250), JM-72 (1:250 in PBS), T2H5 (1:2000) and MIB-1 (1:50), an indirect peroxidase technique was used. After thawing at room temperature for 30 min, sections were fixed again in acetone ( $0^{\circ}\text{C}$ ), or in acetone/ether (60/40 vol.%) for MIB staining, for 10 min. They were washed in PBS and incubated for 1 h with the primary antibody. After being washed twice in PBS, the slides were incubated for 30 min with a solution of peroxidase conjugated rabbit anti-mouse immunoglobulins 1:50 (DAKO-PATTS, Copenhagen, Denmark) in phosphate buffer containing 5% human AB serum. After two further washes in PBS, slides were stained in a solution of 3-amino-9-ethyl-carbazole (AEC) in sodium acetate buffer containing 0.01% H<sub>2</sub>O<sub>2</sub> for 10 min.

Staining with the antibody JM-13 was carried out using the vectastain elite ABC kit (Vector Laboratories, Burlingame, USA). Sections were preincubated for 20 min with 20% normal horse serum, and after removal of excess serum, sections were incubated with an undiluted hybridoma culture supernatant for 60 min. After two washing steps, sections were incubated for 30 min with a solution of horse anti-mouse immunoglobulins, diluted 1:200 in PBS containing 1% bovine serum albumin (BSA). This was followed by a washing step and incubation with Vectastain elite ABC Reagent for 30 min. After two further washes in PBS, slides were stained in a solution of 3-amino-9-ethyl-carbazole (AEC) in sodium acetate buffer containing 0.01% H<sub>2</sub>O<sub>2</sub> for 10 min. All slides were counterstained with Mayer's haematoxylin (Sigma, St. Louis, MO, USA) mounted in glycerine gelatine (Sigma, St. Louis, MO, USA) and studied by light microscopy.

A direct immunofluorescence method was used for staining of immunoglobulins. Slides were incubated with FITC-labelled rabbit anti-human Ig (DAKO, Denmark) diluted in 1:100 PBS containing 1%

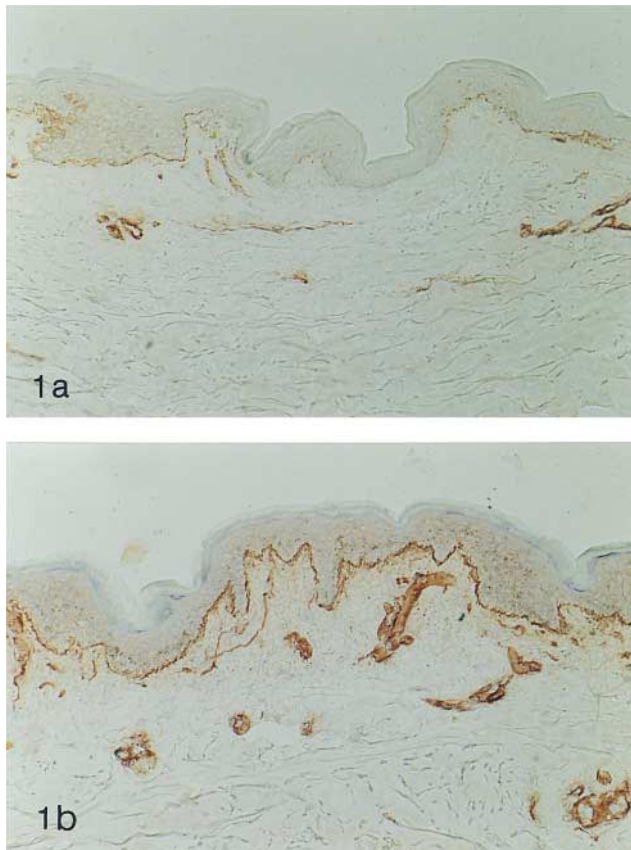


Fig. 1. Immunohistochemical detection of HS side chains by mAb JM-403. (a) Discontinuous staining in patients with anti-ds-DNA antibodies (200 $\times$ ). (b) Continuous staining (200 $\times$ ).

(w/v) BSA for 1 h at room temperature. Slides were embedded in Aquamount (BDH Ltd., Poole, UK) and examined with a Zeiss fluorescence microscope.

#### Histological examination

Coded sections were examined by three independent investigators. The intensity of the fluorescence staining in the dermal-epidermal junction was scored semiquantitatively on a scale of 0-3. The scale was defined as follows: 0=no staining at all, 1=mild staining of the dermal-epidermal junction, 2=moderate staining and 3=strong staining. Staining of HS proteoglycan with the various antibodies JM-403, JM-13 and JM-72 in the BM of the dermal-epidermal junction and BM of blood vessels was graded using a 0-2 scale: 0=staining not present, 1=discontinuous staining, 2=continuous staining. Tenascin expression of the dermis was assessed using an 8-point scale: 0=no staining, 1=sporadic staining in the upper dermis adjacent to the BM of the dermal-epidermal junction, 2=a patchy distribution in the upper dermis adjacent to the BM, but not present in all dermal papillae, 3=a patchy expression in the tips of *all* dermal papillae, but not continuous, 4=3 but extended deeper into the dermis, 5=a thin but continuous layer adjacent to BM, 6=a continuous layer, adjacent to BM and in the papillary dermis, 7=staining extended in the reticular dermis. Epidermal proliferation was measured by counting the number of MIB-1-positive nuclei per mm length of section. All methods of assessment have been published before (16, 17).

#### Statistical analysis

In linear regression analysis, the Spearman correlation was used. The level of significance was  $p \leq 0.05$ . For statistical analysis, the Mann-Whitney U-test was used.

## RESULTS

The clinical characteristics of the 21 SLE patients (4 men and 17 women) from whom the skin biopsies were evaluated are listed in Table I. The duration of the disease ranged from 0.5-31 years (mean 11.1 years). Although all patients had serum anti-DNA antibodies at some point during their disease, at the time of biopsy, only 15 out of the 21 patients had positive titres. Therefore, the patients were divided into two groups: those with anti-DNA antibodies at time of biopsy ( $n=15$ ), and patients with no detectable anti-DNA antibodies at evaluation ( $n=6$ ).

#### HS proteoglycan staining

Staining with the mAb JM-403, directed against the low sulfated domains of the HS side chain of HS proteoglycan, showed a discontinuous pattern in 4 out of 15 biopsies of patients with anti-DNA antibodies (Fig. 1a). The other 9 specimens of the anti-DNA positive group showed continuous, linear staining restricted to the BM of skin and blood vessels (Fig. 1b). All biopsies from the anti-DNA negative group ( $n=6$ ) displayed strong, continuous staining.

Staining with JM-13, directed against the high sulfated HS side chains of the HS proteoglycans, and with JM-72, directed against the core protein of HS proteoglycan, was positive in all specimens. Both in the anti-DNA positive and negative patients, staining was continuous and restricted to the BM of the dermal-epidermal junction (JM-72 and JM-13) and blood vessels (JM-72). In normal skin, studied extensively in previous studies (16, 17), we never found a discontinuous staining pattern with any of the three mAbs directed against HS proteoglycan (JM-403, JM-13, JM-72); they all showed strong and continuous staining of the BM.

#### Immunoglobulin staining

For the patients with positive anti-DNA antibodies, in 6 out of 15 specimens, immunoglobulin depositions were found at the dermal-epidermal junction. In 2 specimens, this staining was mild, in 1 biopsy staining was moderate and in 3 biopsies a strong fluorescence was observed (Fig. 2). No immunoglobulin depositions were found in biopsies from patients without anti-DNA antibodies. The 4 specimens with discontinuous JM-403 staining had immunoglobulin depositions at the dermal-epidermal junction, except the one from patient no. 6. The subgroups identified by this procedure had no specific clinical picture.

#### Tenascin and MIB expression

In both the anti-DNA positive and negative groups, the tenascin expression was distributed discontinuously, varying from sporadic to patchy. In two specimens, a thin but continuous staining adjacent to the BM was found. This distribution pattern is comparable to the pattern of tenascin found in normal human skin (17). The mean number of MIB-positive nuclei per mm length of section was  $12.2 \pm 1.2$  (SEM), which is within the range of MIB distribution for normal human skin.

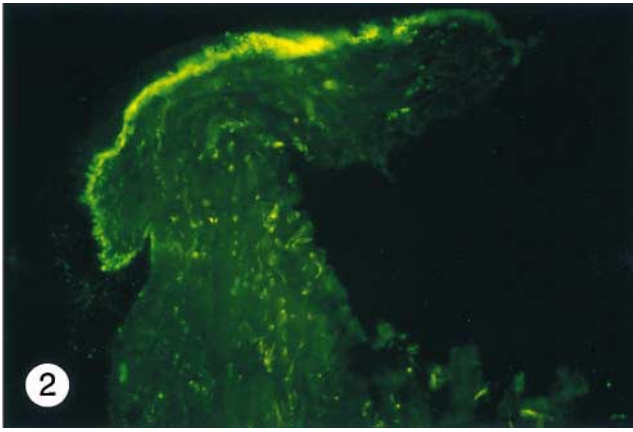


Fig. 2. Direct immunofluorescence of Ig deposition at the dermal–epidermal junction in the biopsy of a patient with anti-DNA antibodies (250 ×).

### Correlations

An inverse correlation was found between JM-403 staining and the presence of immunoglobulins in the BM of the dermal–epidermal junction ( $r_s = -0.466$ ,  $p < 0.04$ ). However, no correlation was found between the presence of serum anti-DNA antibodies and JM-403 staining, nor between the presence of serum anti-DNA antibodies and immunoglobulin deposits. No correlations were found between JM-403 staining and tenascin or MIB staining. The presence of immunoglobulin deposits was correlated with many clinical parameters (e.g. nephritis, urinary protein, arthritis), but no significant correlations could be found.

### DISCUSSION

In this study, we investigated HS proteoglycan and HS staining intensity in the BM zone in skin biopsies taken from SLE patients and its relation to the presence of circulating anti-DNA antibodies. In a subgroup of patients with anti-DNA antibodies (4 out of 15 biopsies), an abnormal, discontinuous staining of HS, as assessed by JM-403, was found. This pattern differs from that seen in the biopsies taken from patients without anti-DNA antibodies, where all biopsies showed a normal, continuous linear staining of JM-403. A positive correlation between the presence of immunoglobulin depositions and discontinuous JM-403 staining was found. This correlation could be due to masking of the JM-403 epitope by immunoglobulins, as demonstrated in kidney biopsies from SLE patients (6). In the GBM, the binding of anti-nuclear antibodies to HS is mediated via bound complexes containing both DNA and histones (i.e. nucleosomes) (3, 4). In addition, the presence of nucleosomes and histones was demonstrated in glomerular deposits, and their presence was correlated with a loss of HS staining in the GBM (7). It is unclear whether the JM-403 epitope in the BM of the skin is also blocked by nucleosome anti-nuclear antibody complexes. To further investigate this possibility, we stained for nucleosomes and histones using nucleosome-specific monoclonal antibody #34 and the polyclonal rabbit antihistone antiserum, as described previously (7). We were unable to detect nucleosomes or histones in the BMZ, although in the

skin biopsies, this analysis was hampered by a high background staining.

Several studies have indicated a significant correlation between cutaneous immunoglobulin deposition and the presence of anti-DNA antibodies (18, 19). In addition, anti-nuclear activity has been found with antibodies eluted from the skin of SLE patients (20). Another study suggested that serum anti-DNA antibodies could bind to dsDNA released locally from epidermal nuclear breakdown (21). It was thus concluded by Furukawa et al. that anti-DNA containing complexes may be one of the causes of immunoglobulin deposition at the dermal–epidermal junction (22). Based on these facts, it is striking that only 6 of the 15 patients with serum anti-DNA showed immunoglobulin depositions at the dermal–epidermal junction. On the other hand, we found no immunoglobulin depositions in SLE patients without serum anti-DNA antibodies. The presence of immunoglobulins did not have any influence on the expression of MIB-1, a marker for proliferation, nor on tenascin, a dermal glycoprotein, present adjacent to the BM. Recently, we have found that reactive oxygen species are able to depolymerize HS at least *in vitro* and in the GBM (23). That this mechanism is also operative in non-lesional skin of SLE patients is unlikely, since we found no signs of inflammation in any of the skin specimens.

In conclusion, a decreased HS staining was observed in the non-lesional skin of a subgroup of SLE patients. This decreased staining correlated with the presence of immunoglobulin deposits in the dermal–epidermal junction. This is in line with our previous studies on kidney biopsies (6), which makes it likely that similar mechanisms, i.e. masking of HS by immunoglobulin deposits, are at work in the skin and kidneys of SLE patients.

### ACKNOWLEDGEMENTS

Dr. M. van Bruggen is supported by a grant from the Dutch Kidney Foundation (C 95.1513) and Dr. J. van den Born by a grant from the NWO Dutch Diabetes Fund.

### REFERENCES

1. Aiba S, Yoshie O, Tomita Y, Tagami H. Cross-reactivity of murine monoclonal anti-DNA antibodies with human and murine skin: a possible pathogenetic role in skin lesions of lupus erythematosus. *J Invest Dermatol* 1989; 93: 739–745.
2. Tax WJ, Kramers C, van Bruggen MC, Berden JHM. Apoptosis, nucleosomes, and nephritis in systemic lupus erythematosus [editorial]. *Kidney Int* 1995; 48: 666–673.
3. Termaat RM, Brinkman K, van Gompel F, van den Heuvel LP, Veerkamp JH, Smeenk-RJ, et al. Cross-reactivity of monoclonal anti-DNA antibodies with heparan sulfate is mediated via bound DNA/histone complexes. *J Autoimmun* 1990; 3: 531–545.
4. Kramers C, Hylkema MN, van Bruggen MC, van de Lagemaat R, Dijkman HB, Assmann KJ, et al. Anti-nucleosome antibodies complexed to nucleosomal antigens show anti-DNA reactivity and bind to rat glomerular basement membrane *in vivo*. *J Clin Invest* 1994; 94: 568–577.
5. van den Born J, van den Heuvel LP, Bakker MA, Veerkamp JH, Assmann KJ, Weening-JJ, et al. Distribution of GBM heparan sulfate proteoglycan core protein and side chains in human glomerular diseases. *Kidney Int* 1993; 43: 454–463.
6. van Bruggen MC, Kramers K, Hylkema MN, van den Born J, Bakker MA, Assmann KJ, et al. Decrease of heparan sulfate stain-

- ing in the glomerular basement membrane in murine lupus nephritis. *Am J Pathol* 1995; 146: 753–763.
7. van Bruggen MCJ, Kramers C, Walgreen B, Elema JD, Kallenberg CGM, van den Born J, et al. Nucleosomes and histones are present in glomerular deposits in human lupus nephritis. *Nephrol Dial Transplant* 1997; 12: 57–66.
  8. Brown MM, Yount WJ. Skin immunopathology in system lupus erythematosus. *JAMA* 1980; 243: 38–42.
  9. Baart de la Faille Kuyp, Cormane RH. The occurrence of certain serum factors in the dermal–epidermal junction and vessel walls of the skin in lupus erythematosus and other (skin) diseases. *Acta Derm Venereol (Stockh)* 1968; 48: 578–588.
  10. Schalkwijk J, van Vlijmen I, Oosterling B, Perret C, Koopman R, van den Born J, et al. Tenascin expression in hyperproliferative skin diseases. *Br J Dermatol* 1991; 124: 13–20.
  11. Tan EM, Cohen AS, Fries JF, Masi AT, McShane DJ, Rothfield NF, et al. The 1982 revised criteria for the classification of systemic lupus erythematosus. *Arthritis Rheum* 1982; 25: 1271–1277.
  12. van den Born J, Gunnarsson K, Bakker MA, Kjellen L, Kusche Gullberg M, MacCarana M, et al. Presence of N-unsubstituted glucosamine units in native heparan sulfate revealed by a monoclonal antibody. *J Biol Chem* 1995; 270: 31303–31309.
  13. van den Born J, van den Heuvel LP, Bakker MA, Veerkamp JH, Assmann KJ, Berden JH. A monoclonal antibody against GBM heparan sulfate induces an acute selective proteinuria in rats. *Kidney Int* 1992; 41: 115–123.
  14. van den Born J, van den Heuvel LP, Bakker MA, Veerkamp JH, Assmann KJ, Berden JH. Monoclonal antibodies against the protein core and glycosaminoglycan side chain of glomerular basement membrane heparan sulfate proteoglycan: characterization and immunohistological application in human tissues. *J Histochem Cytochem* 1994; 42: 89–102.
  15. van den Born J, van den Heuvel LP, Bakker MA, Veerkamp JH, Assmann KJ, Berden JH. Production and characterization of a monoclonal antibody against human glomerular heparan sulfate. *Lab Invest* 1991; 65: 287–297.
  16. Seyger MMB, van den Born J, Schalkwijk J, van de Kerkhof PCM, de Jong EMGJ. Altered distribution of heparan sulfate proteoglycans in psoriasis. *Acta Derm Venereol (Stockh)* 1997; 77: 105–109.
  17. Seyger MMB, van Pelt JPA, van den Born J, Latijnhouwers MA, de Jong EMGJ. Epicutaneous application of leukotriene B4 induces patterns of tenascin and a heparan sulfate proteoglycan epitope that are typical for psoriatic lesions. *Arch Dermatol Res* 1997; 289: 331–336.
  18. Provost TT, Andres G, Maddison PJ, Reichlin M. Lupus band test in untreated SLE patients: correlation of immunoglobulin deposition in the skin of the extensor forearm with clinical renal disease and serological abnormalities. *J Invest Dermatol* 1980; 74: 407–412.
  19. Sontheimer RD, Gilliam JN. A reappraisal of the relationship between subepidermal immunoglobulin deposits and DNA antibodies in systemic lupus erythematosus: a study using the Crithidia luciliae immunofluorescence anti-DNA assay. *J Invest Dermatol* 1979; 72: 29–32.
  20. Landry M, Sams WM Jr. Basement-membrane antibodies in two patients with systemic lupus erythematosus. *Lancet* 1972; 1: 821–822.
  21. Gilliam JN. The significance of cutaneous immunoglobulin deposits in lupus erythematosus and NZB/NZW F1 hybrid mice. *J Invest Dermatol* 1975; 65: 154–161.
  22. Furukawa F, Ohshio G, Imamura S. Pathogenesis of lupus dermatoses in autoimmune mice. XIX. Attempts to induce subepidermal immunoglobulin deposition in MRL/Mp- +/+ mice. *Arch Dermatol Res* 1993; 285: 20–26.
  23. Raats CJ, Bakker MA, van den Born J, Berden JH. Hydroxyl radicals depolymerize glomerular heparan sulfate in vitro and in experimental nephrotic syndrome. *J Biol Chem* 1997; 272: 26734–26741.