




ELSEVIER

Contents lists available at ScienceDirect

Medical Mycology Case Reports

journal homepage: www.elsevier.com/locate/mmcr

Screening of the central nervous system in children with invasive pulmonary aspergillosis



Emmi Broenen^a, Annelies Mavinkurve-Groothuis^a, Karin Kamphuis-van Ulzen^b, Roger Brüggemann^{c,e}, Paul Verweij^{d,e}, Adilia Warris^{a,e,*}

^a Department of Pediatrics, Radboud University Nijmegen Medical Center, P.O. Box 9101, 6500 HB Nijmegen, The Netherlands

^b Department of Radiology, Radboud University Nijmegen Medical Center, P.O. Box 9101, 6500 HB Nijmegen, The Netherlands

^c Department of Clinical Pharmacy, Radboud University Nijmegen Medical Center, P.O. Box 9101, 6500 HB Nijmegen, The Netherlands

^d Department of Medical Microbiology, Radboud University Nijmegen Medical Center, P.O. Box 9101, 6500 HB Nijmegen, The Netherlands

^e Nijmegen Institute for Infection, Immunity and Inflammation, Radboud University Nijmegen Medical Center, P.O. Box 9101, 6500 HB Nijmegen, The Netherlands

ARTICLE INFO

Article history:

Received 10 January 2014

Received in revised form

31 January 2014

Accepted 3 February 2014

Keywords:

Aspergillosis

Central nervous system

Therapeutic drug monitoring

Screening

Pediatrics

Voriconazole

ABSTRACT

The existing guidelines regarding the management of invasive pulmonary aspergillosis do not recommend screening of the extra-pulmonary sites. Due to the fact that the presence of central nervous system (CNS) aspergillosis will influence treatment decisions regarding which antifungal to use and the aimed target concentrations of azoles in plasma, to be informed about dissemination of the infection to the CNS is absolutely necessary. We demonstrate the need for a structured approach to screening of pediatric patients for CNS aspergillosis.

© 2014 The Authors. International Society for Human and Animal Mycology. Published by Elsevier B.V.

Open access under [CC BY-NC-SA license](http://creativecommons.org/licenses/by-nc-sa/4.0/).

1. Introduction

Children with hematological malignancies are at high risk for developing invasive pulmonary aspergillosis (IPA) with a high mortality rate [1–3], despite their currently good prognosis of the underlying malignancy. The most frequent extra-pulmonary site in children is the central nervous system (CNS) [4]. Central nervous system involvement is reported in a frequency of 9–39% with exceeding mortality rates of 88% and higher [3,4]. Voriconazole is the mainstay of systemic treatment for cerebral aspergillosis due to its good penetration into the central nervous system. This drug has substantially reduced the mortality rate to 65% [5].

To our knowledge, the existing guidelines regarding the management of persistent febrile neutropenia or invasive aspergillosis [6–8] do not recommend screening of the extra-pulmonary sites in the absence of localized signs and symptoms and/or in those situations where a proven or probable IPA [9] has been diagnosed.

Due to the fact that the presence of CNS aspergillosis will influence treatment decisions regarding which antifungal to use and the aimed target concentrations of azoles in plasma, to be informed about dissemination of the infection to the CNS is absolutely necessary. We demonstrate the need for a structured approach to screening of pediatric patients for CNS aspergillosis by using two clinical cases to exemplify this. Next we discuss the possible indications when to perform this diagnostic work-up.

2. Case

2.1. Case 1

An 8-year-old boy presented with an episode of febrile neutropenia during his treatment for High Risk Acute Lymphoblastic Leukemia (HR-ALL). Broad spectrum antibiotics were started and galactomannan (GM) screening was performed according to our local protocols (e.g., twice weekly during neutropenia irrespective of fever). Galactomannan in serum showed an index of 0.6 (negative < 0.5) and suspicion of invasive aspergillosis was risen. Treatment with voriconazole (8 mg/kg/day including loading dose of 12 mg/kg/day) i.v. was started (day 0) and further diagnostic

* Corresponding author. Present address: University of Aberdeen, School of Medicine and Dentistry, Institute of Medical Sciences, Rm 4.23, Foresterhill, Aberdeen AB25 2ZD, Scotland, UK. Tel.: +44 1224437596; fax: +44 1224437506.

E-mail address: a.warris@abdn.ac.uk (A. Warris).

work-up was performed. Culture of the sputum was positive for *Aspergillus fumigatus*. HRCT-thorax revealed five round densities and a cavity forming lesion resembling an air crescent sign, suggestive of invasive pulmonary aspergillosis. Voriconazole treatment was switched (day +4) to oral formulation (200 mg twice a day) due to a satisfactory clinical condition and he was discharged on day 5. Two weeks after the boy was discharged from the hospital he presented with fatigue, headache and vomiting (day +19). CT-cerebrum showed two large abscesses causing midline shift (Fig. 1). CNS aspergillosis was suspected and surgical drainage of one abscess was performed. Direct microscopy of the fluid revealed branching hyphae compatible with *Aspergillus* sp., although culture was negative. Ambisome (5 mg/kg/day) was added to the voriconazole treatment (day +22) since we could either be facing an azole-resistant *Aspergillus* sp., or insufficient plasma concentrations resulting in suboptimal cerebral concentrations of voriconazole. PCR analysis targeted at Cyp51A-mediated resistance markers, as described previously [10], was performed using the isolate recovered from sputum and directly on the bronchoalveolar lavage (BAL) sample showing a wild type Cyp51A-gene supporting azole susceptibility. In addition, a presumed adequate intralesional voriconazole concentration of 2.33 mg/L was found. Voriconazole was continued till 3 months after end of chemotherapy (day +477). He fully recovered from his disseminated aspergillosis and is currently in a good clinical condition.

2.2. Case 2

A 2.5-year-old girl, diagnosed with medium risk (MR) ALL, presented with coughing, malaise and febrile neutropenia 1 month after start of chemotherapy. During physical examination of the lungs, bilateral bronchi were noticed. Blood and sputum cultures were taken. Broad spectrum intravenous antibiotics were started according to our local protocol. Four days after presentation, serum GM showed an increased index (GMI) of 6.2. Voriconazole (14 mg/kg/day) i.v. was started immediately (day 0). The next day a HRCT-thorax was performed which showed ground glass aspect areas in both lungs, peribronchial consolidations and a halo sign in the right upper lobe suspect for an invasive fungal infection. A BAL was performed and showed *Aspergillus* sp. by PCR and *A. fumigatus* was cultured. GM index in BAL was 7.4. Susceptibility testing showed an intermediate susceptibility of voriconazole (MIC 2.0 mg/L, determined according EUCAST guideline). Therefore,

trough plasma concentrations of voriconazole were targeted at >3 mg/L keeping in mind the increased chance of toxicity at higher concentrations. Follow-up evaluation (day +21) of the pulmonary abnormalities after 3 weeks of antifungal treatment showed only residual lesions. On day 28 of IV voriconazole treatment the route of administration was switched to oral. Five months later (day +180), while under continued oral voriconazole treatment with varying dosages (based on TDM) the patient was admitted to our hospital with clinical signs of encephalopathy, without focal neurological symptoms, in the presence of a toxic voriconazole plasma concentration of 13.2 mg/L. Voriconazole was immediately ceased for a temporary time period. MRI-cerebrum showed multiple lesions with extensive amounts of edema, especially in the right parietal lobe and the left frontal lobe (Fig. 2). Trepanation of the occipital lesion was performed. The biopsy showed fungal hyphae. Voriconazole level intralesional was 0.6 mg/L, with a plasma concentration of 0.51 mg/L at the time of surgery. *A. fumigatus* (MIC 1 mg/L) was cultured from the cerebrospinal fluid and the GM index was increased (1.4) as well. Since plasma concentrations decreased substantially (as demonstrated in the rapid decline after cessation of voriconazole), antifungal therapy was restarted (day +185) and controlled by intensive TDM. Four months after cessation of the antileukemic treatment, voriconazole treatment was discontinued (day +720). Cerebral and pulmonary imaging show still residual lesions without clinical symptoms.

3. Discussion

We describe two children both presenting with a CNS aspergillosis during treatment for IPA. In our opinion, the dissemination of the IPA to the brain should not be considered as a treatment failure in the presented cases, but infection of the brain most likely has been present at the time IPA was diagnosed. Due to the fact that neurological signs and symptoms were absent, imaging of the brain was not performed initially. In retrospect, the fungal lesions must have been developing during voriconazole treatment for IPA, being an adequate treatment choice, although higher trough concentrations in plasma would have been aimed for. In the latter case we present, the elevated MIC of the *Aspergillus* isolate requires even higher target concentrations and has been complicating optimal treatment. In addition, surgical treatment could have been considered in an earlier stage of disease [11]. This raises the question if earlier screening of the central nervous system

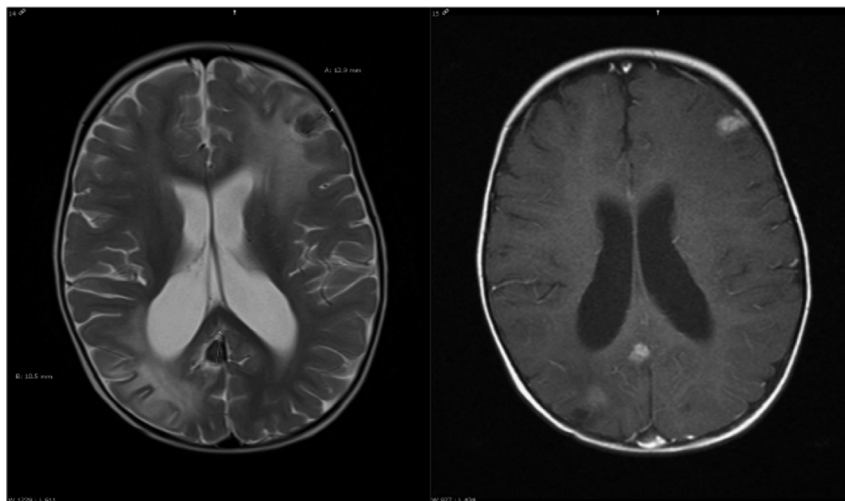


Fig. 1. Patient 1: axial T2 (left) and T1 (right) contrast enhanced MRI-cerebrum show multiple lesions intracerebral at the corticomedullary junction, with low T2 signal with surrounding edema and rim enhancement.

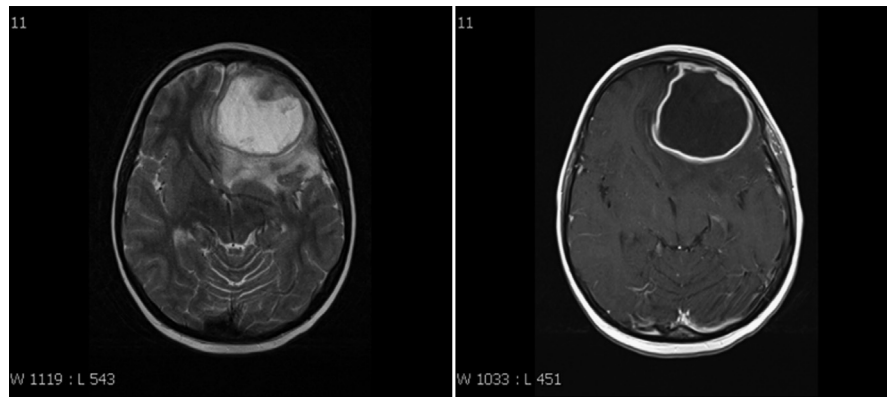


Fig. 2. Patient2: axial T2 (left) weighted image and T2 (right) contrast enhanced MRI-cerebrum show a large lesion with surrounding edema and rim enhancement.

might have led to earlier detection of dissemination of the disease. Consequently, improved and directed treatment options could have been initiated and could have prevented the worsening neurological condition as seen in the presented cases. The incidence of dissemination of IPA to the CNS is not well known. Only one study has analyzed the prevalence of CNS aspergillosis in the presence of IPA in leukemic patients [12]. Of the 100 microbiological proven invasive aspergillosis cases, 14 suffered from CNS aspergillosis as well (incidence of 14%). Ten out of these 14 patients suffered from neurological symptoms being already on antifungal treatment. A dismal outcome was observed, 11 of those 14 patients died (79%) and the diagnosis was confirmed at autopsy. Hagensee et al. showed that 87% of the *Aspergillus* brain abscesses in post-BMT patients were secondary to invasive pulmonary aspergillosis, neurological symptoms developed while on antifungal therapy (amphotericin B) and most cases were diagnosed only at autopsy [13]. Considering the dismal outcome of CNS aspergillosis, the late appearance of clinical symptoms, and the improved therapeutic measurements for cerebral aspergillosis, a structured screening program in case a diagnosis of probable or proven aspergillosis is made, should be strongly considered.

The current guidelines do not make recommendations for screening of the CNS in case of IPA [6–8]. In the clinical practice guidelines for the management of aspergillosis of the Infectious Diseases Society of America (IDSA) it is only mentioned that aggressive diagnostic intervention is needed in patients with documented invasive pulmonary aspergillosis and signs of neurological deficits [7]. In the international pediatric fever and neutropenia guideline, although not specific for the management of invasive aspergillosis, it is mentioned that analysis of GM in CSF might be considered in pediatric patients with a high-risk for invasive fungal disease, and/or targeted imaging of extrapulmonary sites of clinically suspected areas of infection [6]. In our opinion, imaging of the CNS should be performed upon diagnosis of IPA irrespectively of neurological signs and symptoms, due to the fact that they appear late in the course of disease. Although limited evidence shows that GM in CSF can support a diagnosis of probable CNS aspergillosis [14], it is questionable if it is useful as a screening test for CNS aspergillosis.

MRI-cerebrum should be the screening instrument of choice to detect intracranial fungal lesions [8]. The best timing for cerebral screening remains a question. Radiologic images will depend on the immune status. Based on our observations and those from others, screening of the CNS by MRI should be preferably performed after recovery of the neutrophils [15]. Voriconazole, if possible along with surgical drainage, is first choice therapy in CNS aspergillosis [16], but needs to be combined with TDM [17]. Experts have suggested that if the localization of invasive aspergillosis, caused by voriconazole susceptible *Aspergillus* spp, is in

a less accessible area as the brain, higher trough concentrations in plasma of greater than 2 mg/L should be aimed for [18,19]. Efforts should be made to isolate the causative *Aspergillus* sp. from the brain, especially when no isolate has been obtained from the lungs. Azole resistance among *A. fumigatus* is an emerging problem and seems to have a predilection for brain tissue [20,21] urging the need for a mycological diagnosis.

In summary, cerebral aspergillosis has a high mortality rate. Presenting symptoms are often non-specific and become apparent only late in the course of disease which may cause delay in diagnosis associated with a worse outcome. In order to attempt optimal treatment for patients with cerebral aspergillosis, screening patients with proven or probable IPA by MRI of the brain is needed to detect concurrent cerebral aspergillosis before clinical symptoms occurs. Early detection of cerebral aspergillosis will lead to adequate and directed treatment regarding the choice of an antifungal with sufficient CNS penetration including the optimal dose.

Conflict of interest statement

There are none.

References

- [1] Mor M, Gilad G, Kornreich L, Fisher S, Yaniv I, Levy I. Invasive fungal infections in pediatric oncology. *Pediatr Blood Cancer* 2011;56:1092–7.
- [2] Steinbach WJ, Marr KA, Anaissie EJ, Azie N, Quan SP, Meier-Kriesche HU, et al. Clinical epidemiology of 960 patients with invasive aspergillosis from the PATH Alliance registry. *J Infect* 2012;65:453–64.
- [3] Lin SJ, Schranz J, Teutsch SM. Aspergillosis case-fatality rate: systematic review of the literature. *Clin Infect Dis* 2001;32:358–66.
- [4] Abbasi S, Shenep JL, Hughes WT, Flynn PM. Aspergillosis in children with cancer: a 34-year experience. *Clin Infect Dis* 1999;29:1210–9.
- [5] Schwartz S, Ruhnke M, Ribaud P, Corey L, Driscoll T, Cornely OA, et al. Improved outcome in central nervous system aspergillosis, using voriconazole treatment. *Blood* 2005;106:2641–5.
- [6] Lehrnbecher T, Phillips R, Alexander S, Alvaro F, Carlesse F, Fisher B, et al. Guideline for the management of fever and neutropenia in children with cancer and/or undergoing hematopoietic stem-cell transplantation. *J Clin Oncol* 2012;30:4427–38.
- [7] Walsh TJ, Anaissie EJ, Denning DW, Herbrecht R, Kontoyiannis DP, Marr KA, et al. Treatment of aspergillosis: clinical practice guidelines of the Infectious Diseases Society of America. *Clin Infect Dis* 2008;46:327–60.
- [8] Arendrup MC, Bille J, Dannaoui E, Ruhnke M, Heussel C-P, Kibbler C. ECIL-3 classical diagnosis of invasive fungal diseases in patients with leukaemia. *Bone Marrow Transpl* 2012;47:1030–45.
- [9] De Pauw B, Walsh TJ, Donnelly JP, Stevens DA, Edwards JE, Calandra T, et al. Revised definitions of invasive fungal disease from the European Organization for Research and Treatment of Cancer/Invasive Fungal Infections Cooperative Group and the National Institute of Allergy and Infectious Diseases Mycoses Study Group (EORTC/MSG). *Clin Infect Dis* 2008;46:1813–21.
- [10] van der Linden JW, Snelders E, Arends JP, Daenen SM, Melchers WJ, Verweij PE. Rapid diagnosis of azole-resistant aspergillosis by direct PCR using tissue specimens. *J Clin Microbiol* 2010;48:1478–80.

- [11] Burgos A, Zaoutis TE, Dvorak CC, Hoffman JA, Knapp KM, Nania JJ, et al. Pediatric invasive aspergillosis: a multicenter retrospective analysis of 139 contemporary cases. *Pediatrics* 2008;121:e1286–94.
- [12] Pagano L, Ricci P, Montillo M, Cenacchi A, Nosari A, Tonso A, et al. Localization of aspergillosis to the central nervous system among patients with acute leukemia: report of 14 cases. Gruppo Italiano Malattie Ematologiche dell'Adulto Infection Program. *Clin Infect Dis* 1996;23:628–30.
- [13] Hagensee ME, Bauwens JE, Kjos B, Bowden RA. Brain abscess following marrow transplantation: experience at the Fred Hutchinson Cancer Research Center, 1984–1992. *Clin Infect Dis* 1994;19:402–8.
- [14] Viscoli C, Machetti M, Gazzola P, de Maria A, Paola D, Van Lint MT, et al. *Aspergillus* galactomannan antigen in the cerebrospinal fluid of bone marrow transplant recipients with probable cerebral aspergillosis. *J Clin Microbiol* 2002;40:1496–9.
- [15] Jain KK, Mittal SK, Kumar S, Gupta RK. Imaging features of central nervous system fungal infections. *Neurol India* 2007;55:241–50.
- [16] Schwartz S, Thiel E. Cerebral aspergillosis: tissue penetration is the key. *Med Mycol* 2009;47:S387–93.
- [17] Brüggemann RJM, van der Linden JWM, Verweij PE, Burger DM, Warris A. Impact of therapeutic drug monitoring of voriconazole in a paediatric population. *Pediatr Infect Dis J* 2011;30:533–4.
- [18] Brüggemann RJM, Donnelly JP, Aarnoutse RE, Warris A, Blijlevens NMA, Mouton JW, et al. Therapeutic drug monitoring of voriconazole. *Ther Drug Monit* 2008;30:403–11.
- [19] Seyedmousavi S, Mouton JW, Verweij PE, Brüggemann RJ. Therapeutic drug monitoring of voriconazole and posaconazole for invasive aspergillosis. *Expert Rev Anti-Infect Ther* 2013;11:931–41.
- [20] Van der Linden JWM, Jansen RR, Bresters D, Visser CE, Geerlings SE, Kuijper EJ, et al. Azole resistant central nervous system aspergillosis. *Clin Infect Dis* 2009;48:1111–3.
- [21] Howard SJ, Cerar D, Anderson MJ, Albarrag A, Fisher MC, Pasqualotto AC, et al. Frequency and evolution of azole resistance in *Aspergillus fumigatus* associated with treatment failure. *Emerg Infect Dis* 2009;15:1068–76.