

PDF hosted at the Radboud Repository of the Radboud University Nijmegen

The following full text is a publisher's version.

For additional information about this publication click this link.

<http://repository.ubn.ru.nl/handle/2066/126853>

Please be advised that this information was generated on 2019-04-23 and may be subject to change.

Neuropsychological phenotype of a patient with a de novo 970 kb interstitial deletion in the distal 16p11.2 region

Jos I M Egger¹⁻³
Willem M A Verhoeven^{1,4}
Wim Verbeek⁵
Nicole de Leeuw⁶

¹Vincent van Gogh Institute for Psychiatry, Centre of Excellence for Neuropsychiatry, Venray, the Netherlands; ²Donders Institute for Brain, Cognition and Behaviour, Radboud University Nijmegen, Nijmegen, the Netherlands; ³Behavioural Science Institute, Radboud University Nijmegen, Nijmegen, the Netherlands; ⁴Erasmus University Medical Centre, Department of Psychiatry, Rotterdam, the Netherlands; ⁵Vincent van Gogh Institute for Psychiatry, Centre for Autism and ADHD, Venray, the Netherlands; ⁶Department of Human Genetics, Radboud University Medical Centre, Nijmegen, the Netherlands

Abstract: The 16p11.2 microdeletion syndrome is characterized by a wide range of phenotypic expressions and is frequently associated with developmental delay, symptoms from the autism spectrum, epilepsy, congenital anomalies, and obesity. These phenotypes are often related to a proximal 16p11.2 deletion of approximately 600 kb (BP4–BP5) that includes the *SH2B1* gene that is reported to be causative for morbid obesity. This more centromeric deletion is most strongly related to autism spectrum susceptibility and is functionally different from the more distal 16p12.2p11.2 region, which includes the so-called atypical 16p11.2 BP2–BP3 deletion (approximately 220 kb) presenting with developmental delay, behavioral problems and mild facial dysmorphisms. Here, an adult male with a long history of maladaptive behaviors is described who was referred for diagnostic assessment of his amotivational features. Extensive neuropsychological examination demonstrated rigid thinking, anxious beliefs, and ideas of reference in the presence of normal intelligence. Microarray analysis demonstrated a de novo 970 kb 16p11.2 BP1–BP4 microdeletion that can be regarded as explanatory for his behavioral profile. It is concluded that microdeletion syndromes are not exclusively related to intellectual disabilities and genetic testing is of putative relevance for the understanding of neuropsychiatric and neuropsychological phenomena.

Keywords: SNP array, microdeletion, distal 16p11.2, neuropsychological phenotype, social cognition

Introduction

Since high resolution comparative genomic hybridization techniques are increasingly available in the diagnostic procedures for patients with developmental disorders, several novel microdeletion and microduplication syndromes have been identified.¹⁻³ One of these is the 16p11.2 microdeletion syndrome (Online Mendelian Inheritance in Man [OMIM]: 611913). As reviewed by the research groups of Battaglia and Barge-Schaapveld, the typical 16p11.2 microdeletion syndrome is characterized by a wide range of phenotypic expressions and is frequently associated with developmental delay, symptoms from the autism spectrum, epilepsy, congenital anomalies, and obesity.^{4,5} These phenotypes are often related to a proximal 16p11.2 deletion of approximately 600 kb (BP4–BP5) encompassing 29 genes,⁶⁻¹⁰ of which the *SH2B1* gene (OMIM: 608937) is reported to be causative for morbid obesity.¹¹⁻¹³ Battaglia et al⁴ stated that this more centromeric deletion is most strongly related to autism spectrum susceptibility and is functionally different from the more distal region (16p12.2–p11.2; OMIM: 613604) which includes the so called atypical 16p11.2 deletion

Correspondence: Jos I M Egger
Vincent van Gogh Institute for Psychiatry, Centre of Excellence for Neuropsychiatry, Stationsweg 46, Venray, 5803AC, the Netherlands
Tel +31 478 527 339
Fax +31 478 630 797
Email j.egger@psych.ru.nl

(approximately 220 kb) presenting with developmental delay, behavioral problems, and mild facial dysmorphisms.⁵

In the present paper, an adult male with a long history of maladaptive behaviors, later associated with recurrent mild depressive and autistic symptoms, is described; the patient was referred for reevaluation of his clinical picture, particularly the amotivational features.

Patient and methods

Clinical description

The referred patient, a 33-year-old male, is the second son of non-consanguineous parents. He has a 5 years older, healthy brother. Apart from recurrent depression in his mother, there is no family history of intellectual disability, congenital anomalies, or neuropsychiatric disorders. The patient was born after an uncomplicated pregnancy and he had a normal birth weight and length (2,730 g and 48 cm, respectively; 0 standard deviation). No congenital anomalies were observed. There were normal developmental milestones. During early primary school years, both parents and teachers noticed social withdrawal tendencies and, incidentally, disproportionate reactions like clownish and impulsive behaviors to minor social stress, especially in novel and unstructured situations. Aged 16, a preliminary diagnosis of pervasive developmental disorder was made by a remedial educationalist at a community mental health center. Because of persistent behavioral problems, regularly accompanied by compelling and angry attitudes, secondary school education was fragmented; however, after several school changes, he finally completed high school at age 20. One year later, the patient discontinued his university studies because of problems with initiative and structuring of daily life. He was then admitted to a sheltered home facility. At the age of 24–25 years, marked motivational problems and recurrent mild depressive symptoms and/or ideas of reference necessitated several hospitalizations. Treatment with antidepressants and antipsychotics was given, without any effect. Ultimately, the patient was diagnosed with Asperger's syndrome, a pervasive developmental disorder, and he was admitted to a specialized department for autism spectrum disorders. Neither somatic and neurological examination nor hematological and biochemical parameters disclosed any abnormalities. Electroencephalogram (EEG)-registration, magnetic resonance imaging (MRI), and dopamine transporter – single photon emission computed tomography (DAT-SPECT) of the brain were all normal. The diagnosis of Asperger's disorder was confirmed and the patient subsequently entered a specialized sheltered home facility.

Present assessments

At the age of 32, he was referred for detailed reevaluation of his persistent amotivational behavior, for which no explanation could be given. Therefore, apart from somatic and neurological reexamination, extensive neuropsychological assessment including a Kaufman Adolescent and Adult Intelligence Test (KAIT) and a Minnesota Multiphasic Personality Inventory 2 Restructured Form (MMPI-2-RF) restructured clinical scale profiling was performed,^{14,15} as well as high density resolution, genome-wide array analysis.

Results

At examination, no dysmorphic features were found. Somatic and neurological examination did not disclose any abnormalities. Length and weight were 183 cm and 80 kg, respectively.

Neuropsychological profile

The patient's behavior showed autistic-like elements such as diminished social reciprocity, paucity of speech, poor pragmatic language, and enhanced sensory perception. No major psychiatric symptoms could be detected. Neuropsychological assessment revealed a KAIT¹⁴ total intelligence quotient of 112 and undisturbed attention, memory, and executive functioning. MMPI-2-RF testing¹⁵ disclosed poor reality testing, marked feelings of distrust, and an anxious disposition with excessive worrying (Figure 1). This profile suggests an enhanced vulnerability to psychotic experiences.

Affymetrix Cytoscan HD array

Genome wide array analysis with an average resolution of approximately 20 kb was performed using the Affymetrix

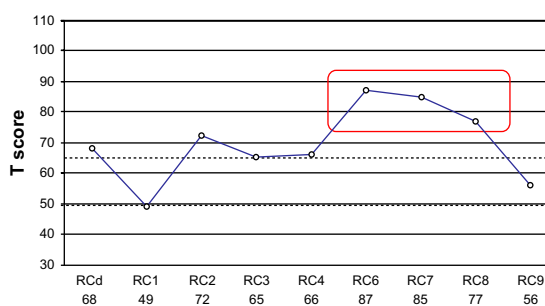


Figure 1 MMPI-2-RF restructured clinical scale profile of the patient with a de novo, approximately 970 kb interstitial deletion in 16p11.2.

Note: Scale scores are uniform T scores.

Abbreviations: MMPI-2-RF, Minnesota Multiphasic Personality Inventory 2 Restructured Form; RCd, Demoralization; RC1, Somatic Complaints; RC2, Low Positive Emotions; RC3, Cynicism; RC4, Antisocial Behavior; RC6, Persecutory Ideation; RC7, Dysfunctional Negative Emotions; RC8, Aberrant Experiences; RC9, Hypomanic Activation.

CytoScan HD array platform (Affymetrix Inc., Santa Clara, CA, USA) with 2.6 million markers, including 750,000 genotype-able single nucleotide polymorphisms and 1.9 million nonpolymorphic probes. The array results showed a 970 kb microdeletion in the short arm of chromosome 16. Subsequent carrier testing by array analysis in the parents revealed that the 16p11.2 microdeletion had occurred de novo in their child, resulting in the karyotype: arr[hg19] 16p11.2(28,461,879-29,428,533)x1 dn. This novel 16p11.2 BP1–BP4 microdeletion encompasses 20 known protein coding genes and two microRNAs (Figure 2).

Discussion

In the present paper, a 33-year-old, non-obese male with normal intelligence is described in whom a de novo, distal 16p11.2 BP1–BP4 microdeletion was demonstrated; this microdeletion can be regarded as causative for his pattern of anxiety-driven withdrawal behaviors, which result in recurrent episodes with referential thoughts. At this moment, no losses of similar size have been reported in healthy individuals (Database of Genomic Variants; <http://dgv.tcag.ca/dgv/app/home>).

So far, seven patients have been reported with a de novo microdeletion of 1.7–8.2 Mb in size, encompassing the 16p11.2 region and including the distal 16p11.2 deletion;

in contrast, in six other patients a de novo distal (previously called atypical) 16p11.2 deletion was demonstrated (Table 1). Recently, Guha and et al reported the results of a large association study with a cohort of 790 patients with schizophrenia spectrum disorders.¹⁶ They found 13 patients with 16p11.2 deletions ranging from BP1–BP4 which are not overlapping the proximal locus (BP4–BP5) that is connected to autism. This finding is in line with other copy-number variation studies and suggests this locus to be implicated in obesity and various neuropsychiatric disorders.^{12,17,18}

The distal 16p11.2 deletion between BP1 and BP4, as reported here, encompasses 20 known protein-coding genes, ie, *CLN3*, *APOBR*, *IL27*, *NUPR1*, *CCDC101*, *SULT1A2*, *SULT1A1*, *EIF3C*, *EIF3CL*, *ATXN2L*, *TUFM*, *SH2B1*, *ATP2A1*, *RABEP2*, *CD19*, *NFATC2IP*, *SPNS1*, *LAT*, *RRN3P2*, and *SNX29P2*. Four of these are disease-causing genes: *CD19* (OMIM: 107265); *TUFM* (OMIM: 602389); *CLN3* (OMIM: 607042); and *ATP2A1* (OMIM: 141750), without, however, any neuropsychiatric sequelae.

In conclusion, the distal 16p11.2 deletion phenotype is neither exclusively related to developmental delay nor to autism spectrum disorders. Rather, it has a highly variable presentation that may include, as demonstrated in the neuropsychological profile of the present patient, high average

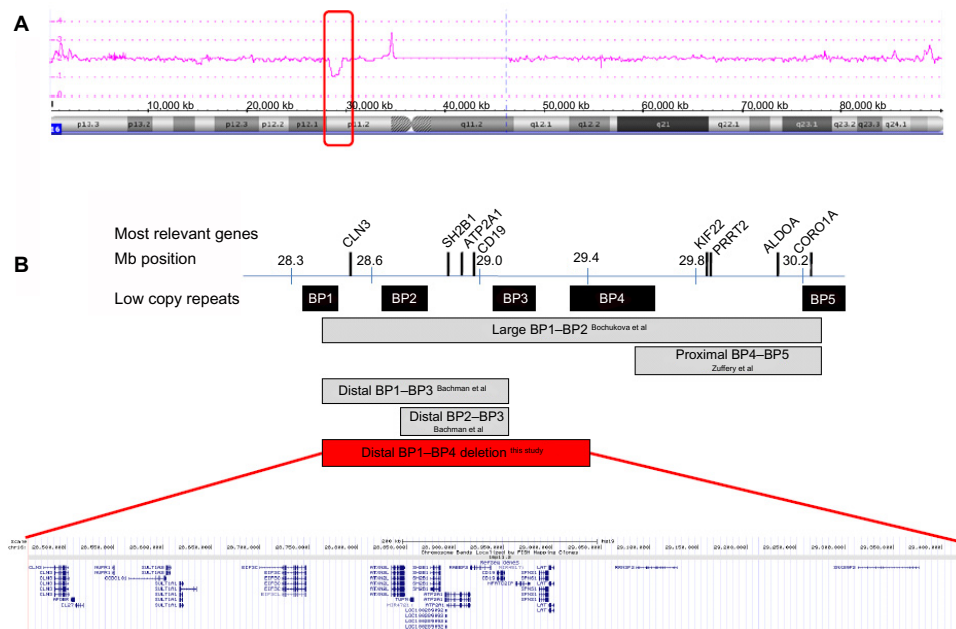


Figure 2 Array plot of chromosome 16 and schematic representation of the distal 16p11.2 region.

Notes: (A) Array plot of chromosome 16 of the patient with an interstitial deletion of 970 kb in 16p11.2 (red rectangle). (B) Schematic representation of the distal region of 16p11.2. Positions of genes and deletions are shown relative to the low copy repeat blocks within the 16p11.2 region (BP1 through BP5). The enlarged view of the distal 16p11.2 region is a screen shot of the UCSC Genome Browser Build 37/hg19 (<http://genome.ucsc.edu/>).

Table 1 Overview of patients with de novo 16p11.2 deletions (partially) overlapping the present deletion

Author	Large/distal only	Size/position	Developmental delay	Facial dysmorphisms	Neuropsychiatry and cognition	Other
Battaglia et al ⁴	Large	~8,2 Mb (21,3–29,5)	+	+	Hyperactivity and attentional problems	N/A
Bochukova et al ¹²	Large	~1,7 Mb (28,3–30,1)	+			
	Large	~1,7 Mb (28,4–30,1)	+			
Hanson et al ⁸	Large (patient 17)	~1,7 Mb (28,4–30,1)				
Sampson et al ⁷	Large (patient 2)	~1,7 Mb (28,4–30,1)	+	+	Autistic features	Eye abnormalities, seizures, renal dysfunction
	Distal only (patient 1)	~217 kb (28,7–29,0)				Agenesis left kidney, aganglionic bowel segment
Bachmann-Gagescu et al ¹¹	Large (patient 4)	~500 kb (28,4–28,9)	+	+		
	Distal only (patient 5)	~200 kb (28,7–28,9)	+		Autistic features	Obesity
Unpublished (cf., Firth et al ¹⁹)	Large	~7,81 Mb (21,4–29,2)	+	+		
	Distal only (DECIPHER 249980)	~220 kb (28,8–29,0)	+	+	Hyperactivity	Seizures
	Distal only (DECIPHER 251199)	~200 kb (28,8–29,0)	+			Obesity
	Distal only (DECIPHER 253362)	~200 kb (28,8–29,0)				
	Distal only (DECIPHER 253364)	~200 kb (28,8–29,0)				
Present patient	Large distal	~970 kb (28,5–29,4)			Ideas of reference, social withdrawal, high average intelligence (IQ = 112)	

Note: Data from Barge-Schaapveld et al.⁵

Abbreviations: IQ, intelligence quotient; N/A, not applicable; cf., conferatur.

intelligence and social cognitive dysfunctions referring to Asperger's syndrome.

Acknowledgments

The patient provided written informed consent for publication. This case has been submitted to the ECARUCA database (<http://www.ecaruca.net>) with identification number 5037. This study is part of a collaborative project of the research group "Psychopathology and Genetics" of the Radboud University Nijmegen and the Vincent van Gogh Institute for Psychiatry, Venray, the Netherlands.

Disclosure

The authors report no conflicts of interest in this work.

References

- Veltman JA. Genomic microarrays in clinical diagnosis. *Curr Opin Pediatr.* 2006;18(6):598–603.

- Slavotinek AM. Novel microdeletion syndromes detected by chromosome microarrays. *Hum Genet.* 2008;124(1):1–17.
- Vissers LELM, de Ligt J, Gilissen C, et al. A de novo paradigm for mental retardation. *Nat Genet.* 2010;42(12):1109–1112.
- Battaglia A, Novelli A, Bernardini L, Iglizzo, R, Parrini B. Further characterization of the new microdeletion syndrome of 16p11.2–p12.2. *Am J Med Genet.* 2009;149A(6):1200–1204.
- Barge-Schaapveld DQ, Maas SM, Polstra A, Knecht LC, Hennekam RC. The atypical 16p11.2 deletion: a not so atypical microdeletion syndrome? *Am J Med Genet A.* 2011;155A(5):1066–1072.
- Weiss LA, Shen Y, Korn JM, et al; Autism Consortium. Association between microdeletion and microduplication at 16p11.2 and autism. *N Engl J Med.* 2008;358(7):667–675.
- Sampson MG, Coughlin CR, Kaplan P, et al. Evidence for a recurrent microdeletion at chromosome 16p11.2 associated with congenital anomalies of the kidney and urinary tract (CAKUT) and Hirschsprung disease. *Am J Med Genet.* 2010;152A(10):2618–2622.
- Hanson E, Nasir RH, Fong A, et al; 16p11.2 Study Group Clinicians. Cognitive and behavioural characterization of 16p11.2 deletion syndrome. *J Dev Behav Pediatr.* 2010;31(8):649–657.
- Crepel A, Steyaert J, De la Marche W, et al. Narrowing the critical deletion region for autism spectrum disorders on 16p11.2. *Am J Med Genet.* 2011;156(2):243–245.

10. Zufferey F, Sherr EH, Beckmann ND, et al. Simons VIP Consortium; 16p11.2 European Consortium. A 600 kb deletion syndrome at 16p11.2 leads to energy imbalance and neuropsychiatric disorders. *J Med Genet.* 2012;49(10):660–668.
11. Bachmann-Gagesku R, Mefford HC, Cowan C, et al. Recurrent 200-kb deletions of 16p11.2 that include the SH2B1 gene are associated with developmental delay and obesity. *Genet Med.* 2010;12(10):641–647.
12. Bochukova EG, Huang N, Keigh J, et al. Large, rare chromosomal deletions associated with severe early-onset obesity. *Nature.* 2010;463(7281):666–670.
13. Walters RG, Jacquemont S, Valsesia A, et al. A novel highly-penetrant form of obesity due to microdeletions on chromosome 16p11.2. *Nature.* 2010;463(7281):671–675.
14. Kaufman S, Kaufman NL, Mulder JL, Dekker R, Dekker PH. *Dutch Adaptation of the Kaufman Adolescent and Adult Intelligence Test.* Amsterdam: Pearson; 2004.
15. van der Heijden PT, Egger JI, Derksen JJ. Psychometric evaluation of the MMPI-2 Restructured Clinical scales in two Dutch samples. *J Pers Assess.* 2008;90(5):456–464.
16. Guha S, Rees E, Darvasi A, et al. Molecular Genetics of Schizophrenia Consortium; Wellcome Trust Case Control Consortium 2. Implication of a rare deletion at distal 16p11.2 in schizophrenia. *JAMA Psychiatry.* 2013;70(3):253–260.
17. Cooper GM, Coe BP, Girirajan S, et al. A copy number variation morbidity map of developmental delay. *Nat Genet.* 2011;43(9):838–846.
18. Kirov G, Pocklington AJ, Holmans P, et al. De novo CNV analysis implicates specific abnormalities of postsynaptic signalling complexes in the pathogenesis of schizophrenia. *Mol Psychiatry.* 2012;17(2):140–153.
19. Firth HV, Richards SM, Bevan AP, et al. DECIPHER: Database of chromosomal imbalance and phenotype in humans using ensemble resources. *Am J Hum Genet.* 2009;84(4):524–533.

Neuropsychiatric Disease and Treatment

Dovepress

Publish your work in this journal

Neuropsychiatric Disease and Treatment is an international, peer-reviewed journal of clinical therapeutics and pharmacology focusing on concise rapid reporting of clinical or pre-clinical studies on a range of neuropsychiatric and neurological disorders. This journal is indexed on PubMed Central, the 'PsycINFO' database and CAS.

The manuscript management system is completely online and includes a very quick and fair peer-review system, which is all easy to use. Visit <http://www.dovepress.com/testimonials.php> to read real quotes from published authors.

Submit your manuscript here: <http://www.dovepress.com/neuropsychiatric-disease-and-treatment-journal>