

Pathophysiology of impaired hand function in children with unilateral cerebral palsy

ANDREW M GORDON¹ | YANNICK BLEYENHEUFT² | BERT STEENBERGEN³

1 Department of Biobehavioral Sciences, Teachers College, Columbia University, New York, NY, USA. **2** Institute of Neuroscience, Université catholique de Louvain, Brussels, Belgium. **3** Radboud University Nijmegen, Behavioural Science Institute, Nijmegen, the Netherlands.

Correspondence to Dr Andrew M Gordon, Department of Biobehavioral Sciences, Box 93, Teachers College, Columbia University, 525 West 120th Street, New York, NY 10027, USA. E-mail: ag275@columbia.edu

PUBLICATION DATA

Accepted for publication 4th April 2013.

ABBREVIATION

CST Corticospinal tract

Unilateral spastic cerebral palsy, caused by damage to the developing central nervous system, is characterized by motor impairments mainly lateralized to one side of the body, with hand impairments greatly contributing to functional limitations. The integrity of the motor areas and the corticospinal tract (CST) is often compromised. The specific etiology may drastically influence subsequent development of CST pathways. Here we describe the pathophysiology underlying impaired upper extremity function, with particular emphasis on the relation between CST damage and hand function. We also describe the resulting sensory and motor deficits, with an emphasis on studies of precision grip, which highlight impairments in motor execution, sensorimotor integration, motor planning, and bimanual coordination beyond dexterity impairments. We show that the type and extent of early brain damage and/or CST reorganization is highly predictive of the severity of these impairments. We discuss the clinical implications of these findings, including the intriguing possibility that the specific pathophysiology is predictive of treatment outcomes. We suggest that a 'one-treatment fits all approach' may be insufficient, and that future rehabilitation efforts will be best guided by closely relating treatment efficacy with the specific pathophysiology.

Cerebral palsy (CP) is among the most common pediatric neurological disorders, and is caused by damage to the brain during early development. Unilateral spastic CP, characterized by motor impairments mainly lateralized to one body side, is among the most common subtypes.

Here we review the pathophysiology and mechanisms underlying impaired upper extremity function of unilateral spastic CP. We also relate the specific pathophysiology with the hand impairments, showing clear relations between the type and extent of early brain damage and/or reorganization with impairment severity. Finally we discuss clinical implications, including possible pathophysiological predictors of treatment outcome.

NEURAL BASIS OF UNILATERAL SPASTIC CP

During typical human development, corticospinal tract (CST) motor pathways from motor areas, notably primary motor cortex, develop in a corticofugal manner, approaching the spinal cord by the 20th week of gestation.¹ Subsequently these projections undergo synaptogenesis, with target cells at the spinal-segmental level. The motor cortices initially develop bilateral projections (i.e. projections to both contralateral and ipsilateral upper extremities). Continued development is characterized by gradual weakening of ipsilateral projections, and strengthening of contralateral projections through synaptic competition,¹ which is driven by primary motor cortex activity.² This intricate process is susceptible to prenatal and perinatal brain damage. CST directly innervates hand motoneurons, which provide the capacity for selective upper extremity movement control.³ Thus, damage to this developing system can permanently impair manual dexterity.³

Unilateral spastic CP is typically the result of middle cerebral artery infarct, hemi-brain atrophy, periventricular lesions, brain malformation, or posthemorrhagic porencephaly,^{4,5} and the integrity of the motor areas and CST is often compromised.^{6,7} The specific etiology may drastically influence subsequent development of CST pathways.¹ The severity of hand impairments largely depends on the extent of damage to the CST,^{7,8} which can be estimated by using both conventional MRIs and diffusion tensor imaging, by measuring the asymmetry in the cross-sectional area of the cerebral peduncles through which the CST passes (Fig. 1a),⁷ or by measuring the fractional anisotropy.⁸ The asymmetry in the CST innervating each hand (Fig. 1a) is highly correlated to severity of manual dexterity impairments, with higher asymmetry (values below 100) related to greater impairments. The timing of CST damage is also predictive of outcome. Generally speaking, cortical malformation in the first two trimesters results in less severe hand impairments than periventricular lesions early in the third trimester or middle cerebral artery damage later in the third trimester (Fig. 1b).⁶ Unilateral brain damage occurring during the intrauterine period can attenuate or prevent neuronal activity in CST projections originating in the affected hemisphere, with the result being that the ipsilateral projections are maintained and strengthened during further development, whereas the contralateral projections are partly or completely abolished, especially in individuals with large lesions.^{1,6,9} Even in individuals with small lesions, there can also be a reorganization whereby involvement of the ipsilateral hemisphere can show significant activation of ipsilateral premotor areas.¹ Generally, individuals who undergo such ipsilateral reor-

ganization have more severely affected hand function (fewer blocks manipulated, Fig. 1c)¹⁰ and the persistence of mirror movements. However, that is not to say that this reorganization is dysfunctional; instead, it probably represents functional compensation of the affected hemisphere by the unaffected hemisphere. The extent to which this ipsilateral reorganization is able to compensate for the absent contralateral projects decreases with increasing age at the time of damage.⁶ It should also be pointed out that CST projections to spinal interneurons, which are also important for transmitting signals from cortex to muscle, are also impaired, further affecting coordination and reflex control.¹¹

MOVEMENT EXECUTION IMPAIRMENTS

As a result of the damage to the CST and other developing motor pathways described above, there are impairments in movement execution by the upper extremity. For example, the upper extremity is often weak, and the lack of selective finger movements results in the use of several fingers when fewer are required (e.g. precision grip), making movements slow and clumsy.¹² The relation between type/timing of the lesion and such execution deficits is described above.

Hand motor control has been quantified for more than two decades by the examination of fingertip forces during precision grasping. Fingertip coordination in typically developing children generally approximates adult coordination by 6 to 8 years of age.¹³ In contrast, children with CP at this age often have force coordination resembling that of very young children, with prolonged delays between movement phases (e.g. grasp contact and subsequent load force initiation) and sequential generation of grip and load force.¹⁴ Although most children with CP are capable of adjusting their fingertip forces to the object's weight and texture, their forces are often variable and excessive, with reduced adaptation compared with typically developing children.¹⁵ Fingertip force coordination is also impaired during object release,¹⁶ which is exacerbated when speed and accuracy constraints are imposed.¹⁷ Precision grip in

What this paper adds

- Type and extent of early brain damage and/ or CST reorganization is highly predictive of the severity of these upper extremity impairments.
- Future rehabilitation efforts will be best guided by closely relating treatment efficacy with the specific pathophysiology.

children with CP does improve with development¹⁸ and extended practice,¹⁹ which has helped motivate intensive rehabilitation protocols (e.g. constraint-induced movement therapy).^{20,21}

SENSORIMOTOR IMPAIRMENTS

Because thalamocortical somatosensory projections reach their cortical destination sites during the third trimester, typically they are undamaged by periventricular lesions, or they may circumvent the lesion to terminate in the postcentral gyrus.¹ In contrast, middle cerebral artery infarctions, occurring later and often affecting the postcentral gyrus, are more likely to affect the somatosensory system.¹ Thus, children with unilateral spastic CP, especially of middle cerebral artery origin, often have sensory impairments, which may further compromise fine motor skills.^{12,22} Specifically, tactile perception (light touch) and discrimination, stereognosis, and proprioception are often impaired,^{23,24} with the amount of impairment related to the integrity of ascending sensorimotor pathways.⁸ These sensory impairments may be at least partly responsible for the precision grip impairments found in CP²³ as the latter impairments resemble precision grip control under digital anesthesia.²⁵ However, the relation between sensory and motor abilities is not trenchant. A relation has been established between stereognosis and motor function,²³ but conflicting results are reported for other modalities.

MOTOR PLANNING IMPAIRMENTS

In addition to movement execution and sensory impairments, individuals with unilateral spastic CP have impairments in motor planning,²⁶ which can also impact precision grasping. During object manipulation, the development of fingertip forces must be

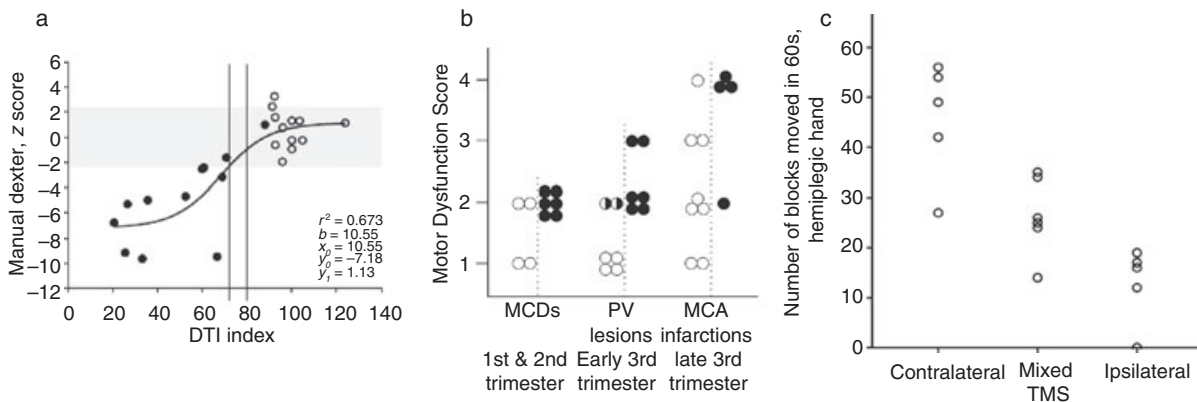


Figure 1: (a) Cross-sectional area of corticospinal tract (CST) estimated with diffusion tensor imaging (DTI) as it passes through the cerebral peduncles at the level of the mammillary bodies. Correlations between manual ability measured using box and blocks and DTI symmetry indexes of the CST in children with unilateral spastic cerebral palsy (filled circles) and controls (open circles). Modified from Bleyenheuft et al.⁷ (b) Comparison of hand motor dysfunction scores among patients with congenital lesions acquired during the three major timing periods (malformations of cortical development [MCD], first and second trimester of pregnancy; periventricular [PV] lesions, early third trimester of pregnancy; middle cerebral artery [MCA] infarctions, late third trimester of pregnancy). Open circles, patients with preserved crossed corticospinal projections from the affected hemispheres; filled circles, patients with reorganized ipsilateral projections from the contra-lesional hemispheres; half-filled circles, patients with both preserved contralateral and reorganized ipsilateral corticospinal projections to the more-affected hand. Modified from Staudt et al.⁵ (c) Relation between box and blocks score using the more-affected hand and the CST motor-projection pattern to the hand, assessed using transcranial magnetic stimulation (TMS). Modified from Holstrom et al.¹⁰

planned before initiation because sensory information about some object properties (e.g. weight) is not immediately available. This type of planning involves the formation and use of internal models of objects based on previous experience manipulating a given object.¹⁹ Children with unilateral spastic CP have a decreased ability to scale the amplitude of the force development in their more-affected hand.¹⁵ However, impairments in force development scaling are reduced after extensive practice,¹⁹ providing the basis for intensive rehabilitation protocols. The observed planning deficits may at least partly reflect deficits in motor learning, involving the extraction of appropriate sensory information to form internal models, and integrating it with motor commands during subsequent actions. However, this does not mean that all planning deficits can be ameliorated with practice. One dynamic action in which children with unilateral spastic CP perform routinely yet have deficits is walking with a hand-held object, which requires precise coupling of fingertip forces in an anticipatory manner. Because the inertial forces acting on the hand-held object oscillate in a sinusoidal manner owing to gait-related events (e.g. initial foot contact), the grip force must be actively timed and modulated to the resulting inertial force oscillations. This force coupling reduces the need to maintain high grasping forces (risking fatigue) by ensuring that the grip force is sufficient at critical points (initial foot contact) to prevent slips, as seen in typically developed adults.²⁷ Figure 2 shows the fluctuations in inertial force as a result of gait and the grip force responses for a child with unilateral spastic CP. A coupling of the inertial and grip forces can be seen in the less-affected hand, where both forces fluctuate in parallel. In contrast, the fluctuations of the grip force in the more affected hand appear to be unrelated to the gait-induced inertial force fluctuations (Fig. 2).²⁸

Children with unilateral spastic CP usually demonstrate 'global planning' impairments that are independent of the effector used.²⁶ The relation between type/timing of the lesion and such planning deficits is unknown. Oddly, the force scaling deficits during object lifting^{15,19} are effector dependent: a lack of planning is observed in the more-affected, but not less-affected, upper extremity. A similar finding during load force perturbations was reported, with an inability to anticipate the consequences of a dynamic perturbation.²⁹ Interestingly, after several lifts with the less-affected hand, anticipatory planning, reflected by force rates that appropriately reflect the object's weight, is immediately present in the more-affected hand.³⁰ In a subsequent study,³¹ we found that, despite its absence in more-affected hand, anticipatory control may be transferred from the more-affected to the less-affected hand. Thus children with unilateral spastic CP achieve sufficient sensory

information to form internal models for subsequent use with their less-affected hand. This suggests that the impaired planning may be due to an inability to integrate sensory information with the motor command in the more-affected hand. We also found that simultaneous grasp and lift of an object in each hand improved some aspects of grip performance compared with unilateral lifts with the more-affected hand,³² although the grip-lift movements became slower, probably because of the requirement to divide attention between the two hands. These findings helped motivate bimanual training approaches (e.g. hand-arm bimanual intensive therapy).^{21,33}

BIMANUAL COORDINATION IMPAIRMENTS

Children with unilateral spastic CP have impairments in bimanual coordination beyond unimanual dexterity deficits.³⁴⁻³⁶ Similar to motor planning, the relation between type/timing of the lesion and such bimanual coordination impairments is unknown. During symmetrical, bimanual reaching tasks, children with unilateral spastic CP showed the ability to coordinate their bimanual movements by compensating with their non-involved hand as long as accuracy demands or task complexity were not increased. In a recent study, participants were instructed to hold a grip device in each hand and place one device on top of the other while the grip and load force were recorded simultaneously in both hands (Fig. 3a).³⁷ Children with CP initiated the task by decreasing grip force in the releasing hand before increasing the force in the holding hand during the preparation phase, with the subsequent grip force increase in the holding hand being smaller and occurring later (transition phase) than that of typically developing children (Fig. 3a). The impairments were unrelated to the presence of mirror movements. The impairment was greater when the less-affected hand served as the holding hand.

In another series of studies,^{38,39} participants were asked to open a drawer with one hand and manipulate its contents with the other hand. Children with unilateral spastic CP were less coordinated, with reduced movement overlap of the drawer-opening hand (solid trace) and manipulating hand (dashed trace) (ii-v) and sequential completion of opening the drawer and manipulating its contents (v, vi) (Fig. 3b).³⁸ Interestingly, bimanual training improved some aspects of this coordination more than constraint-induced movement therapy.³⁹

CONCLUSION

Overall, we have described the pathophysiology underlying impaired upper extremity function of unilateral spastic CP, with particular emphasis on the relation between CST damage and

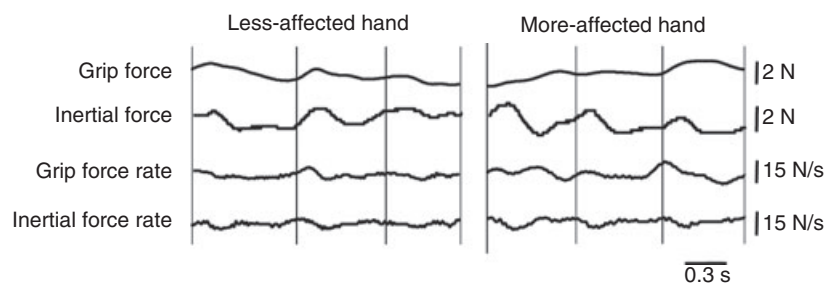


Figure 2: Grip force, inertial force, and grip and inertial force rate from a child with unilateral spastic cerebral palsy using the more- and less-affected hands while walking with the grip instrument. Vertical lines represent the time of initial contact of the foot. Modified from Prabhu et al.²⁸

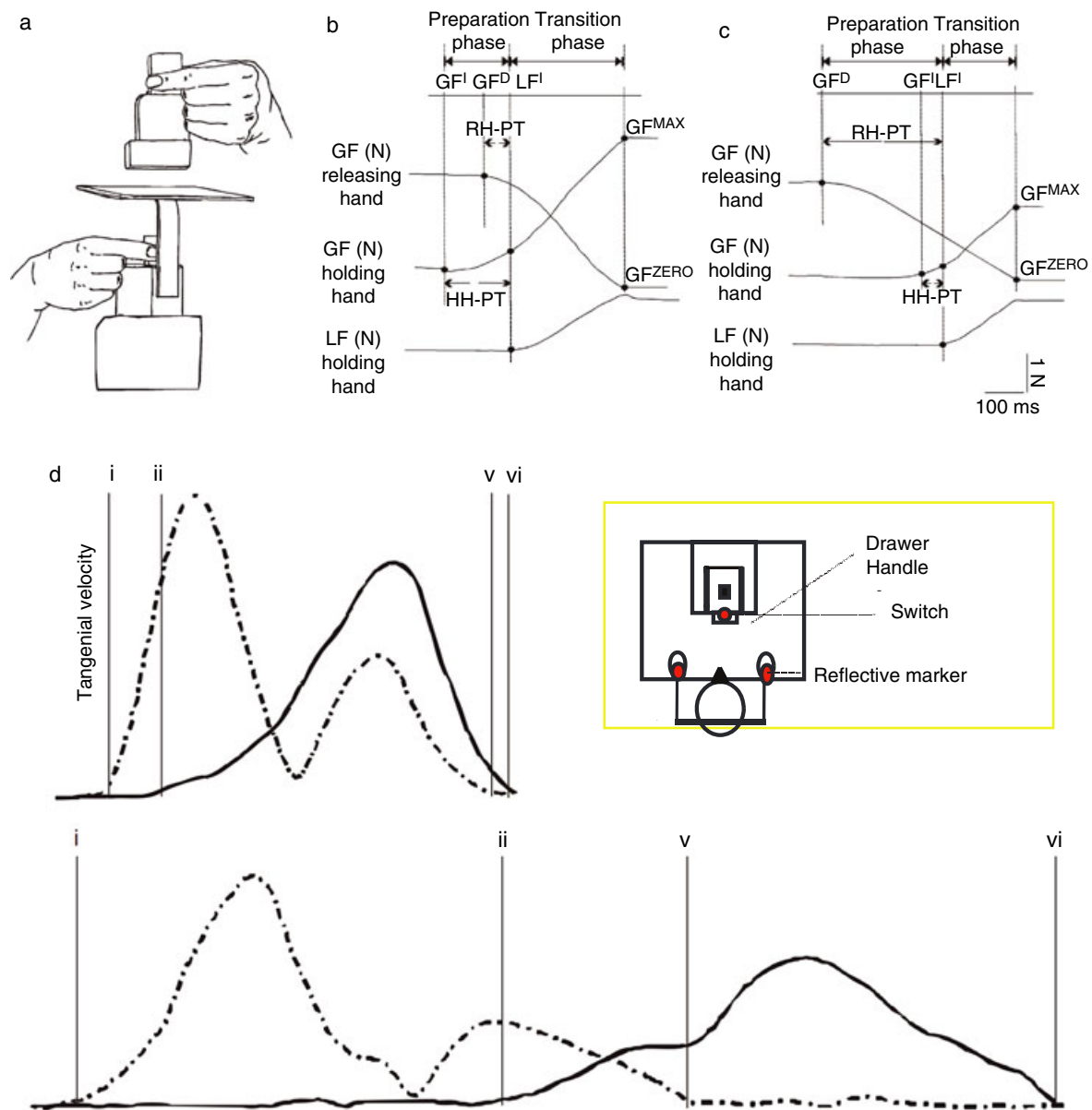


Figure 3: (a) Schematic diagram of the experimental set-up. Modified from Islam et al.³⁷ (b, c) Schematic force trajectories showing temporal and force parameters while performing the bimanual task for (b) typically developing participants and (c) participants with cerebral palsy (CP). The vertical lines define different time events in the preparation and transition phases in milliseconds. GF^D , grip force starts to decrease; GF^I , grip force starts to increase; GF^{MAX} , grip force maximum; GF^{ZERO} , grip force zero; LF^I , load force increase; HH-PT, holding hand preparation time; RH-PT, releasing hand preparation time; N, newtons. (d) Tangential velocity kinematic traces of a typically developing child and child with unilateral spastic CP. Top, comparison participant using dominant hand to open drawer at self-pace. Bottom, a child with unilateral spastic CP using non-involved hand to open drawer at self-pace. (i) Movement onset of drawer hand. (ii) Movement onset of task hand. (v) Movement offset of drawer hand when drawer is completely opened. (vi) Movement offset of task hand. (ii–v) Movement overlap time for two hands. (v–vi) Duration of goal synchronization. Modified from Hung et al.³⁸

hand function. We have described the resulting sensory and motor deficits, with an emphasis on studies of precision grip. These studies show impairments in (1) motor execution; (2) sensorimotor integration; (3) motor planning; and (4) bimanual coordination beyond dexterity impairments. Knowledge about the various forms of unilateral spastic CP is still rather limited. The type/timing of the lesion is fairly predictive of motor execution and sensorimotor integration impairments, although the relation

between lesions and motor planning and bimanual coordination is much less understood.

These findings have several clinical implications. First, the finding that precision grip improves only with extensive practice¹⁹ emphasizes the importance of intensity of training. In agreement, training protocols that provide such intensity (such as constraint-induced movement therapy and intensive bimanual training)^{20,21} appear to be efficacious in improving hand function, whereas little

evidence exists for treatments provided at usual and customary care schedules. Second, the potential interference of the more-affected hand on the less-affected hand³⁶ during bimanual activities may partly explain why children with unilateral spastic CP prefer to use only one hand during tasks typically using both hands. Findings that environmental constraints affect performance¹⁷ suggest the importance of context, and that environmental constraints could be used in rehabilitation to create variability of practice. Finally, improved performance during simultaneous or sequential (transfer) bimanual actions (e.g. kinematic mirroring) emphasizes the potential contribution that the less-affected hand could make to rehabilitation of the more-affected hand.

Although the CST damage is highly predictive of severity of hand impairments, an intriguing possibility is that the specific pathophysiology is predictive of treatment outcomes. For example, it has been suggested that individuals who have undergone reorganization of the CST fare worse after constraint-induced movement therapy than individuals who maintain contralateral CST innervation.⁴⁰ This raises the possibility that there is an interaction between the connectivity and integrity of the CST and the efficacy of different training approaches for the upper extremities. Constraining the less-affected upper extremity may drive decrease activity in the unaffected primary motor cortex and thus

decrease the consequent interhemispheric inhibition of that hemisphere over the affected primary motor cortex. This may be suitable for children maintaining contralateral CST innervation; however, in children with ipsilateral CST reorganization, constraining the less-affected upper extremity may drive down primary motor cortex activity controlling both upper extremities, possibly impeding recovery. One could speculate that bimanual training may be a better approach for children with ipsilateral CST innervation, but the efficacy may depend on the integrity of interhemispheric connections. Thus a 'one-treatment fits all approach' may not be sufficient. We speculate that future rehabilitation efforts will be best guided by testing these possibilities and closely relating treatment efficacy with specific pathophysiology on an individual-by-individual basis.

ACKNOWLEDGEMENTS

This work was supported by a grant from the Thrasher Research Fund and CVS Caremark.

CONFLICTS OF INTEREST

The authors declare no conflicts of interest.

REFERENCES

1. Staudt M. Brain plasticity following early life brain injury: insights from neuroimaging. *Semin Perinatol* 2010; **34**: 87–92.
2. Friel KM, Chakrabarty S, Martin JH. Pathophysiological mechanisms of impaired limb use and repair strategies for motor systems after unilateral injury of the developing brain. *Dev Med Child Neurol* 2013.
3. Lawrence DG, Kuypers HG. The functional organization of the motor system in the monkey. I. The effects of bilateral pyramidal lesions. *Brain* 1967; **91**: 1–14.
4. Uvebrandt P. Hemiplegic cerebral palsy. Aetiology and outcome. *Acta Paediatr Scand Suppl* 1988; **345**: 1–100.
5. Cioni G, Sales B, Paolicelli PB, Petacchi E, Scusa MF, Canapicchi R. MRI and clinical characteristics of children with hemiplegic cerebral palsy. *Neuropediatrics* 1999; **30**: 249–55.
6. Staudt M, Gerloff C, Grodd W, et al. Reorganization in congenital hemiparesis acquired at different gestational ages. *Ann Neurol* 2004; **56**: 854–63.
7. Bleyenheuft Y, Grandin CB, Cosnard G, Olivier E, Thonnard JL. Corticospinal dysgenesis and upper-limb deficits in congenital hemiplegia: a diffusion tensor imaging study. *Pediatrics* 2007; **120**: e1502–11.
8. Scheck SM, Boyd RN, Rose SE. New insights into the pathology of white matter tracts in cerebral palsy from diffusion magnetic resonance imaging: a systematic review. *Dev Med Child Neurol* 2012; **54**: 684–96.
9. Eyre JA, Smith M, Dabydeen L, et al. Is hemiplegic cerebral palsy equivalent to amblyopia of the corticospinal system? *Ann Neurol* 2007; **62**: 493–503.
10. Holmström L, Vollmer B, Tedroff K, et al. Hand function in relation to brain lesions and corticomotor-projection pattern in children with unilateral cerebral palsy. *Dev Med Child Neurol* 2010; **52**: 145–52.
11. Harrison A. Spastic cerebral palsy: possible spinal interneuronal contributions. *Dev Med Child Neurol* 1988; **30**: 769–80.
12. Brown JK, van Rensburg E, Walsh G, Lakin M, Wright GW. A neurological study of hand function of hemiplegic children. *Dev Med Child Neurol* 1987; **29**: 287–304.
13. Gordon AM. Development of hand motor control. In: Kalverboer AF, Gramsbergen A, editors. *Handbook of Brain and Behaviour in Human Development*. Dordrecht: Kluwer, 2001: 513–37.
14. Eliasson AC, Gordon AM, Forssberg H. Basic coordination of manipulative forces of children with cerebral palsy. *Dev Med Child Neurol* 1991; **33**: 659–68.
15. Eliasson AC, Gordon AM, Forssberg H. Impaired anticipatory control of isometric forces during grasping by children with cerebral palsy. *Dev Med Child Neurol* 1992; **34**: 216–25.
16. Eliasson AC, Gordon AM. Impaired force coordination during object release in children with hemiplegic cerebral palsy. *Dev Med Child Neurol* 2000; **42**: 228–34.
17. Gordon AM, Lewis S, Eliasson AC, Duff S. Object release under varying task constraints in children with hemiplegic cerebral palsy. *Dev Med Child Neurol* 2003; **45**: 240–8.
18. Eliasson AC, Forssberg H, Hung YC, Gordon AM. Development of hand function and precision grip control in individuals with cerebral palsy: a 13-year follow up study. *Pediatrics* 2006; **118**: e1226–36.
19. Gordon AM, Duff SV. Fingertip forces during object manipulation in children with hemiplegic cerebral palsy. I: anticipatory scaling. *Dev Med Child Neurol* 1999; **41**: 166–75.
20. Gordon AM. To constrain or not to constrain, and other stories of intensive upper extremity training for children with unilateral cerebral palsy. *Dev Med Child Neurol* 2011; **53**(Suppl. 4): 56–61.
21. Gordon AM. Constraint-induced therapy and bimanual training in children with unilateral cerebral palsy. In: Shepherd R, editor. *Cerebral Palsy in Infancy and Early Childhood Optimizing Growth, Development and Motor Performance*. Elsevier. Forthcoming.
22. Moberg E. Criticism and study of methods for examining sensibility in the hand. *Neurology* 1962; **12**: 8–19.
23. Gordon AM, Duff SV. Relation between clinical measures and fine manipulative control in children with hemiplegic cerebral palsy. *Dev Med Child Neurol* 1999; **41**: 586–91.
24. Bleyenheuft Y, Thonnard JL. Tactile spatial resolution in unilateral brain lesions and its correlation with digital dexterity. *J Rehabil Med* 2011; **43**: 251–6.
25. Johansson RS, Westling G. Roles of glabrous skin receptors and sensorimotor memory in automatic control of precision grip when lifting rougher or more slippery objects. *Exp Brain Res* 1984; **56**: 550–64.
26. Steenbergen B, Jongbloed-Pereboom M, Spruijt S, Gordon AM. Impaired motor planning and motor imagery in children with unilateral spastic cerebral palsy: challenges for the future of pediatric rehabilitation. *Dev Med Child Neurol* 2013.
27. Gysin P, Kaminski TR, Hass CJ, Gordon AM. Effects of gait variations on grip force coordination during object transport. *J Neurophysiol* 2008; **100**: 2477–85.
28. Prabhu S, Diermayr G, Gysin P, Gordon AM. Impaired anticipatory control of grasp during gait in children with hemiplegic cerebral palsy. *Dev Med Child Neurol* 2011; **53**: 865–9.
29. Bleyenheuft Y, Thonnard JL. Predictive and reactive control of precision grip in children with congenital hemiplegia. *Neurorehabil Neural Repair* 2010; **24**: 318–27.
30. Gordon AM, Charles J, Duff SV. Fingertip forces during object manipulation in children with hemiplegic cerebral palsy. II: bilateral coordination. *Dev Med Child Neurol* 1999; **41**: 176–85.
31. Gordon AM, Charles J, Steenbergen B. Movement planning is disrupted by impaired sensorimotor integration in children with hemiplegic cerebral palsy. *Pediatr Res* 2006; **60**: 587–91.
32. Steenbergen B, Charles J, Gordon AM. Fingertip force control during bimanual object lifting in hemiplegic cerebral palsy. *Exp Brain Res* 2008; **186**: 191–201.
33. Gordon AM, Hung YC, Brandao M, et al. Bimanual training and constraint-induced movement therapy in children with hemiplegic cerebral palsy: a randomized trial. *Neurorehabil Neural Repair* 2011; **25**: 692–702.
34. Steenbergen B, Hulstijn W, De Vries A, Berger M. Bimanual movement coordination in spastic hemiparesis. *Exp Brain Res* 1996; **110**: 91–8.
35. Steenbergen B, Van Thiel E, Hulstijn W, Meulenbroek RGJ. The coordination of reaching and grasping in spastic hemiparesis. *Hum Mov Sci* 2000; **19**: 75–105.
36. Gordon AM, Steenbergen B. Bimanual coordination in children with cerebral palsy. In: Eliasson AC, Burtner P,

- editors. Improving Hand Function in Children with Cerebral Palsy: Theory, Evidence and Intervention. Clinics in Developmental Medicine. London: Mac Keith Press, 2008: 160–75.
37. Islam M, Gordon AM, Forssberg H, Sköld A, Eliasson AC. Grip force coordination during a bimanual task in unilateral cerebral palsy. *Dev Med Child Neurol* 2011; **53**: 920–6.
38. Hung Y-C, Charles J. Gordon, AM Bimanual coordination of arm movements in children with hemiplegia. *Dev Med Child Neurol* 2004; **46**: 746–53.
39. Hung Y-C, Casertano L, Hillman A, Gordon AM. The effect of training specificity on bimanual coordination in children with hemiplegia. *Res Dev Disabil* 2011; **32**: 2724–31.
40. Kuhnke N, Juenger H, Walther M, Berweck S, Mall V, Staudt M. Do patients with congenital hemiparesis and ipsilateral corticospinal projections respond differently to constraint-induced movement therapy? *Dev Med Child Neurol* 2008; **50**: 898–903.

An International Meeting on Developmental Neurology

INSPIRING INFANCY

Interrelations between sensory, motor, and cognitive abilities during typical and atypical development

Organized by the University Medical Center,
Groningen, the Netherlands

May 15–17 2014

Further information:

www.developmentalneurology.com

m.hadders-algra@umcg.nl