

CASE REPORT

Neuroaspergillosis Following Postoperative Radiotherapy for Temporal Bone Squamous Cell Carcinoma

Jan Boucek, Bas Staffhorst, André Grotenhuis, Henricus Kunst

Department of ENT and HNS, Radboud University Nijmegen Medical Centre, Nijmegen, The Netherlands, H.Kunst@kno.umcn.nl (JB, BS, HK)

Department of Anaesthesiology, Radboud University Nijmegen Medical Centre, Nijmegen, The Netherlands, basstaffhorst@gmail.com (BS)

Department of Neurosurgery, Radboud University Nijmegen Medical Centre, Nijmegen, The Netherlands, J.Grotenhuis@nch.umcn.nl (AG)

Department of Otorhinolaryngology Head and Neck Surgery, First Faculty of Medicine, Charles University in Prague, University Hospital Motol, Prague, Czech Republic, jboucek99@seznam.cz (JB)

Neuroaspergillosis usually manifests in immunocompromised patients. Here we present a case report of neuroaspergillosis in an immunocompetent host after postoperative radiotherapy for squamous cell carcinoma of temporal bone.

Submitted : 09 October 2012

Revised : 28 November 2012

Accepted : 11 December 2012

Introduction

Neuroaspergillosis is a very rare clinical entity but is concerned as a serious disease, mostly presenting in immunocompromised patients or patients with diabetes, tuberculosis or after intracranial or skull base surgery^[1-3]. An infection caused by *Aspergillus fumigatus* usually extends intracranially directly from paranasal sinuses or disseminates hematogenously from distant foci, e.g. lung^[4]. Despite adequate treatment, the prognosis is very poor with a mortality approaching 100% in immunocompromised patients^[5]. In the presented case, neuroaspergillosis developed in an immunocompetent host with a history of surgery and fractionated radiotherapy for squamous cell carcinoma (SCC) of the temporal bone. We hypothesize that post-surgical defect of

the lateral skull base exposed to irradiation played a major role in the pathogenesis of the invasive aspergillosis. The preventing therapeutic possibilities are hypothesized in the article.

Case Report

A previously healthy 67 years old woman was referred to our centre in June 2006 with progressive right-sided hearing loss and otorrhoea. Otomicroscopic examination revealed an obstructive bulging of the posterior wall of the right external auditory canal. Histopathological examination confirmed the diagnosis of SCC. Computed tomography (CT) scanning showed no evident signs of bone destruction (Figure 1), the soft tissues of middle ear were involved, without convincing sign of the involvement of medial wall, but with possible soft tissue

Corresponding address:

Jan Boucek
Department of Otorhinolaryngology Head and Neck Surgery,
First Faculty of Medicine, Charles University in Prague,
University Hospital Motol, Prague, Czech Republic,
Telephone: 00-420-224434357, Fax number: 00-420-224434319,
e-mail: jboucek99@seznam.cz

Copyright 2005 © The Mediterranean Society of Otolaryngology and Audiology

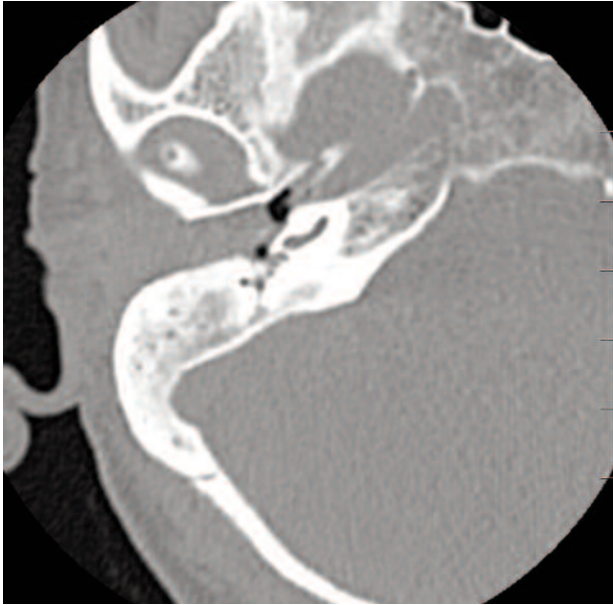


Figure 1. Initial CT scan (June 2006), axial plane, where soft tissue mass completely fills the right-sided external auditory canal and extends also into the middle ear.

involvement in the hypotympanum. Ultrasonographic evaluation of the neck and chest radiography revealed no regional or distant metastatic disease. According to the modified system of the , the tumour was preoperatively staged as cT3-4N0M0^[6,7]. The patient underwent a lateral temporal bone resection. Peroperatively, bone involvement in antrum and hypotympanum was obvious, but the tumour was resected completely, and the frozen sections showed negative lateral margins. The tumour was postoperatively staged as pT4N0M0. Because of the stage of the tumour, the patient underwent adjuvant fractionated radiotherapy with a total dose of 66 Gy.

Despite regular intensive follow-up, one year postoperatively she developed a right-sided facial palsy (House-Brackmann grade VI), and severe otalgia. Otoscopy revealed a cavity filled with multiple fungal hyphae and necrotic tissue debris, with exposed osteomyelitic bone at the bottom of the cavity. Magnetic resonance imaging (MRI) excluded tumour recurrence. She was treated with peroral ciprofloxacin (500mg/12h) in combination with decreasing dose scheme of prednisone (50 mg for three days, then reduced by 5 mg each day), and with local itraconazole. She also underwent additional hyperbaric

oxygen therapy. Because of no improvement of her facial palsy and an unfavourable state in the cavity, 5 months later she underwent subtotal petrosectomy in order to explore the field and remove osteonecrotic bone. A well vascularized temporal muscle flap and abdominal fat was employed to obliterate the cavity. All frozen sections were free of tumour. The microbiological analyses revealed an invasive infection with *Aspergillus Fumigatus* and treatment with intravenous voriconazole (8mg/kg/12h) was started.

CT, later followed by MRI (Figure 2) examinations were done due to headache and showed swelling of the temporal lobe, thromboses of the transverse and sigmoid sinuses and a hypodensity in the right temporal lobe suspicious for an intracranial abscess. Cerebrospinal fluid (CSF) examination was highly suggestive of central nervous system aspergillus infection, most likely related to the aspergillus osteomyelitis of the lateral skull base. Besides the pre-existent facial nerve paralysis, there were no signs of other neurological deficits. Therefore, conservative treatment with intravenous voriconazole (8mg/kg every 12h) continued, monitoring its therapeutic level (above 2mg/L) in blood and CSF^[5]. Weekly MRI scans were done to verify the effect of treatment. After three months the abscess showed no signs of regression (Figure 3) and neurosurgical intervention with drainage was performed. Histopathological and microbiological examinations confirmed the diagnosis neuroaspergillosis. The postoperative course was without any complication, intravenous treatment with voriconazole for two weeks was followed with oral administration of the drug for more than six months.

Five months later, she presented with a progressive preauricular and infraauricular swelling, accompanied by oedema of the right side of the face and neck since three weeks. She had also lost weight and complained of a significant decline in her physical status. MRI showed a probable recurrence in the right parotid gland, pterygoid fossa and the temporo-mandibular joint regions in addition to the metastatic spread to the regional lymph nodes in the level II verified with a fine needle aspiration biopsy. No curative options were left and she died in 3 months later.

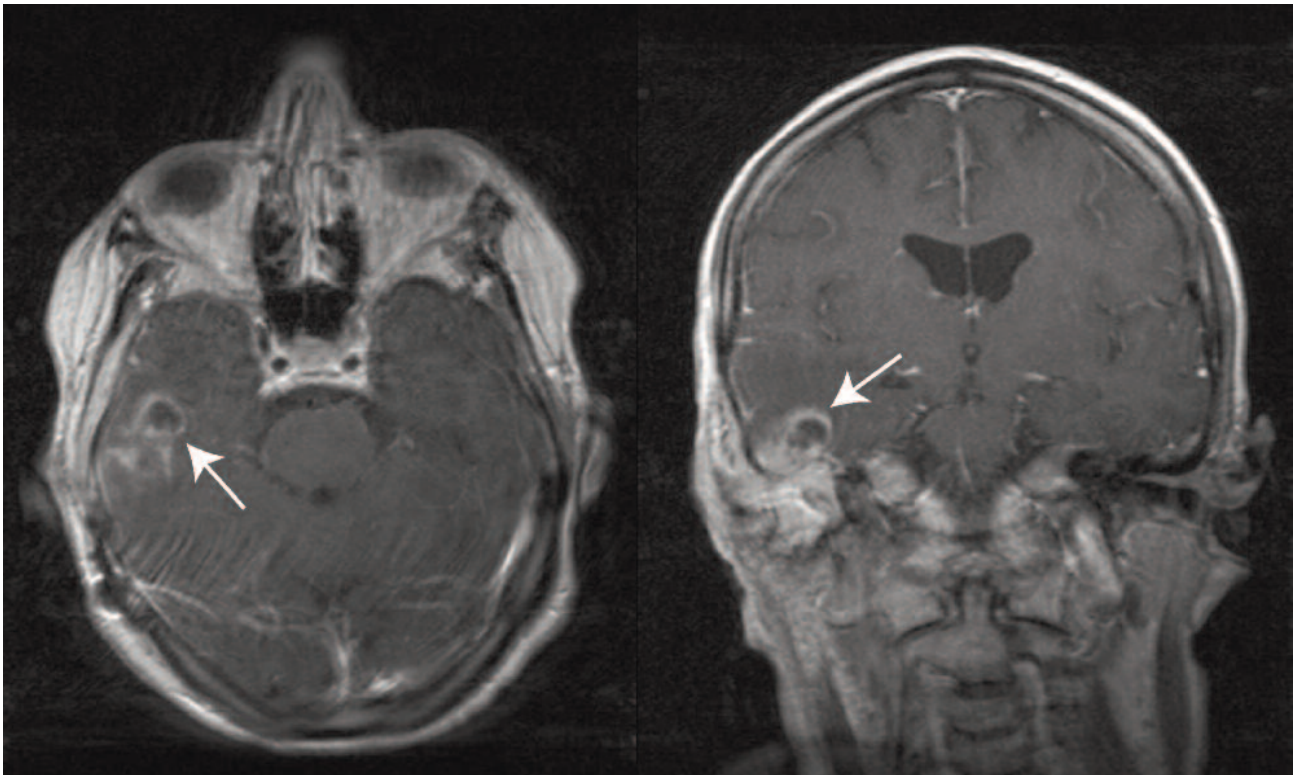


Figure 2. MRI scan (T1W + flowcomp, axial and coronal plane) was taken 5 days after the subtotal petrosectomy (January 2008). The arrows indicate the presence of an intracranial abscess.

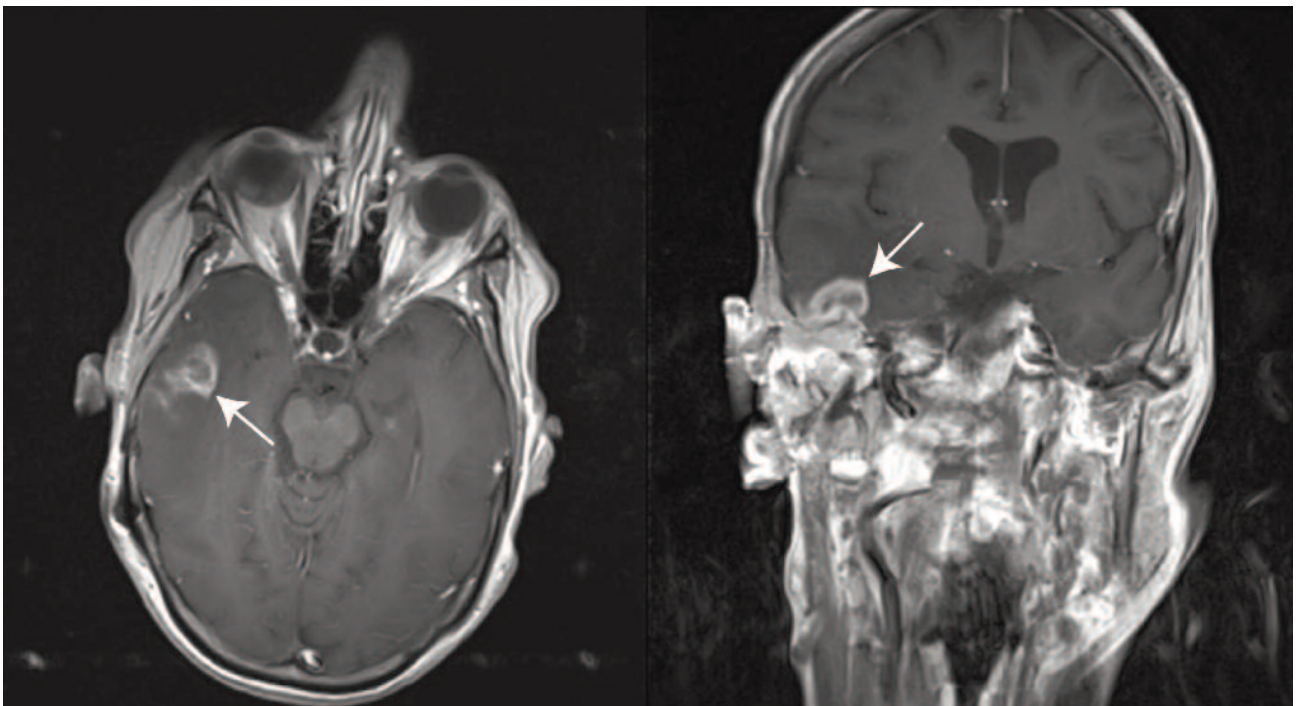


Figure 3. Unchanged MRI scan (T1W + flowcomp, axial and coronal plane) before the neurosurgical intervention and drainage (March 2008). The arrows indicate the presence of an intracranial abscess.

Discussion

Neuroaspergillosis is a very rare disease, even in immunocompromised patients. Low local complement synthesis and activation may represent a central reason for the insufficient defence in the brain of patients with neuroaspergillosis, causing the almost 100 % mortality of this disease^[8]. Only few cases have been described in the literature involving immunocompetent hosts^[9-11].

Intracranial involvement by aspergillus species occurs via haematogenous dissemination from the lungs, extension from paranasal sinuses, or by direct introduction at time of surgery. Haematogenous dissemination from a pulmonary focus is the most frequent cause of neuroaspergillosis, almost only involving immunocompromised patients. In the present case, pulmonary etiology was ruled out by the chest x-ray. Extension from paranasal sinuses is a more frequent cause in immunocompetent patients, but seemed highly unlikely because neither physical examination nor imaging findings showed any evidence of paranasal sinuses disease.

In this case, the possibility of direct introduction during surgery also seems implausible. Moreover, there was a small CSF leak during subtotal petrosectomy for salvage surgery, but the leak was directly plugged by periosteum, and the time interval between surgery and MRI diagnosis of intracranial abscess was thought to be very short (11 days) for an iatrogenic situation. In literature, the average time between surgery and diagnosis of a postoperative abscess was 3 months (1 to 12 months)^[3]. Therefore, it is more likely that the aspergillus invaded the central nervous system before the time of surgery, which was also supported by the retrospective findings on CT scan (i.e. thrombosis of the sigmoid and transverse sinus, Figure 4).

We suggest that the neuroaspergillosis of this patient was caused by extension of the invasive aspergillus infection from the temporal bone. We can hypothesise that the invasive effect of the SCC^[12] and post-operative radiotherapy caused a local immune attenuation which enabled the aspergillus fumigatus to invade intracranially, probably by a haematogenous pathway. Lateral skull base osteomyelitis caused by aspergillus had been described in

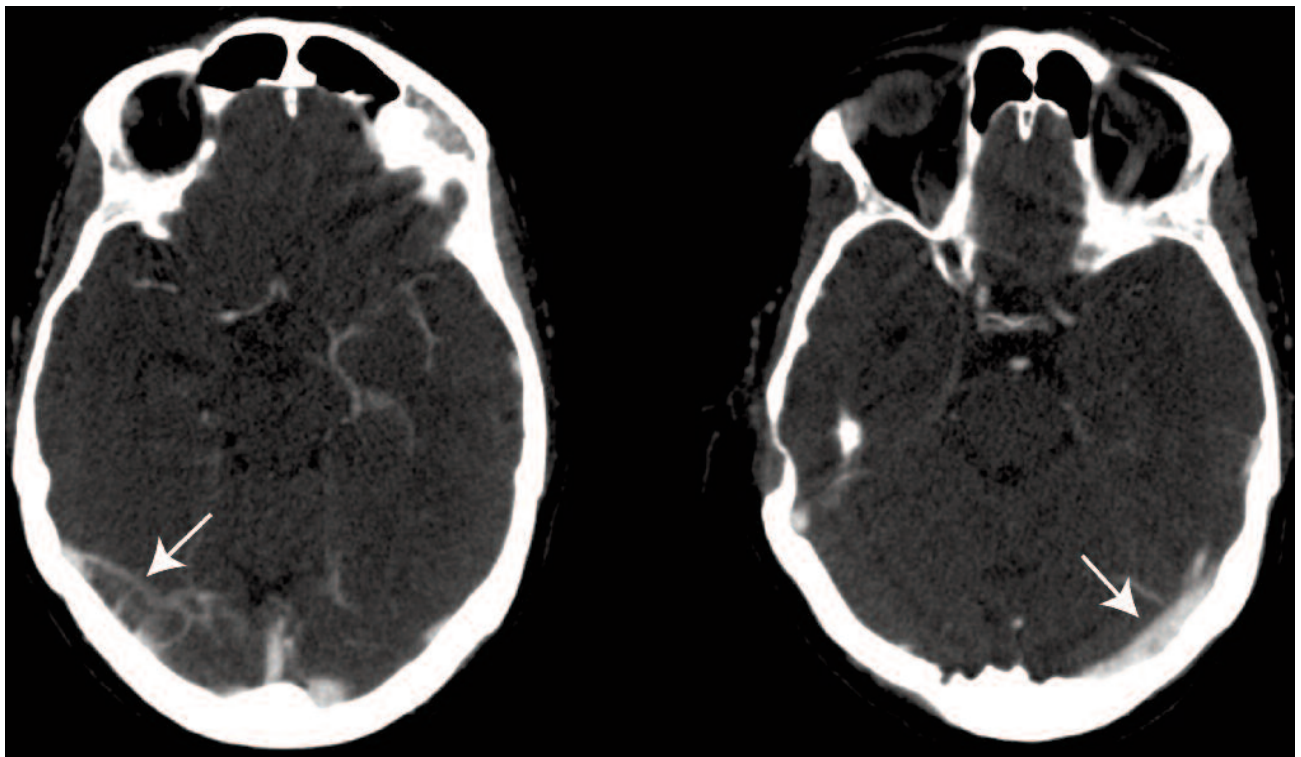


Figure 4. CT scan (August 2007) with contrast in the axial plane showing a thrombosis of the transverse sinus on the right site. Arrows indicate the position of the transverse sinus, no flow is visible on the right side.

immunocompetent hosts^[1] and also aspergillus infections were reported following radiotherapy in the other parts of the body^[2]. Nevertheless, there was no reported case in literature, where the invasive intracranial aspergillus infection would follow the irradiation of the temporal bone in an immunocompetent patient.

Based on our previous experience^[13] and with the knowledge of the clinical course in this particular case, we optimized our therapeutic strategy for the patients who should undergo temporal bone resection and post-operative radiotherapy because of SCC of the temporal bone.

In concordance with other authors^[14], we consider a lateral temporal bone resection, sometimes with parotidectomy (superficial or total based on the T stage) and neck dissection (if clinically positive) as the optimal treatment. The surgery is always followed by radiotherapy in T2 and larger tumours, and in those with perineural or vascular invasion, positive margins or cervical metastases. The cavity after lateral temporal bone resection needs adequate coverage to prevent osteoradionecrosis, colonisation with aggressive fungal and bacterial strains and potential spread of this infection, mainly intracranially. Abdominal fat obliteration combined with temporal muscle flap reconstruction is considered to be the best option^[15, 16].

Nevertheless, it is obvious that oncologic follow-up is compromised by the obliteration technique. However, consequent postoperative MRI scanning, in four to six months intervals (after baseline MRI three months postoperatively) would be an acceptable alternative. The complete eradication of the disease in the first attempt, including reconstruction, must be preferred because the efficacy of the treatment of recurrent tumours is very poor^[13, 14].

Hearing is more impaired than when leaving an open cavity, which however can be overcome by placing a bone conduction device.

Conclusion

Key learning points of this case are that a life-threatening disease as neuroaspergillosis can occur in an immunocompetent host and might be related to postoperative radiation therapy. This should always be considered in patients with a history of irradiation of the

lateral skull base. Moreover, in patients undergoing a temporal bone resection for SCC of the temporal bone, obliteration of the cavity by abdominal fat and or by local temporal muscle flap could be performed to prevent invasive aspergillosis or other invasive fungal or bacterial strains to colonize a cavity with the potential risk of spread of the infection.

Acknowledgement

The work was supported by the grants IGA MZ CR (grant NT/11542-6 and NT/11543-6) and by the Charles University in Prague, Project for support of Specific University Research No. 262510.

References

1. Marzo, S.J. and J.P. Leonetti. Invasive fungal and bacterial infections of the temporal bone. *Laryngoscope* 2003; 113: 1503-7.
2. Ogawa, Y., N. Nishiyama, A. Hagiwara, T. Ami, H. Fujita, T. Yoshida, et al. A case of laryngeal aspergillosis following radiation therapy. *Auris Nasus Larynx* 2002; 29: 73-6.
3. Pasqualotto, A.C. and D.W. Denning. Post-operative aspergillosis. *Clin Microbiol Infect* 2006; 12:1060-76.
4. Siddiqui, A.A., A.A. Shah, and S.H. Bashir. Craniocerebral aspergillosis of sinonasal origin in immunocompetent patients: clinical spectrum and outcome in 25 cases. *Neurosurgery* 2004; 55: 602-11; discussion 611-3.
5. Schwartz, S., M. Ruhnke, P. Ribaud, L. Corey, T. Driscoll, O.A. Cornely, et al. Improved outcome in central nervous system aspergillosis, using voriconazole treatment. *Blood* 2005; 106: 2641-5.
6. Moody, S.A., B.E. Hirsch, and E.N. Myers. Squamous cell carcinoma of the external auditory canal: an evaluation of a staging system. *Am J Otol* 2000; 21:582-8.
7. Gillespie, M.B., H.W. Francis, N. Chee, and D.W. Eisele. Squamous cell carcinoma of the temporal bone: a radiographic-pathologic correlation. *Arch Otolaryngol Head Neck Surg* 2001; 127: 803-7.
8. Rambach, G., M. Hagleitner, I. Mohsenipour, C. Lass-Flörl, H. Maier, R. Würzner, et al. Antifungal activity of the local complement system in cerebral aspergillosis. *Microbes Infect* 2005; 7: 1285-95.

9. Kose, S., G. Cavdar, S.S. Senger, and G. Akkoçlu. Central nervous system aspergillosis in an immunocompetent patient. *J Infect Dev Ctries* 2011; 5:313-5.
10. Iyeyasu, J.N., F. Reis, A.M. Altemani, and K.M. Carvalho. Intracranial and orbital aspergillosis in immunocompetent patient. *Arq Neuropsiquiatr* 2011; 69:41.
11. Hiraga, A., A. Uzawa, M. Shibuya, T. Numata, S. Sunami, and I. Kamitsukasa. Neuroaspergillosis in an immunocompetent patient successfully treated with voriconazole and a corticosteroid. *Intern Med* 2009; 48:1225-9.
12. Schreiber, R.D., L.J. Old, and M.J. Smyth. Cancer immunoediting: integrating immunity's roles in cancer suppression and promotion. *Science* 2011;331:1565-70.
13. Kunst, H., J.P. Lavieille, and H. Marres. Squamous cell carcinoma of the temporal bone: results and management. *Otol Neurotol* 2008;29:549-52.
14. Gidley, P.W., D.B. Roberts, and E.M. Sturgis. Squamous cell carcinoma of the temporal bone. *Laryngoscope* 2010;120:1144-51.
15. Marzo, S.J., B. Benschoter, and J.P. Leonetti. Contemporary options for lateral skull base reconstruction following tumour extirpation. *Curr Opin Otolaryngol Head Neck Surg* 2011;19:330-4.
16. Benschoter, B.J., J.J. Jaber, M.L. Kircher, S.J. Marzo, and J.P. Leonetti. Osseointegrated implant applications in cosmetic and functional skull base rehabilitation. *Skull Base* 2011;21:303-8.