

Pulmonary Perifissural Nodules on CT Scans: Rapid Growth Is Not a Predictor of Malignancy¹

Bartjan de Hoop, MD, PhD
Bram van Ginneken, PhD
Hester Gietema, MD, PhD
Mathias Prokop, MD, PhD

Purpose:

To assess the prevalence, natural course, and malignancy rate of perifissural nodules (PFNs) in smokers participating in a lung cancer screening trial.

Materials and Methods:

As part of the ethics-committee approved Dutch-Belgian Randomised Lung Cancer Multi-Slice Screening Trial (NELSON), computed tomography (CT) was used to screen 2994 current or former heavy smokers, aged 50–74 years, for lung cancer. CT was repeated after 1 and 3 years, with additional follow-up CT scans if necessary. All baseline CT scans were screened for nodules. Nodule volume was determined with automated volumetric analysis. Homogeneous solid nodules, attached to a fissure with a lentiform or triangular shape, were classified as PFNs. Nodules were considered benign if they did not grow during the total follow-up period or were proved to be benign in a follow-up by a pulmonologist. Prevalence, growth, and malignancy rate of PFNs were assessed.

Results:

At baseline screening, 4026 nodules were detected in 1729 participants, and 19.7% (794 of 4026) of the nodules were classified as PFNs. The mean size of the PFNs was 4.4 mm (range: 2.8–10.6 mm) and the mean volume was 43 mm³ (range: 13–405 mm³). None of the PFNs were found to be malignant during follow-up. Between baseline and the first follow-up CT scan, 15.5% (123 of 794) were found to have grown, and 8.3% (66 of 794) had a volume doubling time of less than 400 days. One PFN was resected and proved to be a lymph node.

Conclusion:

PFNs are frequently found at CT scans for lung cancer. They can show growth rates in the range of malignant nodules, but none of the PFNs in the present study turned out to be malignant. Recognition of PFNs can reduce the number of follow-up examinations required for the workup of suspicious nodules.

© RSNA, 2012

¹From the Department of Radiology, Rijnstate Hospital, Wagnerlaan 55, 6815 AD, Arnhem, the Netherlands (B.d.H.); Department of Radiology (B.d.H., H.G., M.P.) and Image Sciences Institute (B.v.G.), University Medical Center, Utrecht, the Netherlands; and Department of Radiology, Radboud University Nijmegen Medical Center, Nijmegen, the Netherlands (B.v.G., M.P.). Received November 5, 2011; revision requested January 11, 2012; revision received March 13; accepted May 1; final version accepted May 18. Address correspondence to B.d.H. (e-mail: BdeHoop@rijnstate.nl).

The detection of small pulmonary nodules has increased with the introduction of multidetector computed tomography (CT); noncalcified nodules are detected in up to 69% of asymptomatic smokers who participate in lung cancer screening trials. Smokers are selected for screening trials because they are at increased risk for developing lung cancer, but this group's malignancy rate of noncalcified nodules is only 1.0%–3.6% (1–4). Due to the prevalence of detected indeterminate nodules and their small size, physicians distinguish potentially malignant nodules from those that are benign by assessing their growth on follow-up CT scans. The negative aspects of this follow-up strategy include patient anxiety, cost, and radiation burden on the affected population.

Several characteristics could help reduce the number of follow-up CT scans for suspicious nodules, such as broad-based attachment to the pleura, attachment to vessels, and perifissural location (5,6). Ahn et al (5) reported that none of the perifissural nodules (PFNs) detected in their lung cancer screening trial turned out to be malignant during follow-up. If PFNs

are benign and can be reliably recognized, their identification may reduce the number of follow-up examinations. PFNs may represent lymph nodes (7); therefore, PFNs may show a growth rate similar to that of malignant nodules on follow-up CT scans. We hypothesized that the growth of PFNs is not a sign of malignancy and that growing PFNs will decrease in size on further follow-up CT images. Therefore, we studied all intraparenchymal noncalcified nodules that were detected in a lung cancer screening trial. The detected noncalcified nodules were classified as either parenchymal nodules or PFNs. The purpose of this study was to assess the prevalence, natural course, and malignancy rate of PFNs in smokers participating in a lung cancer screening trial.

Materials and Methods

Study Participants

The Dutch-Belgian Randomised Lung Cancer Screening Trial (NELSON) was approved by the Netherlands Ministry of Health, and a waiver was received for this part of the study. All participants at one of the study sites (University Medical Center, Utrecht, the Netherlands) were included. All participants were either current or former heavy smokers and were between the ages of 50 and 75 years (8).

All participants underwent baseline screening with low-dose CT scanners according to the NELSON protocol as previously described (9). In short, all CT studies were screened for noncalcified nodules by independent first and second readers. The experience of the first readers ranged from none to more than

20 years of experience reading thoracic CT scans (median, 6 years); the second readers had 6 years of experience. Maximum intensity projection images were used to improve the detection of nodules. Nodules were reported if their volume met or exceeded 15 mm³ (~3 mm in diameter). This study included all nodules that were found by at least one observer, while the overall results of the NELSON study only included lesions that were found by one observer and confirmed as a nodule by a second observer. The volumes of all detected nodules were determined by using volumetric software (Lungcare Somaris/5 VB 10A; Siemens, Erlangen, Germany). Variability for measuring nodule volume with this particular software proved not to be substantially influenced by nodule volume in previous research (10).

Patients with a nodule larger than 500 mm³ (~9.8 mm in diameter) were immediately referred to a pulmonologist for further examination. Patients with at least one nodule measuring between 50 and 500 mm³ (5.0–9.8 mm in diameter) underwent a 3-month follow-up CT scan. All patients who had nodules with a volume doubling time (VDT) between 20 and 400 days were also referred to a pulmonologist. The pulmonologist decided whether resection was necessary.

Advances in Knowledge

- Perifissural nodules (PFNs) represented 19.7% (794 of 4026) of all detected nodules in a large lung cancer screening trial in heavy smokers.
- None of the PFNs turned out to be malignant after 5.5 years of follow-up.
- The malignancy rate in fissure-attached nodules that did not meet the PFN criteria for shape, margin, or homogeneity was 1.7% (four of 230).
- Volume doubling times of less than 400 days were found in 8.3% (66 of 794) of PFNs but were not a sign of malignancy in a smoker population without known extrathoracic malignancy participating in a screening study.

Implications for Patient Care

- PFNs detected in asymptomatic heavy smokers participating in a screening study are almost certainly benign and do not require follow-up.
- Recognition of PFNs can reduce the number of follow-up examinations performed for the work-up of suspicious nodules.

Published online before print

10.1148/radiol.12112351 **Content codes:** GH CT

Radiology 2012; 265:611–616

Abbreviations:

CI = confidence interval
 NELSON = Dutch-Belgian Randomised Lung Cancer Screening Trial
 PFN = perifissural nodule
 VDT = volume doubling time

Author contributions:

Guarantors of integrity of entire study, B.d.H., M.P.; study concepts/study design or data acquisition or data analysis/interpretation, all authors; manuscript drafting or manuscript revision for important intellectual content, all authors; approval of final version of submitted manuscript, all authors; literature research, B.d.H., H.G., M.P.; clinical studies, all authors; experimental studies, B.v.G.; statistical analysis, B.d.H., M.P.; and manuscript editing, B.d.H., H.G., M.P.

Conflicts of interest are listed at the end of this article.

Regular CT screening was repeated as part of the NELSON trial 1, 3, and 5.5 years after baseline. All patients were followed up during this period, and nodules that did not meet the criteria for referral during the 5.5-year follow-up period were considered benign, as were nodules that proved to be benign after examination by a pulmonologist. The patients' medical histories were taken, and they underwent a physical examination, positron emission tomography, and bronchoscopy. CT-guided biopsy was performed on nodules that were suspected of being malignant. The first follow-up scan—either a regular scan at 1 year or an additional follow-up CT scan at 3 months—was used to study growth rates of PFNs detected at baseline.

Acquisition and Evaluation of CT Scans

All CT scans were obtained with a 16-detector row CT system (Mx8000 IDT 16; Philips Medical Systems, Cleveland, Ohio) by using a spiral mode with 16×0.75 -mm collimation. Exposure settings were 30 mAs at 120 kVp for patients weighing 80 kg or less and 30 mAs at 140 kVp for patients weighing more than 80 kg. No intravenous contrast material was used. Axial images were reconstructed at 1.0-mm thickness and 0.7-mm increment by using a moderately soft reconstruction kernel (B kernel; Philips Medical Systems) and the smallest field of view that included the outer rib margins and a 512×512 matrix.

Definition of PFNs

Some investigators have suggested that subpleural nodules are actually intrapulmonary lymph nodes. Intrapulmonary lymph nodes have a lentiform or triangular shape, a homogeneous solid appearance, and sharp margins. It is not clear whether these lymph nodes can be safely identified. We aimed to do so by matching the definition of a PFN to the morphologic features previously described for intrapulmonary lymph nodes (7,11–13).

Pulmonary nodules were classified as typical PFN, atypical PFN, or non-PFN (Fig 1). Similar to the description of intrapulmonary lymph nodes

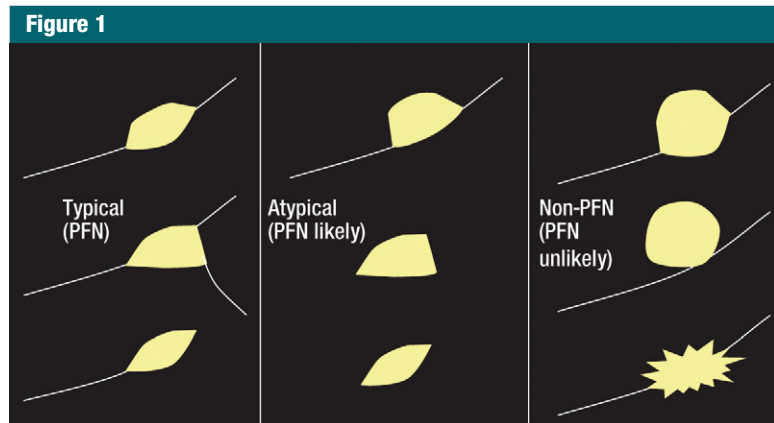


Figure 1: Fissure-attached nodules that met previously described features of intrapulmonary lymph nodes were defined as typical PFNs. Atypical PFNs were nodules that either met all features but were not attached to a visible fissure or were fissure-attached nodules, convex on one side and rounded on the other. All other fissure-attached nodules with a shape that did not appear to be influenced by the fissure were defined as non-PFN.

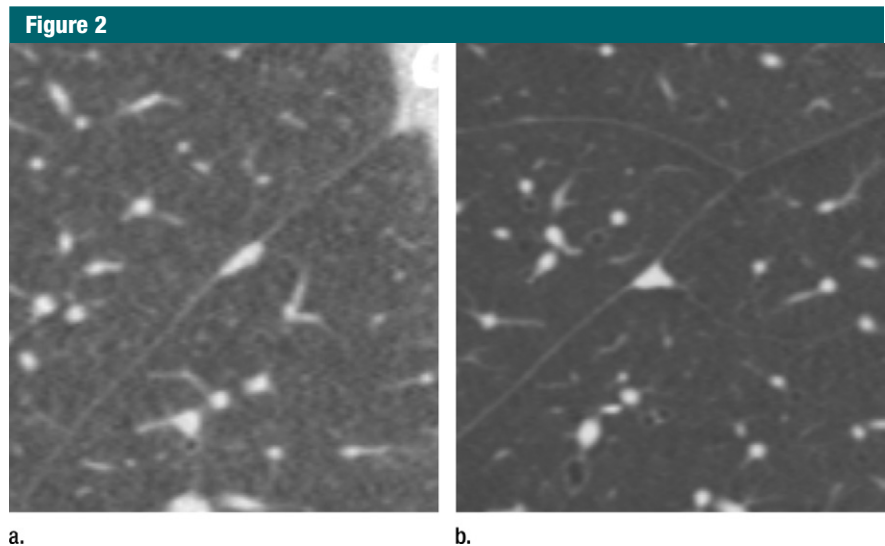


Figure 2: Sagittal CT images show examples of typical PFNs with (a) lentiform or (b) triangular shape.

(7,11–13), we defined a *typical PFN* as a fissure-attached, homogeneous, solid nodule that had smooth margins and an oval, lentiform, or triangular shape (Fig 2).

Atypical PFNs usually had a perifissural location. We defined *atypical PFNs* as nodules that met all of the features of typical PFNs but were not visibly attached to a fissure. The fissure may have been absent or too thin to be visible with CT. Also defined as atypical

PFNs were fissure-attached nodules, convex on one side and rounded on the other, which suggested that they were not influenced by the fissure (Fig 1).

All other nodules were defined as *non-PFN*. This included nodules that showed features typical of malignancy, like spiculation. Spherical nodules were also classified as non-PFN because a spherical shape suggests that the nodule is not influenced by the fissure, but is instead growing through the fissure.

Classification of PFNs

The NELSON protocol did not include classification of nodules into PFN or non-PFN categories. Therefore, all baseline nodules were reevaluated twice by two independent sets of observers. The observers were six medical students trained to recognize PFNs. Before the observers began to evaluate the nodules, they practiced characterizing nodules and were administered an identification test, in which they had to correctly label at least 95% of 200 randomly chosen nodules derived from the study set. These 200 nodules were detected during baseline screening and previously labeled by a radiologist who had over 20 years of experience in the field (M.P.). Nodules were prospectively labeled; the observers had no knowledge of the nodule's outcome or prevalence of disease. All baseline CT images were viewed at a window width of 1400 HU and a window level of -650 HU, and in orthogonal planes because lentiform PFNs may easily be misinterpreted as round in a plane perpendicular to the long axis of the nodule. If the two observers disagreed, consensus was established with a third observer—a radiology researcher with more than 3 years of experience evaluating lung cancer screening studies and who had performed over 1000 CT examinations (B.d.H.). Nodule shape was determined and categorized as lentiform, triangular, spherical, or irregular. A nodule was defined as *lentiform* when it had a biconvex, lenslike shape. Three-cornered nodules were defined as *triangular*. *Spherical nodules* were defined as such because they had an approximately constant radius. All other shapes were defined as *irregular*. For each PFN, the observers determined whether the PFN was connected to the major fissure, minor fissure, or an accessory or rudimentary fissure. We did not differentiate between accessory and rudimentary fissures, and henceforth these will be referred to as *accessory fissures*.

Definition of Nodule Growth

Volume change between baseline and the first follow-up CT scan was assessed. Growth or regression of a nodule was defined as a discernable

increase or decrease in volume between the baseline and first follow-up CT scan (ie, a difference larger than the variability in the measurement). The 95% limits of agreement in variability for measuring volume with our software have previously been reported to be $\pm 22.3\%$ (14).

Statistical Analysis

No formal hypothesis testing was conducted in this study. Calculations of means, volume changes, and VDTs were performed by using Microsoft Excel (Microsoft, Redmond, Washington). The 95% confidence interval (CI) provided for the number of benign PFNs was calculated by using exact statistics.

Results

Baseline

In total, 2994 participants (2478 men and 516 women) underwent baseline CT screening in our hospital (University Medical Center Utrecht, Utrecht, the Netherlands). At least one noncalcified nodule was found in 1729 (57.7%) participants. The number of nodules per patient varied from one to 20, resulting in a total of 4026 nodules.

Of all baseline detected nodules, 19.7% (794 of 4026) were classified as typical PFNs. Consensus in the decision to label nodules as PFN was needed in 5.0% (200 of 4026) of the nodules. Multiple typical PFNs were seen in 133 patients: 96 patients had two PFNs, 22 patients had three PFNs, and 15 patients had four to seven PFNs. Mean volume was 43 mm^3 (95% CI: 41 mm^3 , 44 mm^3 ; range: 13–405 mm^3) with a mean diameter of 4.4 mm (95% CI: 4.4 mm, 4.5 mm; range: 2.8–10.6 mm). A maximum diameter exceeding 4 mm was seen in 56.2% (446 of 794) of typical PFNs. Note that the diameters were calculated from nodule volume and are estimates, because most nodules were not perfectly round. Typical PFNs were most frequently located in the left major fissure ($n = 254$), 240 were situated in the right minor fissure, 213 in the right major fissure, and 87 in an accessory fissure in the left or right lung. The shape of the typical PFN

was lentiform in 444 cases and triangular in 350 cases.

Of all detected nodules, 3.1% (125 of 4026) were classified as atypical PFNs. Atypical PFNs were seen in 118 patients. The average volume of these atypical PFNs was 51 mm^3 (95% CI: 48 mm^3 , 54 mm^3 ; range: 15–216 mm^3) and the average maximum diameter was 4.7 mm (95% CI: 4.6 mm, 4.8 mm; range: 2.9–8.2 mm). The typical shape was found in 42 atypical PFNs that lacked visible attachment to a fissure. The remaining 83 atypical PFNs were attached to a visible fissure but were only flattened at the side of the fissure. Thirty-four of all typical and atypical PFNs were found in patients that developed lung cancer from a nodule other than the PFN during the follow-up period. Another 230 nodules were found to be fissure-attached but were classified as non-PFN because of shape, margin, or inhomogeneous appearance.

Follow-up

The malignancy rate in all participants in the NELSON trial was 1.7% (127 of 7557) after 2 years of screening (15). In our study population, 0% of the nodules labeled typical or atypical PFN at baseline were found to be malignant during the 5.5 years of follow-up (95% CI: 0%, 0.5%). There were no malignancies found in the 200 nodules that were labeled typical or atypical PFN by only one of the two observers. One growing PFN was resected and proved to be an intrapulmonary lymph node (Fig 3). Four malignancies were attached to a fissure; all were classified as non-PFN at baseline.

Volume Change from Baseline to First Follow-up CT

The average duration between baseline and first follow-up CT scan was 223 days (95% CI: 219, 227; range: 63–464). Significant loss in volume was shown at follow-up in 8.6% (79 of 919) of both typical and atypical PFNs and 25.4% (233 of 919) were no longer reported, indicating that they had either totally regressed or had decreased in size below the 15- mm^3 threshold for reporting nodules. In total, 279 typical and 33 atypical PFNs showed regression (Table).

A stable volume was seen in 50.5% (464 of 919) of PFNs.

Growth was seen in 15.5% (123 of 794) of the typical PFNs and in 16.0% (20 of 125) of the atypical PFNs. The average VDT in the typical PFNs was 474 days (95% CI: 462, 485; range: 61–1225). From baseline to the first follow-up CT scan, 8.3% (66 of 794) of the typical PFNs had VDTs that were less than 400 days. The average VDT in the growing atypical PFNs was 630 days (95% CI: 598, 662; range: 72–1164) with 5.6% (seven of 125) showing a VDT less than 400 days.

Within this group of 73 typical and atypical PFNs with a VDT of less than 400 days, regression was seen in 26 between the second and third CT scans. Five PFNs showed growth and 42 PFNs remained stable in volume. None of the typical or atypical PFNs had a VDT of less than 400 days during the total follow-up period of the study.

Discussion

Pulmonary nodules are a common finding on CT scans for lung cancer (4). We found that 22.8% (919 of 4026) of all detected nodules fulfilled the predefined criteria for a typical or atypical PFN. In this population with no known extrathoracic malignancy, none of these PFNs proved to be malignant during the 5.5-year follow-up.

The low potential for malignancy has previously been described by Ahn et al (5). They reported that none of the 234 PFNs that were detected in smokers were malignant. The majority of the nodules in their study were less than 5 mm in diameter, with a low likelihood of malignancy. We showed that those results are also applicable for PFNs in the range of 5–10 mm.

Follow-up CT scans are needed to assess growth rate because growth rate effectively differentiates between benign and malignant nodules. Malignant solid nodules have a VDT of around 150 days (16), while benign nodules slowly change in size or remain stable. A recent report that used VDTs to differentiate nodules showed that this approach has a sensitivity of 98.6% with a specificity of 98.3%

Change in Volume from Baseline to First Follow-up CT for all PFNs

Type of Change	Typical PFNs (n = 794)	Atypical PFNs (n = 125)
Regression	279 (35.1)	33 (26.4)
Stable	392 (49.4)	72 (57.6)
Growth	123 (15.5)	20 (16.0)
VDT > 400 d*	57 (7.2)	13 (10.4)
VDT < 400 d*	66 (8.3)	7 (5.6)

Note.—Numbers in parentheses are percentages.

* VDTs are given for those PFNs that showed growth.

(15). In the previous study by Ahn et al, PFNs were measured with electronic calipers and growth was found in only seven of 234 PFNs. In the present study, volume was determined for all detected nodules, enabling a precise quantification of nodule growth expressed as VDT. Using this method of growth quantification, we found that 15.5% (123 of 794) of the typical PFNs showed a discernible increase in volume (ie, PFNs grew more than 22.3%). Moreover, several of the typical PFNs (8.3%) had a VDT of fewer than 400 days—a threshold that is commonly accepted to indicate malignant growth. Our results show that, because none of the PFNs were malignant, even rapidly growing PFNs are still very likely to be benign in a population without known cancer.

We matched our definition of PFNs to the morphologic features previously described for intrapulmonary nodules. Whether all typical PFNs indeed represent lymph nodes is not certain; in our study, the single PFN that was resected proved to be an intrapulmonary lymph node. The large differences in growth rates among PFNs also seemed to indicate that they were lymph nodes because of their reaction to various stimuli (they may expand or regress). Based on evidence that includes the similarities to morphologic features on CT scans, growth rate, and the resected PFN, it is likely that the majority of PFNs indeed represent lymph nodes.

Many nodules that were attached to a fissure were not labeled as PFN because of their shape or margin. Attachment to a fissure does not exclude

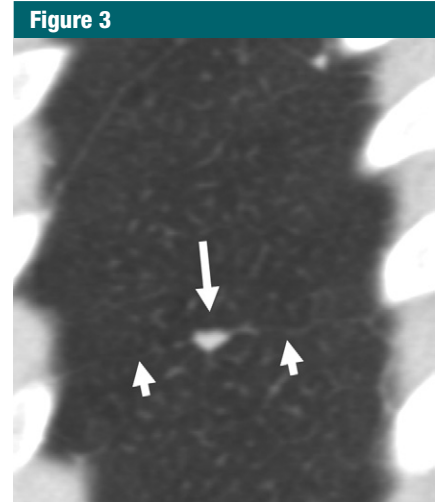


Figure 3: Sagittal CT image of one PFN that was resected (large arrow). This PFN increased from 150 to 180 mm³ in 3 months, a VDT of 270 days. Nodule was marked with a CT-guided needle and wedge resection was performed. Histologic evaluation showed a lymph node. Note that the PFN is attached to an accessory fissure (small arrows).

malignancy—four malignant nodules were found attached to a fissure. An example is shown in Figure 4. This nodule was classified non-PFN because it was neither sharply demarcated nor shaped like a PFN. The round shape with the concave connection to the fissure suggested that this nodule was not originally attached to a fissure. It was likely a parenchymal nodule that coincidentally grew next to a fissure. We found that none of the atypical PFNs were malignant; this result makes the discrimination between typical and atypical PFNs less important. However, when

Figure 4

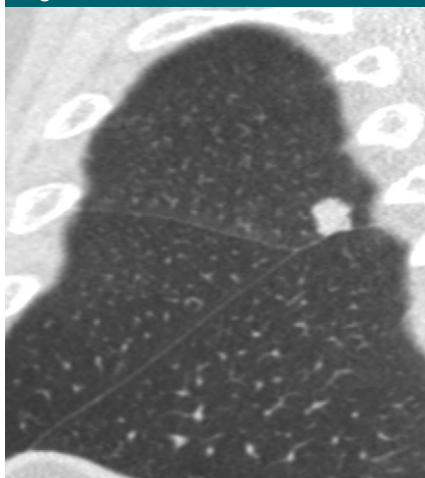


Figure 4: Sagittal CT image shows adenocarcinoma connected to a pulmonary fissure. Note the margins and that the nodule, unlike PFNs, is flattened at only one side.

classifying a nodule as either atypical or non-PFN, follow-up CT scans should be considered.

This study was limited by the lack of pathology results to support the hypothesis that PFNs represent intrapulmonary lymph nodes. Nevertheless, none of nodules that met the criteria for PFNs proved to be malignant or showed a malignant growth rate for the total follow-up period, and these PFN criteria may already distinguish nodules that are almost certainly benign. A second limitation was the use of medical students instead of radiologists to label the nodules. However, the students were well trained, and all nodules were labeled twice by two separate observers. Finally, we found that shape was sometimes difficult to distinguish for the very small nodules.

In conclusion, we found that PFNs, defined as fissure-attached solid nodules

with a lentiform or triangular shape, represented almost 20% of all detected nodules in our lung cancer screening. PFNs are almost certainly benign and likely represent lymph nodes. VDTs less than 400 days are not uncommon in PFNs and are not predictors of malignancy. Recognition of PFNs can reduce the number of follow-up CT scans needed for screen-detected nodules.

Disclosures of Conflicts of Interest: **B.d.H.** No relevant conflicts of interest to disclose. **B.v.G.** No relevant conflicts of interest to disclose. **H.G.** No relevant conflicts of interest to disclose. **M.P.** No relevant conflicts of interest to disclose.

References

- Diederich S, Thomas M, Semik M, et al. Screening for early lung cancer with low-dose spiral computed tomography: results of annual follow-up examinations in asymptomatic smokers. *Eur Radiol* 2004;14(4):691-702.
- Henschke CI, Yankelevitz DF, Mirtcheva R, et al. CT screening for lung cancer: frequency and significance of part-solid and nonsolid nodules. *AJR Am J Roentgenol* 2002;178(5):1053-1057.
- Swensen SJ, Jett JR, Hartman TE, et al. Lung cancer screening with CT: Mayo Clinic experience. *Radiology* 2003;226(3):756-761.
- National Lung Screening Trial Research Team, Aberle DR, Adams AM, et al. Reduced lung-cancer mortality with low-dose computed tomographic screening. *N Engl J Med* 2011;365(5):395-409.
- Ahn MI, Gleeson TG, Chan IH, et al. Perifissural nodules seen at CT screening for lung cancer. *Radiology* 2010;254(3):949-956.
- Xu DM, van der Zaag-Loonen HJ, Oudkerk M, et al. Smooth or attached solid indeterminate nodules detected at baseline CT screening in the NELSON study: cancer risk during 1 year of follow-up. *Radiology* 2009;250(1):264-272.
- Matsuki M, Noma S, Kuroda Y, Oida K, Shindo T, Kobashi Y. Thin-section CT features of intrapulmonary lymph nodes. *J Comput Assist Tomogr* 2001;25(5):753-756.
- van Iersel CA, de Koning HJ, Draisma G, et al. Risk-based selection from the general population in a screening trial: selection criteria, recruitment and power for the Dutch-Belgian randomised lung cancer multi-slice CT screening trial (NELSON). *Int J Cancer* 2007;120(4):868-874.
- Xu DM, Gietema H, de Koning H, et al. Nodule management protocol of the NELSON randomised lung cancer screening trial. *Lung Cancer* 2006;54(2):177-184.
- Gietema HA, Schaefer-Prokop CM, Mali WP, Groenewegen G, Prokop M. Pulmonary nodules: Interscan variability of semiautomated volume measurements with multi-section CT— influence of inspiration level, nodule size, and segmentation performance. *Radiology* 2007;245(3):888-894.
- Yokomise H, Mizuno H, Ike O, Wada H, Hitomi S, Itoh H. Importance of intrapulmonary lymph nodes in the differential diagnosis of small pulmonary nodular shadows. *Chest* 1998;113(3):703-706.
- Bankoff MS, McEniff NJ, Bhadelia RA, Garcia-Moliner M, Daly BD. Prevalence of pathologically proven intrapulmonary lymph nodes and their appearance on CT. *AJR Am J Roentgenol* 1996;167(3):629-630.
- Miyake H, Yamada Y, Kawagoe T, Hori Y, Mori H, Yokoyama S. Intrapulmonary lymph nodes: CT and pathological features. *Clin Radiol* 1999;54(10):640-643.
- de Hoop B, Gietema H, van Ginneken B, Zanen P, Groenewegen G, Prokop M. A comparison of six software packages for evaluation of solid lung nodules using semi-automated volumetry: what is the minimum increase in size to detect growth in repeated CT examinations. *Eur Radiol* 2009;19(4):800-808.
- van Klaveren RJ, Oudkerk M, Prokop M, et al. Management of lung nodules detected by volume CT scanning. *N Engl J Med* 2009;361(23):2221-2229.
- Hasegawa M, Sone S, Takashima S, et al. Growth rate of small lung cancers detected on mass CT screening. *Br J Radiol* 2000;73(876):1252-1259.