

Femoral Component Revision with Use of Impaction Bone-Grafting and a Cemented Polished Stem

A Concise Follow-up, at Fifteen to Twenty Years, of a Previous Report*

Martijn A.J. te Stroet, MD, Jean W.M. Gardeniers, MD, PhD, Nico Verdonshot, PhD, Wim H.C. Rijnen, MD, PhD, Tom J.J.H. Slooff, MD, PhD, and B. Willem Schreurs, MD, PhD

Investigation performed at the Department of Orthopaedics, Radboud University Nijmegen Medical Centre, Nijmegen, the Netherlands

Abstract: We previously reported our results for thirty-three consecutive femoral component revisions with impaction bone-grafting, performed with the X-change femoral revision system and a cemented polished Exeter stem, at a minimum of eight years of follow-up. The present updated study shows the results after fifteen to twenty years. One stem was revised again for mechanical reasons during a rerevision of an acetabular cup. The probability of survival at seventeen years was 96% (95% confidence interval [CI], 72% to 99%) with a femoral rerevision for any reason as the end point and 100% (95% one-sided CI, 69% to 100%) with rerevision for aseptic loosening as the end point. The average subsidence was 3 mm and stable relative to our previous report. Although three early femoral fractures occurred after this surgery, in this update no additional fractures were seen. In conclusion, the probability of survival of femoral component revisions with impaction bone-grafting and a cemented polished stem was excellent at a mean of seventeen years.

Level of Evidence: Therapeutic Level IV. See Instructions for Authors for a complete description of levels of evidence.

Background

Previously, we reported the clinical and radiographic outcomes of the first thirty-three consecutive femoral revisions, including the learning curve, performed with the impaction bone-grafting technique with use of the X-change femoral revision system (Stryker Howmedica, Newbury, United Kingdom) and a cemented polished Exeter stem¹. This procedure was the first femoral revision in fourteen patients, the second in eighteen patients, and the third in one patient. The average duration of follow-up was 10.4 years (range, eight to thirteen years). The Kaplan-Meier analysis showed that the probability of survival of the femoral component was 100% (95% one-sided confidence interval [CI], 100% to 91%) with rerevision of the femoral component for any reason as the end point and 85% (95% CI, 72% to 99%) with reoperation for any reason as the end point¹. The average subsidence of the femoral stem within the cement mantle was 3 mm, with seven stems that migrated ≥ 5 mm. There were three postoperative femoral fractures, which all healed after

surgery with use of plate fixation, and none of these stems had failed at the time of follow-up. The purpose of the present study was to update the clinical and radiographic results of our previous report after a mean duration of follow-up of seventeen years (range, fifteen to twenty years).

Methods

The study was approved by our institutional review board. Between March 1991 and February 1996, thirty-three consecutive femoral revisions were performed with the impaction bone-grafting technique, with use of the X-change femoral revision system and a cemented polished Exeter stem, in thirty-three patients. The surgical technique has been previously described in detail². In addition to the standard technique, the calcar region was reinforced with metal mesh and cerclage wires in twelve hips, and a distal femoral segmental defect was also augmented with metal mesh in seven of them. In another seven hips, only cerclage wires were used to support the weakened proximal cortical bone to prevent fracturing during the impaction process. Thirty-one acetabular cups were also revised at the same surgery.

For this update report, we reviewed all femoral revisions at a minimum follow-up period of fifteen years. All patients were prospectively followed annually or biennially for at least fifteen years or until rerevision or death.

*Original Publication

Schreurs BW, Arts JJ, Verdonshot N, Buma P, Slooff TJ, Gardeniers JW. Femoral component revision with use of impaction bone-grafting and a cemented polished stem. *J Bone Joint Surg Am*. 2005 Nov;87(11):2499-507.

Disclosure: One or more of the authors received payments or services, either directly or indirectly (i.e., via his or her institution), from a third party in support of an aspect of this work. In addition, one or more of the authors, or his or her institution, has had a financial relationship, in the thirty-six months prior to submission of this work, with an entity in the biomedical arena that could be perceived to influence or have the potential to influence what is written in this work. No author has had any other relationships, or has engaged in any other activities, that could be perceived to influence or have the potential to influence what is written in this work. The complete **Disclosures of Potential Conflicts of Interest** submitted by authors are always provided with the online version of the article.

Femoral bone-stock defects were classified with use of the system of the Endoklinik³ (see Appendix). Radiographic evidence of bone-graft incorporation was defined as equal radiodensity of graft and host bone, with a trabecular pattern throughout, according to Conn et al.⁴. Subsidence of the femoral stem was determined with the method of Fowler et al.⁵, and radiolucent lines between the cement and the bone were scored with use of the classification system of Gruen et al.⁶. As of the last review in 2011, all living patients with surviving hips had had clinical and radiographic examinations and a Harris hip score had been obtained. All patients who died during the period of follow-up were followed on a regular basis until their death, and their data were included in this report. Failure was defined clinically as the need for rerevision of the femoral component for any reason. Radiographic failure was defined as a circumferential radiolucent line in all seven Gruen zones evaluated on anteroposterior radiographs of the proximal part of the femur.

Kaplan-Meier analysis was performed with four different end points: a rerevision of the femoral component for any reason, a rerevision of the femoral component for aseptic loosening, a femoral reoperation for any reason, or subsidence of ≥ 5 mm. Kaplan-Meier survivorship analysis was performed for the whole group of hips treated with femoral reconstruction and included 95% CIs.

Source of Funding

Stryker Howmedica Osteonics paid or directed, or agreed to pay or direct, benefits to a research fund, foundation, educational institution, or other charitable or nonprofit organization with which the authors are affiliated or associated. On the basis of the Stryker grant to our research fund, the researchers could be paid to perform this study.

Results

Clinical Results

Of the original group of thirty-three patients (thirty-three hips), no patient was lost to follow-up. Nineteen patients (nineteen implants) had died of causes unrelated to the surgery. At the time of final follow-up, thirteen surviving hips were in situ in thirteen patients (mean age, seventy-three years; range, fifty-two to eighty-seven years). Twelve patients were clinically and radiographically evaluated after a mean follow-up period of seventeen years (range, fifteen to twenty years). Unfortunately, one patient was unable to attend because of advanced age and comorbidity; however, by telephone, the patient reported no reoperation and no apparent clinical symptoms of femoral loosening. There was no pain and the hip was functioning well. The average Harris hip score of the surviving patients declined from a mean of 85 points (range, 68 to 100 points) at the time of the previous report to 76 points (range, 51 to 100 points) at the current review.

Rerevisions

One rerevision of a femoral component was performed thirteen years after the first revision surgery. However, the primary indication for this rerevision was aseptic loosening of the cup. During this procedure, it was decided to remove the stem and perform a cement-in-cement rerevision with the Exeter Short Revision Stem (Stryker Howmedica) because of a distal cortex perforation of the original revision stem, as described in the previous report. The stem showed no signs of loosening and during rerevision no osteolysis was seen (see Appendix).

Radiographic Results

Radiographic follow-up was complete for twenty-three hips (70%), which were used for further analysis. Data were incomplete for nine patients (nine hips) who had died and for the patient who was unable to attend. For these patients, the latest radiographs available were used. None of the patients had migration of the cement mantle of the femoral stem relative to the bone; however, there was an average subsidence of the stem of 3 mm (range, 0 to 14 mm) at the time of follow-up. Eleven stems showed no signs of migration, and seven stems (all described in the first report) showed migration of ≥ 5 mm, including the hip that was rerevised because of perforation through the distal cortical window. Three stems had an additional subsidence of 1 mm compared with our first report, resulting in a total subsidence of 3, 3, and 4 mm. The stems with available radiographic follow-up that had migrated ≥ 5 mm, as described in our first report, showed no additional subsidence at the time of follow-up. Of the six hips with radiolucent lines described in our first report, only one hip had lines that were progressive. In this patient, an osteolytic defect situated in Gruen zone 1 had increased in size from 10×4 mm at the time of our first report to 16×6.5 mm at the current report. One patient had new radiolucent lines in Gruen zones 1 and 2. None of the hips demonstrated a circumferential radiolucent line. Signs of trabecular incorporation and cortical bone remodeling were difficult to quantify as metal meshes often obscured these interfaces. The zones that could be evaluated demonstrated evidence of

TABLE I Probability of Survival of the Femoral Component for Different Periods of Follow-up and End Points

	5 Years*		10 Years*		15 Years*		17 Years*	
	Survival (95% CI)	No.	Survival (95% CI)	No.	Survival (95% CI)	No.	Survival (95% CI)	No.
Rerevision for any reason	100% (90%-100%)	29	100% (89%-100%)	25	96% (72%-99%)	18	96% (72%-99%)	8
Rerevision for aseptic loosening	100% (90%-100%)	29	100% (89%-100%)	25	100% (85%-100%)	18	100% (69%-100%)	8
Reoperation for any reason	91% (74%-97%)	26	87% (69%-95%)	22	83% (63%-93%)	16	83% (63%-93%)	7
Subsidence of ≥ 5 mm	88% (70%-95%)	23	78% (57%-90%)	16	73% (51%-87%)	12	73% (51%-87%)	4

*CI = confidence interval, and no. = number of patients at risk.

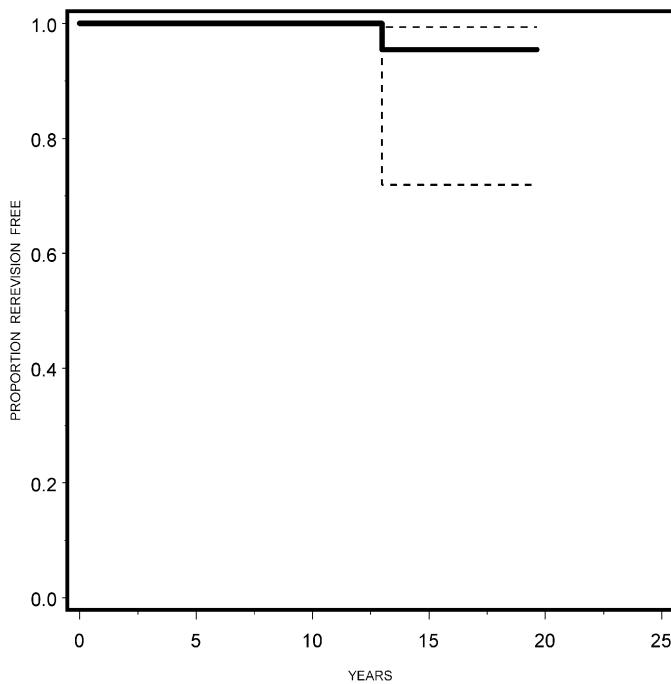


Fig. 1-A

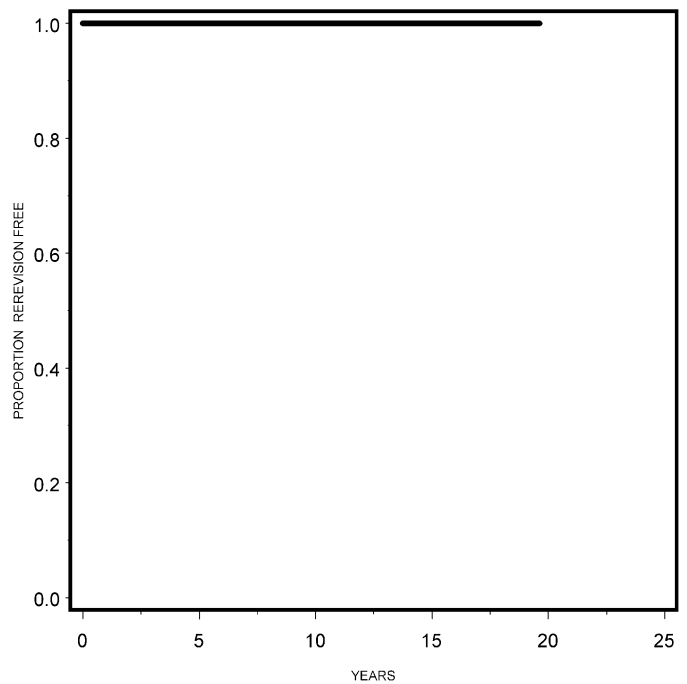


Fig. 1-B

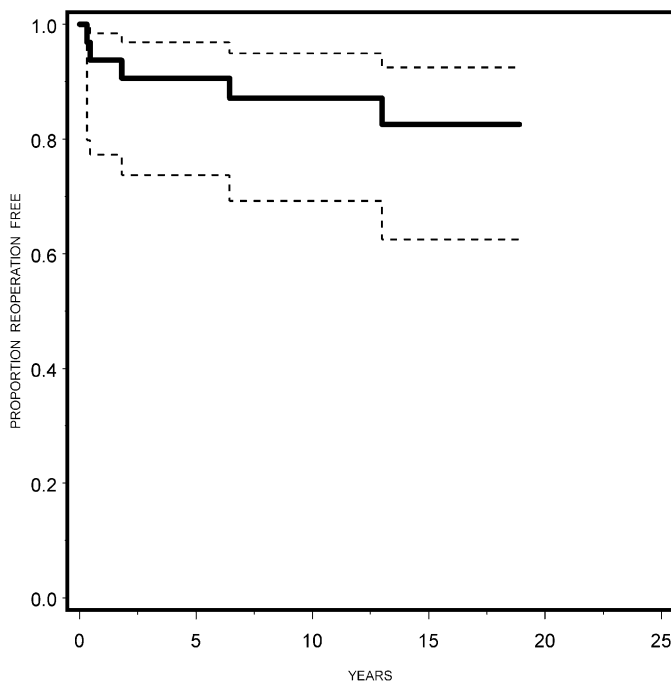


Fig. 1-C

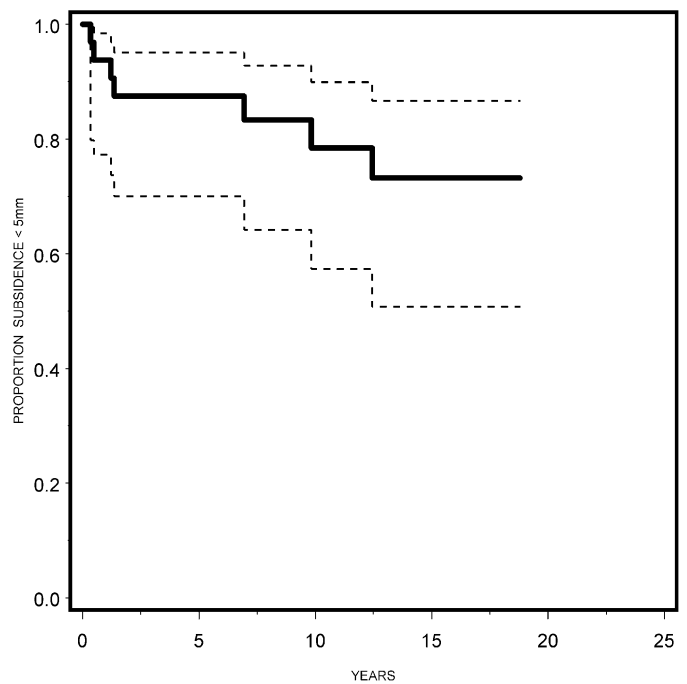


Fig. 1-D

Kaplan-Meier survival curves with the end points of rerevision of the femoral component for any reason (**Fig. 1-A**), rerevision of the femoral component for aseptic loosening (**Fig. 1-B**), femoral reoperation for any reason (**Fig. 1-C**), and subsidence of ≥ 5 mm (**Fig. 1-D**). The broken lines indicate the 95% confidence intervals.

trabecular incorporation in 90% (167 of 186) and cortical remodeling in 29% (fifty-four of 186).

Additional Reoperations and Complications

As noted in our previous report, four additional reoperations on the femoral side were performed. Since our previous report, one acetabular rerevision was performed because of aseptic

loosening of the cup; in this case, the stem was exchanged with the cement-in-cement technique (see Appendix).

Survivorship Analysis

Kaplan-Meier analysis showed the probability of survival of the femoral component, with rerevision for any reason as the end point, at seventeen years was 96% (95% CI, 72% to 99%) (Fig.

1-A). The probability of survival at seventeen years, with re-revision for aseptic loosening as end point, was 100% (95% one-sided CI, 69% to 100%) (Fig. 1-B), and the probability of survival at seventeen years, with femoral reoperation for any reason as the end point, was 83% (95% CI, 63% to 93%) (Fig. 1-C). With subsidence of the femoral stem of ≥ 5 mm as the end point, the probability of survival at seventeen years was 73% (95% CI, 51% to 87%) (Fig. 1-D). The probability of survival of the femoral component at different periods of follow-up and for different end points is shown in Table I.

Conclusions

To our knowledge, this is the first clinical study with a fifteen to twenty-year clinical and radiographic follow-up of the results of femoral revisions performed with use of this relatively new, instrumented impaction bone-grafting technique.

Compared with the results of our previous study¹, the survival rates remain excellent and the survival did not deteriorate with a longer follow-up period. Only one femoral component was re-revised with use of a cement-in-cement technique during a re-revision of the cup. However, the overall clinical scores had deteriorated. This result probably reflects the relative higher age of the patients and, as a result of that, the lower level of function.


A limitation of our study is that, as a result of the long duration of follow-up after femoral revision, only fourteen patients were alive at the final review in February 2011. However, the follow-up was nearly complete, including for the patients who had died, and the fate of every reconstruction was known. Unfortunately, not all radiographic files were complete.

The probability of survival of 100% (95% one-sided CI, 69% to 100%) at seventeen years, with an end point of re-revision of the femoral component for aseptic loosening, is comparable with other long-term reports. Ornstein et al.⁷ reported an excellent survivorship at fifteen years of 99.1% (95% CI, 98.4% to 99.5%) in an impressive group of 1305 revisions identified from the Swedish registry. Seventy re-revisions were performed during follow-up. However, in their study, there was no analysis of clinical scores or radiographs, so potential failures or early ra-

diographic signs may have been missed. Wraighte and Howard⁸ reported results of a series of seventy-five revisions reviewed at a mean of 10.5 years. Survivorship with any further femoral operation as the end point was 92% (95% CI, 82% to 97%).

In conclusion, the probability of survival was excellent at seventeen years following femoral revision with the X-change femoral revision system, impaction of fresh-frozen bone grafts, and insertion of a cemented polished stem. This technique is very useful for the purpose of restoring bone stock in patients with femoral defects that require revision total hip arthroplasty. For over twenty years, we have used this technique as our standard femoral revision technique in patients with femoral bone-stock loss.

Appendix

 A table showing patient demographics and a figure showing preoperative and one-year postoperative radiographs of a femoral component that had a re-revision with an Exeter Short Revision Stem are available with the online version of this article as a data supplement at jbjs.org. ■

NOTE: The authors thank Dr. Jan Hendriks for his statistical support.

Martijn A.J. te Stroet, MD
Jean W.M. Gardeniers, MD, PhD
Nico Verdonschot, PhD
Wim H.C. Rijnen, MD, PhD
Tom J.J.H. Slooff, MD, PhD
B. Willem Schreurs, MD, PhD
Department of Orthopaedics 357,
Radboud University Nijmegen Medical Centre,
P.O. Box 9101, 6500HB Nijmegen, The Netherlands.
E-mail address for M.A.J. te Stroet: m.testroet@orthop.umcn.nl.
E-mail address for B.W. Schreurs: b.schreurs@orthop.umcn.nl.
E-mail address for N. Verdonschot: n.verdonschot@orthop.umcn.nl.
E-mail address for W.H.C. Rijnen: w.rijnen@orthop.umcn.nl.
E-mail address for T.J.J.H. Slooff: tslooff@gmail.com.
E-mail address for J.W.M. Gardeniers: j.gardeniers@orthop.umcn.nl

References

- Schreurs BW, Arts JJ, Verdonschot N, Buma P, Slooff TJ, Gardeniers JW. Femoral component revision with use of impaction bone-grafting and a cemented polished stem. *J Bone Joint Surg Am.* 2005 Nov;87(11):2499-507.
- Schreurs BW, Arts JJ, Verdonschot N, Buma P, Slooff TJ, Gardeniers JW. Femoral component revision with use of impaction bone-grafting and a cemented polished stem. Surgical technique. *J Bone Joint Surg Am.* 2006 Sep;88 Suppl 1 Pt 2:259-74.
- Engelbrecht E, Heinert K. Klassifikation und Behandlungsrichtlinien von Knochensubstanzverlusten bei Revisionsoperationen am Huftgelenk: mittelfristige Ergebnisse. In: *Primare und Revisionsalloarthroplastik Hrsg-Endo-Klinik Hamburg*: Springer; 1987. p 189-201.
- Conn RA, Peterson LFA, Stauffer RN, Ilstrup D. Management of acetabular deficiency: long-term results of bone grafting in the acetabulum in total hip arthroplasty. *Trans Orthop Res Soc.* 1985;9:451-2.
- Fowler JL, Gie GA, Lee AJ, Ling RS. Experience with the Exeter total hip replacement since 1970. *Orthop Clin North Am.* 1988 Jul;19(3):477-89.
- Gruen TA, McNeice GM, Amstutz HC. "Modes of failure" of cemented stem-type femoral components: a radiographic analysis of loosening. *Clin Orthop Relat Res.* 1979 Jun;(141):17-27.
- Ornstein E, Linder L, Ranstam J, Lewold S, Eisler T, Torper M. Femoral impaction bone grafting with the Exeter stem - the Swedish experience: survivorship analysis of 1305 revisions performed between 1989 and 2002. *J Bone Joint Surg Br.* 2009 Apr;91(4):441-6.
- Wraighte PJ, Howard PW. Femoral impaction bone allografting with an Exeter cemented collarless, polished, tapered stem in revision hip replacement: a mean follow-up of 10.5 years. *J Bone Joint Surg Br.* 2008 Aug;90(8):1000-4.