

***Mycobacterium heckeshornense* Infection  
in an Immunocompetent Patient and  
Identification by 16S rRNA Sequence  
Analysis of Culture Material and a  
Histopathology Tissue Specimen**

Rob van Hest, Adri van der Zanden, Martin Boeree, Kristin  
Kremer, Mirjam Dessens, Pieter Westenend, Boulos  
Maraha, René van Uffelen, Ronald Schütte and Wiel de  
Lange

*J. Clin. Microbiol.* 2004, 42(9):4386. DOI:  
10.1128/JCM.42.9.4386-4389.2004.

---

Updated information and services can be found at:  
<http://jcm.asm.org/content/42/9/4386>

---

*These include:*

**REFERENCES**

This article cites 16 articles, 8 of which can be accessed free at:  
<http://jcm.asm.org/content/42/9/4386#ref-list-1>

**CONTENT ALERTS**

Receive: RSS Feeds, eTOCs, free email alerts (when new  
articles cite this article), [more»](#)

---

Information about commercial reprint orders: <http://journals.asm.org/site/misc/reprints.xhtml>  
To subscribe to to another ASM Journal go to: <http://journals.asm.org/site/subscriptions/>

---

## *Mycobacterium heckeshornense* Infection in an Immunocompetent Patient and Identification by 16S rRNA Sequence Analysis of Culture Material and a Histopathology Tissue Specimen

Rob van Hest,<sup>1\*</sup> Adri van der Zanden,<sup>2</sup> Martin Boeree,<sup>3</sup> Kristin Kremer,<sup>4</sup> Mirjam Dessens,<sup>4</sup>  
Pieter Westenend,<sup>5</sup> Boulos Maraha,<sup>6</sup> René van Uffelen,<sup>7</sup> Ronald Schütte,<sup>8</sup>  
and Wiel de Lange<sup>3</sup>

Department of Tuberculosis Control, Municipal Health Service Rotterdam, Rotterdam,<sup>1</sup> Department of Medical Microbiology and Infectious Diseases, Gelre Hospital, Apeldoorn,<sup>2</sup> University Lung Centre Dekkerswald, Groesbeek, and University Medical Centre Nijmegen, Nijmegen,<sup>3</sup> Department of Mycobacteriology, National Institute of Public Health and the Environment, Bilthoven,<sup>4</sup> Regional Laboratory of Pathology,<sup>5</sup> Chest Clinic, Albert Schweitzer Hospital,<sup>7</sup> and Department of Surgery, Albert Schweitzer Hospital,<sup>8</sup> Dordrecht, and Regional Laboratory of Medical Microbiology, Dordrecht/Gorinchem,<sup>6</sup> The Netherlands

Received 20 March 2004/Returned for modification 25 March 2004/Accepted 26 May 2004

***Mycobacterium heckeshornense* is a rare isolate in clinical specimens. We performed simultaneous 16S rRNA sequence analysis of a mycobacterium culture and a histopathology specimen to determine the relevance of *M. heckeshornense* infection in an immunocompetent patient initially presenting with pneumothorax.**

### CASE REPORT

In November 2001, a 43-year-old male technical drawer was admitted to the hospital because of right spontaneous partial pneumothorax. The medical history revealed left spontaneous pneumothorax at age 23, followed by left traumatic pneumothorax caused by a fractured-rib puncture after a car accident 3 years later. In January 2001, he suffered from acute inferior wall myocardial infarction. At that time a chest X-ray (CXR) showed an area of density in the right upper lobe (RUL) of the lungs, which was not evaluated further.

After pleural drainage, the right lung expanded completely, but 8 months later he developed a second pneumothorax at the right side. He had not complained of prolonged cough or fever in recent years. He had noticed episodes of night sweats, weight loss, and fatigue, for which he attended his general practitioner, who believed the complaints were caused by a viral infection. Human immunodeficiency virus serology was negative, and there were no indications of immune deficiency in his medical history. He had a smoking history of 25 pack years, i.e., the equivalent of 20 cigarettes/day for 25 years). He had no history of chronic obstructive pulmonary disease (COPD). Due to considerable air leakage after pleural drainage, a video-assisted thoracoscopy (VATS) with partial pleurectomy and bullectomy was performed. During this procedure, tissue with an abnormal aspect was seen in the apex of the right lung, and a posterolateral thoracotomy was done to excise the abnormal tissue.

Histopathological examination of the pleura tissue specimen recovered by the VATS procedure showed chronic inflammation and fibrosis and no granulomatous inflammation. Two lung tissue specimens with maximum diameters of 4 and 4.5 cm were recovered by the thoracotomy. On macroscopic examina-

tion, both had a granular cut surface, and in one a circumscribed brown-gray nodule of approximately 1 cm was seen. On microscopic examination, this nodule showed extensive necrosis with some nuclear dust and anthracosis, no granulocytes, and a rim of fibrotic tissue containing histiocytic cells and multinucleated giant cells (Fig. 1). Similar, smaller nodules were seen in the rest of the tissue. The surrounding lung tissue showed some fibrosis and chronic inflammation. With fluorescence microscopy of auramine-rhodamine-stained slides, numerous small golden-yellow-stained rods were seen. Microscopic examination of Ziehl-Neelsen-stained slides revealed the same rods but with only faint staining. The histopathological finding of a granulomatous inflammation with mycobacteria led to the provisional clinical diagnosis of pulmonary tuberculosis.

The tuberculin skin test was negative. In an attempt to obtain bacteriological proof of the diagnosis, fluid from a thoracotomy drain was collected. Antituberculous treatment was started with isoniazid, rifampin, pyrazinamide, and ethambutol. The complaints of intermittent night sweats, weight loss, and fatigue disappeared. After 2 months, pyrazinamide was stopped, and the patient continued taking the other drugs, including ethambutol, since the culture at that time was still negative.

The direct acid-fast stain of the drain fluid was negative. The fluid was cultured using two methods: the rapid mycobacterium detection method with liquid mycobacterium growth indicator tubes (BACTEC MGIT 960; Becton Dickinson, Alphen aan de Rijn, The Netherlands) and the solid Löwenstein-Jensen (LJ) medium. Two months later, the result of the MGIT culture was negative but the LJ medium showed a few colonies. A subsequent subculture from the LJ medium became positive 7 weeks later. The acid-fast stain of the isolate showed acid-fast bacilli. The AccuProbe culture identification test (Gen-Probe Inc., San Diego, Calif.) for *Mycobacterium tuberculosis* complex was negative. The isolate was sent to the National Institute of Public Health and the Environment

\* Corresponding author. Mailing address: Department of Tuberculosis Control, Municipal Health Service Rotterdam, P.O. Box 70032, 3000 LP Rotterdam, The Netherlands. Phone: 31 10 4339 657. Fax: 31 10 4339 950. E-mail: vanhestr@ggd.rotterdam.nl.

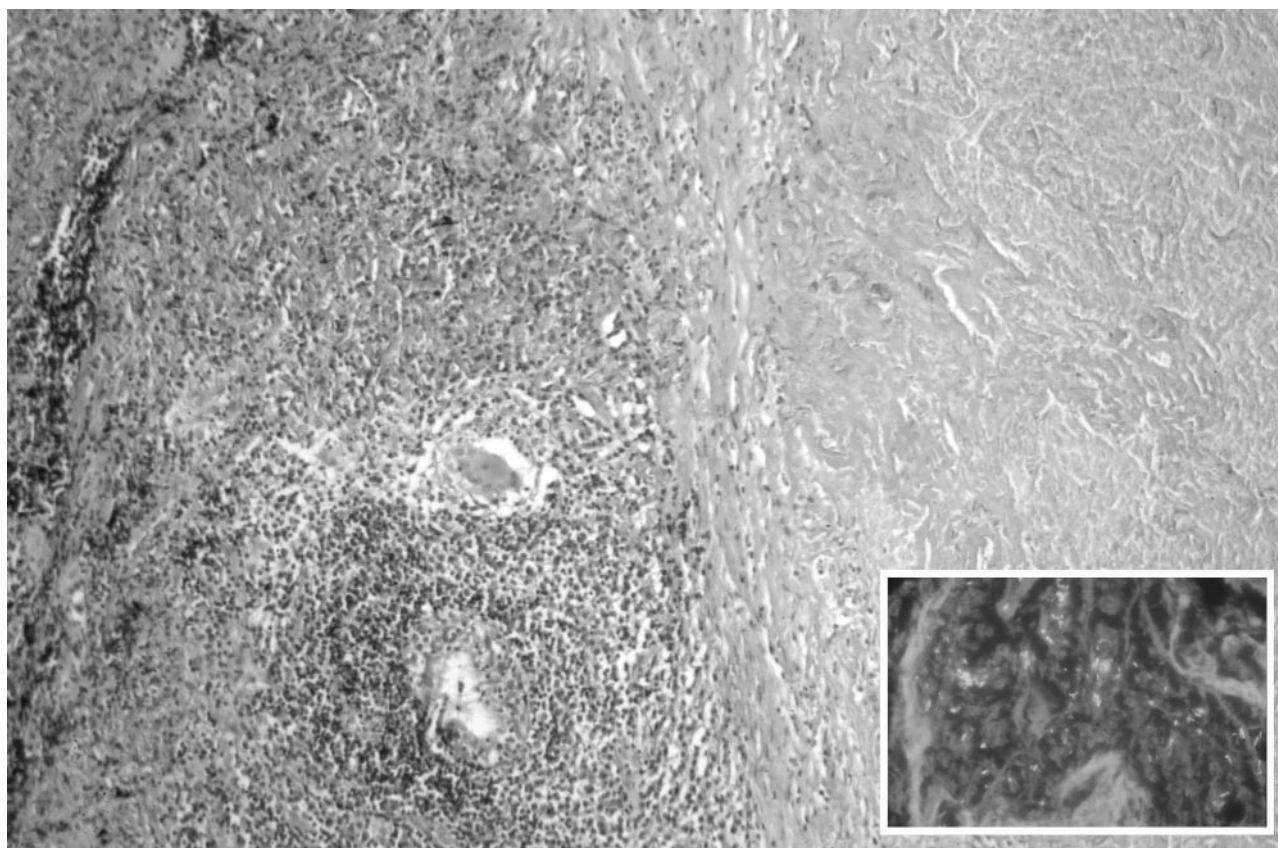


FIG. 1. Lung excision showing granulomatous inflammation: necrosis (right) with a rim of fibrosis containing histiocytes and an occasional multinucleated giant cell (hematoxylin-eosin staining; original magnification,  $\times 100$ ). The inset shows rod-like structures compatible with mycobacteria (auramine-rhodamine fluorescence; original magnification,  $\times 400$ ).

(RIVM) (Bilthoven, The Netherlands) for species identification. At the RIVM, the AccuProbe tests for *M. tuberculosis* complex and *Mycobacterium avium* complex were both negative. The definite determination was performed by DNA sequencing of the species-specific region of the 16S rRNA gene, as described earlier (6, 9). Comparison with known GenBank 16S rRNA gene sequences revealed *Mycobacterium heckeshornense*. Drug susceptibility testing showed that the isolate was susceptible to rifampin, streptomycin, cycloserine, protionamide, ciprofloxacin, clofazimine, clarithromycin, and rifabutin, intermediately sensitive to ethambutol and isoniazid, and resistant to amikacin.

To exclude colonization or instrument contamination during the VATS procedure, simultaneous 16S rRNA sequence analyses of the culture at the RIVM and of the formalin-fixed paraffin wax-embedded tissue specimen were performed. Extraction of DNA from the bacterial cells and paraffin wax-embedded tissues was done as described previously (16). PCR was performed with two oligonucleotide primers, 16S 8-27 F (5'-AGA GTT TGA TC[AC] TGG CTC AG-3') and 16S myc 300 R (5'-GGC CGG ACA CCC TCT C-3'). DNA amplification was done in 50- $\mu$ l reaction volumes containing 80 pmol of 16S 8-27 F, 40 pmol of 16S myc 300 R, and 25  $\mu$ l of Hot Start *Taq* master mix (QIAGEN, Westburg, Leusden, The Netherlands). Extracted DNA from the mycobacterium culture (1  $\mu$ l) and from the sections of the formalin-fixed paraffin wax-em-

bedded tissue (10  $\mu$ l) was added to the tubes, followed by an overlay of sterile mineral oil (Sigma-Aldrich, St. Louis, Mo.). The PCR program consisted of 15 min at 95°C followed by a touchdown of 20 s of denaturation at 95°C, 1 min of annealing, and 1 min of extension at 72°C. The annealing temperature was lowered from 66 to 52°C by 1°C per cycle. At 52°C, an additional 10 cycles were run, and the program ended with 72°C. Purification of the 301-bp PCR product to remove excess primers and nucleotides was performed with purification columns (QIAGEN). Sequencing was done by using fluorescence-labeled-dideoxynucleotide technology, using a 3100-Avant sequencer (Applied Biosystems, Foster City, Calif.). Sequences were assembled, edited, and analyzed with the DNASTar package (Fig. 2). These sequences were deposited in GenBank (accession number AF174290) and compared with known 16S rRNA sequences by applying a BLAST search. The DNA sequences from both strands of the mycobacterium culture and the histopathology specimen aligned 100% with that of the 16S rRNA gene of *M. heckeshornense*.

After 8 months, the simultaneous sequence analyses demonstrated the clinical relevance of the *M. heckeshornense* infection. Lacking any information on suggested therapy for *M. heckeshornense* infection, it was decided that treatment guidelines for *Mycobacterium xenopi* infection (10) would be followed because of the close phylogenetical relationship between these species. Isoniazid was discontinued, and rifampin

	129 region A		
<i>M. heckeshornense</i>	T G A C C T G C C C	T G C A C T T C G G	G A T A A G C C T G
Culture	. . . . .	. . . . .	. . . . .
Tissue	. . . . .	. . . . .	. . . . .
(continued from above)			
<i>M. heckeshornense</i>	G G A A A C T G G G	T C T A A T A C C G	G A T A G G A C C G
Culture	. . . . .	. . . . .	. . . . .
Tissue	. . . . .	. . . . .	. . . . .
(continued from above)			
<i>M. heckeshornense</i>	C G C C A T G C A T	G T G G T G T G G T	G G A A A G C G T G
Culture	. . . . .	. . . . .	. . . . .
Tissue	. . . . .	. . . . .	. . . . .
(continued from above)			
<i>M. heckeshornense</i>	T G G T A G T G G T	G T G G G A T G G G	C C C G C G G C C T
Culture	. . . . .	. . . . .	. . . . .
Tissue	. . . . .	. . . . .	. . . . .
(continued from above)			
<i>M. heckeshornense</i>	A T C A G C T T G T	T G G T G G G G T G	A T G
Culture	. . . . .	. . . . .	. . . . .
Tissue	. . . . .	. . . . .	. . . . .

FIG. 2. Comparison of 16S ribosomal DNA of *M. heckeshornense* (AF174290), the mycobacterium culture, and the formalin-fixed paraffin wax-embedded histopathology tissue specimen. Dots indicate identity.

and ethambutol were continued for 18 months in total. The CXRs did not change during treatment.

In 2000, a pathogenic slowly growing scotochromogenic mycobacterium species with unique 16S rRNA and 16S-23S spacer sequences was reported: *M. heckeshornense* (13). The novel *Mycobacterium* was repeatedly isolated from a 30-year-old immunocompetent patient with severe chronic bilateral cavitary lung disease, and a biopsy of the RUL revealed epithelioid cell granulomatosis. A second patient, also suffering from progressive cavitary lung disease and histologically confirmed epithelioid cell granuloma, was mentioned later (13a). An identical *Mycobacterium* species was already deposited in the GenBank database with the name "*Mycobacterium sydneyiensis*" (11). To our knowledge this is the third patient described with *M. heckeshornense* infection. Furthermore, our patient has an unusual presentation with pneumothorax.

Our diagnosis of *M. heckeshornense* as a pathogen meets the American Thoracic Society diagnostic criteria of nontubercu-

lous mycobacterial lung disease in human immunodeficiency virus-seronegative hosts, together with the modifications applied by Jiva and colleagues for clinical relevance of nontuberculous mycobacteria (1, 5). A suspicious infiltrate was seen in the RUL on a previous CXR in a patient with symptoms which cleared after the start of treatment. The pneumothorax may have been the result of the mycobacterium infection. A lung biopsy showed histopathological features of a mycobacterium infection with granulomatous inflammation and acid-fast bacilli, and a mycobacterial culture on LJ medium from drain fluid was positive for *M. heckeshornense*. The possibility of culture contamination in the present case, especially instrument-associated pseudoinfection as described for *M. xenopi* (2, 4, 17), is unlikely, since the amplification and sequencing of the 16S rRNA gene from both the culture isolate and the histopathological specimen were identical.

*M. heckeshornense* was previously isolated in The Netherlands from a 73-year-old patient with COPD after a CXR showed cavitating opacities in the RUL. Sputa were repeatedly Ziehl-Neelsen smear positive as well as culture positive on LJ

Downloaded from http://jcm.asm.org/ on July 9, 2012 by Universiteitsbibliotheek



slants. The AccuProbe test for *M. tuberculosis* complex was negative, and determination through 16S sequencing at the RIVM showed *M. heckeshornense*. The patient was treated with isoniazid, rifampin, clarithromycin, and levofloxacin. When *M. heckeshornense* was identified shortly afterwards in a 38-year-old patient in the same regional microbiology laboratory, this result was considered to be culture contamination and this patient received no treatment.

*M. heckeshornense* is phylogenetically closely related to *M. xenopi*. *M. xenopi* is recovered frequently from clinical isolates in southern England and the northwest coast of Europe but is relatively uncommon elsewhere (2, 12). In immunocompetent patients, clinical illness typically occurs as an indolent, cavitary lung infection in middle-aged men who have other underlying chronic pulmonary diseases, often COPD (5, 14). It is thought that reliable separation between *M. heckeshornense* and *M. xenopi* at present can be attained only by 16S rRNA DNA sequencing (15).

Spontaneous pneumothorax is described as a complication of pulmonary and miliary tuberculosis (3, 8). Nontuberculous mycobacterial infection complicated with pneumothorax is less often reported but was recently described for *M. avium* infection (7). Two theories have been postulated for the cause of pneumothorax in pulmonary tuberculosis: a rupture of the pleural cavity creates a bronchopleural fistula with spread of infection to the pleura; a second possible mechanism is the development of a submucosal bronchiolar lesion with air trapped in an acinus or subsegment, causing a bleb that can rupture to the pleural space (R. Belmonte and H. M. Crowe, Letter, Clin. Infect. Dis. 20:1565, 1995). Although, due to his medical history, this pneumothorax could be spontaneous, we assume that the mycobacterial process in the RUL perforated the pleural cavity.

Finally, 16S rRNA sequence analysis of a formalin-fixed paraffin wax-embedded histopathology tissue specimen proves to be a useful tool to determine the clinical significance of a culture of *M. heckeshornense*.

We thank Petra de Haas and Dick van Soolingen for valuable comments on an earlier version of the manuscript, Jessica de Beer for technical assistance, and Kees Hol for information on previous *M. heckeshornense* results.

#### REFERENCES

1. American Thoracic Society. 1997. Diagnosis and treatment of disease caused by nontuberculous mycobacteria. Am. J. Respir. Crit. Care Med. 156:S1–S25.
2. Bennett, S. N., D. E. Peterson, D. R. Johnson, W. N. Hall, B. Robinson-Dunn, and S. Dietrich. 1994. Bronchoscopy-associated *Mycobacterium xenopi* pseudoinfections. Am. J. Respir. Crit. Care Med. 150:245–250.
3. Blanco-Perez, J., J. Bordon, L. Pineiro-Amigo, R. Roca-Serrano, R. Izquierdo, and J. Abal-Arca. 1998. Pneumothorax in active pulmonary tuberculosis: resurgence of an old complication? Respir. Med. 92:1269–1273.
4. Gubler, J. G. H., M. Salfinger, and A. Von Graevenitz. 1992. Pseudoepidemic of non-tuberculous mycobacteria due to a contaminated bronchoscope cleaning machine—report of an outbreak and a review of the literature. Chest 101:1245–1249.
5. Jiva, T. M., H. M. Jacoby, L. A. Weymouth, D. A. Kaminski, and A. C. Portmore. 1997. *Mycobacterium xenopi*: innocent bystander or emerging pathogen? Clin. Infect. Dis. 24:226–232.
6. Kirschner, P., A. Meier, and E. Böttger. 1993. Genotypic identification and detection of mycobacteria—facing novel and uncultured pathogens, p. 173–190. In D. H. Persing, T. F. Smith, F. C. Tenover, and T. J. White (ed.), Diagnostic molecular microbiology. Mayo Foundation, Rochester, Minn.
7. Kobayashi, K., S. Yano, K. Kato, S. Saito, and T. Tokushima. 2002. A case of *Mycobacterium avium* pulmonary disease accompanied with pleural effusion. Kekkaku 77:725–728.
8. Mert, A., M. Bilir, C. Akman, R. Ozaras, F. Tabak, R. Ozturk, H. Senturk, and Y. Aktuglu. 2001. Spontaneous pneumothorax: a rare complication of miliary tuberculosis. Ann. Thorac. Cardiovasc. Surg. 7:45–48.
9. Mijls, W., P. de Haas, R. Rossau, T. van der Laan, L. Rigouts, F. Portaels, and D. van Soolingen. 2002. Molecular evidence to support a proposal to reserve the designation '*Mycobacterium avium* subsp. *avium*' to bird-type isolates and '*M. avium* subsp. *hominissuis*' to the human/porcine type of *M. avium*. Int. J. Syst. Evol. Microbiol. 52:1–14.
10. Research Committee of the British Thoracic Society. 2001. First randomised trial of treatments for pulmonary disease caused by *M. avium* intracellulare, *M. malmoense*, and *M. xenopi* in HIV negative patients: rifampicin, ethambutol and isoniazid versus rifampicin and ethambutol. Thorax 56:167–172.
11. Richter, E., S. Niemann, S. Ruesch-Gerdes, and D. Harmsen. 2001. Description of *Mycobacterium heckeshornense* sp. nov. J. Clin. Microbiol. 39:3023–3024.
12. Preheim, L. C. 1999. Other nontuberculous mycobacteria and *Mycobacterium bovis*, p. 401. In D. Schlosser (ed.), Tuberculosis and nontuberculous mycobacterial infections. W. B. Saunders Company, Philadelphia, Pa.
13. Roth, A., U. Reischl, N. Schönfeld, L. Naumann, S. Emler, M. Fischer, H. Mauch, R. Loddenkemper, and R. M. Kroppenstedt. 2000. *Mycobacterium heckeshornense* sp. nov., a new pathogenic slowly growing *Mycobacterium* sp. causing cavitary lung disease in an immunocompetent patient. J. Clin. Microbiol. 38:4102–4107.
- 13a. Roth, A., H. Mausch, N. Schönfeld, R. Loddenkemper, U. Reischl, L. Neumann, and R. M. Kroppenstedt. 2001. Description of *Mycobacterium heckeshornense* sp. nov. J. Clin. Microbiol. 39:3023–3024.
14. Simor, A. E., I. E. Salit, and H. Vellend. 1984. The role of *Mycobacterium xenopi* in human disease. Am. Rev. Respir. Dis. 129:435–438.
15. Torrko, P., M. L. Katila, M. Kontro. 2003. Gas-chromatographic lipid profiles in identification of currently known slowly growing environmental mycobacteria. J. Med. Microbiol. 52:315–323.
16. van der Zanden, A. G. M., A. H. Hoentjen, F. G. C. Heilmann, E. F. Weltevreden, L. M. Schouls, and J. D. van Embden. 1998. Simultaneous detection and strain differentiation of *Mycobacterium tuberculosis* complex in paraffin wax embedded tissues and in stained microscopic preparations. Mol. Pathol. 51:209–214.
17. Wallace, R. J., Jr., B. A. Brown, and D. E. Griffith. 1998. Nosocomial outbreaks/pseudo-outbreaks caused by nontuberculous mycobacteria. Annu. Rev. Microbiol. 52:453–490.